

# ATLAS OF CLINICAL MICROBIOLOGY

## Microscopic slides

*Authors: O. Melter, M. Šolarová, H. Nekvasilová, H. Svojtková, A. Píšová, P. Kabelíková, D. Lžičařová,  
S. Opálková, J. Hurych*

*© Department of Medical Microbiology, 2nd Faculty of Medicine, Charles University, Praha (2018)*



CHARLES UNIVERSITY  
Second Faculty of Medicine



CHARLES UNIVERSITY  
Second Faculty of Medicine

Slide No. 2

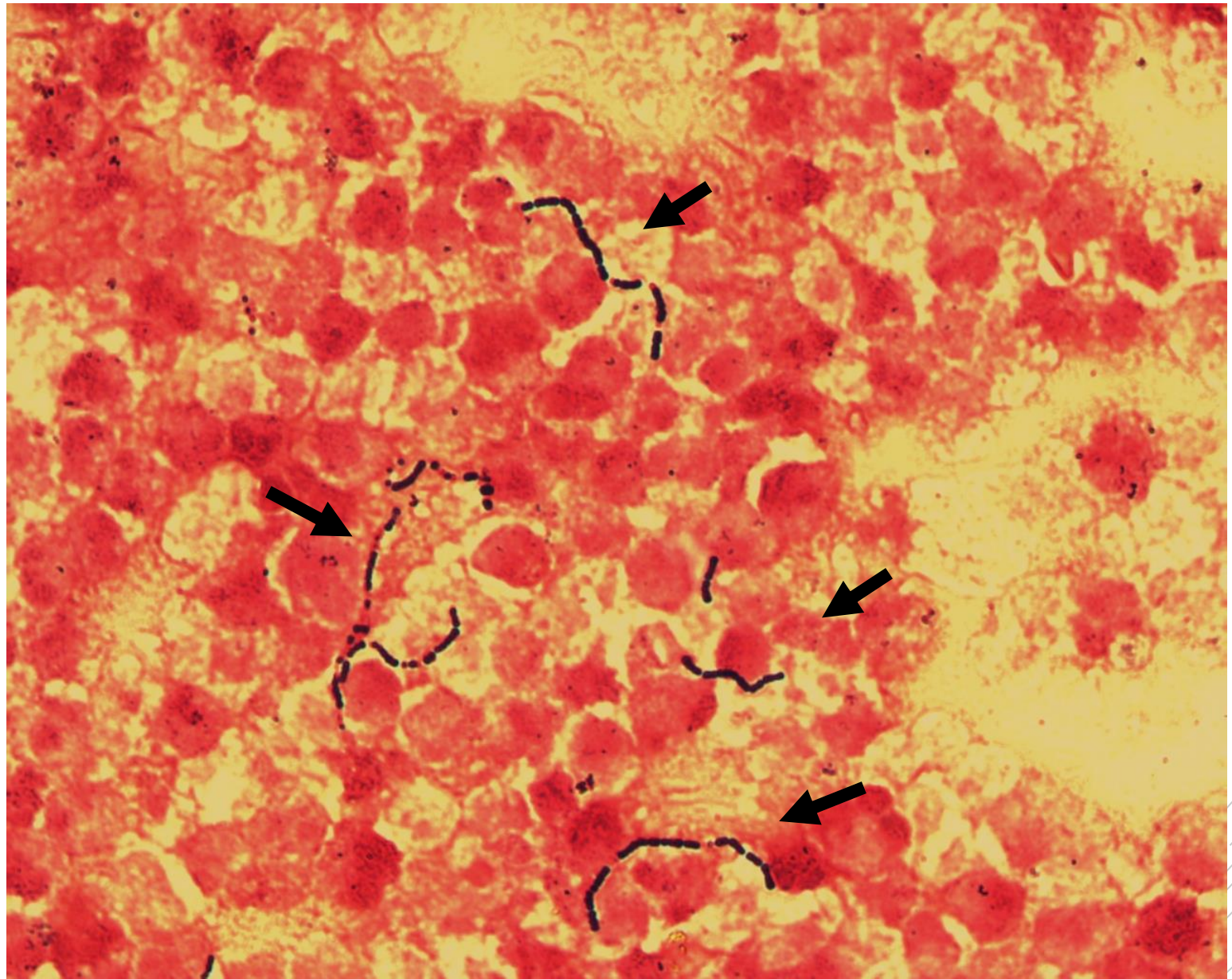
# *Streptococcus agalactiae*

**Material:** pus

**Patient:** man, 77 years old

**Dg:** periappendicular abscess

**Microscopy:** gram positive cocci in chains (see arrows)(further granulocytes, cellular debris)



Author: MUDr. Alena Píšová



CHARLES UNIVERSITY  
Second Faculty of Medicine

Slide No.5

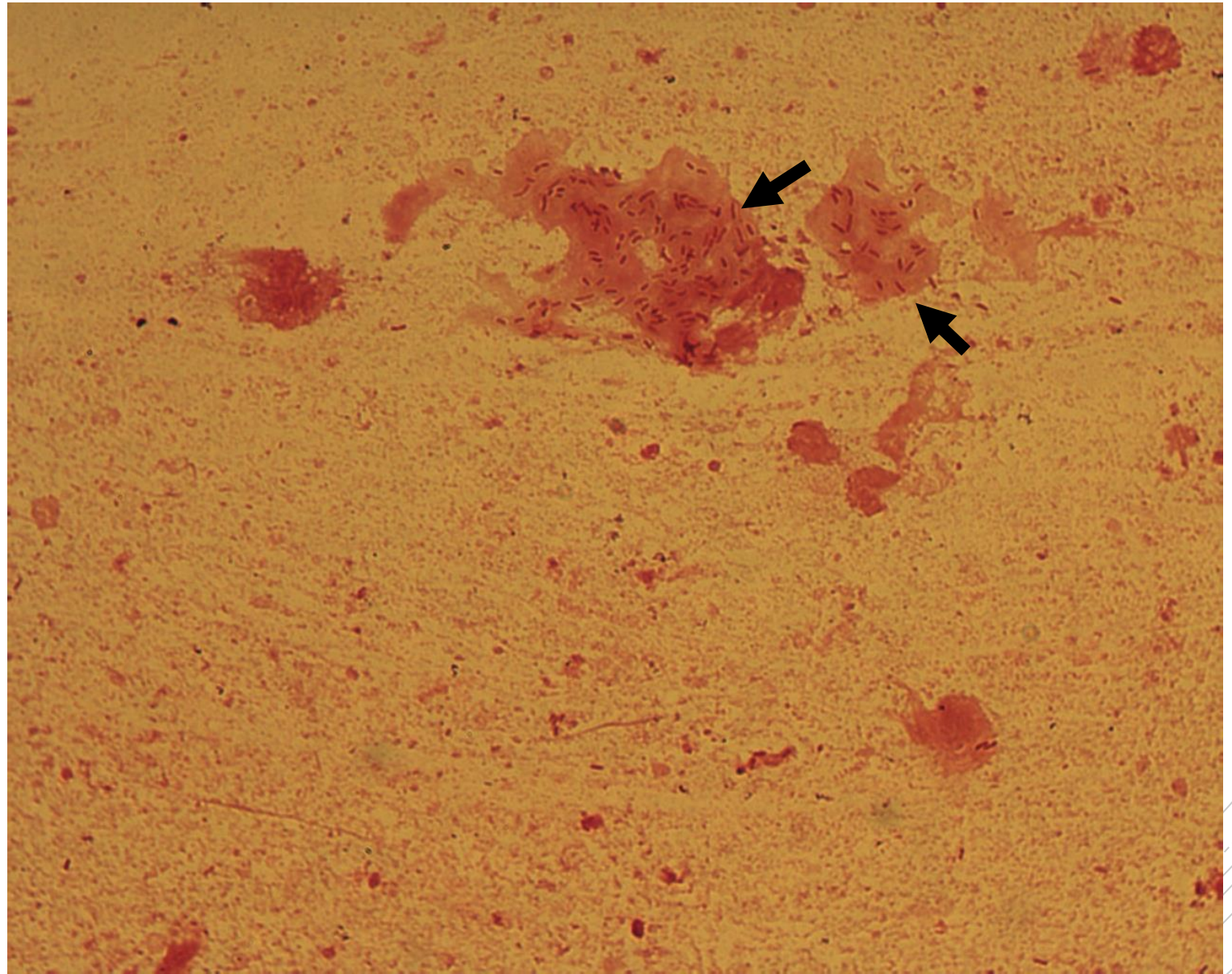
*Pseudomonas  
aeruginosa*

**Material:** sputum

**Patient:** man, 25 years old

**Dg:** exacerbation of cystic fibrosis

**Microscopy:** gram negative rods in  
biofilm (see arrows)(further cellular  
debris)



Author: doc. MVDr. Oto Melter, PhD.



CHARLES UNIVERSITY  
Second Faculty of Medicine

Slide No. 6

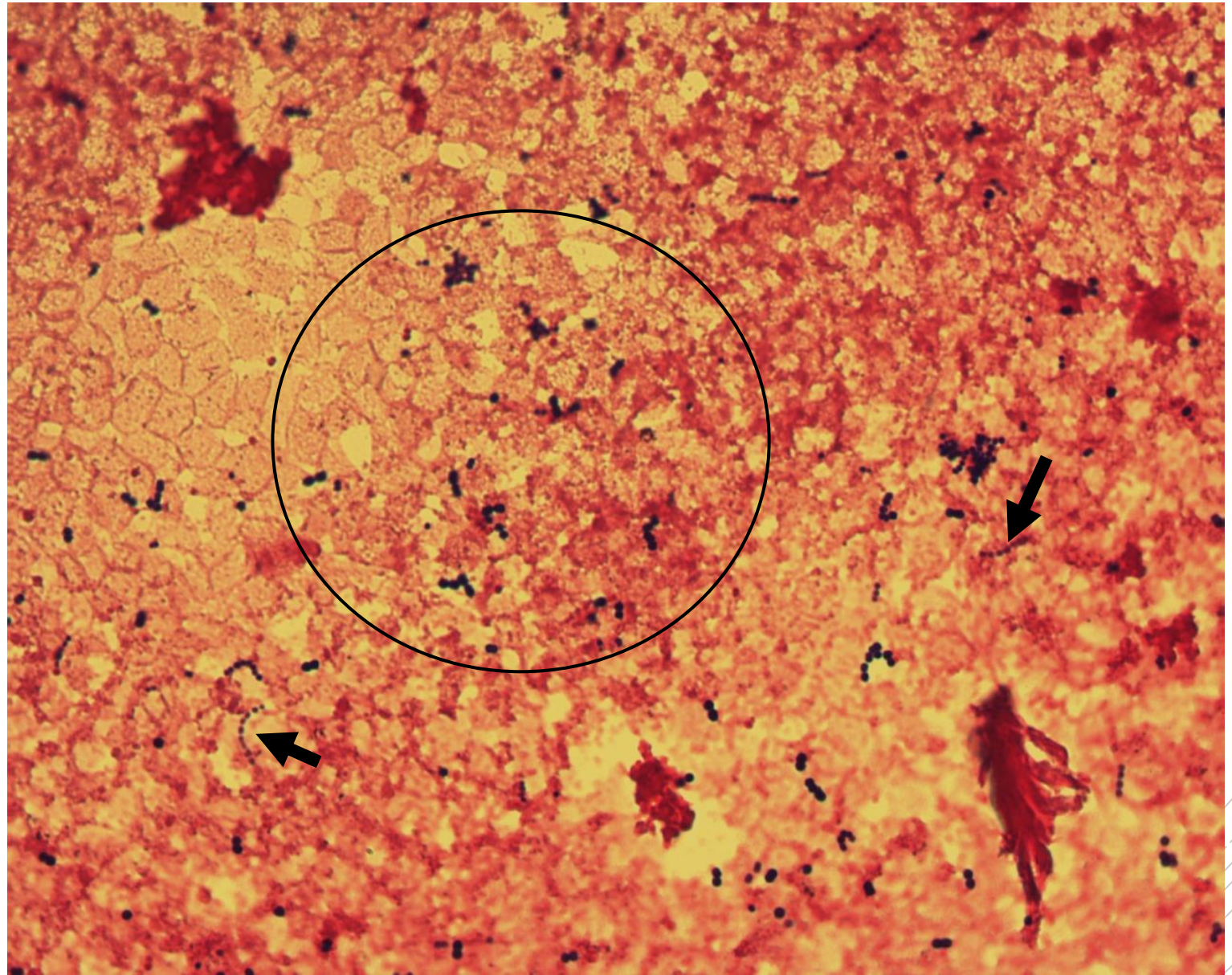
*Enterococcus  
faecalis*

**Material:** hemoculture

**Patient:** woman, 71 years old

**Dg:** cholangitis sepsis (recurrent cholangitis)

**Microscopy:** gram positive cocci in short chains (see circular section)(further cellular debris)



Author: MUDr. Petra Kabelíková



CHARLES UNIVERSITY  
Second Faculty of Medicine

Slide No. 8

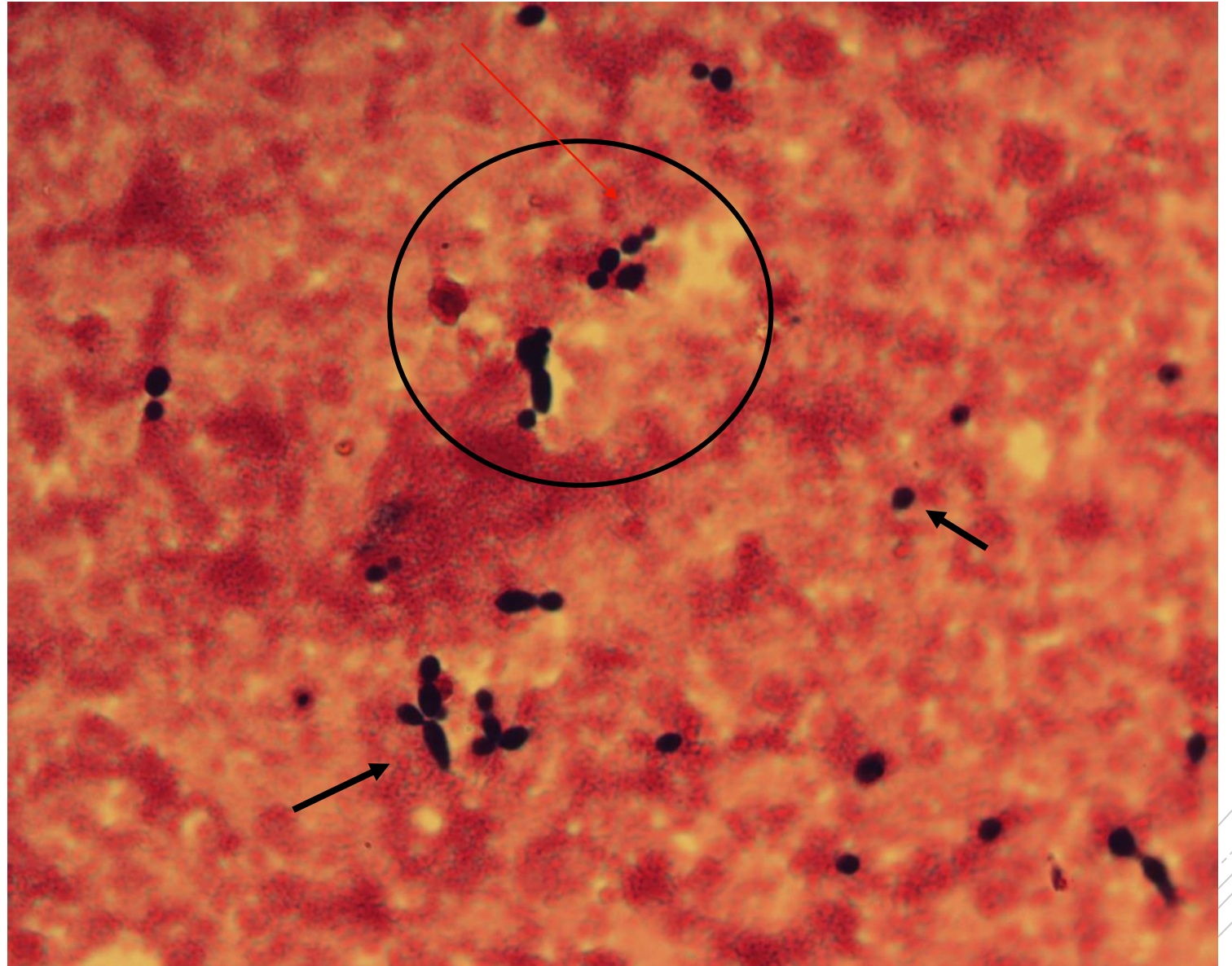
*Candida  
albicans*

**Material:** hemoculture

**Patient:** woman, 9 years old

**Dg:** catheter sepsis

**Microscopy:** yeast blastospores (see circular section and arrows)(further cellular debris)



Author : MUDr. Petra Kabelíková



CHARLES UNIVERSITY  
Second Faculty of Medicine

Slide No. 10

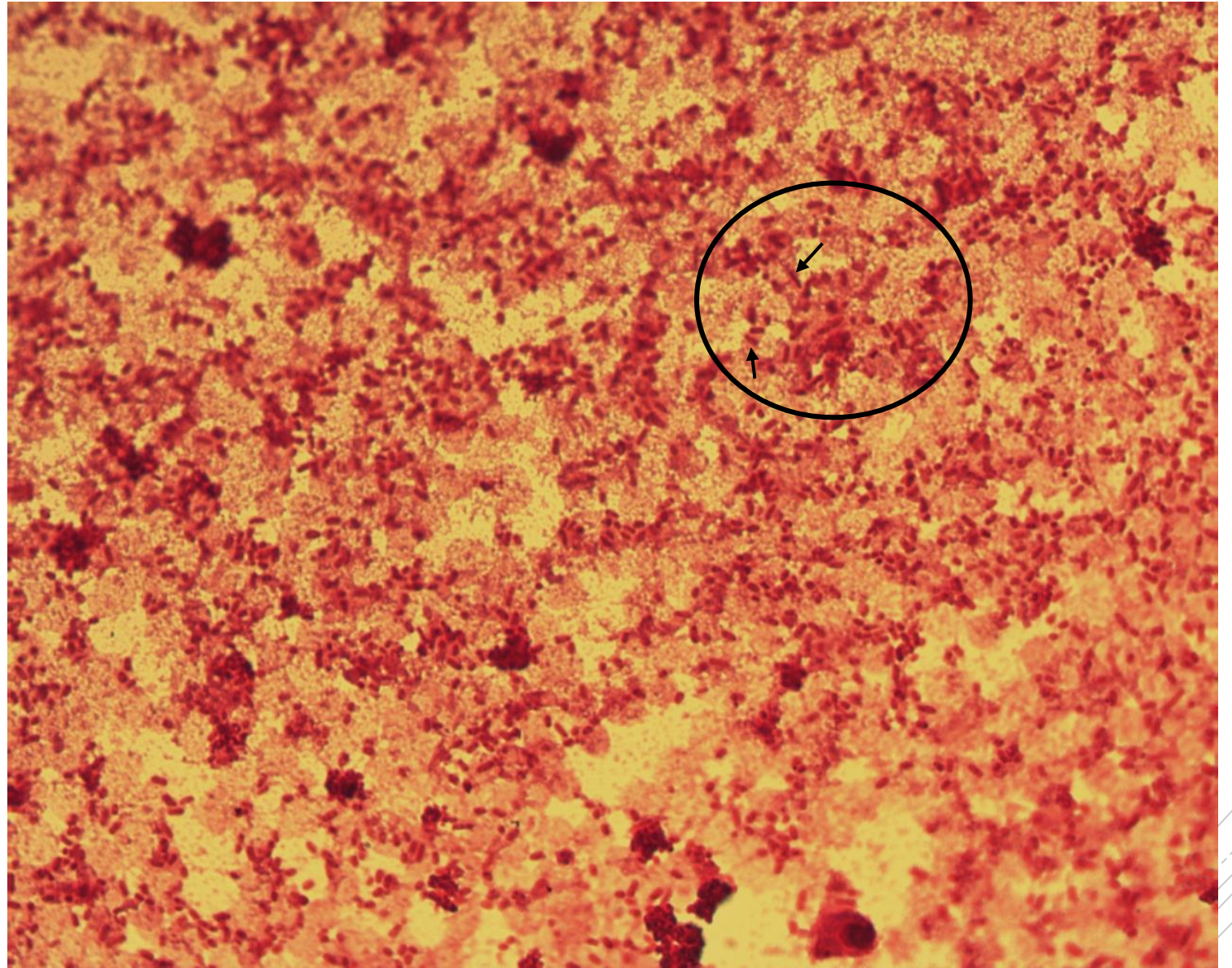
# *Enterobacter cloacae*

**Material:** hemoculture

**Patient:** man, 40 years old

**Dg:** sepsis of unknown origin

**Microscopy:** gram negative rods (see circular section) (further cellular debris and granulocytes)



Author : MUDr. Petra Kabelíková



CHARLES UNIVERSITY  
Second Faculty of Medicine

Slide No. 12

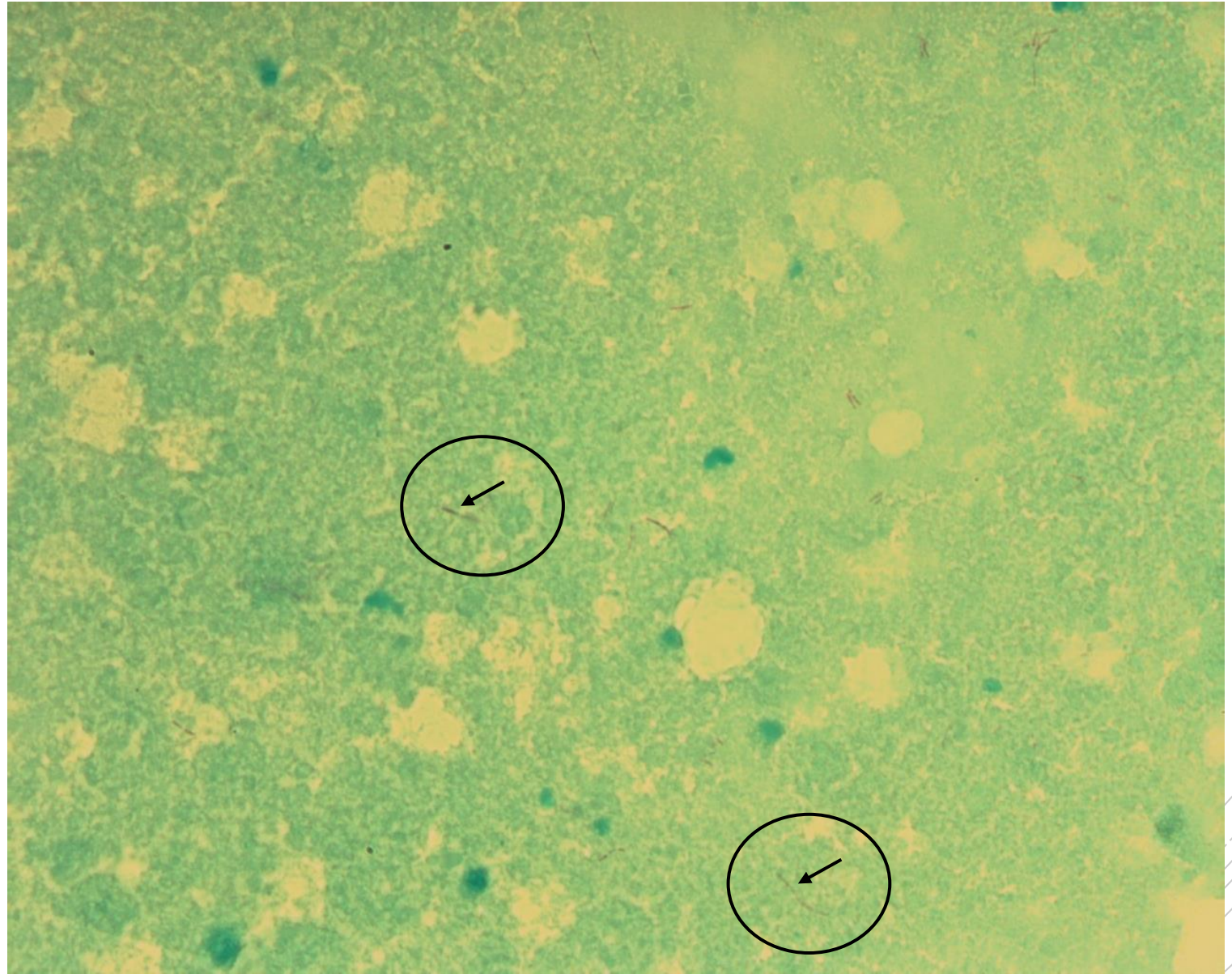
# *Mycobacterium tuberculosis*

**Material:** sputum

**Patient:** man, 45 years old

**Dg:** pneumonia with hemoptysis

**Microscopy:** acid-fast rods (see circular section)



Author: doc. MVDr. Oto Melter, PhD.



CHARLES UNIVERSITY  
Second Faculty of Medicine

Slide No. 15

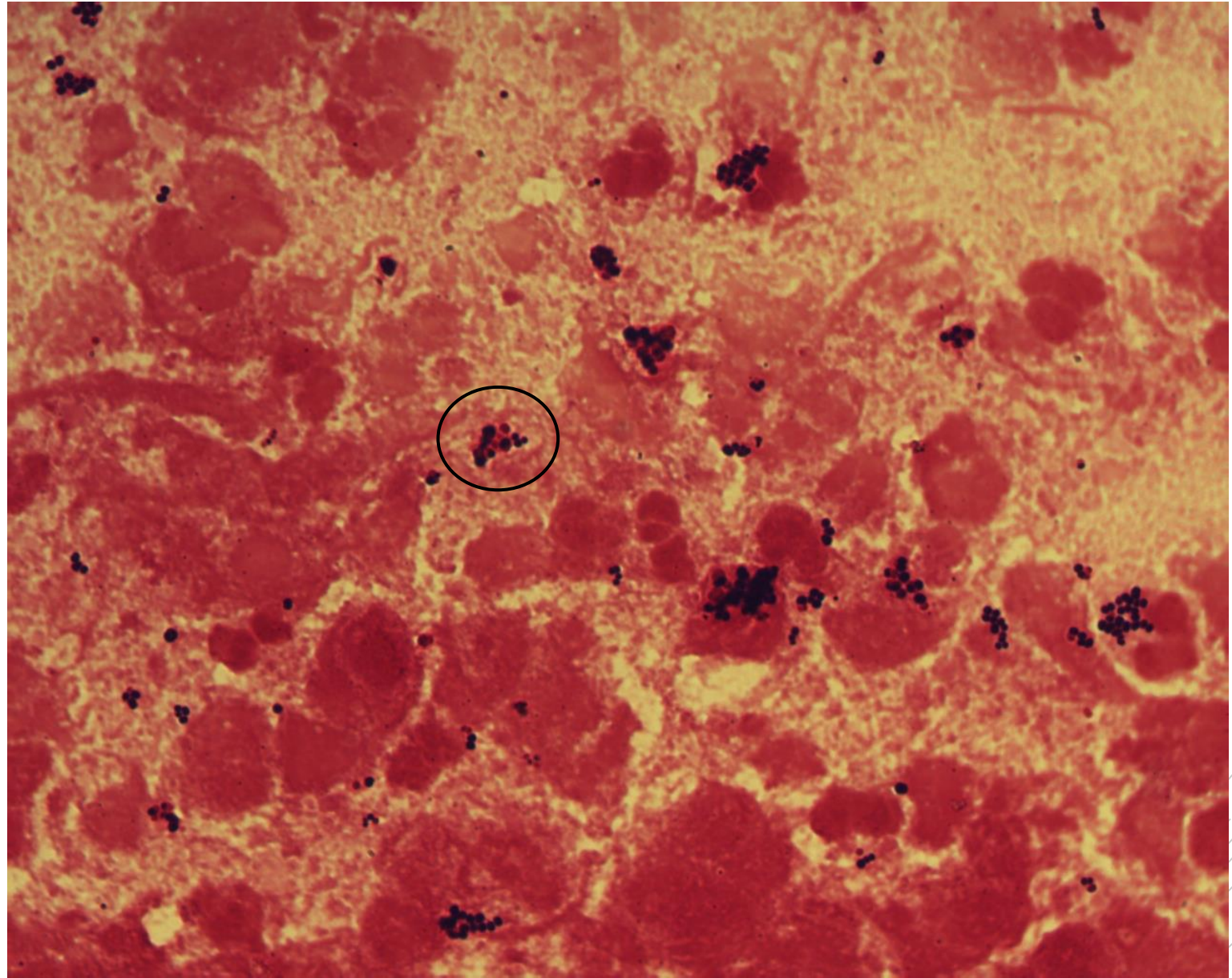
# *Staphylococcus aureus*

**Material:** sputum

**Patient:** woman, 21 years old

**Dg:** pneumonia

**Microscopy:** gram positive cocci forming typical clusters - grapes (see circular section) (further granulocytes and cellular debris)



Author: doc. MVDr. Oto Melter, PhD.





CHARLES UNIVERSITY  
Second Faculty of Medicine

Slide No. 17

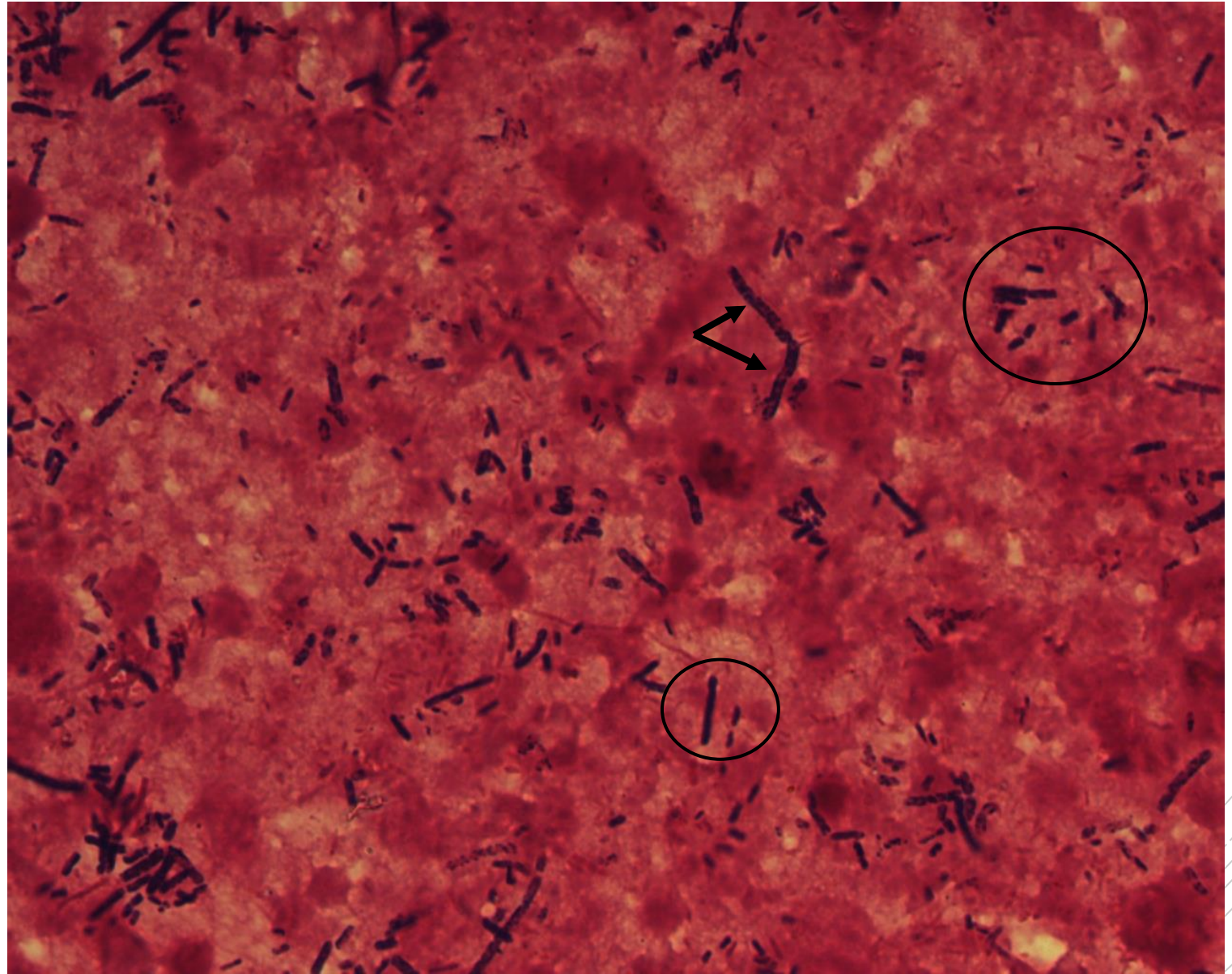
# *Clostridium perfringens*

**Material:** punctate of liver abscess

**Patient:** woman, 80 years old

**Dg:** liver abscess

**Microscopy:** gram positive elongated rods with blunt ends, spores in places (see circular section) (further granulocytes and cellular debris)



Author : MUDr. Alena Píšová



CHARLES UNIVERSITY  
Second Faculty of Medicine

Slide No. 18

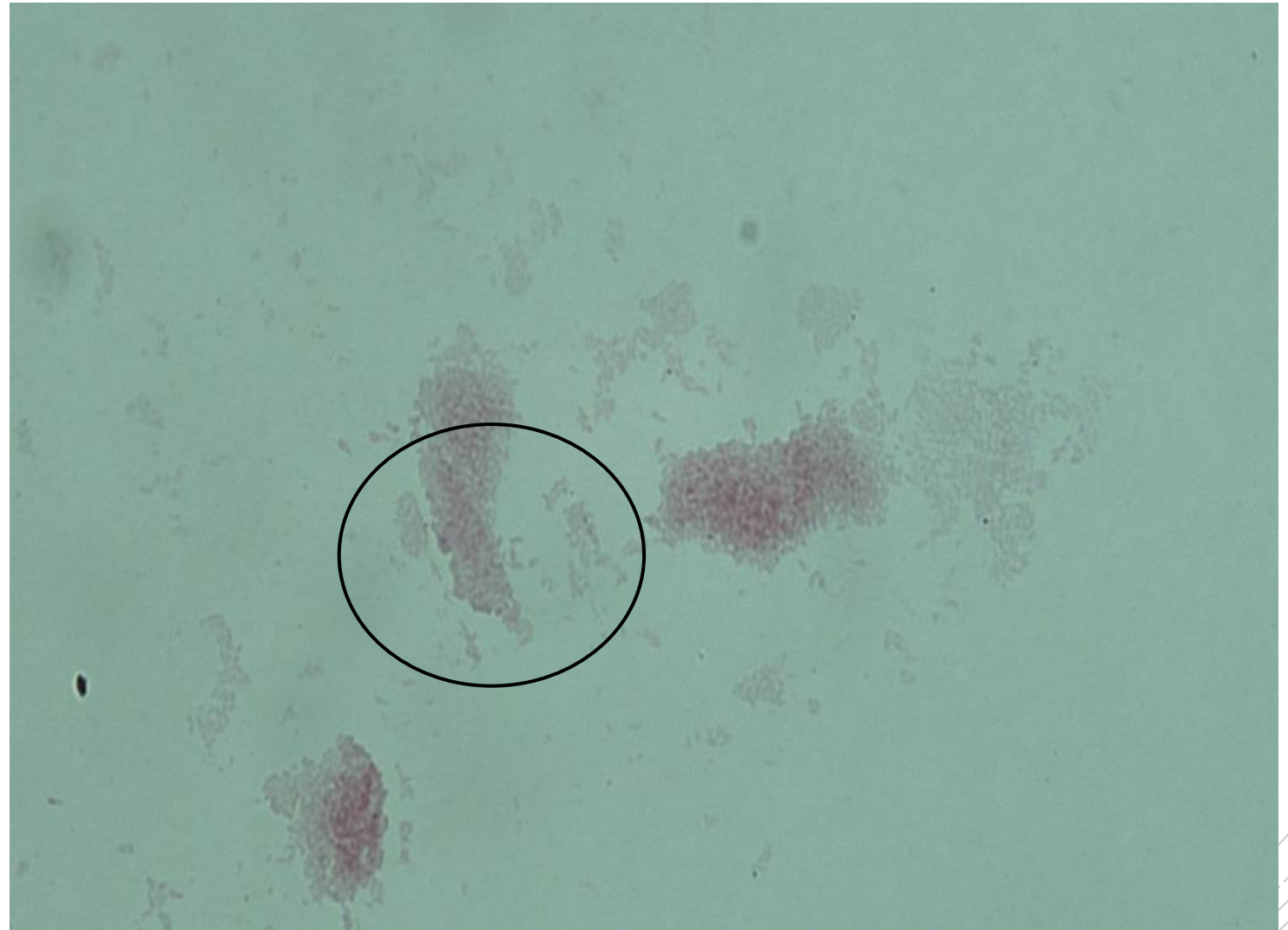
# *Bordetella pertussis*

**Material:** nasopharyngeal swab

**Patient:** woman, 26 years old

**Dg:** irritant cough

**Culture microscopy:** single gram  
negative cocci or clusters (see circular  
section)



Author: MUDr. Lenka Tritová



CHARLES UNIVERSITY  
Second Faculty of Medicine

Slide No. 19

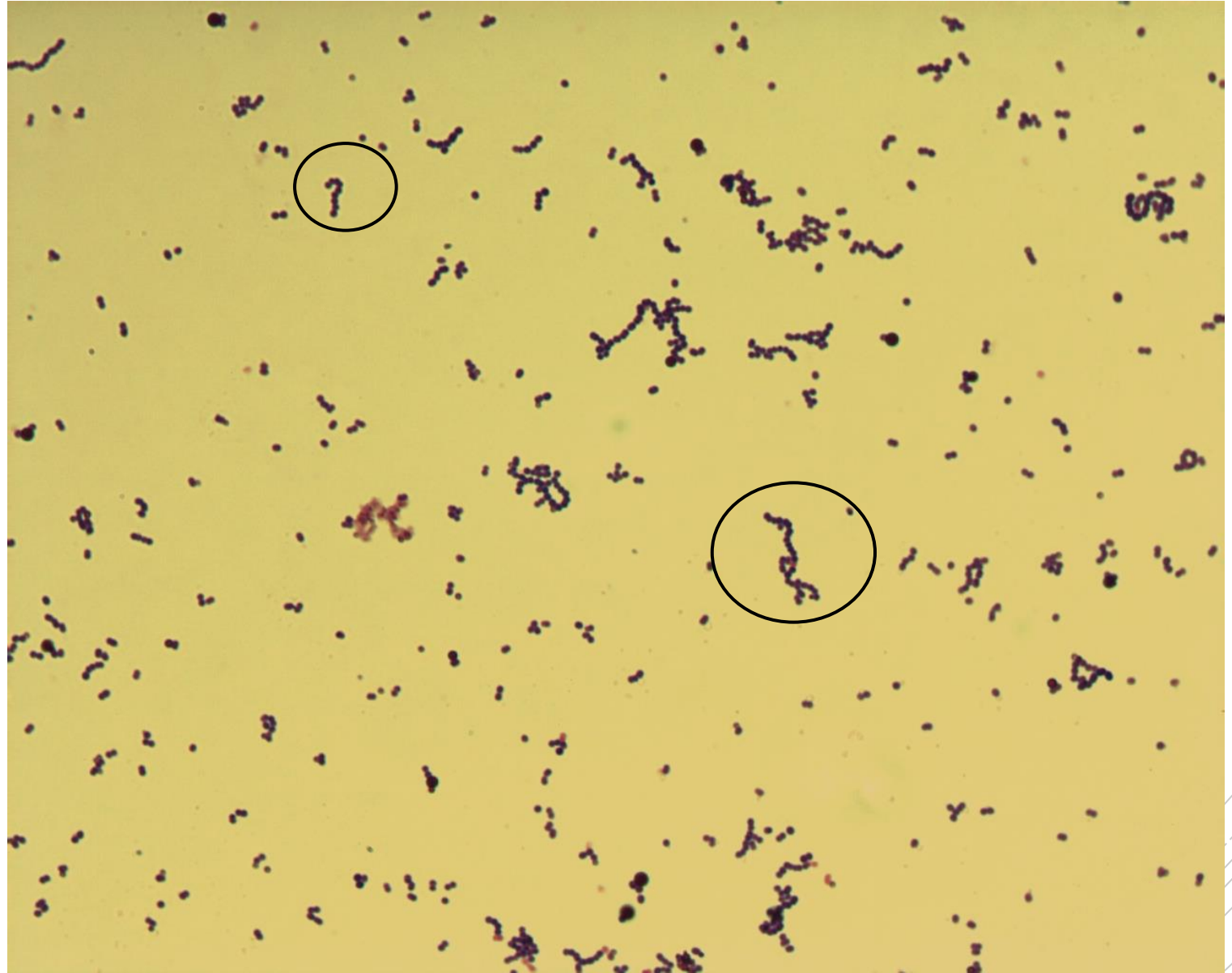
# *Streptococcus pyogenes*

**Material:** tissue sample (biopsy - striated muscle)

**Patient:** man, 40 years old

**Dg:** necrotizing fasciitis

**Microscopy:** gram positive single cocci or chains (see circular section)



Authors: Markéta Šolarová, Hana Nekvasilová



CHARLES UNIVERSITY  
Second Faculty of Medicine

Slide No. 20

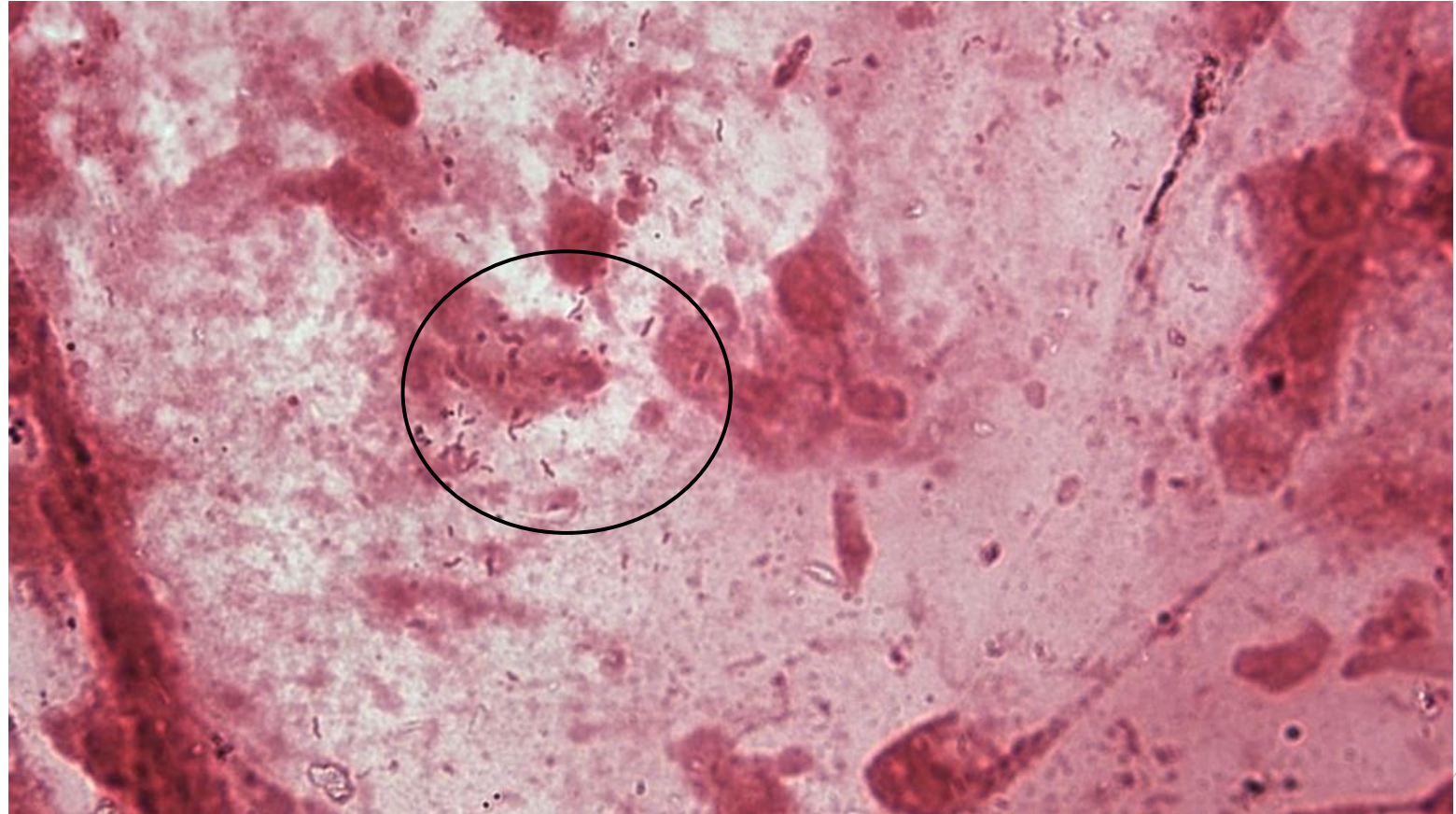# *Helicobacter pylori*

**Material:** gastric mucosa biopsy

**Patient:** woman, 36 years old

**Dg:** chronic gastritis

**Microscopy:** gram negative rods, some in the shape of a flying bird (see circular section)(further gastric mucosal cells and cellular debris)



Author: Markéta Šolarová



CHARLES UNIVERSITY  
Second Faculty of Medicine

Slide No. 21

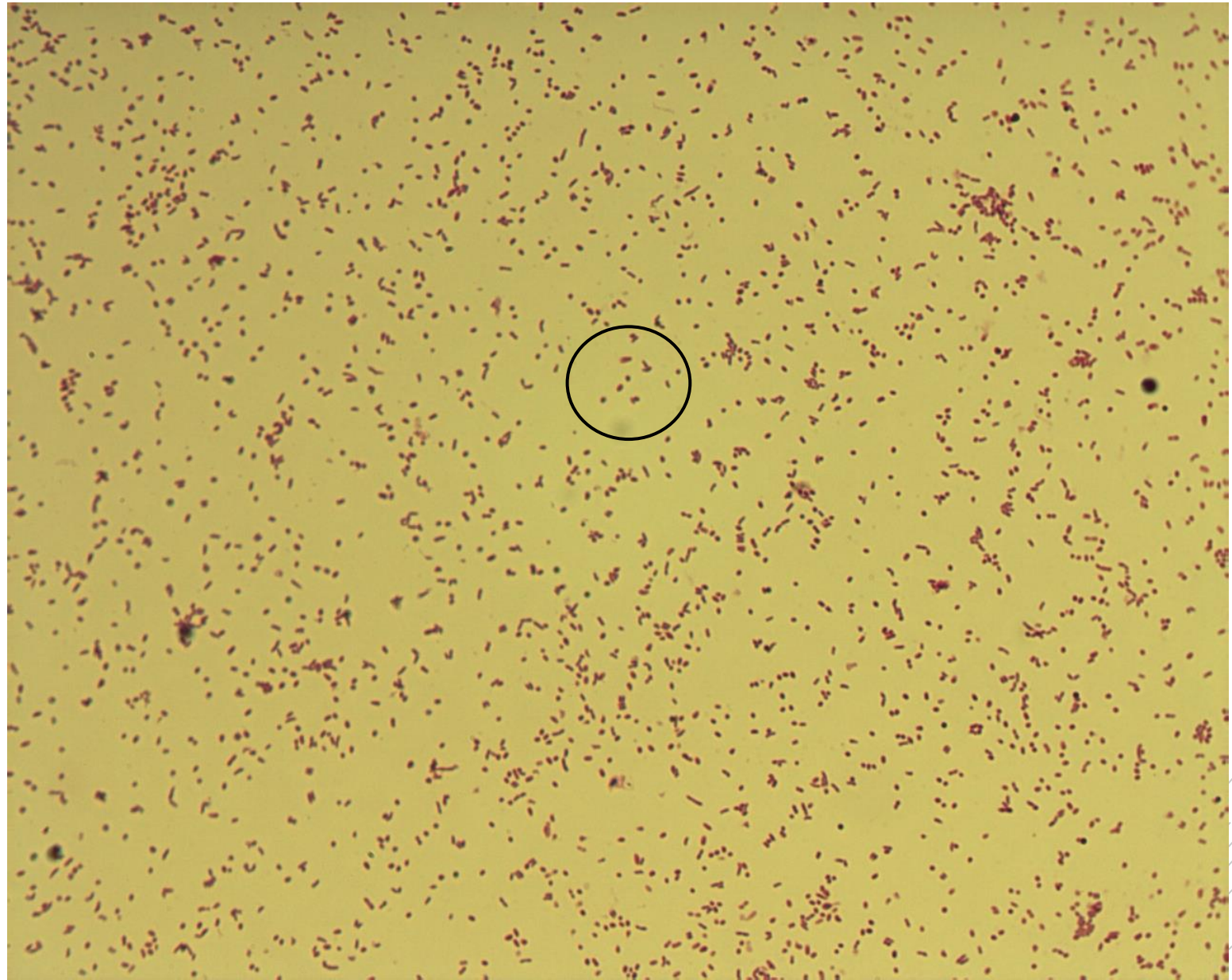
*Haemophilus influenzae typ b*

**Material:** liquor

**Patient:** male, 8 years old

**Dg:** purulent meningitis

**Microscopy:** gram negative  
coccobacilli (see circular section)



Authors: Markéta Šolarová, Hana Nekvasilová



CHARLES UNIVERSITY  
Second Faculty of Medicine

Slide No. 27

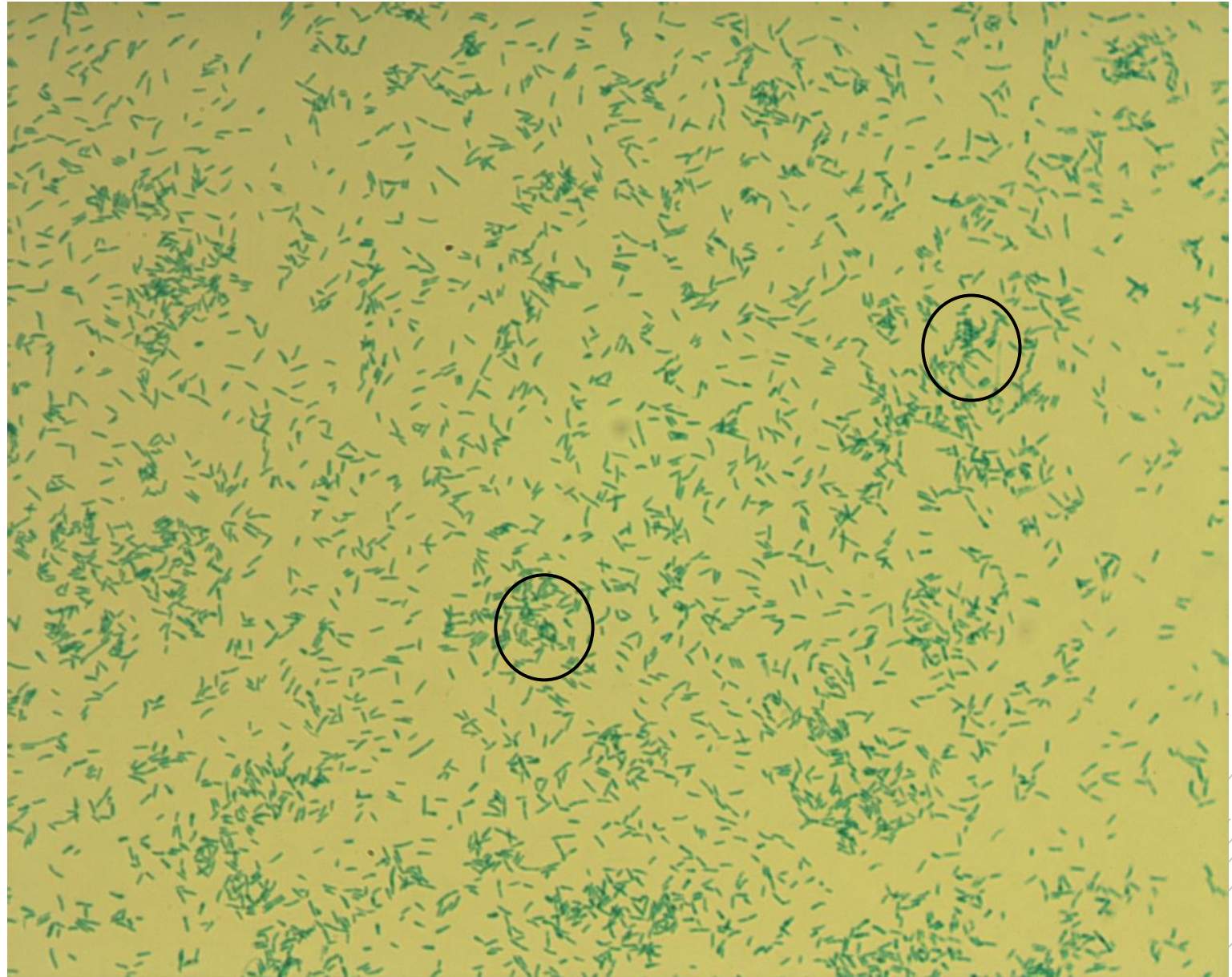
# *Corynebacterium diphtheriae*

**Material:** pharyngeal swab

**Patient:** man, 2 years old

**Dg:** tonsillopharyngitis

**Culture microscopy:** small club-shaped rods with metachromatic granules (see circular section), Albert staining



Authors: Markéta Šolarová, Hana Nekvasilová



CHARLES UNIVERSITY  
Second Faculty of Medicine

Slide No. 28

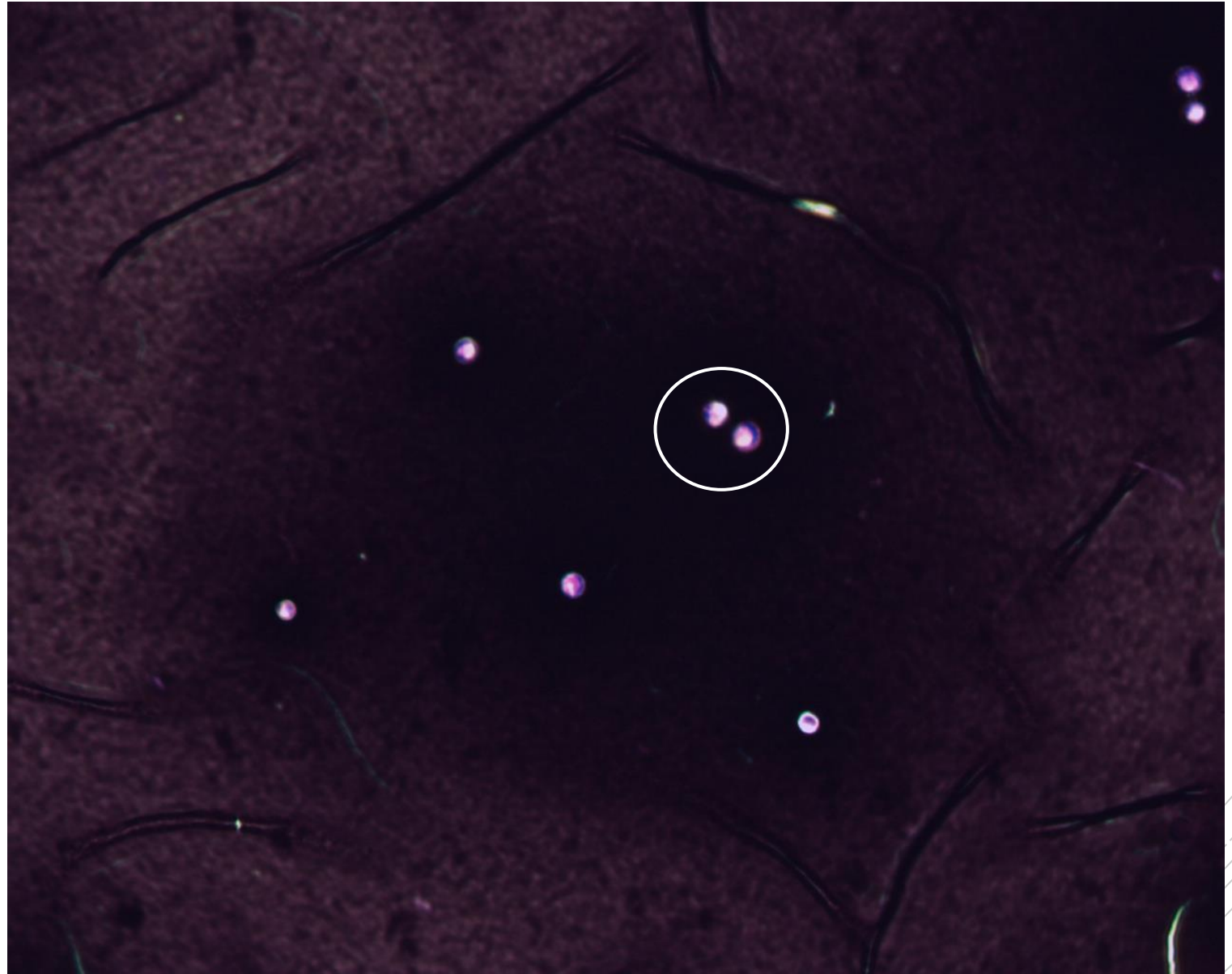
*Cryptococcus  
neoformans*

**Material:** sputum

**Patient:** man, 34 years old

**Dg:** pneumonia

**Microscopy:** demonstration of sheaths  
around yeast, Burri staining (see  
circular section)



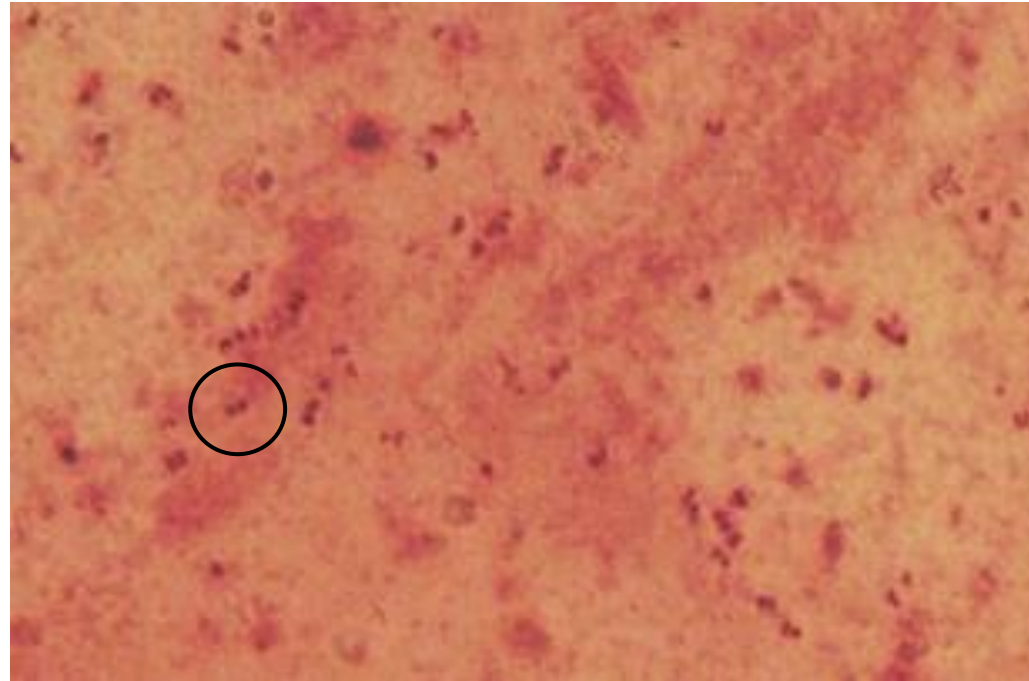
Authors: Markéta Šolarová, Hana Nekvasilová



CHARLES UNIVERSITY  
Second Faculty of Medicine

Slide No. 32

*Neisseria  
gonorrhoeae*



**Material:** cervix smear

**Patient:** woman, 25 years old

**Dg:** cervicitis

**Culture microscopy:** gram negative  
diplococci (see circular section)

Author: MUDr. Alena Píšová





CHARLES UNIVERSITY  
Second Faculty of Medicine

Slide No. 33

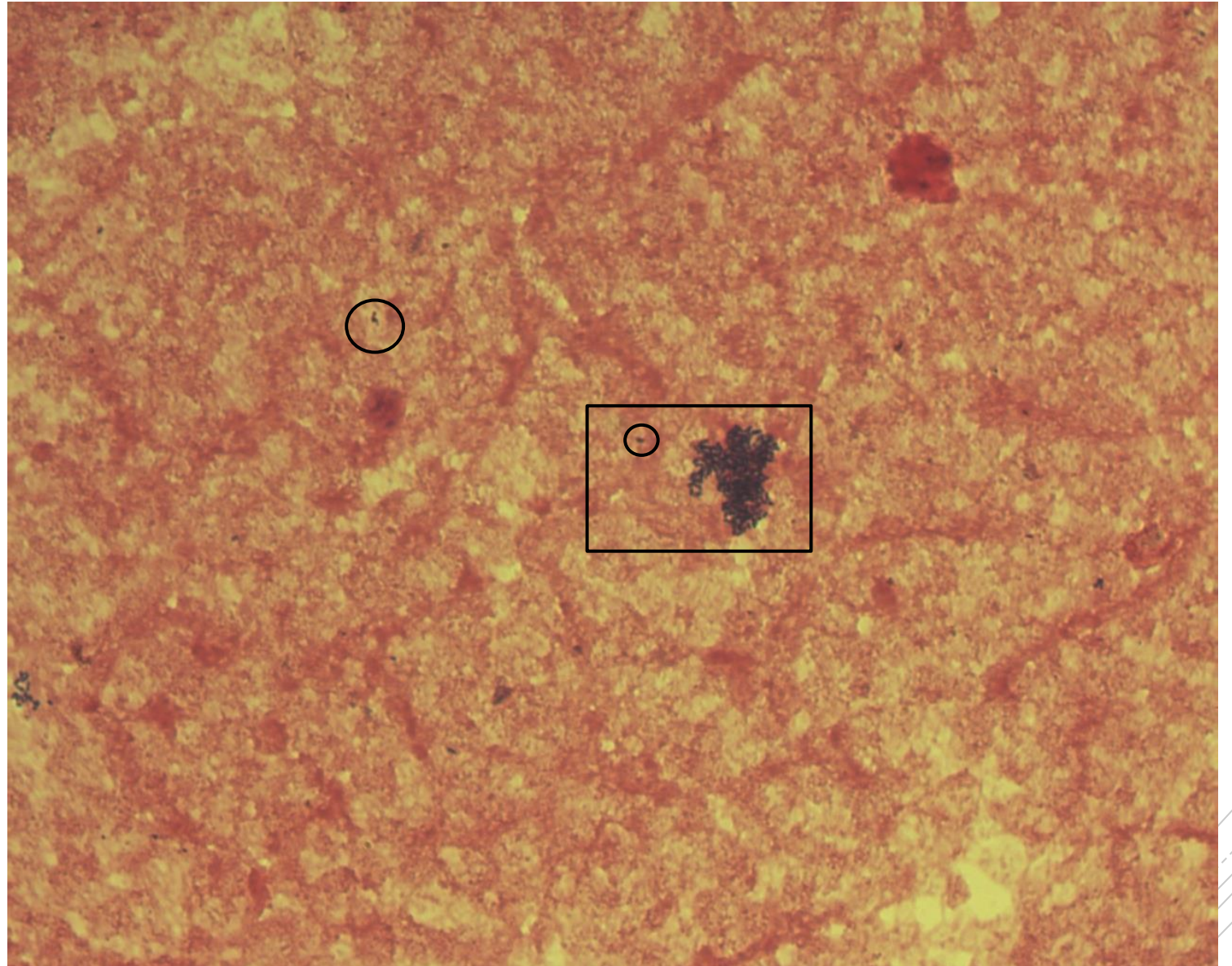
# *Listeria monocytogenes*

**Material:** hemoculture

**Patient:** man, 71 years old

**Dg:** sepsis of immunocompetent patient

**Microscopy:** gram positive rods singly or in clusters (see circular and rectangular section)(further cellular debris)



Authors: MUDr. Petra Kabelíková, Sandra Opálková



CHARLES UNIVERSITY  
Second Faculty of Medicine

Slide No. 35

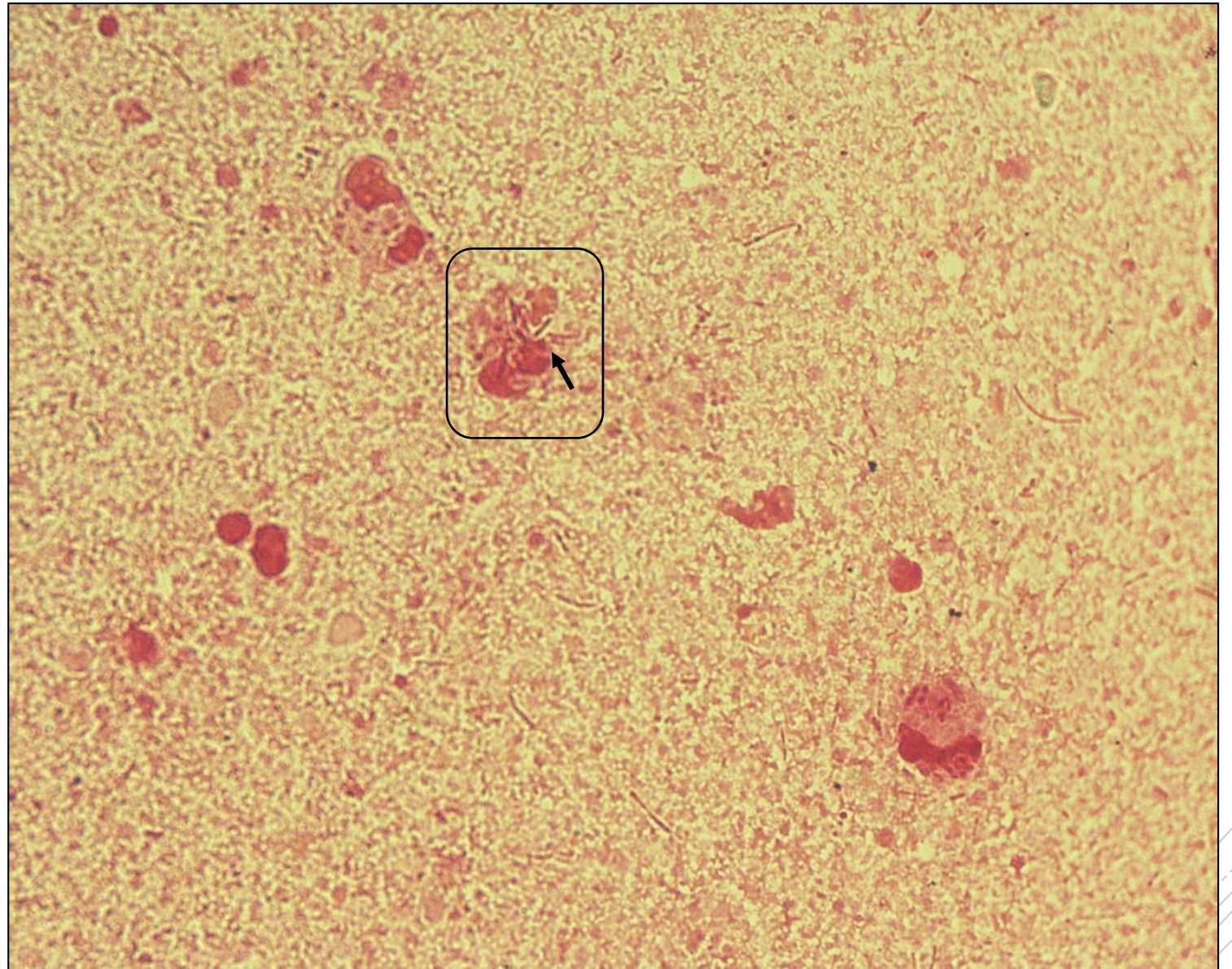
# *Burkholderia cepacia*

**Material:** sputum

**Patient:** maN, 16 years old

**Dg:** cystic fibrosis (exacerbation)

**Microscopy:** gram negative rods of various lengths (see rectangular section) (further granulocytes and cellular debris)



Author: doc. MVDr. Oto Melter, PhD.



CHARLES UNIVERSITY  
Second Faculty of Medicine

Slide No. 36

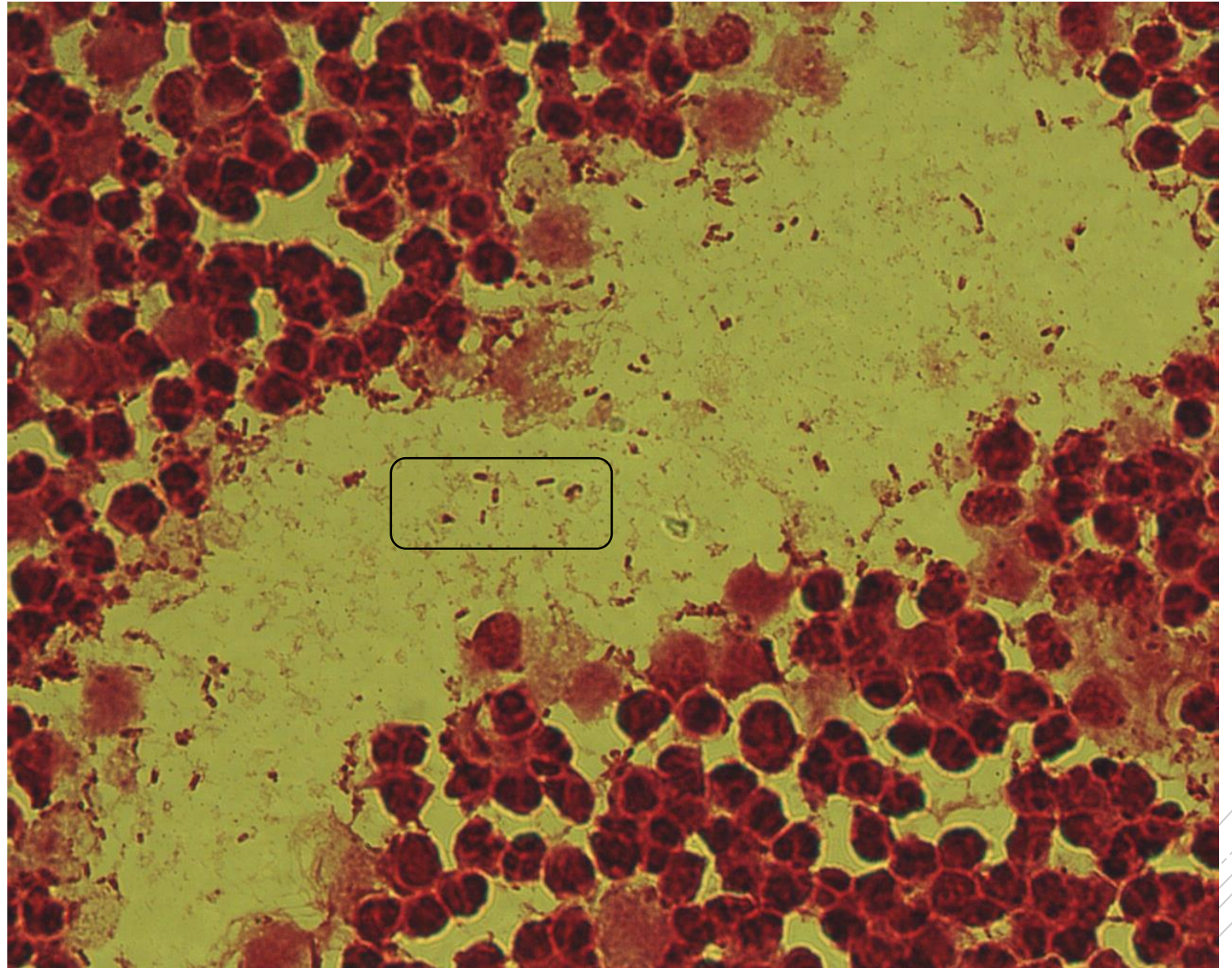
# *Escherichia coli*

**Material:** tissue biopsy from the renal pelvis

**Patient:** woman, 54 years old

**Dg:** pyelolithiasis

**Microscopy:** gram negative rods (see rectangular section) (further granulocytes and cellular debris)



Author: MUDr. Alena Pišová



CHARLES UNIVERSITY  
Second Faculty of Medicine

Slide No. 42

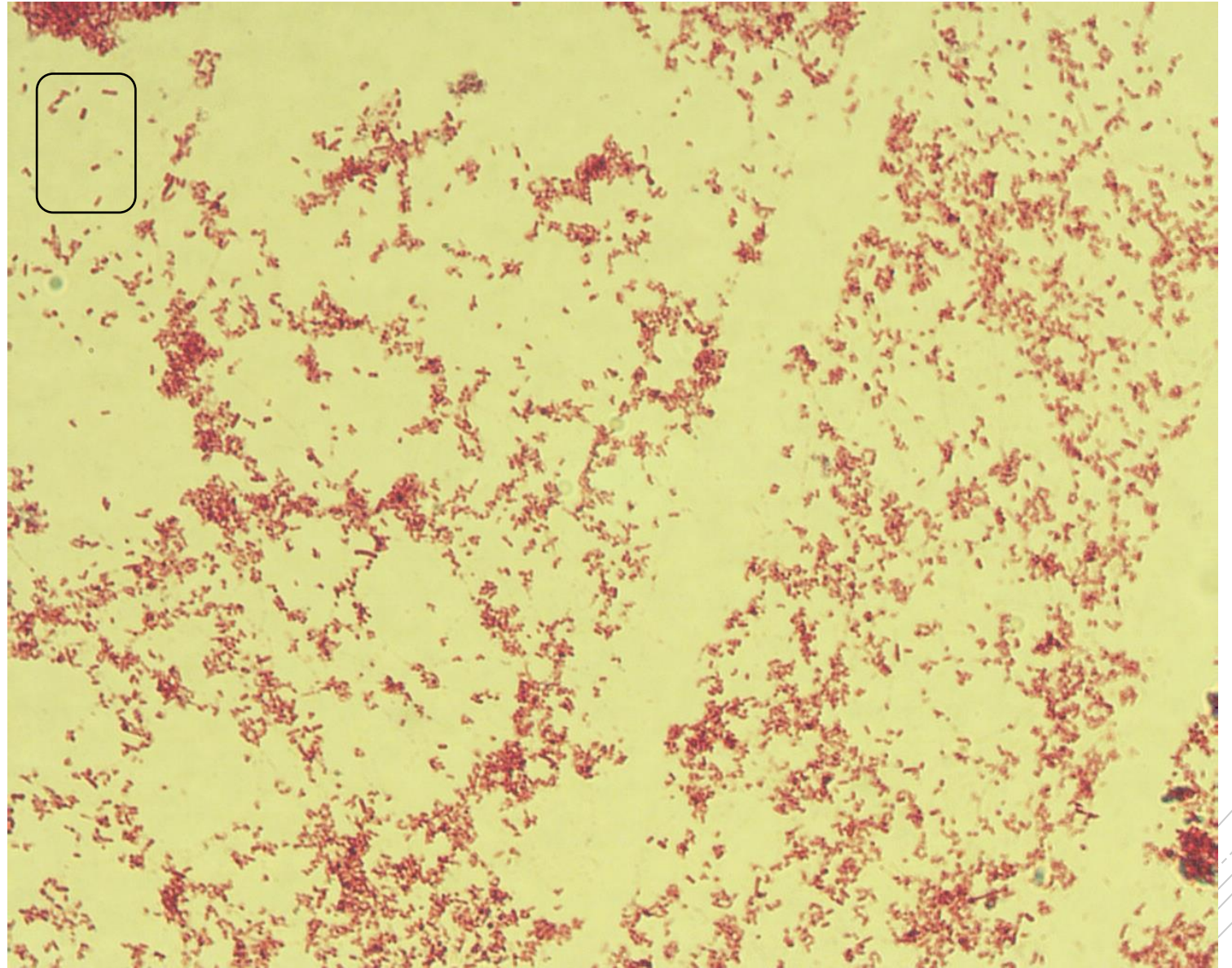
*Salmonella Typhi*

**Material:** stool

**Patient:** man, 32 years old

**Dg:** typhoid fever

**Culture microscopy:** gram negative rods (see circular section)



Author: MUDr. Lenka Tritová



CHARLES UNIVERSITY  
Second Faculty of Medicine

Slide No. 47

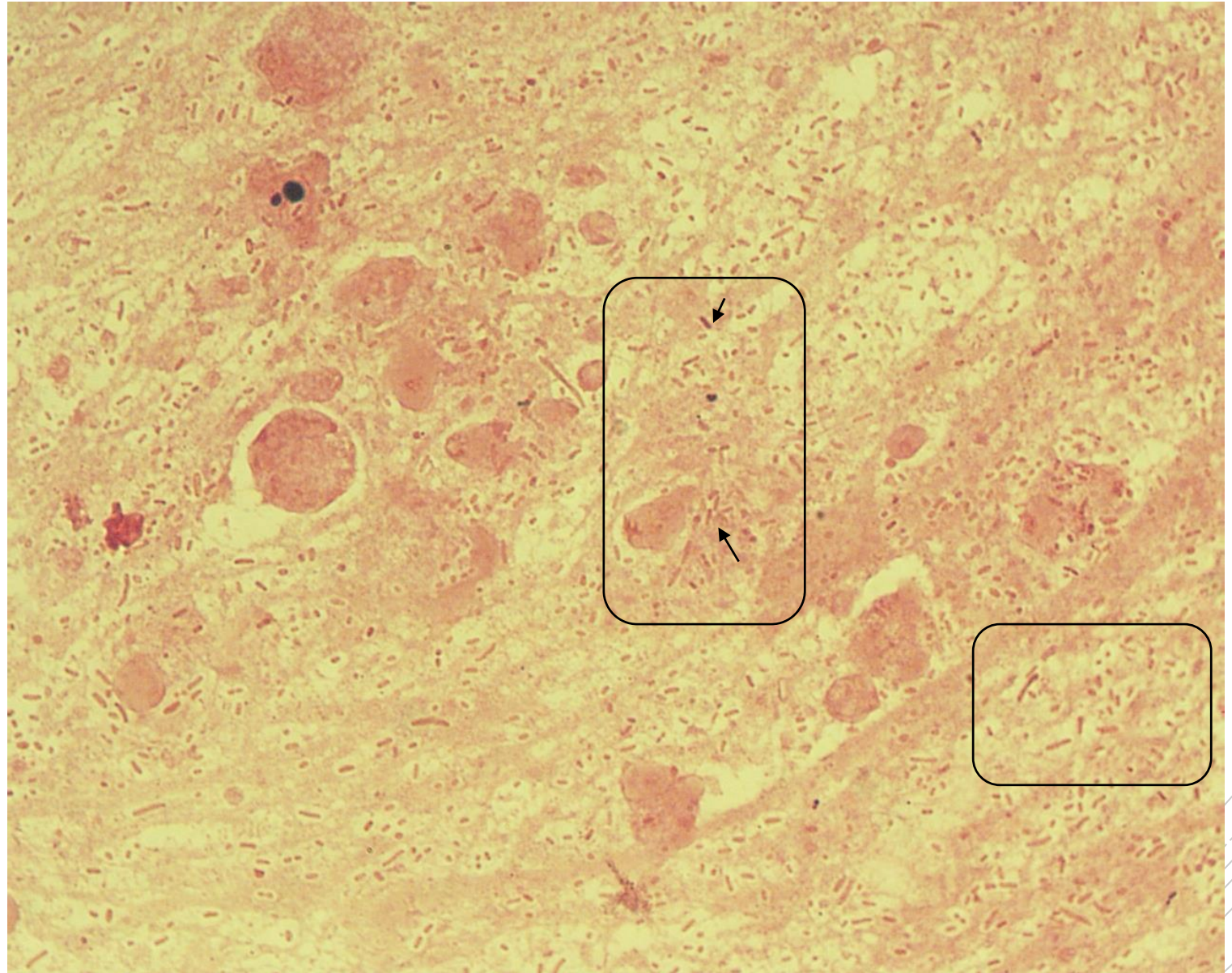
# *Klebsiella pneumoniae*

**Material:** sputum

**Patient:** female 85 years old

**Dg:** pneumonia

**Microscopy:** gram negative rods in mass (rectangular section)(further granulocytes, mucus and cellular debris)



Author: MUDr. Vanda Chrenková



CHARLES UNIVERSITY  
Second Faculty of Medicine

Slide No. 49

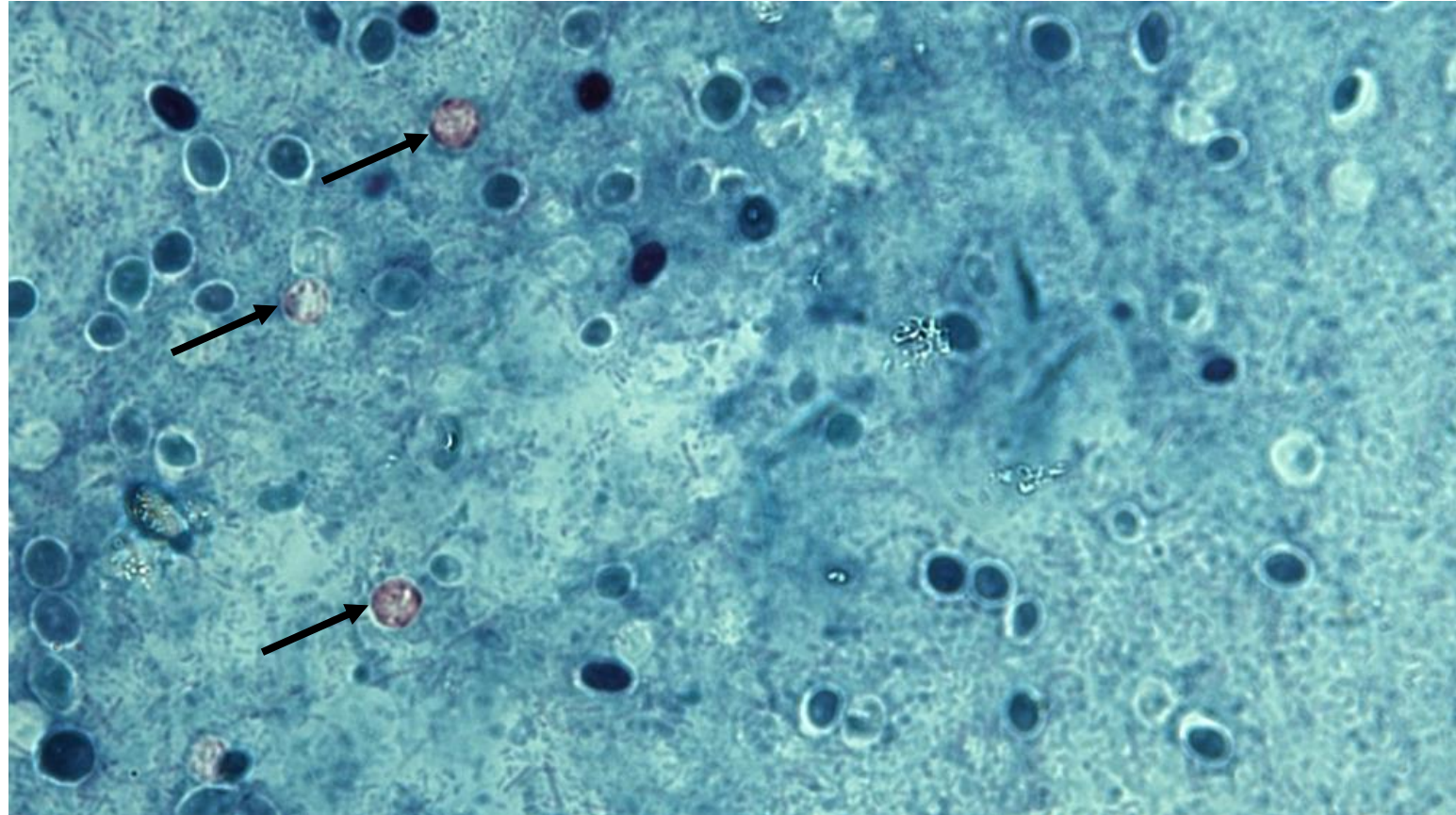
# *Cryptosporidium parvum*

**Material:** stool

**Patient:** HIV positive man, 36 years old,

**Dg:** watery diarrhea

**Microscopy:** cryptosporidium oocysts  
(pink coloured, see arrows), Ziehl-  
Neelsen staining



Author: MUDr. Kamila Dundrová



CHARLES UNIVERSITY  
Second Faculty of Medicine

Slide No. 52

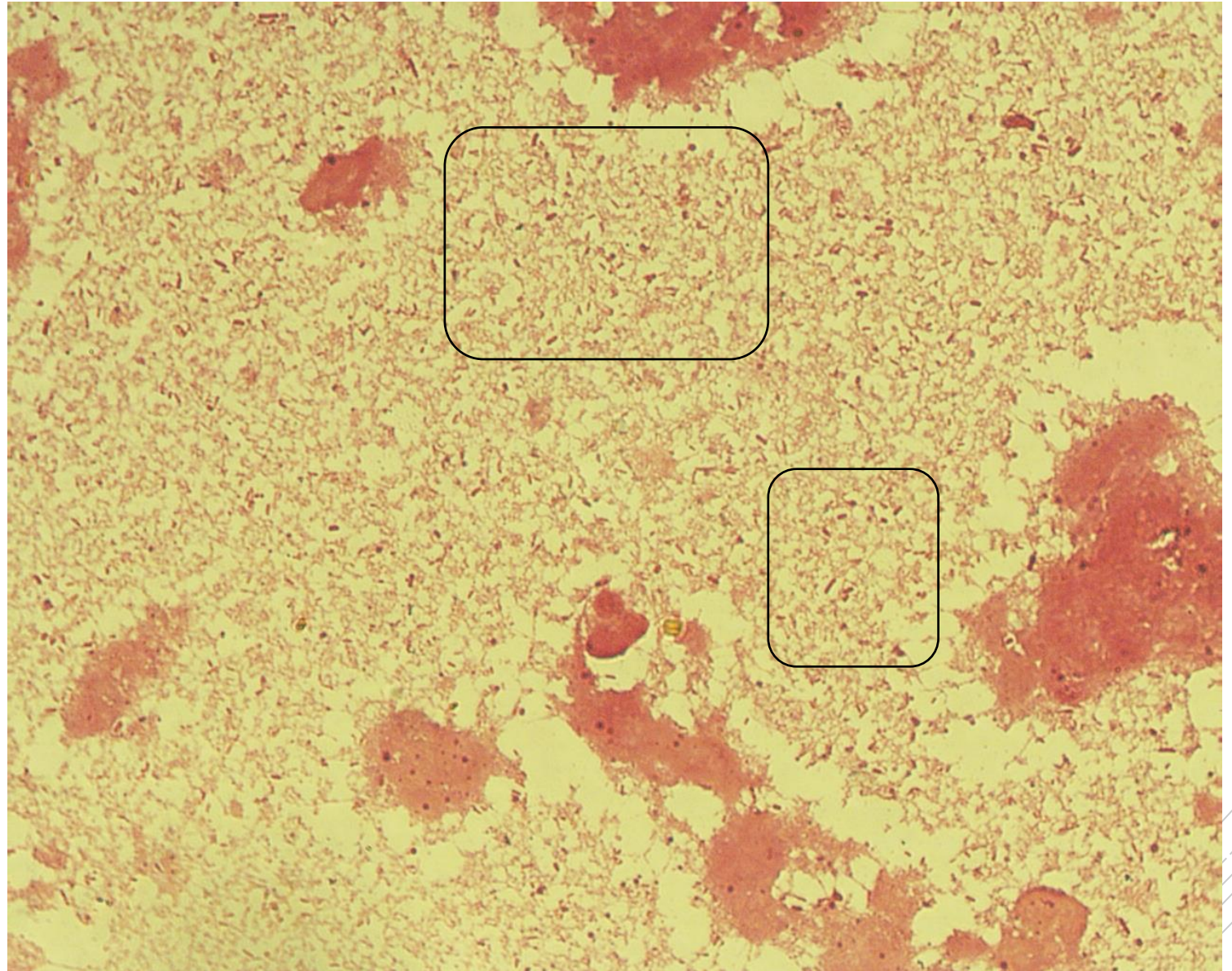
*Bacteroides fragilis, Klebsiella oxytoca, Escherichia coli*

**Material:** pus

**Patient:** woman, 44 years old

**Dg:** liver abscess

**Microscopy:** gram negative rods of various shapes (see rectangular section)(further granulocytes, cellular debris)



Author: MUDr. Alena Píšová



CHARLES UNIVERSITY  
Second Faculty of Medicine

Slide No. 54

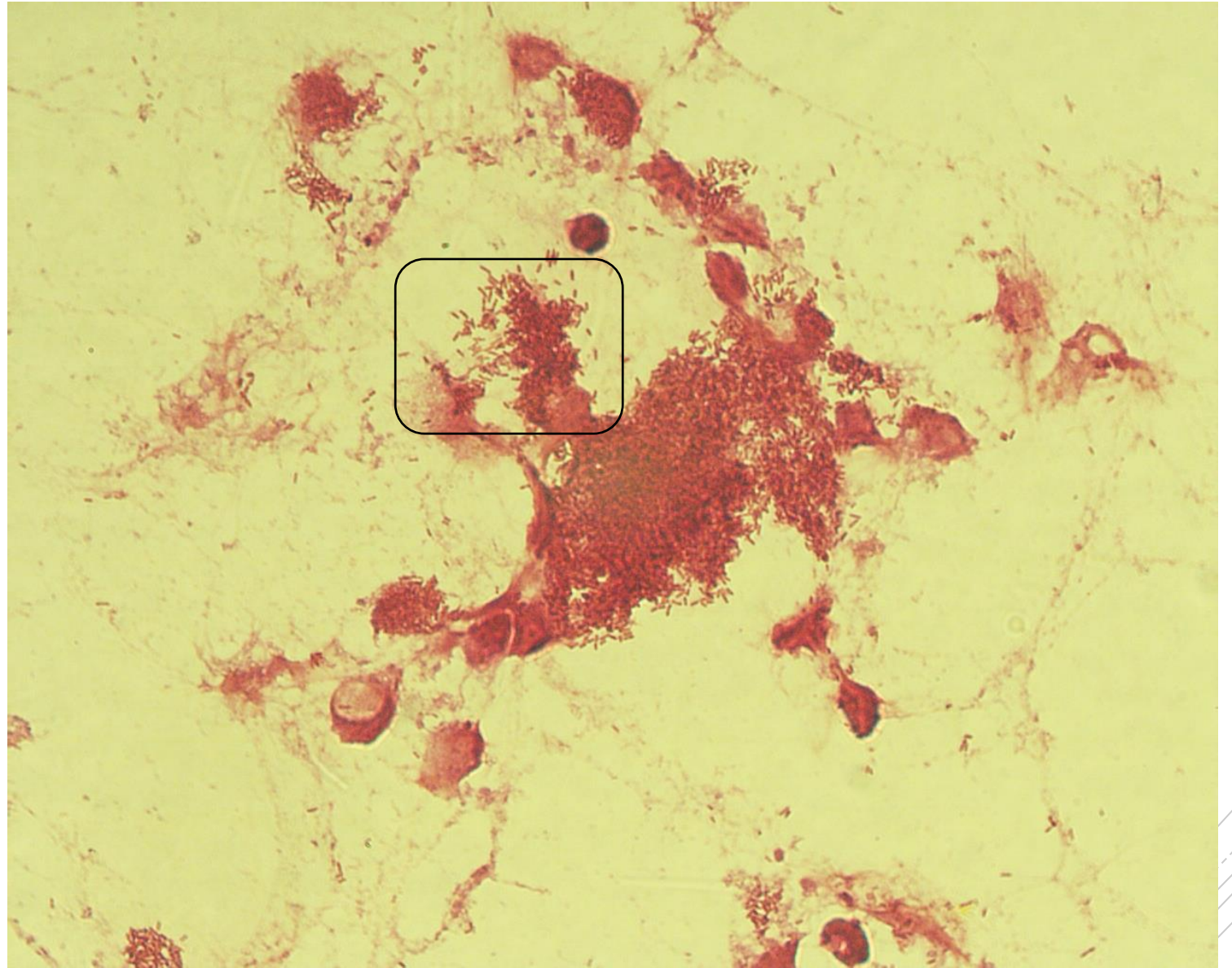
*Stenotrophomonas  
maltophilia*

**Material:** aspirate

**Patient:** man, 30 years old

**Dg:** acute pancreatitis

**Microscopy:** gram negative rods (see rectangular section) (further granulocytes and cellular debris)



Author: MUDr. Alena Píšová





CHARLES UNIVERSITY  
Second Faculty of Medicine

Slide No. 57

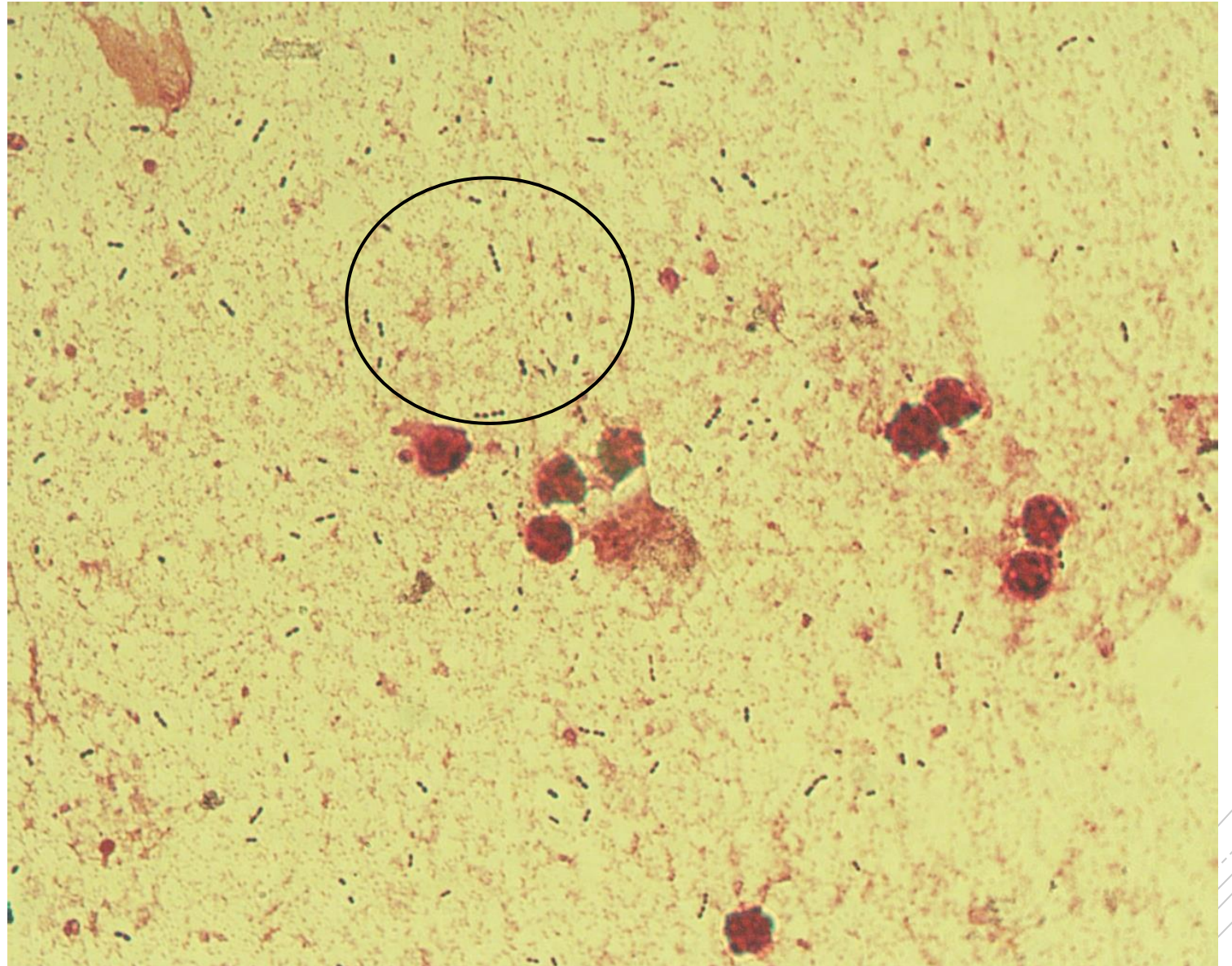
# *Streptococcus pneumoniae*

**Material:** sputum

**Patient:** woman, 16 years old

**Dg:** purulent bronchitis

**Microscopy:** gram positive diplococci  
(see circular section) (further  
granulocytes and cellular debris)



Author: MUDr. Lenka Tritová