

ATLAS OF CLINICAL MICROBIOLOGY

Glass slides microscopy

Author collective:

O. Melter, T. Kopecká, M. Šolarová, H. Nekvasilová, H. Svojtková, A. Píšová, P. Kabelíková, D. Lžičařová,
S. Opálková, K. Dundrová, J. Hurych, M. Finsterle

© Department of Medical Microbiology, Second Faculty of Medicine, Charles University, Prague (2019)



CHARLES UNIVERSITY
Second Faculty of Medicine



CHARLES UNIVERSITY
Second Faculty of Medicine

Slide No. 1

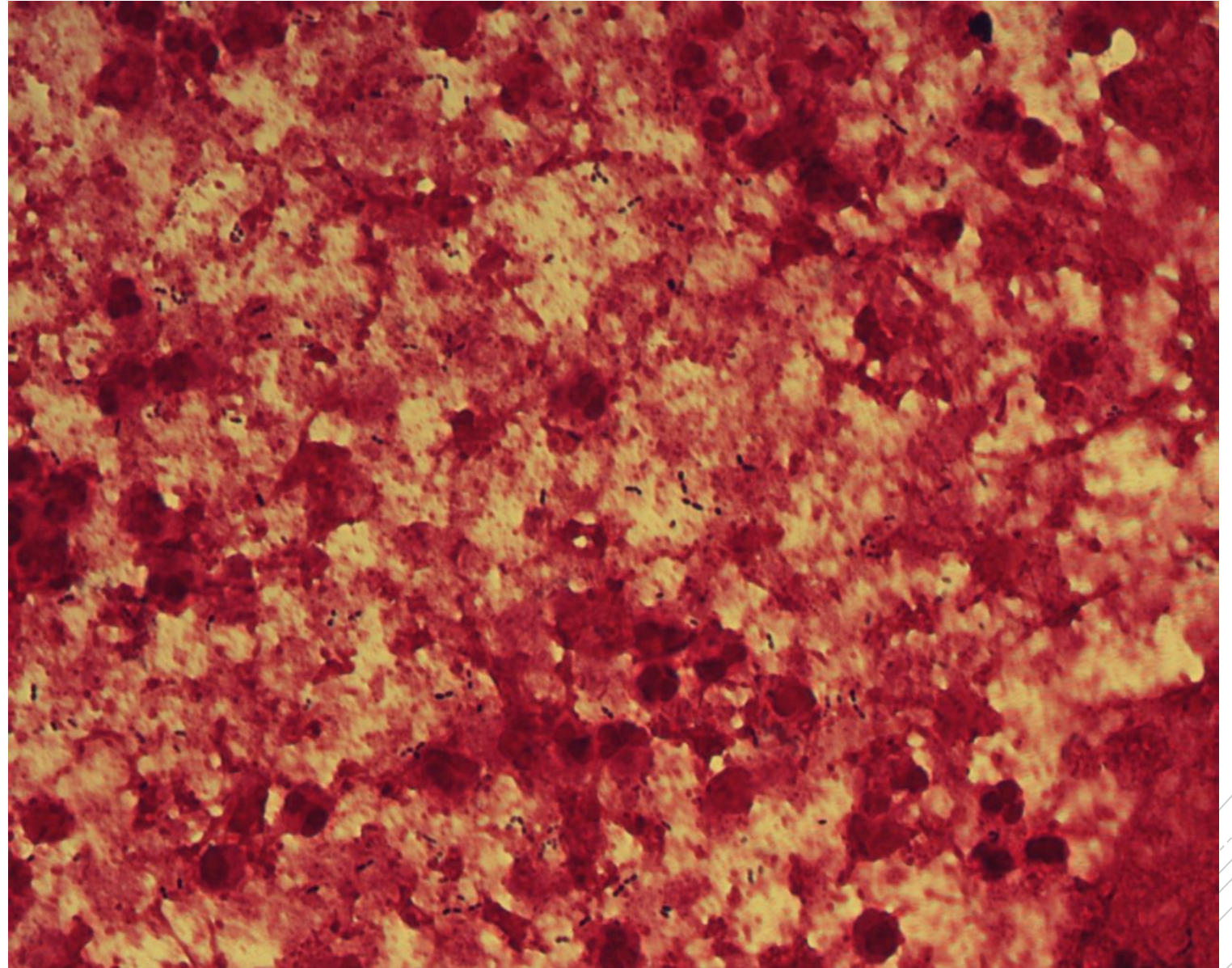
Streptococcus pneumoniae

Specimen: sputum

Patient: male, 42 years old

Dg.: exacerbation of bronchiectasis

Microscopy: Gram-positive diplococci,
lancet-shaped



Author: MUDr. Alena Pířová



CHARLES UNIVERSITY
Second Faculty of Medicine

Slide No. 1


Streptococcus pneumoniae

Specimen: sputum

Patient: male, 42 years old

Dg.: exacerbation of bronchiectasis

Microscopy: Gram-positive diplococci,
lancet-shaped



Author: MUDr. Alena Pířová



CHARLES UNIVERSITY
Second Faculty of Medicine

Slide No. 2

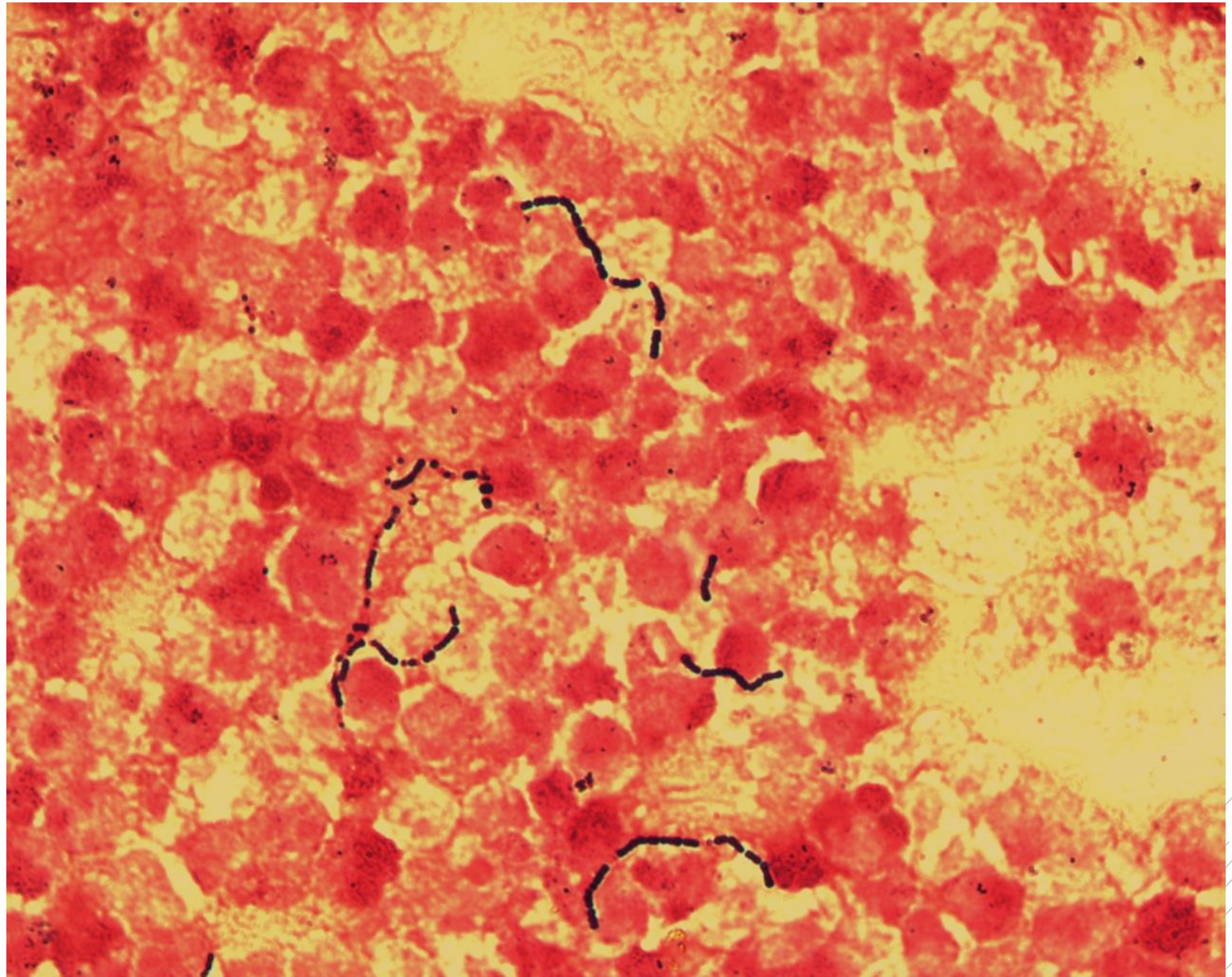
Streptococcus agalactiae

Specimen: Pus

Patient: male, 77 years old

Dg.: periappendicular abscess

Microscopy: Gram-positive cocci
in chains



Author: MUDr. Alena Pířová



CHARLES UNIVERSITY
Second Faculty of Medicine

Slide No. 2


Streptococcus agalactiae

Specimen: Pus

Patient: male, 77 years old

Dg.: periappendicular abscess

Microscopy: Gram-positive cocci
in chains



Author: MUDr. Alena Pířová



CHARLES UNIVERSITY
Second Faculty of Medicine

Slide No. 3

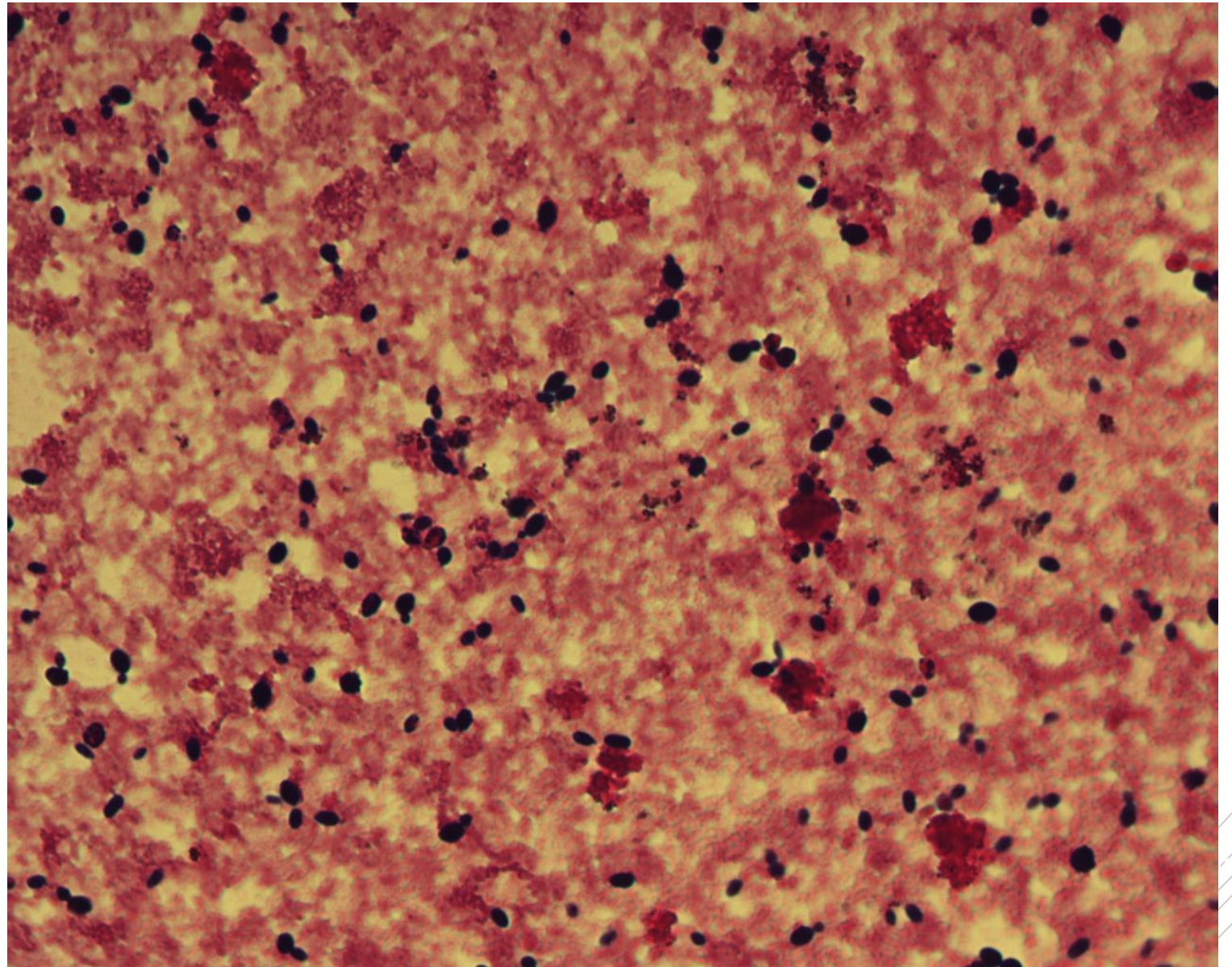
Candida fabianii

Specimen: blood culture

Patient: male, 2 years old

Dg.: acute myeloid leukemia

Microscopy: yeast blastoconidia



Author: MUDr. Petra Kabelíková



CHARLES UNIVERSITY
Second Faculty of Medicine

Slide No. 3

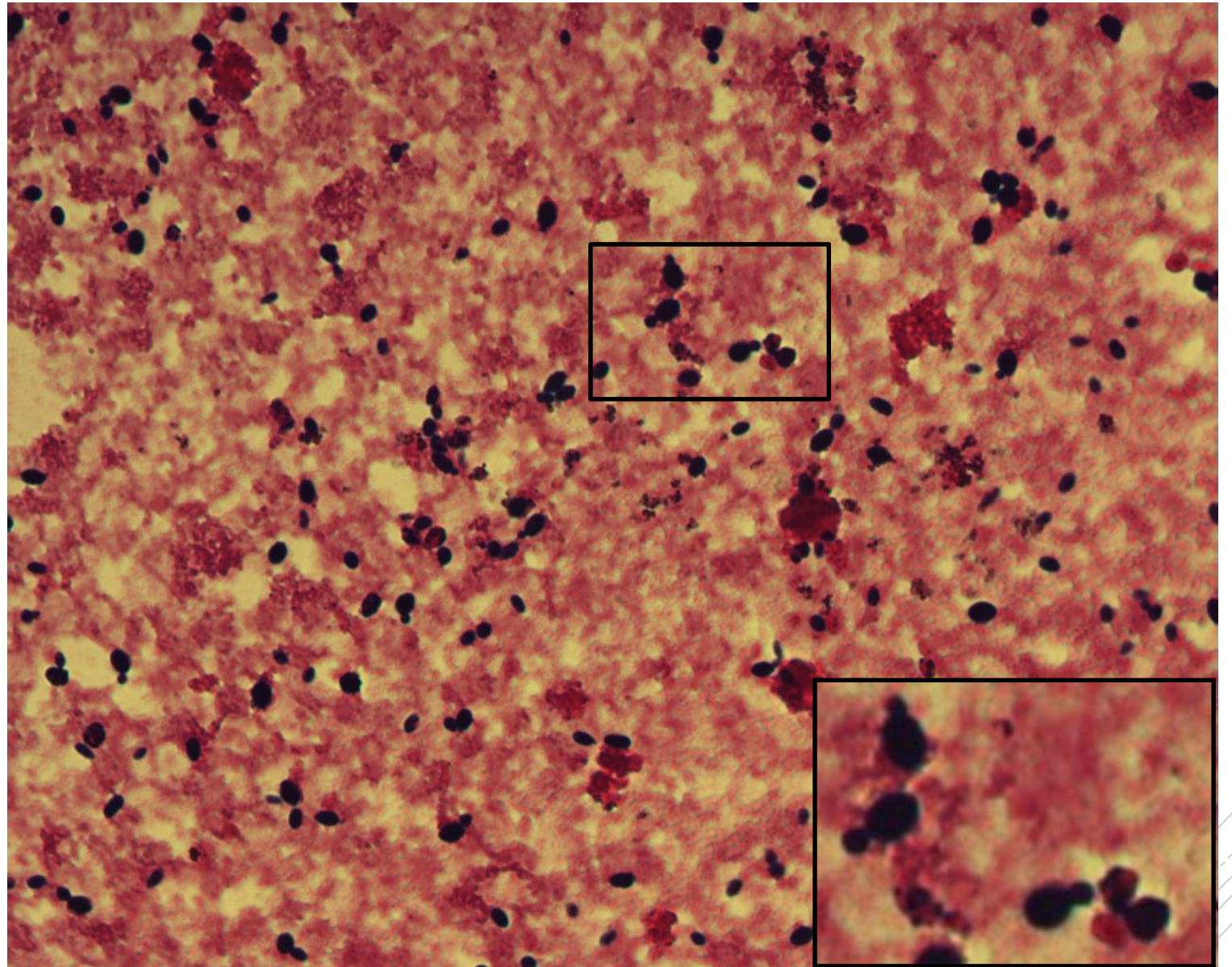
Candida fabianii

Specimen: blood culture

Patient: male, 2 years old

Dg.: acute myeloid leukemia

Microscopy: yeast blastoconidia



Author: MUDr. Petra Kabelíková



CHARLES UNIVERSITY
Second Faculty of Medicine

Slide No. 4

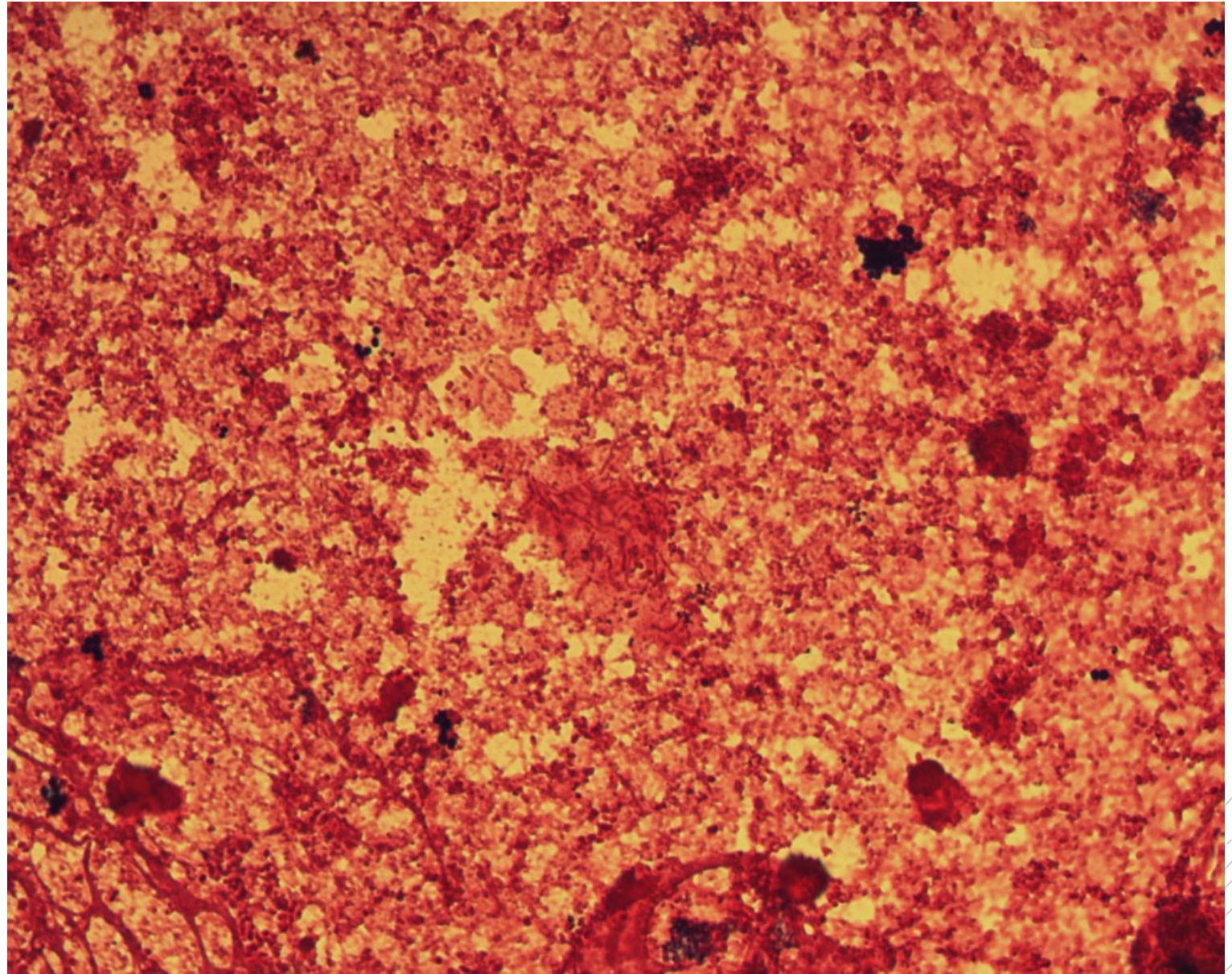
Escherichia coli, *Proteus mirabilis*

Specimen: blood culture

Patient: female, 89 years old

Dg.: urosepsis

Microscopy: Gram-negative rods



Author: MUDr. Petra Kabelíková



CHARLES UNIVERSITY
Second Faculty of Medicine

Slide No. 4

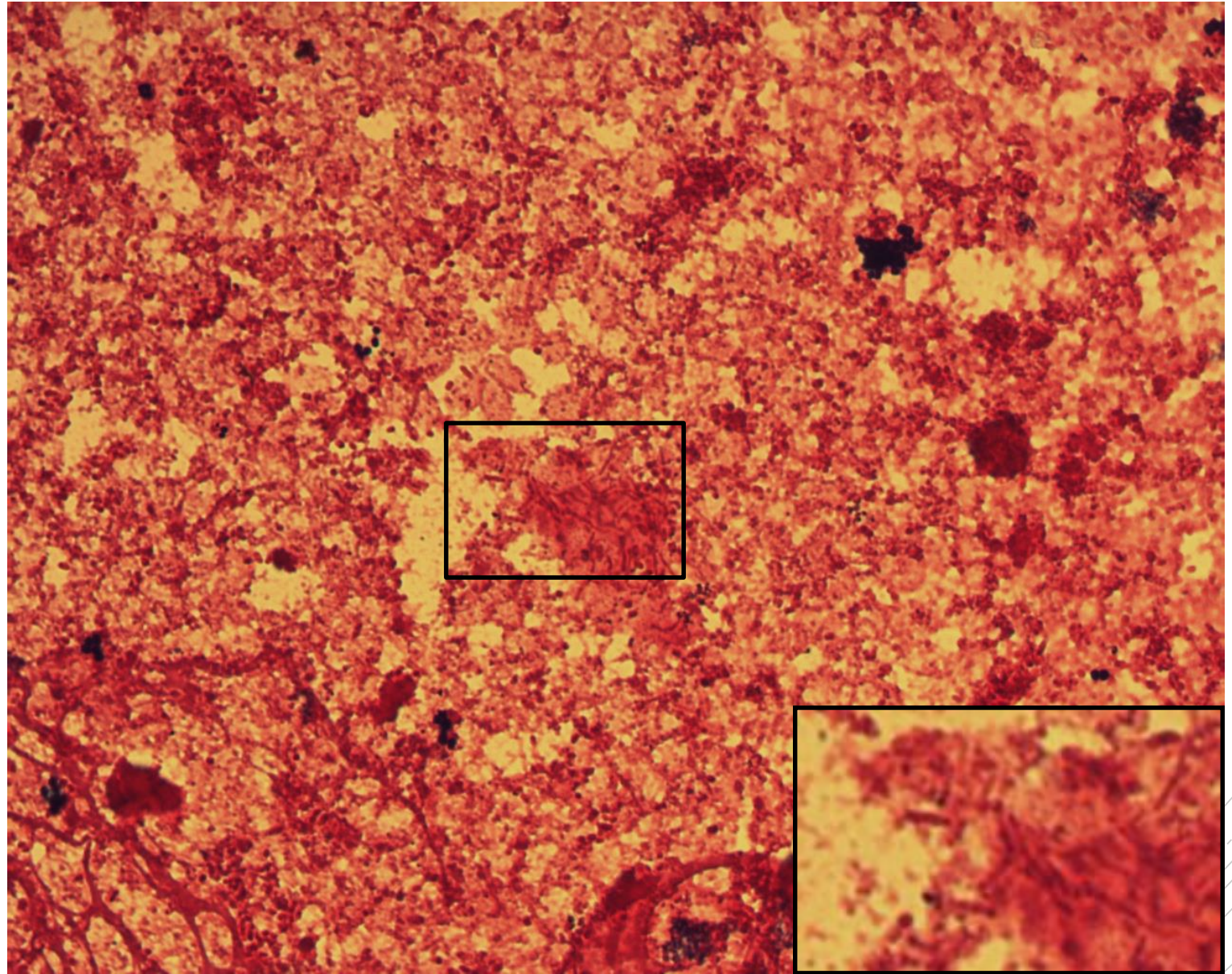
Escherichia coli, *Proteus mirabilis*

Specimen: blood culture

Patient: female, 89 years old

Dg.: urosepsis

Microscopy: Gram-negative rods



Author: MUDr. Petra Kabelíková



CHARLES UNIVERSITY
Second Faculty of Medicine

Slide No. 5

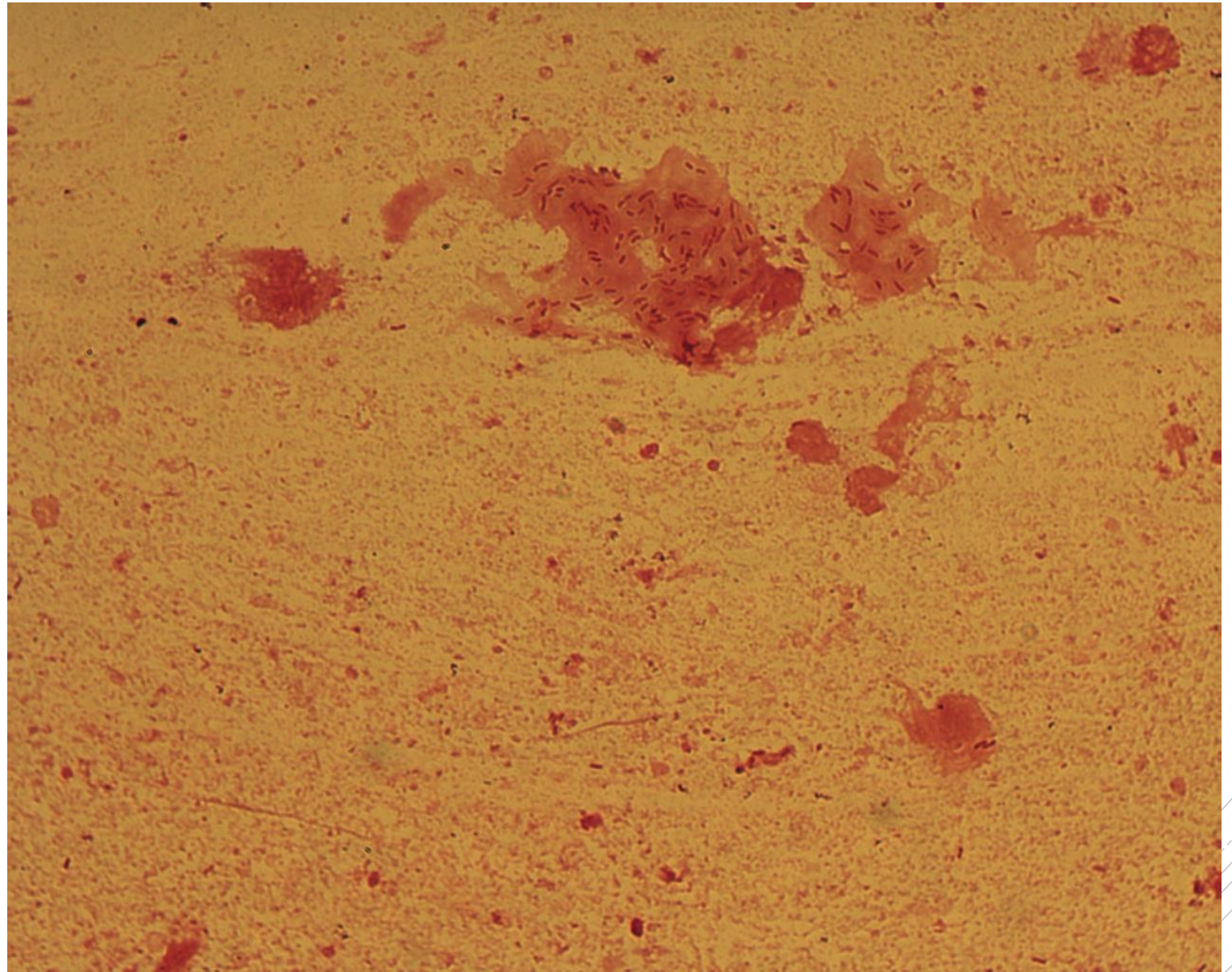
Pseudomonas aeruginosa

Specimen: sputum

Patient: male, 25 years old

Dg.: cystic fibrosis exacerbation

Microscopy: Gram-negative rods
in a biofilm fragment



Author: doc. MVDr. Oto Melter, PhD.



CHARLES UNIVERSITY
Second Faculty of Medicine

Slide No. 5

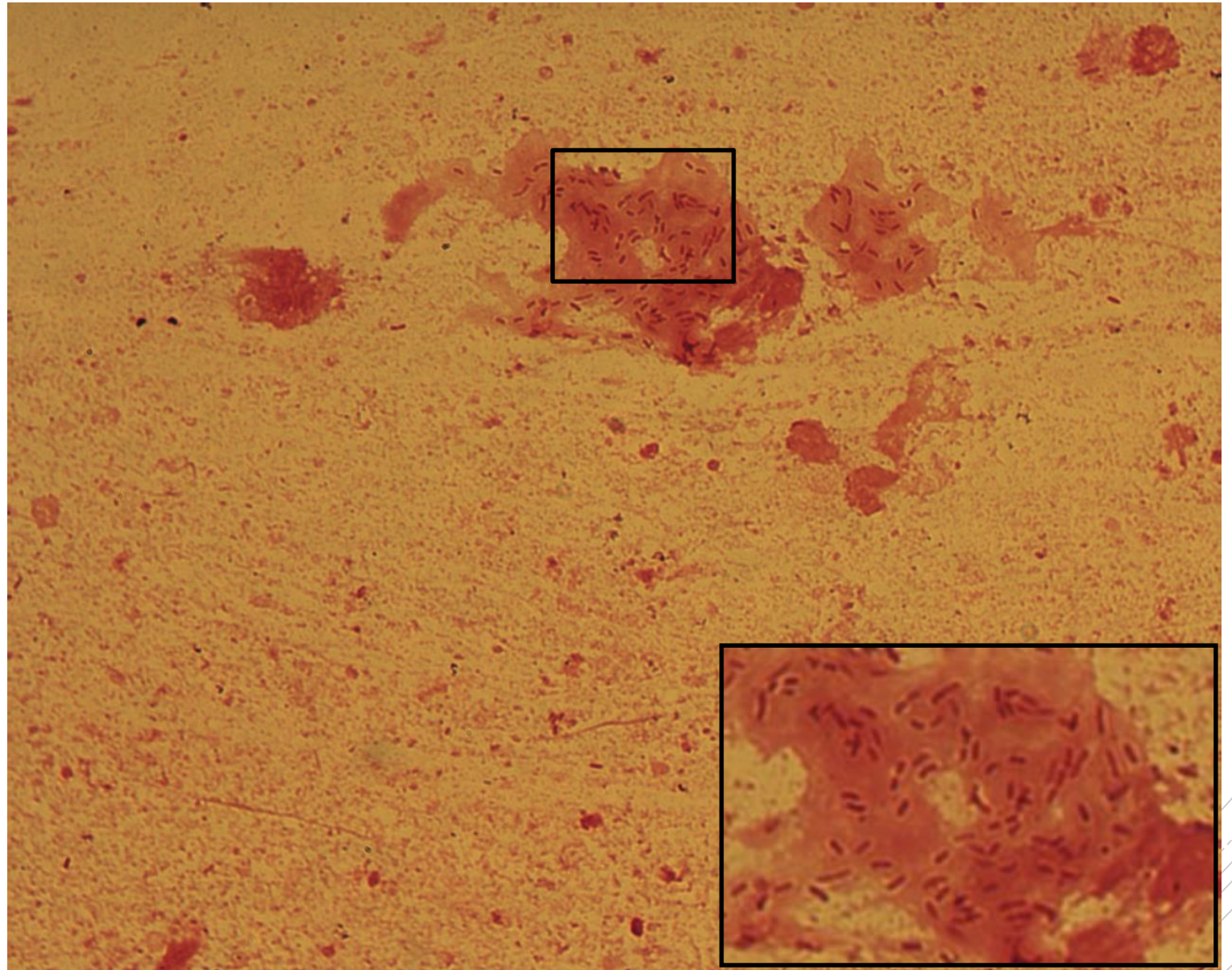
Pseudomonas aeruginosa

Specimen: sputum

Patient: male, 25 years old

Dg.: cystic fibrosis exacerbation

Microscopy: Gram-negative rods
in a biofilm fragment



Author: doc. MVDr. Oto Melter, PhD.



CHARLES UNIVERSITY
Second Faculty of Medicine

Slide No. 6

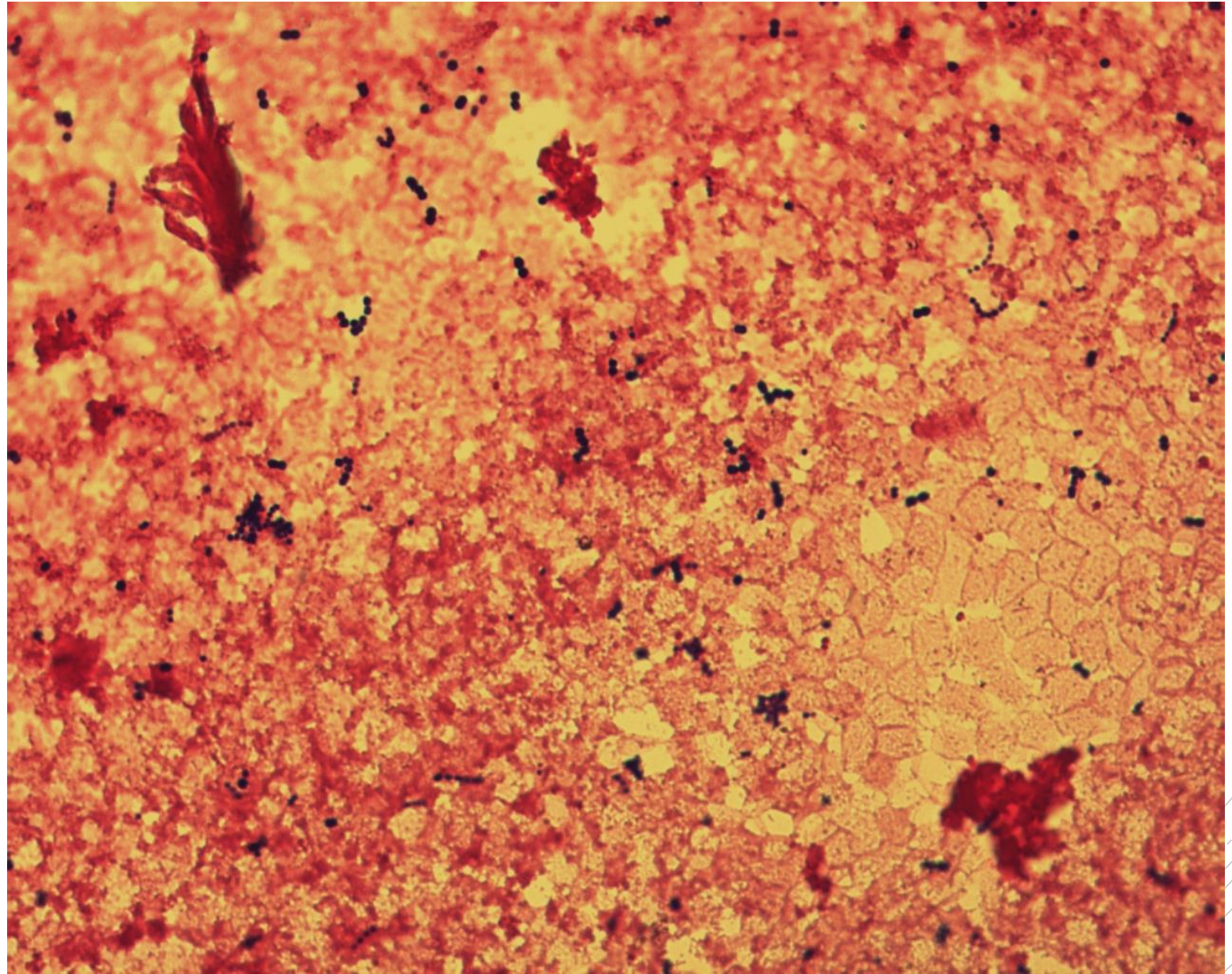
Enterococcus faecalis

Specimen: blood culture

Patient: female, 71 years old

Dg.: gallbladder sepsis

Microscopy: Gram-positive cocci
in chains



Author: MUDr. Petra Kabelíková



CHARLES UNIVERSITY
Second Faculty of Medicine

Slide No. 6

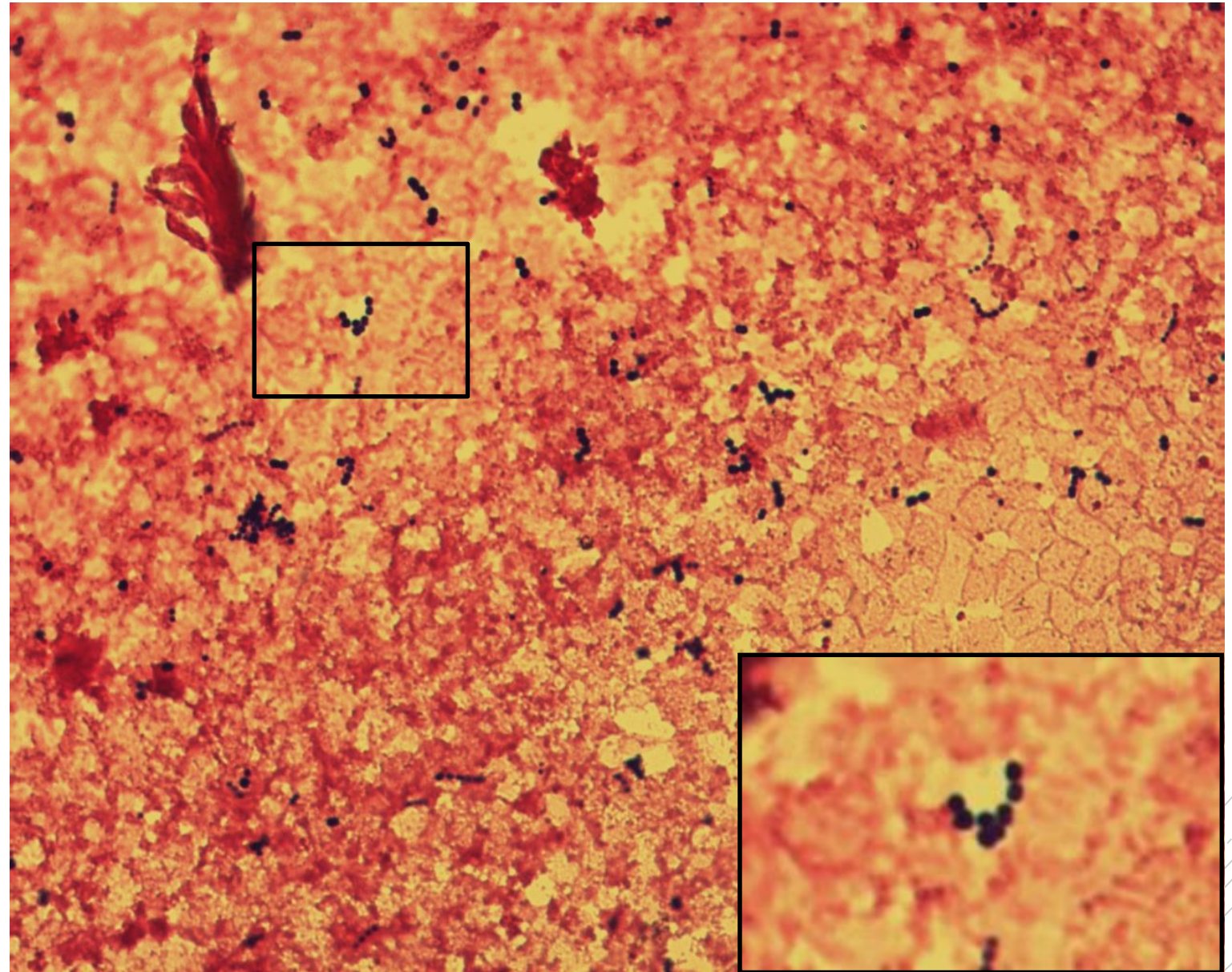
Enterococcus faecalis

Specimen: blood culture

Patient: female, 71 years old

Dg.: gallbladder sepsis

Microscopy: Gram-positive cocci
in chains



Author: MUDr. Petra Kabelíková



CHARLES UNIVERSITY
Second Faculty of Medicine

Slide No. 7

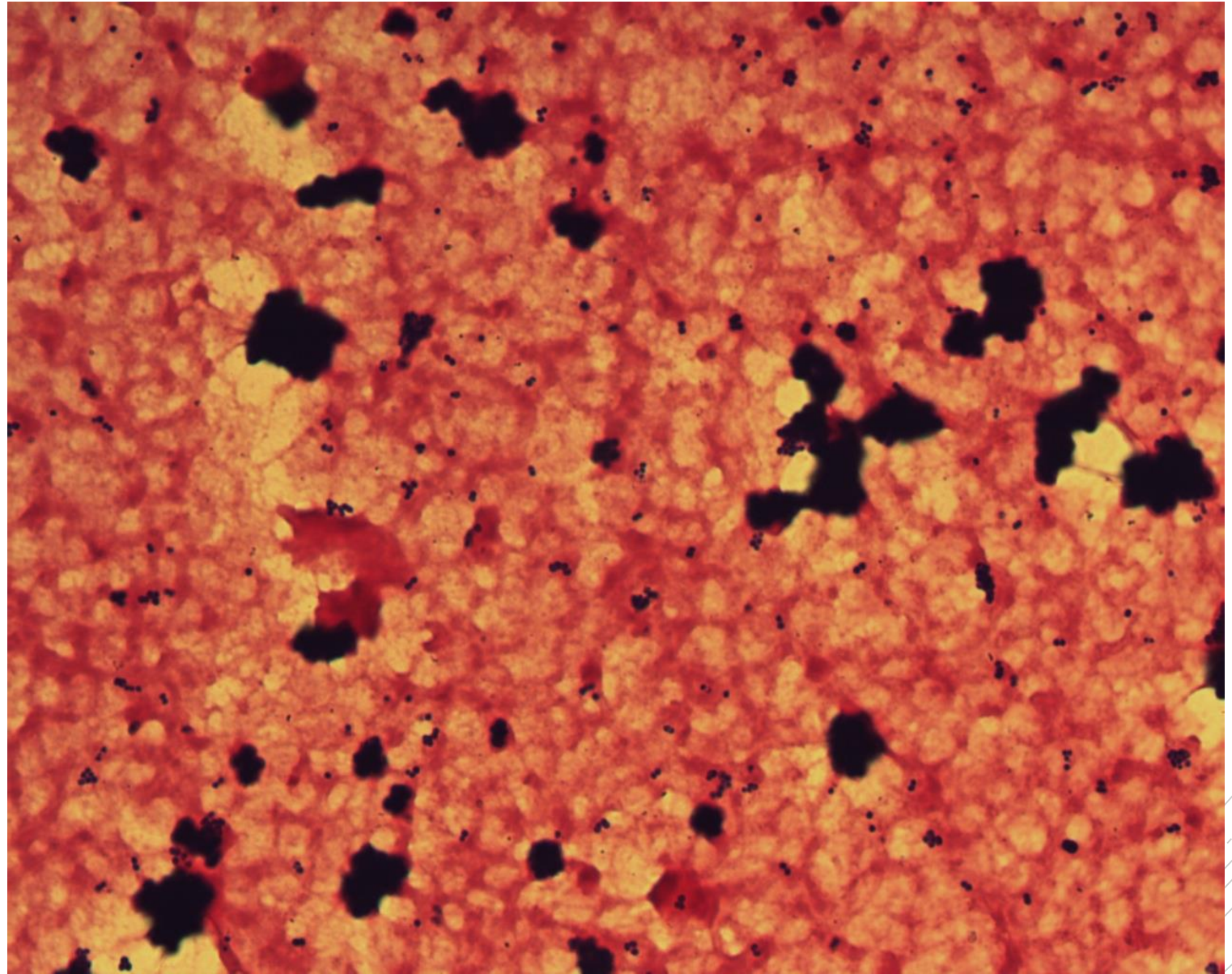
Staphylococcus aureus

Specimen: blood culture

Patient: female, 84 years old

Dg.: endocarditis

Microscopy: Gram-positive cocci
in clusters



Author: MUDr. Petra Kabelíková



CHARLES UNIVERSITY
Second Faculty of Medicine

Slide No. 7


Staphylococcus aureus

Specimen: blood culture

Patient: female, 84 years old

Dg.: endocarditis

Microscopy: Gram-positive cocci
in clusters



Author: MUDr. Petra Kabelíková



CHARLES UNIVERSITY
Second Faculty of Medicine

Slide No. 8

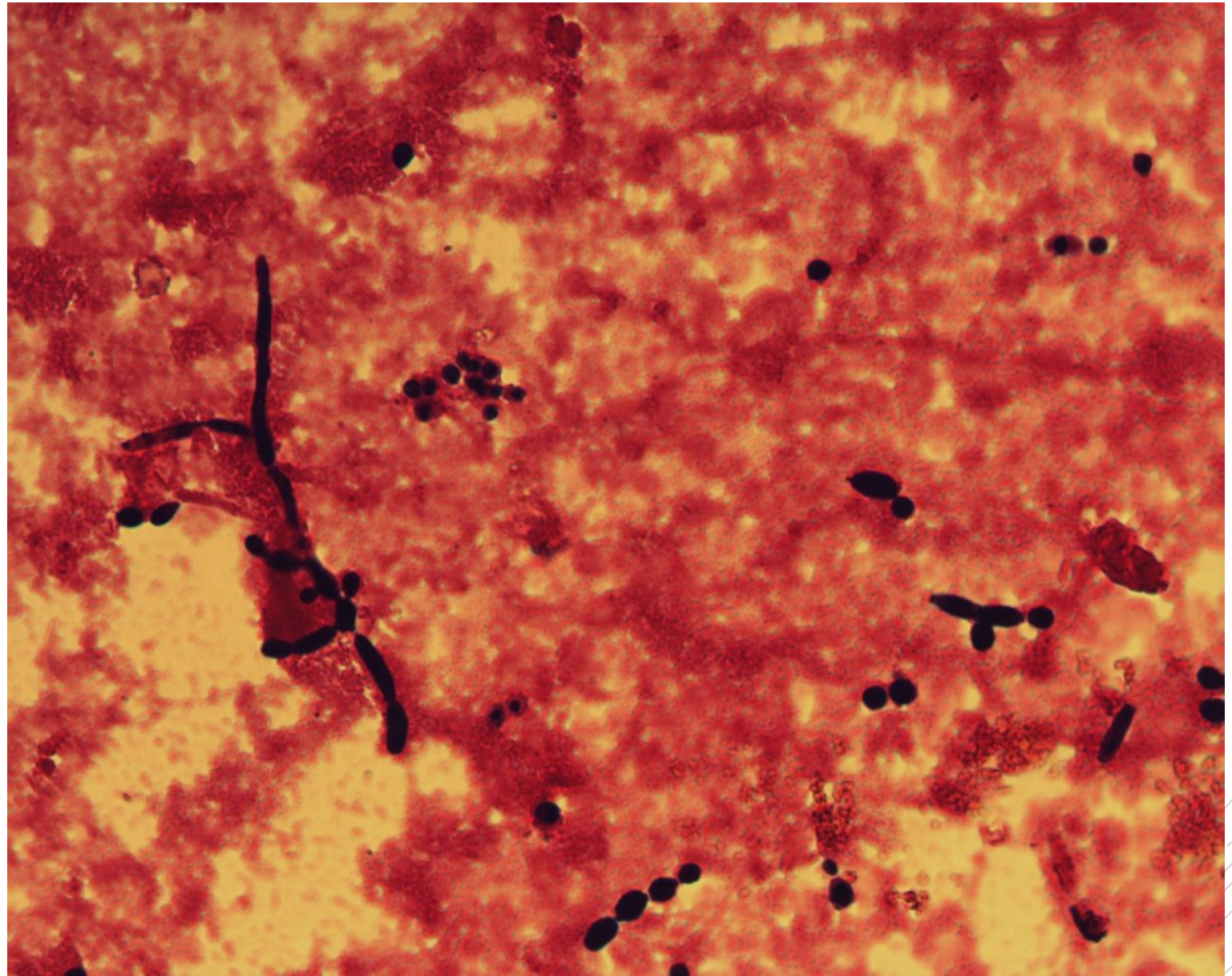
Candida albicans

Specimen: blood culture

Patient: female, 9 years old

Dg.: catheter sepsis

Microscopy: yeast blastoconidia,
pseudohyphae



Author: MUDr. Petra Kabelíková



CHARLES UNIVERSITY
Second Faculty of Medicine

Slide No. 8

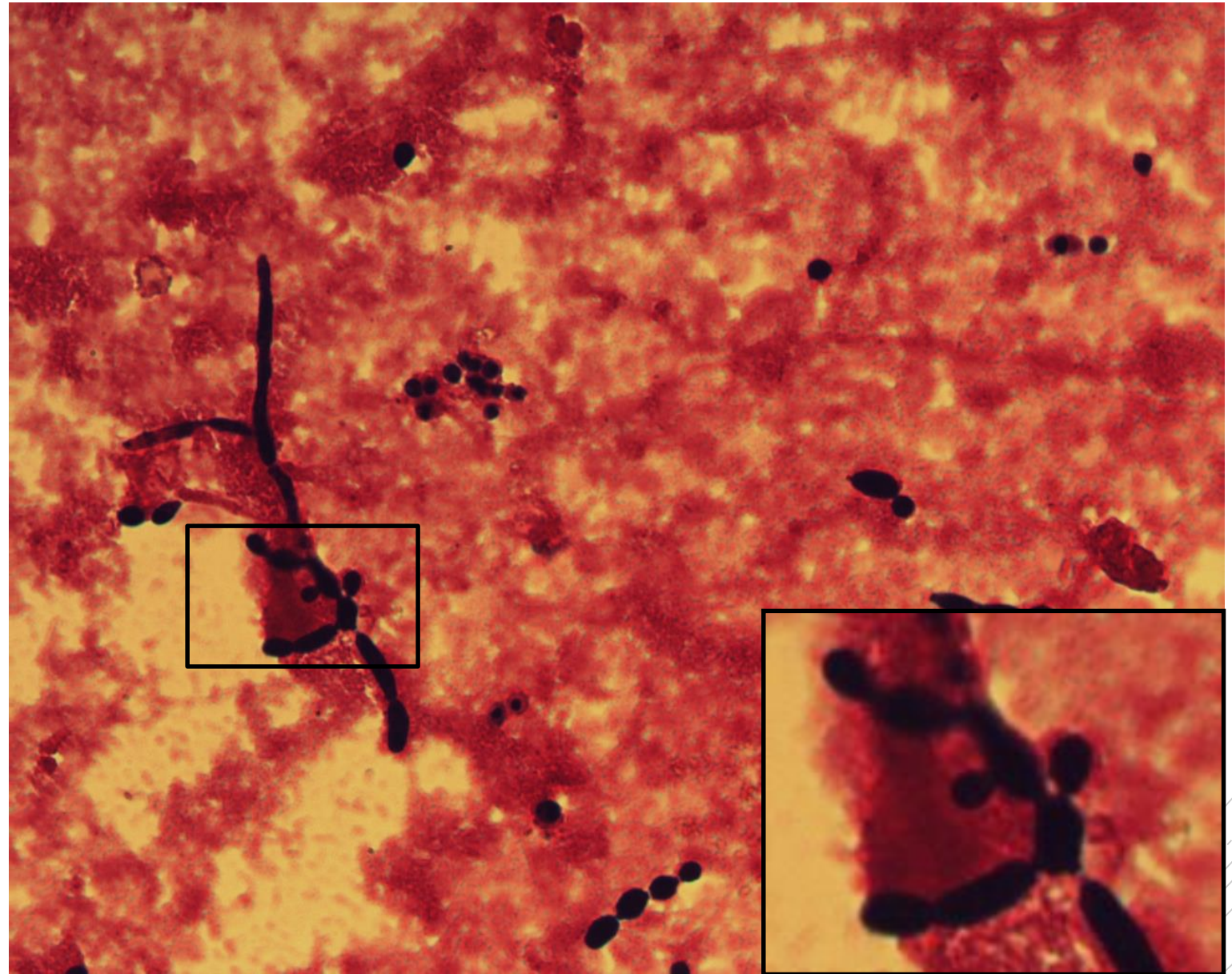
Candida albicans

Specimen: blood culture

Patient: female, 9 years old

Dg.: catheter sepsis

Microscopy: yeast blastoconidia,
pseudohyphae



Author: MUDr. Petra Kabelíková



CHARLES UNIVERSITY
Second Faculty of Medicine

Slide No. 9

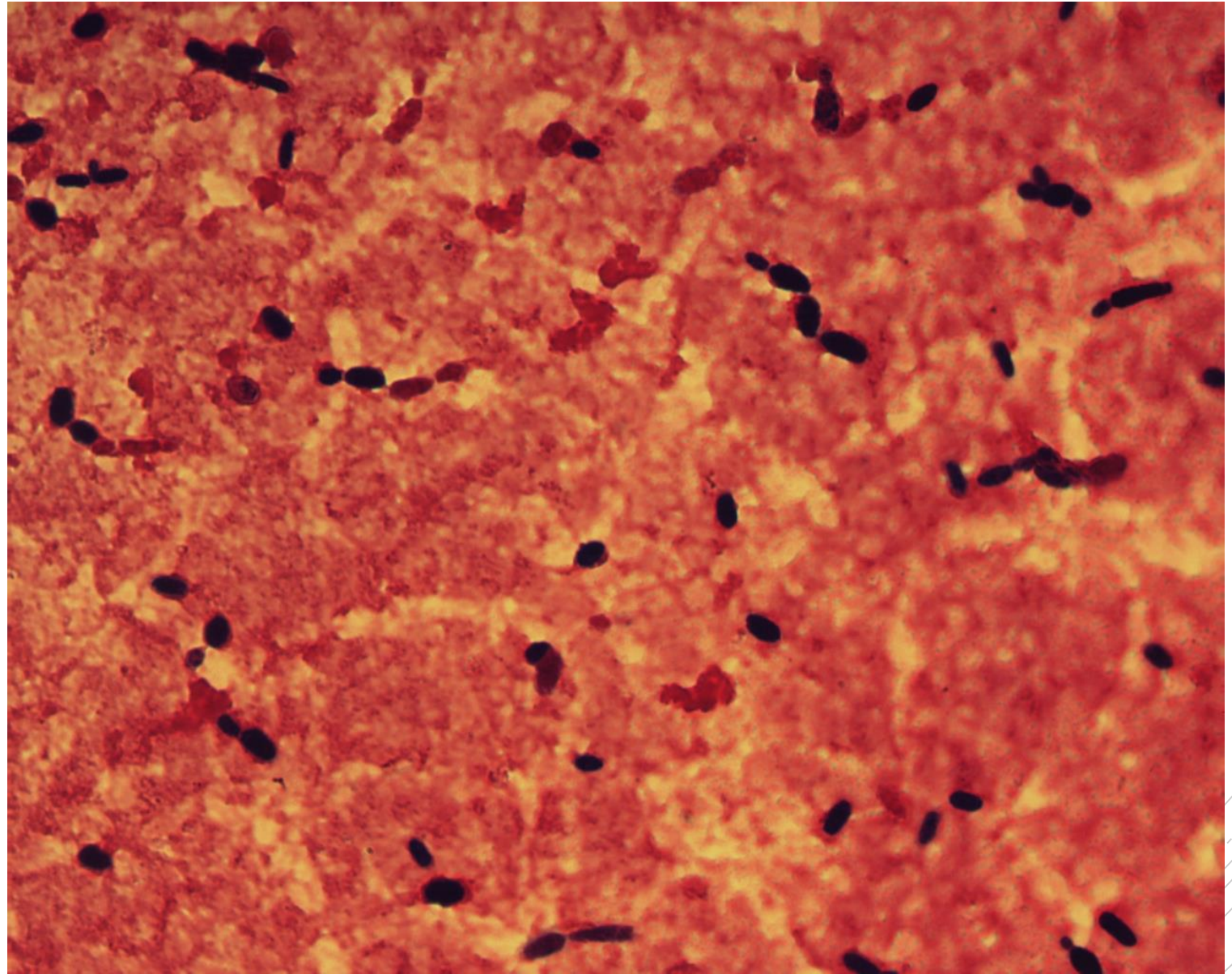
Candida tropicalis

Specimen: blood culture

Patient: female, 75 years old

Dg.: catheter sepsis

Microscopy: yeast blastoconidia



Author: MUDr. Petra Kabelíková



CHARLES UNIVERSITY
Second Faculty of Medicine

Slide No. 9

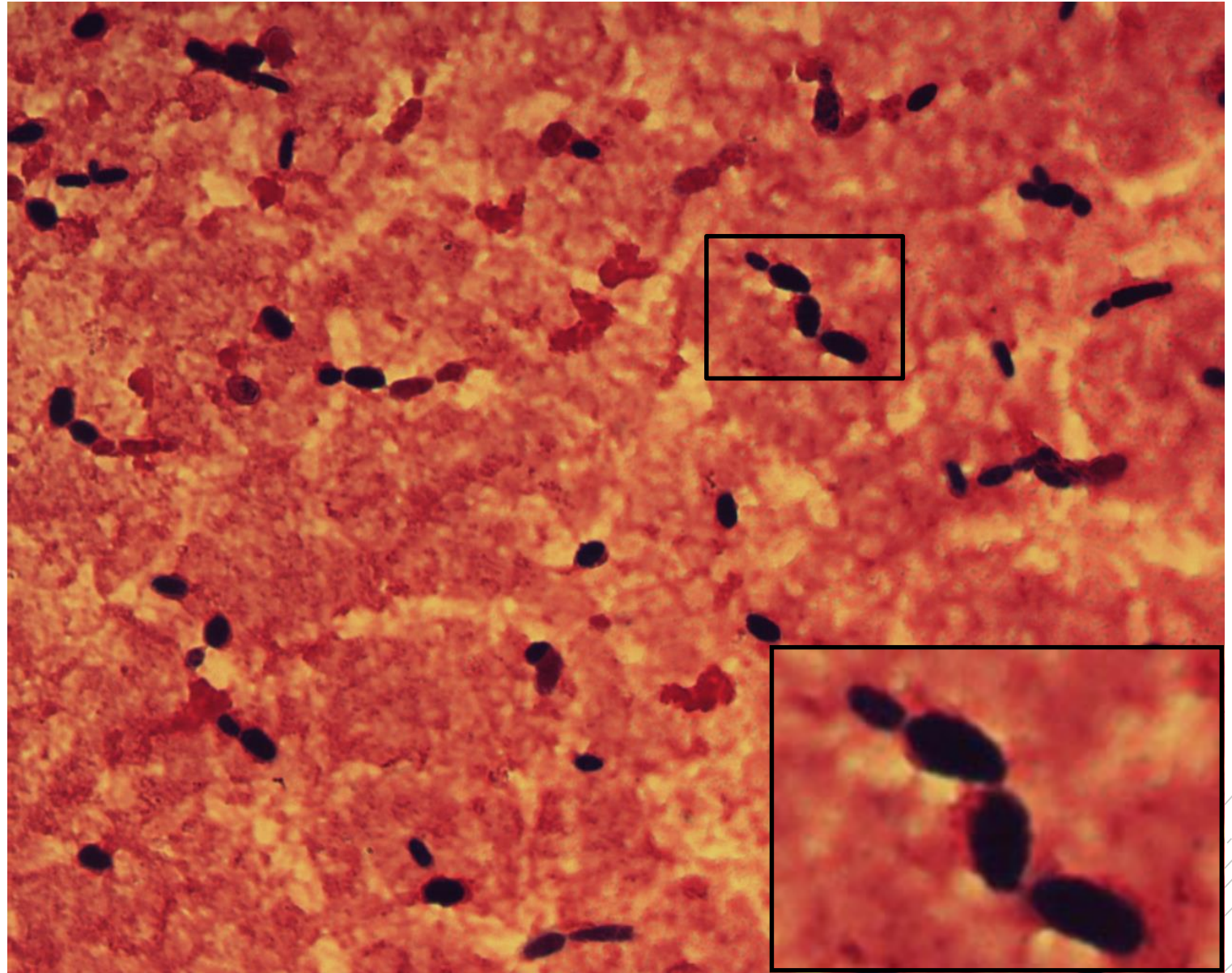
Candida tropicalis

Specimen: blood culture

Patient: female, 75 years old

Dg.: catheter sepsis

Microscopy: yeast blastoconidia



Author: MUDr. Petra Kabelíková



CHARLES UNIVERSITY
Second Faculty of Medicine

Slide No. 10

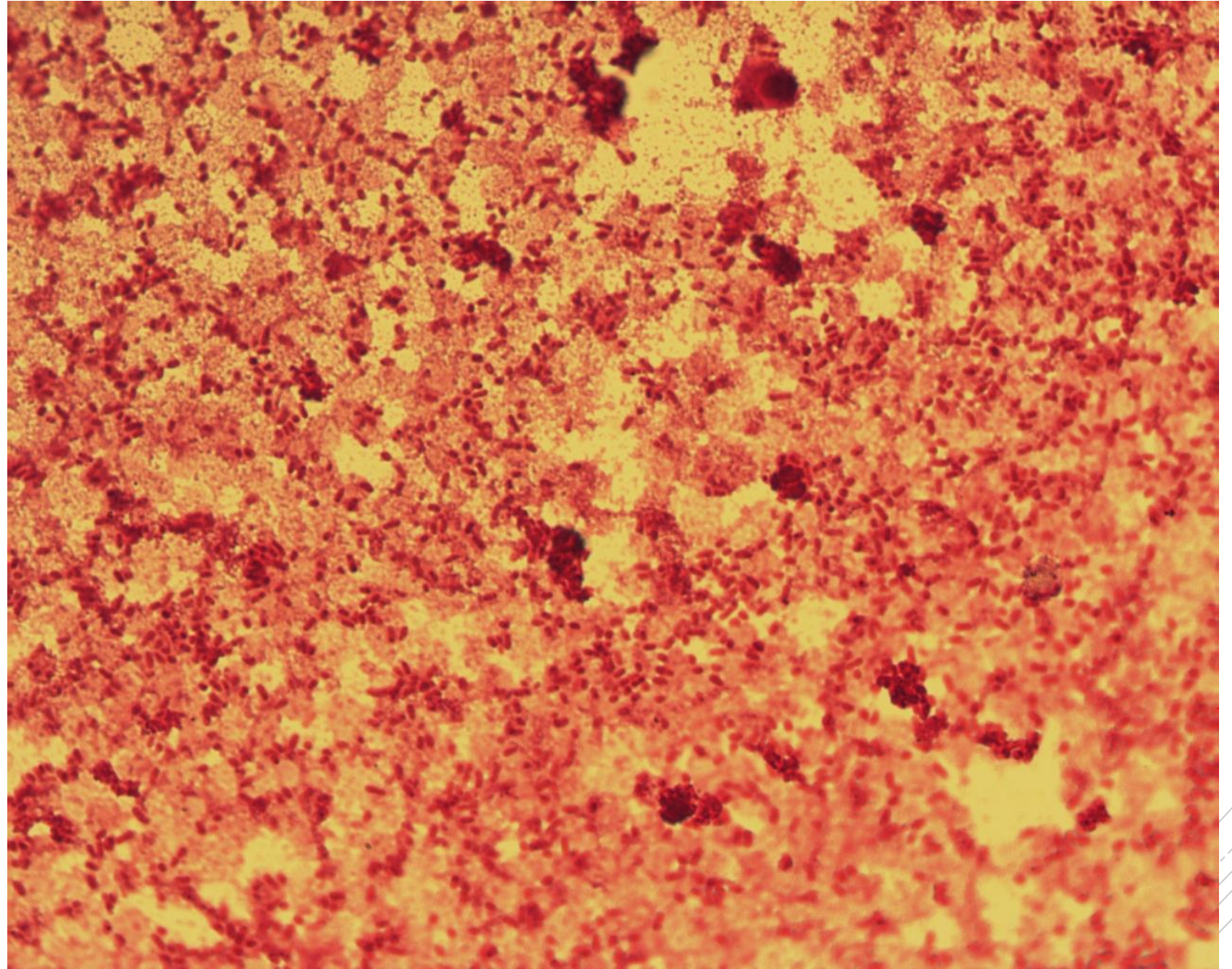
Klebsiella pneumoniae

Specimen: blood culture

Patient: male, 40 years old

Dg.: sepsis of unknown origin

Microscopy: Gram-negative rods



Author: MUDr. Petra Kabelíková



CHARLES UNIVERSITY
Second Faculty of Medicine

Slide No. 10

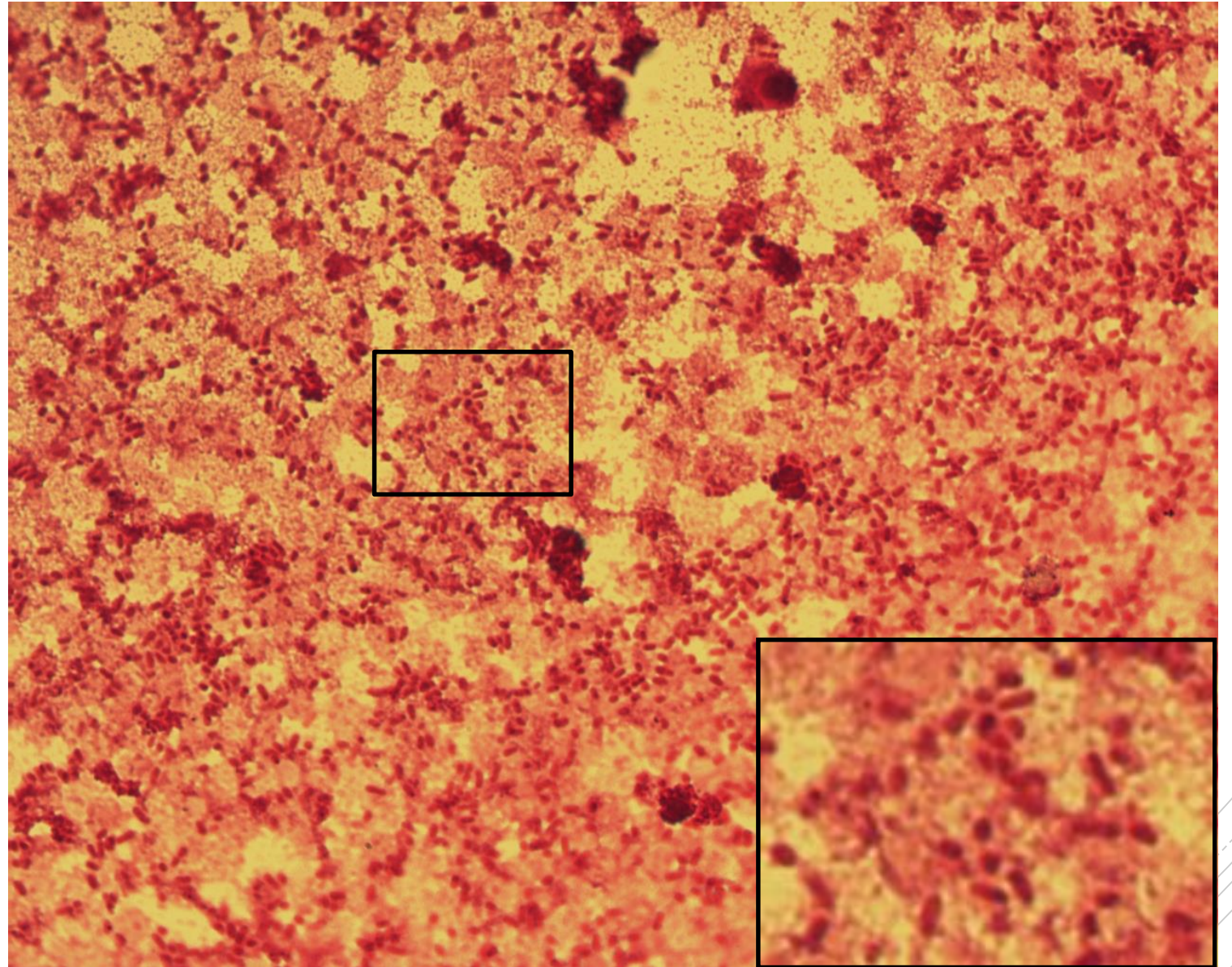
Klebsiella pneumoniae

Specimen: blood culture

Patient: male, 40 years old

Dg.: sepsis of unknown origin

Microscopy: Gram-negative rods



Author: MUDr. Petra Kabelíková



CHARLES UNIVERSITY
Second Faculty of Medicine

Slide No. 11

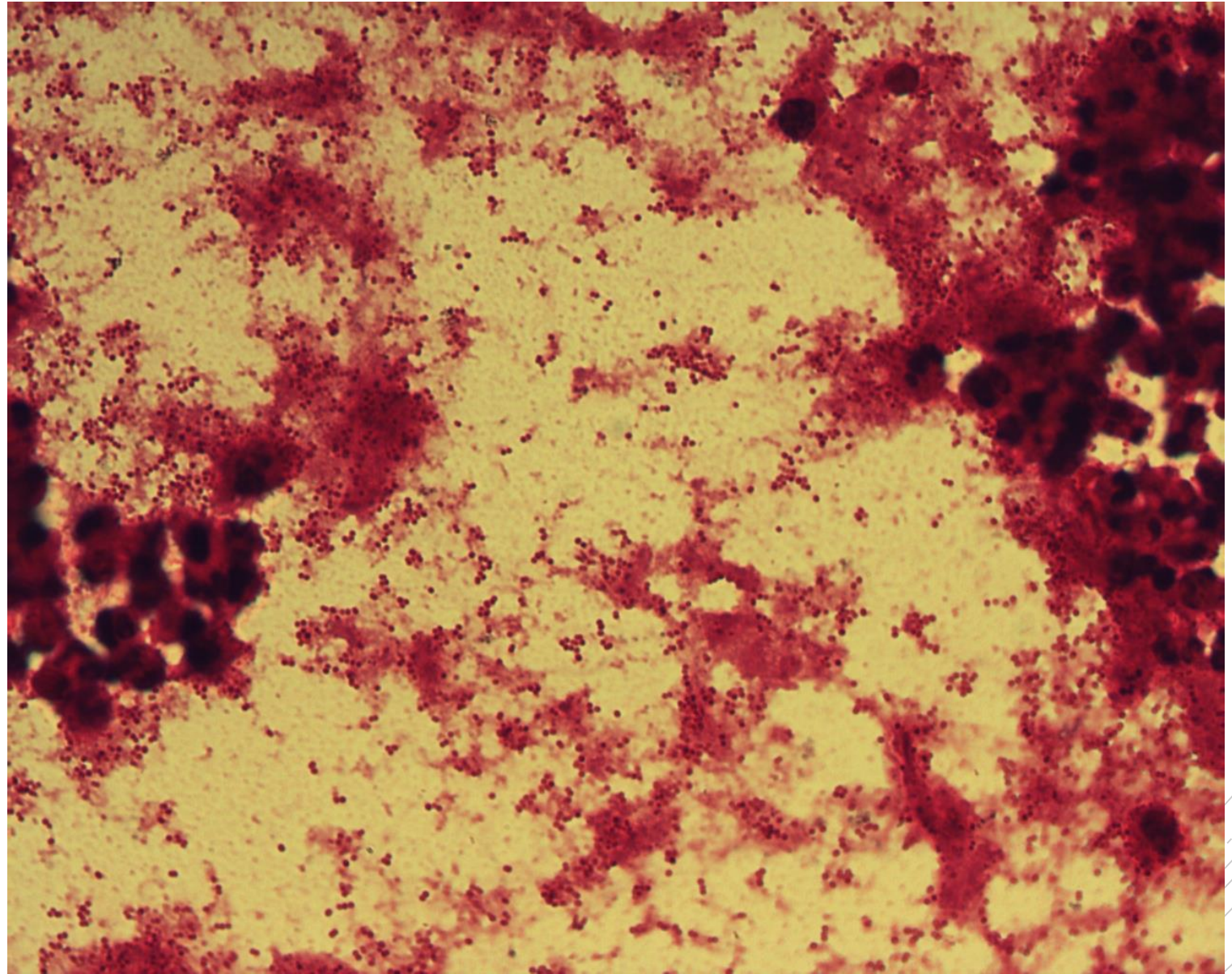
Branhamella catarrhalis

Specimen: sputum

Patient: male, 85 years old

Dg.: nosocomial pneumonia

Microscopy: Gram-negative cocci
in couples and clusters



Author: MUDr. Alena Pířová



CHARLES UNIVERSITY
Second Faculty of Medicine

Slide No. 11

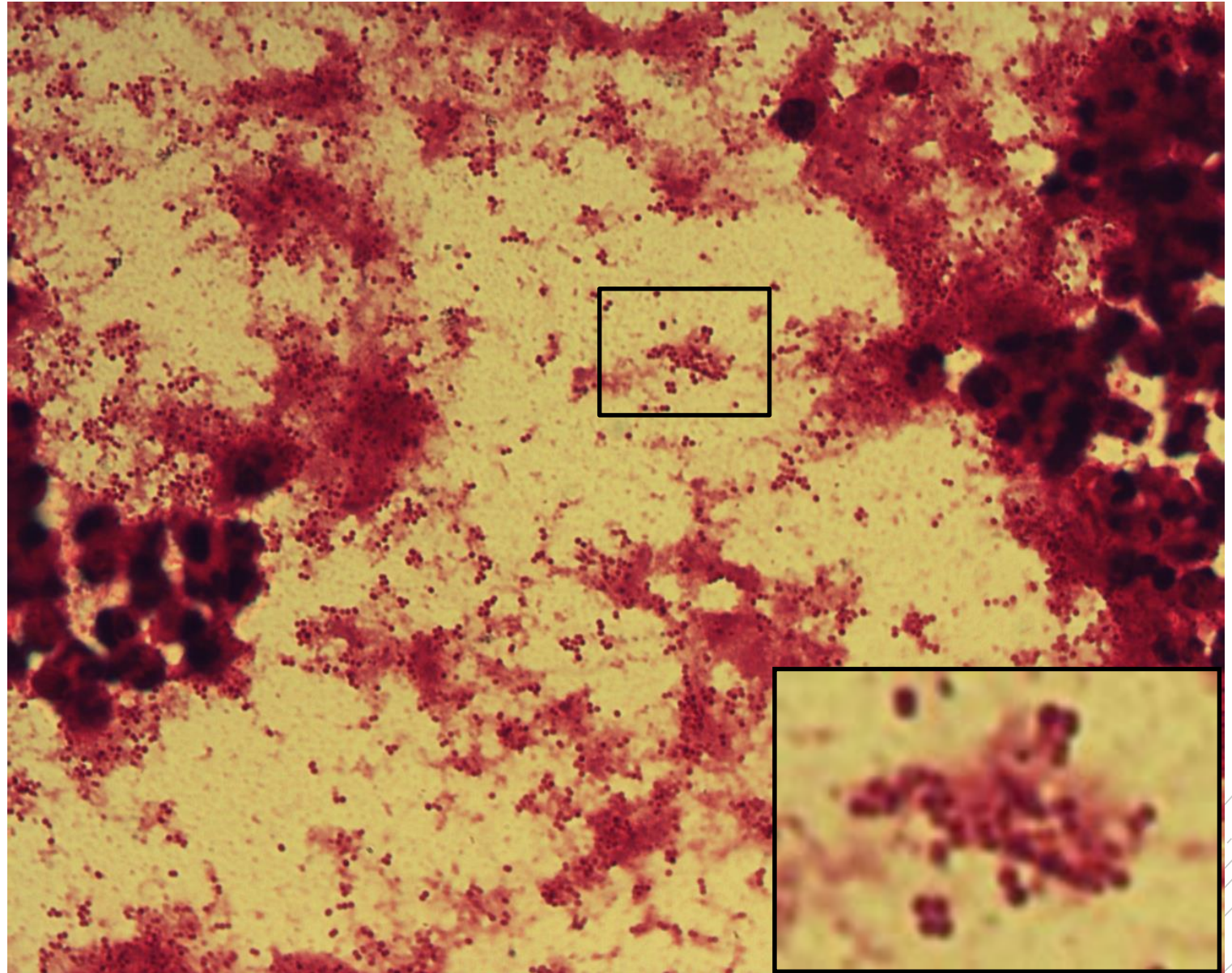
Branhamella catarrhalis

Specimen: sputum

Patient: male, 85 years old

Dg.: nosocomial pneumonia

Microscopy: Gram-negative cocci
in couples and clusters



Author: MUDr. Alena Pířová



CHARLES UNIVERSITY
Second Faculty of Medicine

Slide No. 12

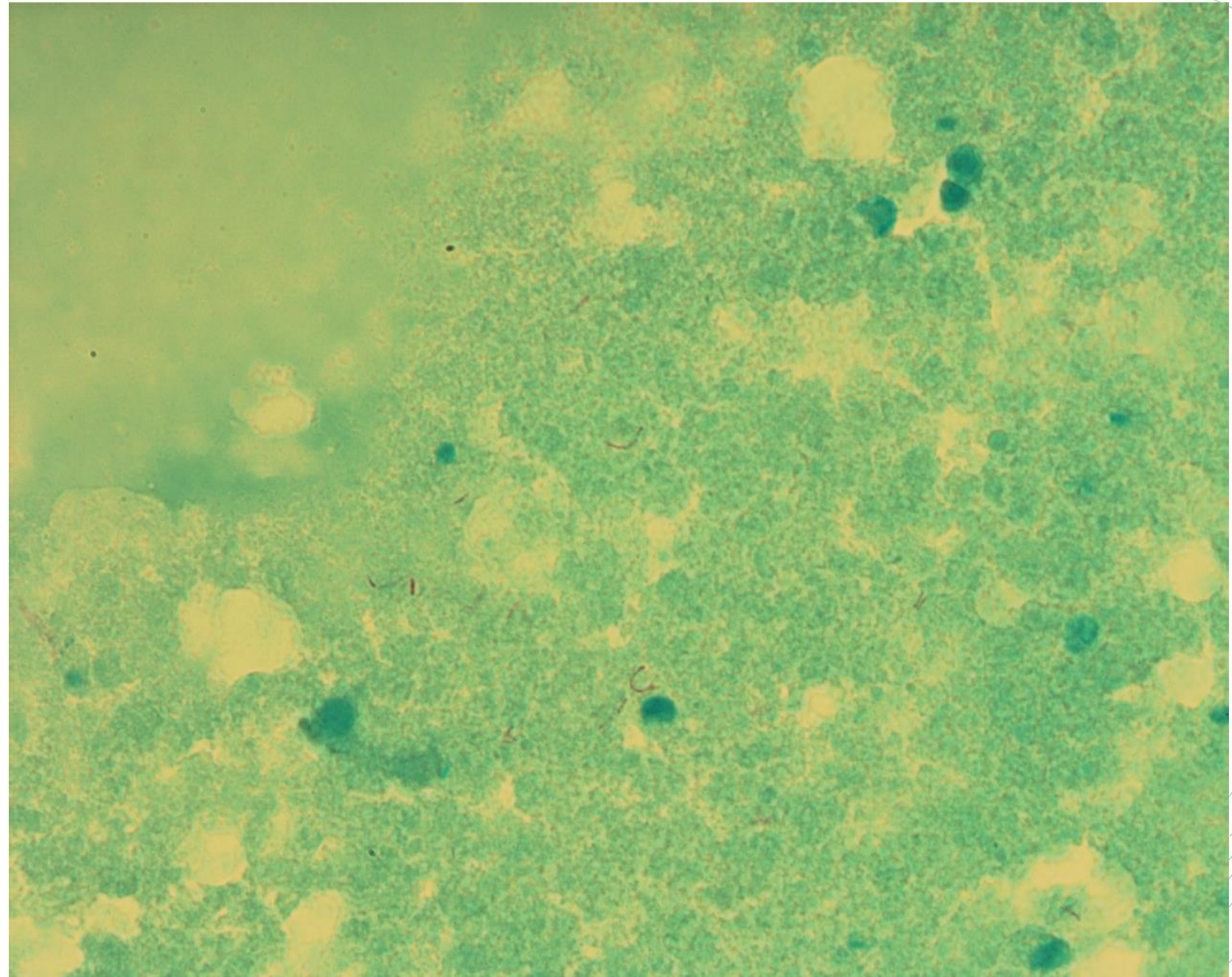
Mycobacterium abscessus

Specimen: sputum

Patient: female, 15 years old

Dg.: cystic fibrosis

Microscopy: acidoresistant rods



Author: doc. MVDr. Otto Melter, PhD.



CHARLES UNIVERSITY
Second Faculty of Medicine

Slide No. 12

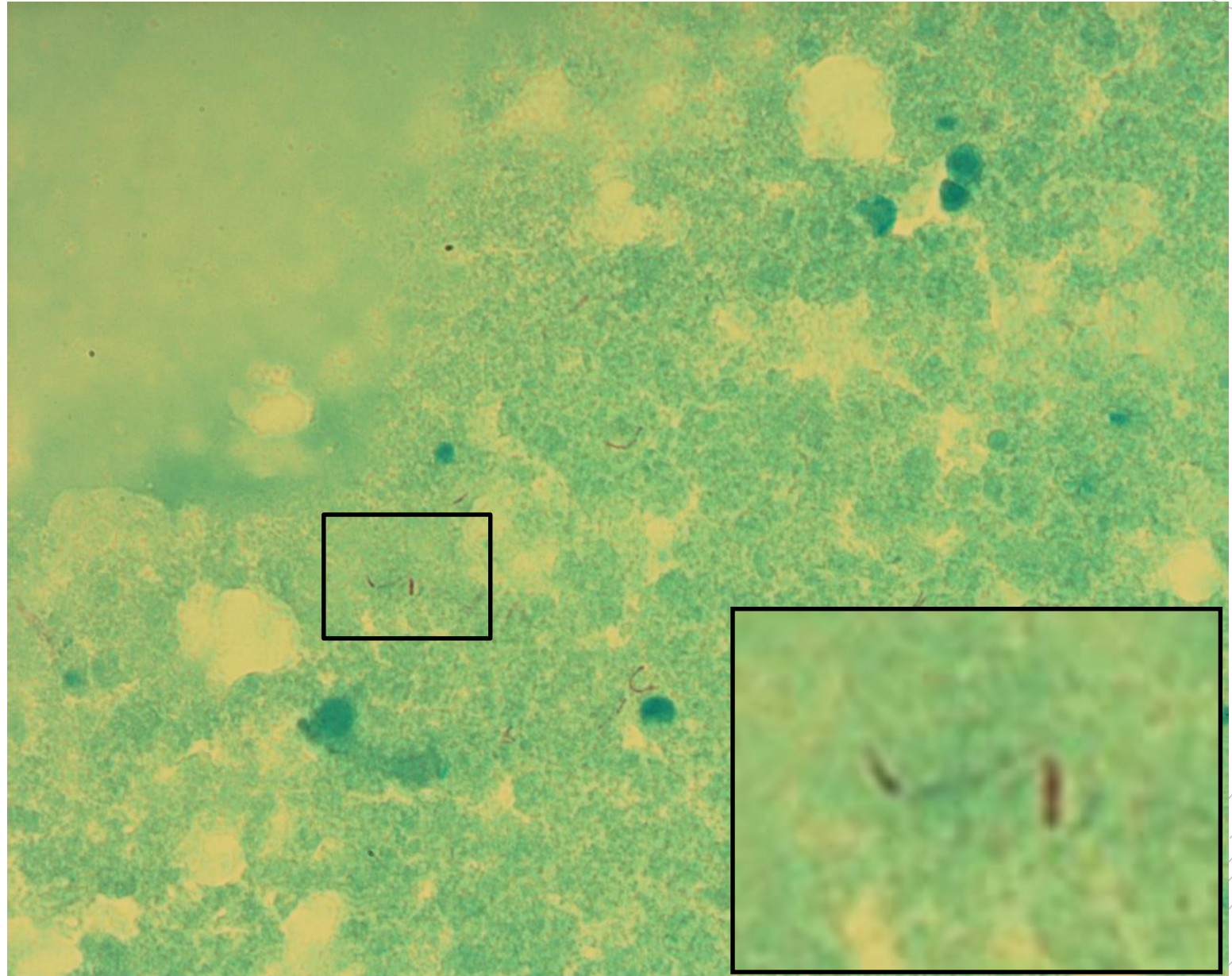
Mycobacterium abscessus

Specimen: sputum

Patient: female, 15 years old

Dg.: cystic fibrosis

Microscopy: acidoresistant rods



Author: doc. MVDr. Otto Melter, PhD.



CHARLES UNIVERSITY
Second Faculty of Medicine

Slide No. 13

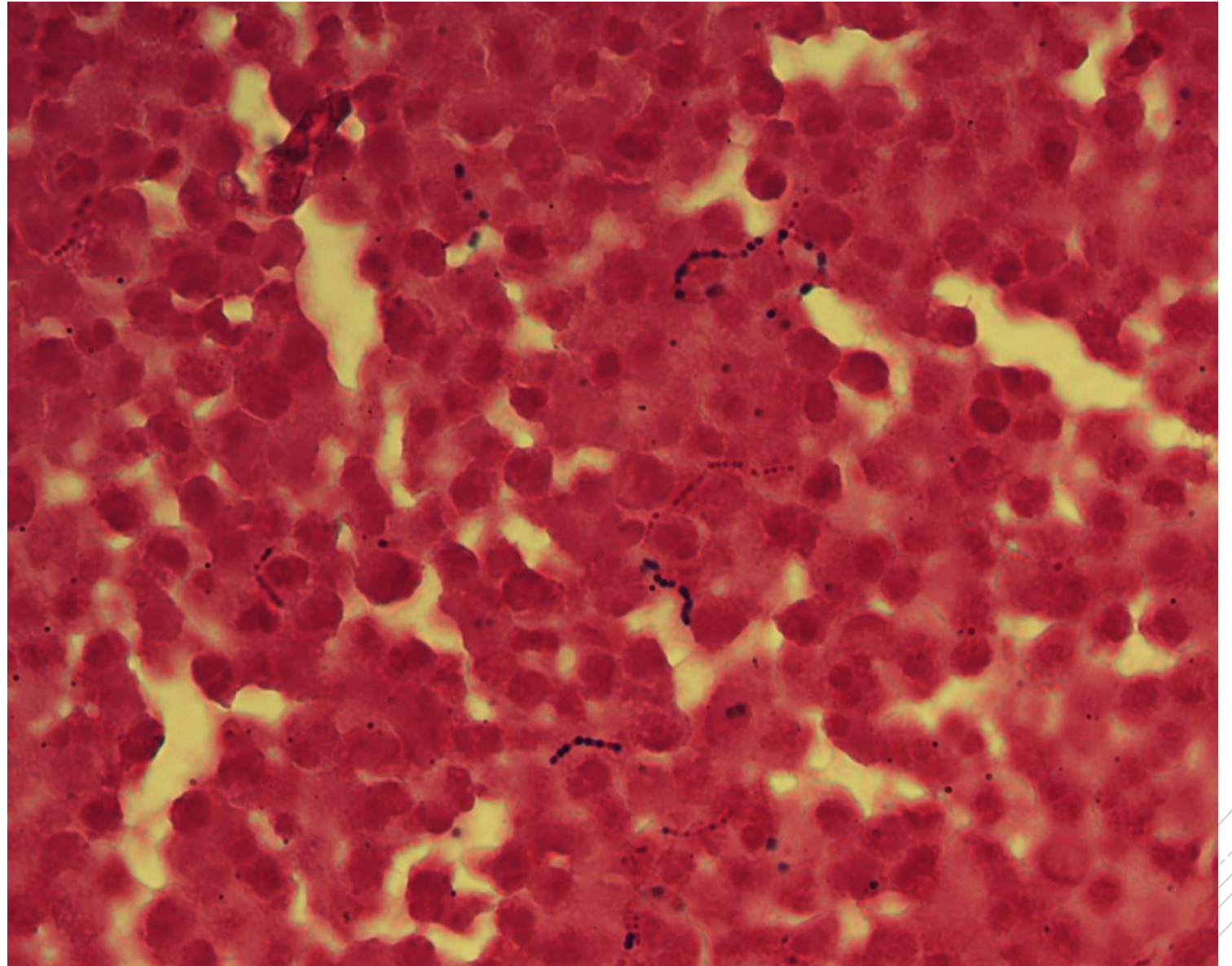
Streptococcus agalactiae

Specimen: joint fluid

Patient: male, 47 years old

Dg.: infectious arthritis

Microscopy: Gram-positive cocci
in chains



Author: MUDr. Lenka Tritová



CHARLES UNIVERSITY
Second Faculty of Medicine

Slide No. 13

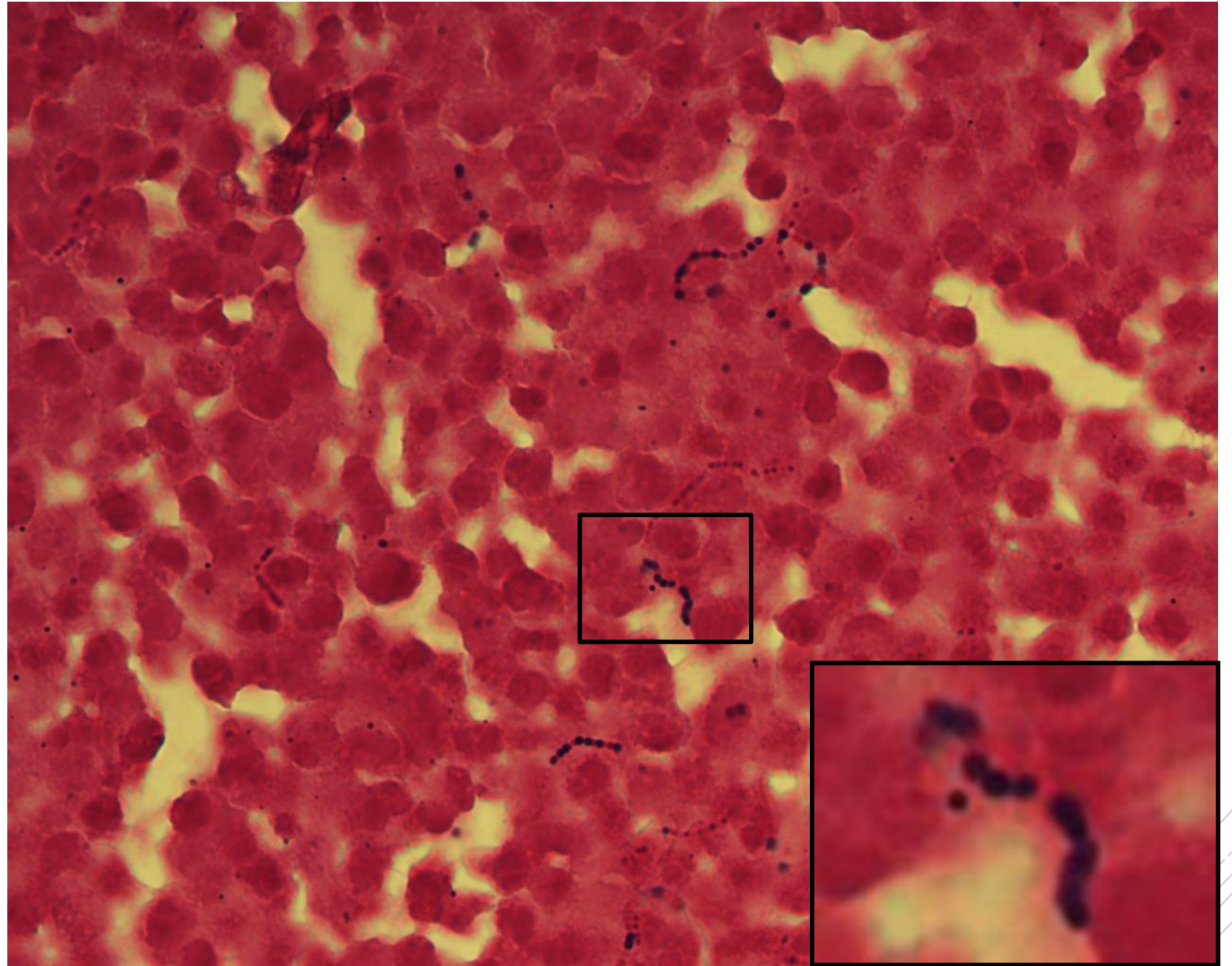
Streptococcus agalactiae

Specimen: joint fluid

Patient: male, 47 years old

Dg.: infectious arthritis

Microscopy: Gram-positive cocci
in chains



Author: MUDr. Lenka Tritová



CHARLES UNIVERSITY
Second Faculty of Medicine

Slide No. 14

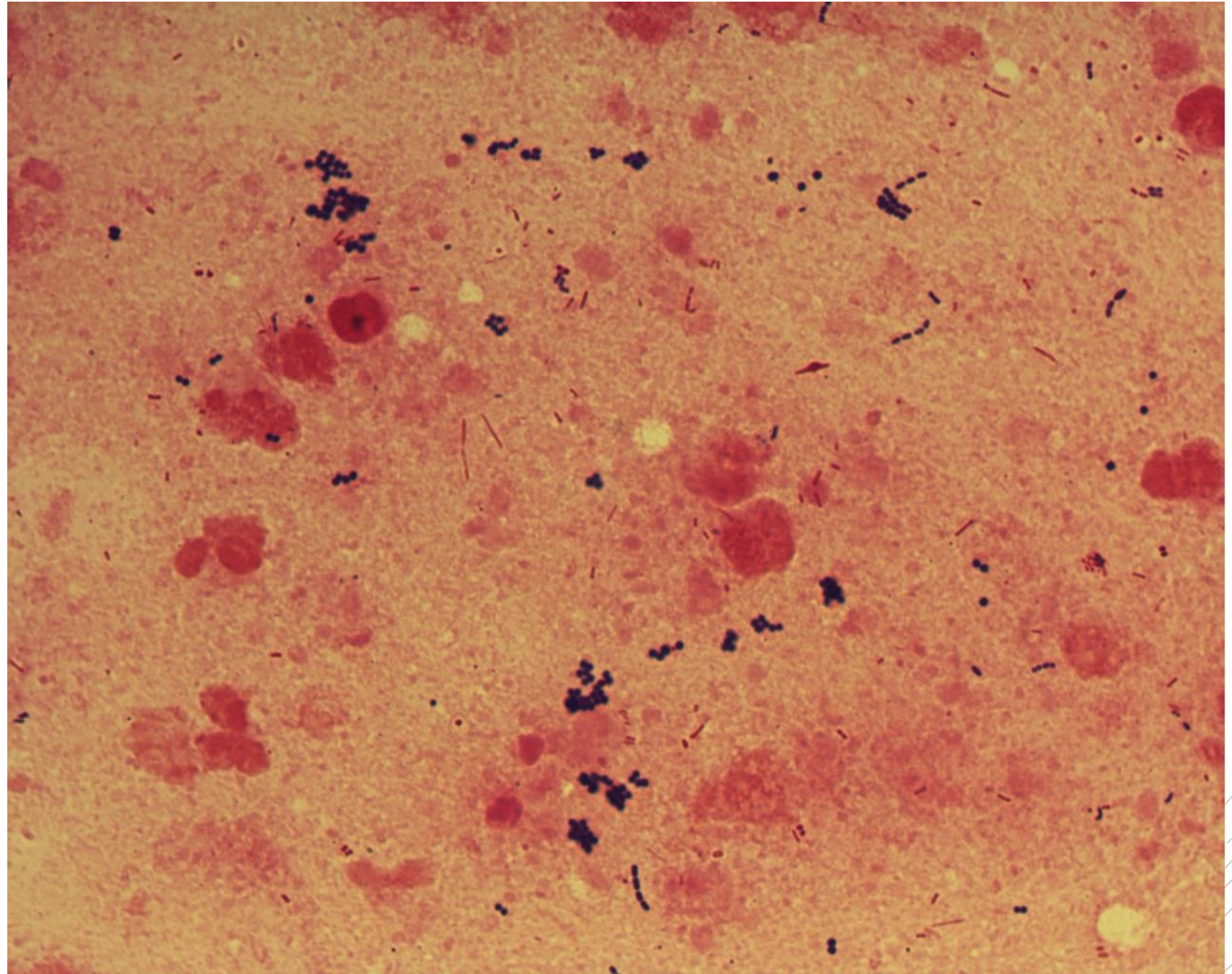
Staphylococcus aureus,
Pseudomonas aeruginosa

Specimen: sputum

Patient: male, 17 years old

Dg.: cystic fibrosis

Microscopy: Gram-positive cocci
in clusters, Gram-negative rods



Author: doc. MVDr. Otto Melter, PhD.



CHARLES UNIVERSITY
Second Faculty of Medicine

Slide No. 14

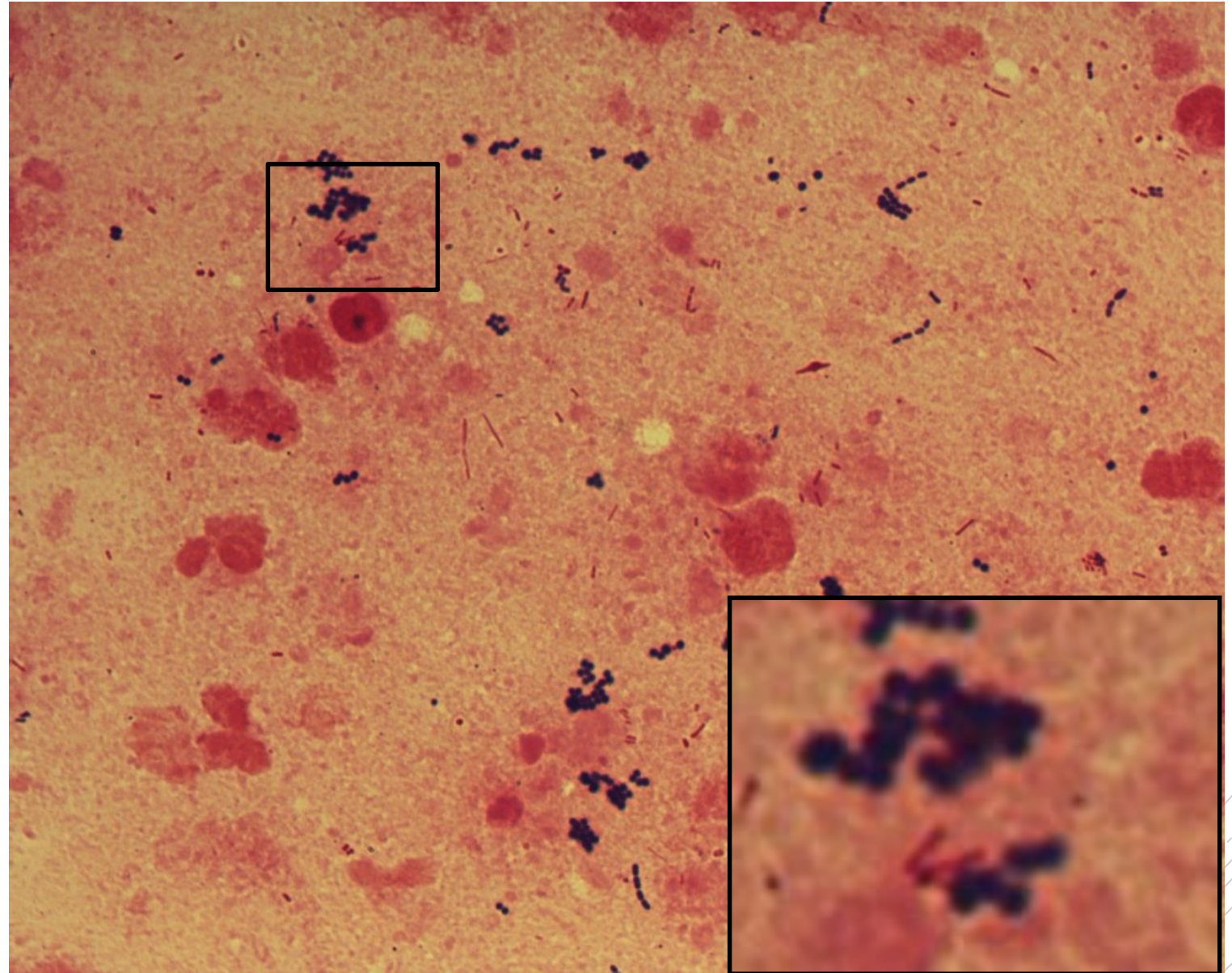
Staphylococcus aureus,
Pseudomonas aeruginosa

Specimen: sputum

Patient: male, 17 years old

Dg.: cystic fibrosis

Microscopy: Gram-positive cocci in clusters, Gram-negative rods



Author: doc. MVDr. Otto Melter, PhD.



CHARLES UNIVERSITY
Second Faculty of Medicine

Slide No. 15

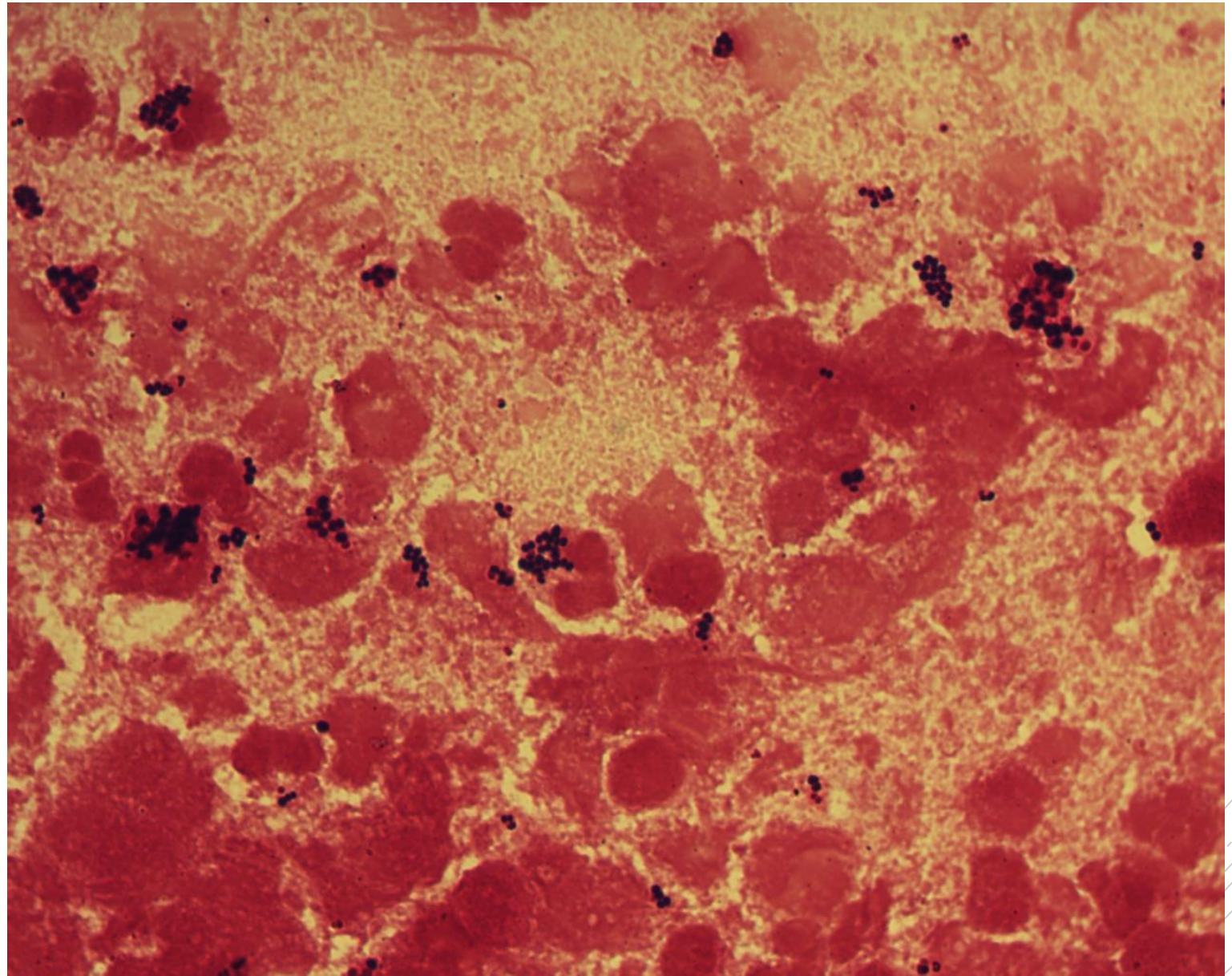
Staphylococcus aureus

Specimen: sputum

Patient: female, 21 years old

Dg.: cystic fibrosis

Microscopy: Gram-positive cocci
in clusters



Author: doc. MVDr. Otto Melter, PhD.



CHARLES UNIVERSITY
Second Faculty of Medicine

Slide No. 15

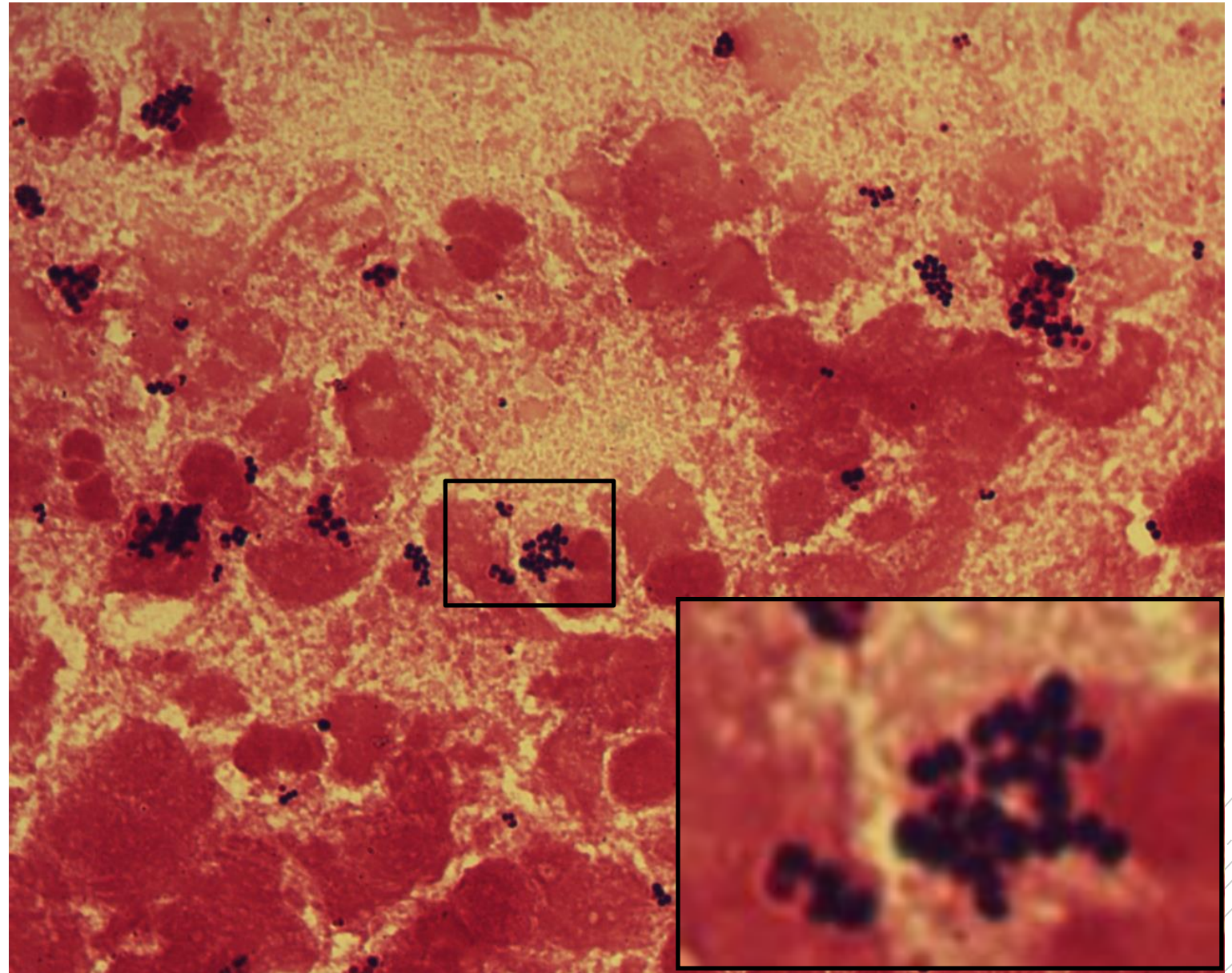
Staphylococcus aureus

Specimen: sputum

Patient: female, 21 years old

Dg.: cystic fibrosis

Microscopy: Gram-positive cocci
in clusters



Author: doc. MVDr. Otto Melter, PhD.



CHARLES UNIVERSITY
Second Faculty of Medicine

Slide No. 16

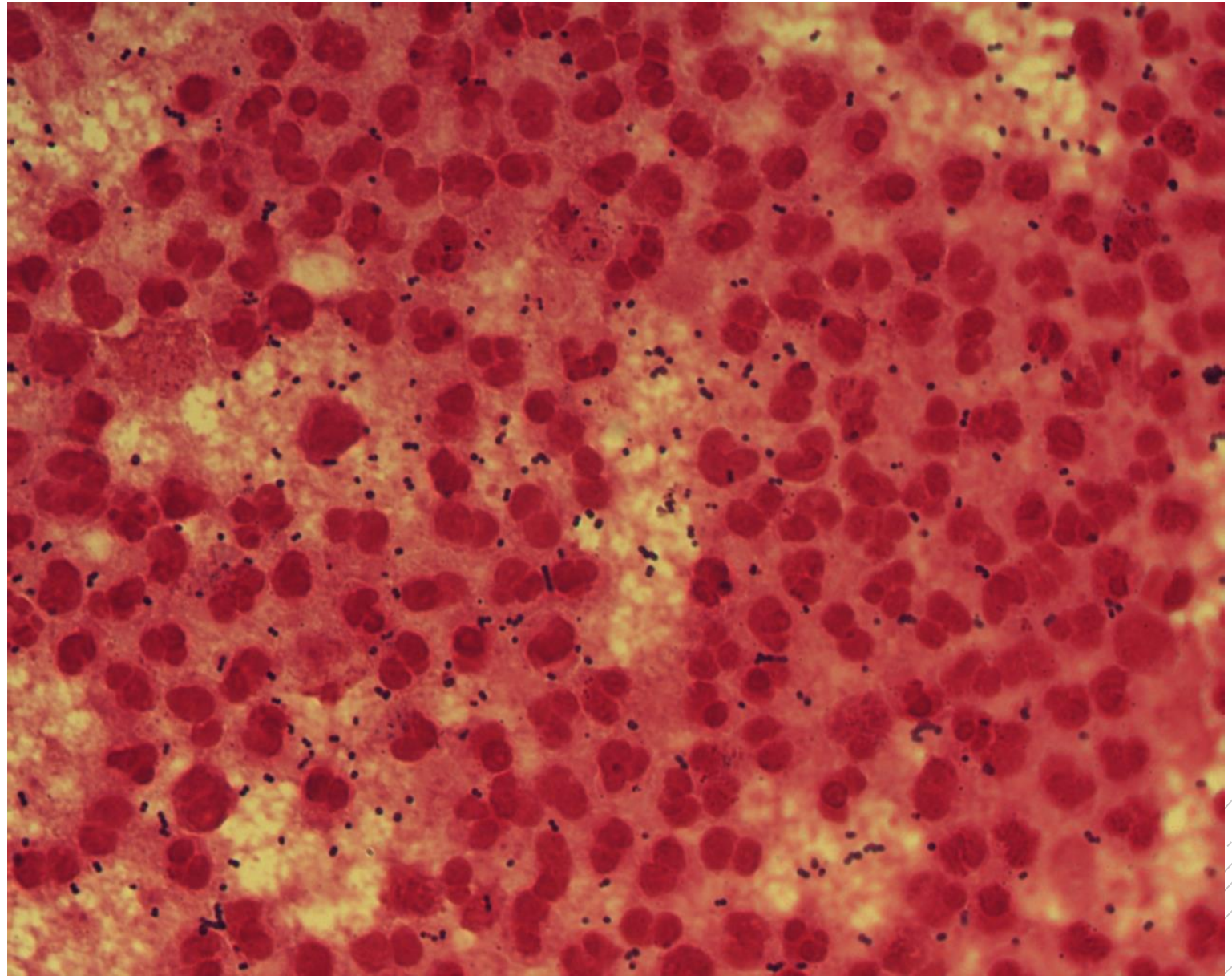
*Streptococcus
beta-haemolyticus
group G*

Specimen: knee joint fluid

Patient: male, 81 years old

Dg.: prosthesis infection

Microscopy: Gram-positive diplococci



Author: MUDr. Anastázia Ešnerová



CHARLES UNIVERSITY
Second Faculty of Medicine

Slide No. 16

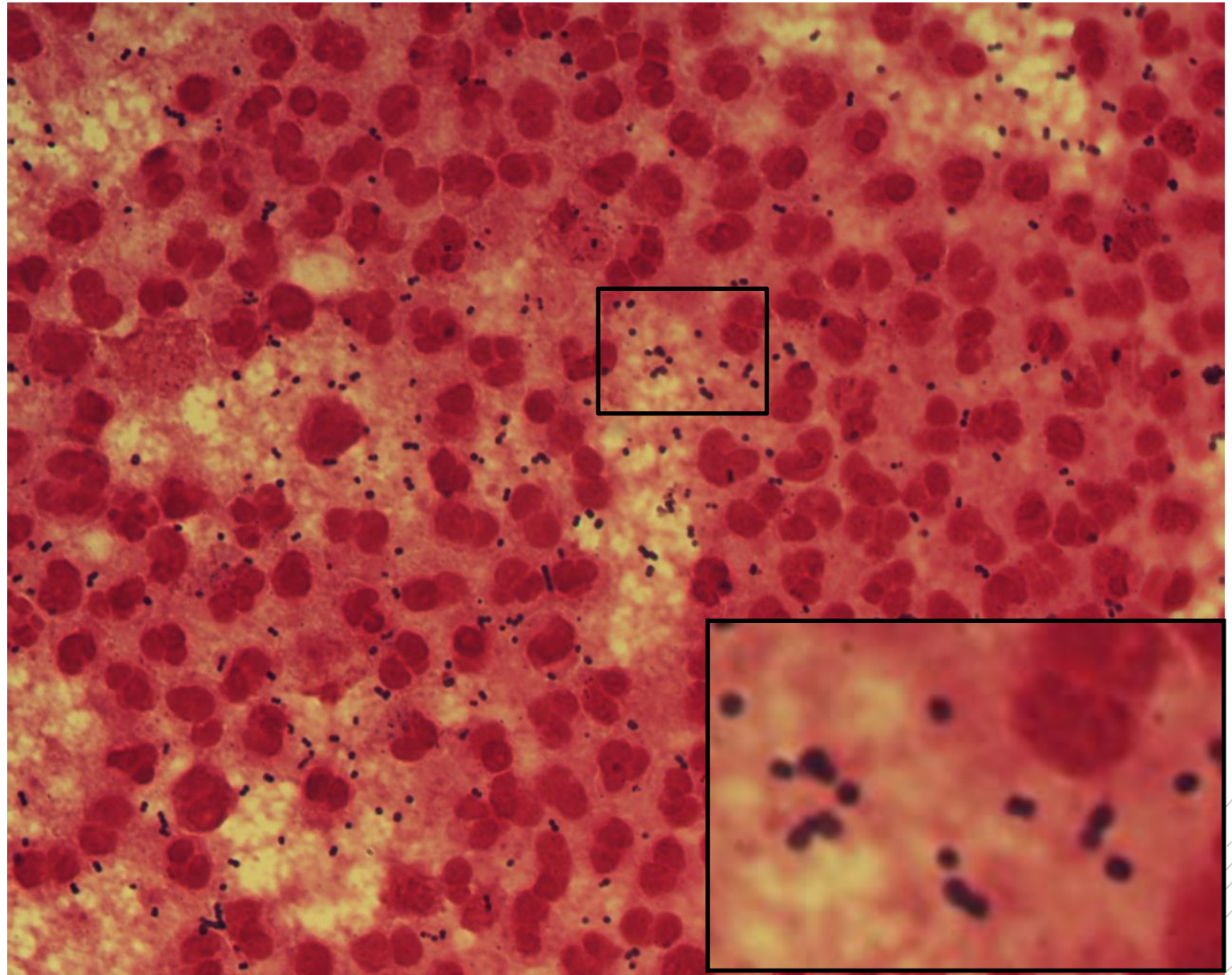
*Streptococcus
beta-haemolyticus
group G*

Specimen: knee joint fluid

Patient: male, 81 years old

Dg.: prosthesis infection

Microscopy: Gram-positive diplococci



Author: MUDr. Anastázia Ešnerová



CHARLES UNIVERSITY
Second Faculty of Medicine

Slide No. 17

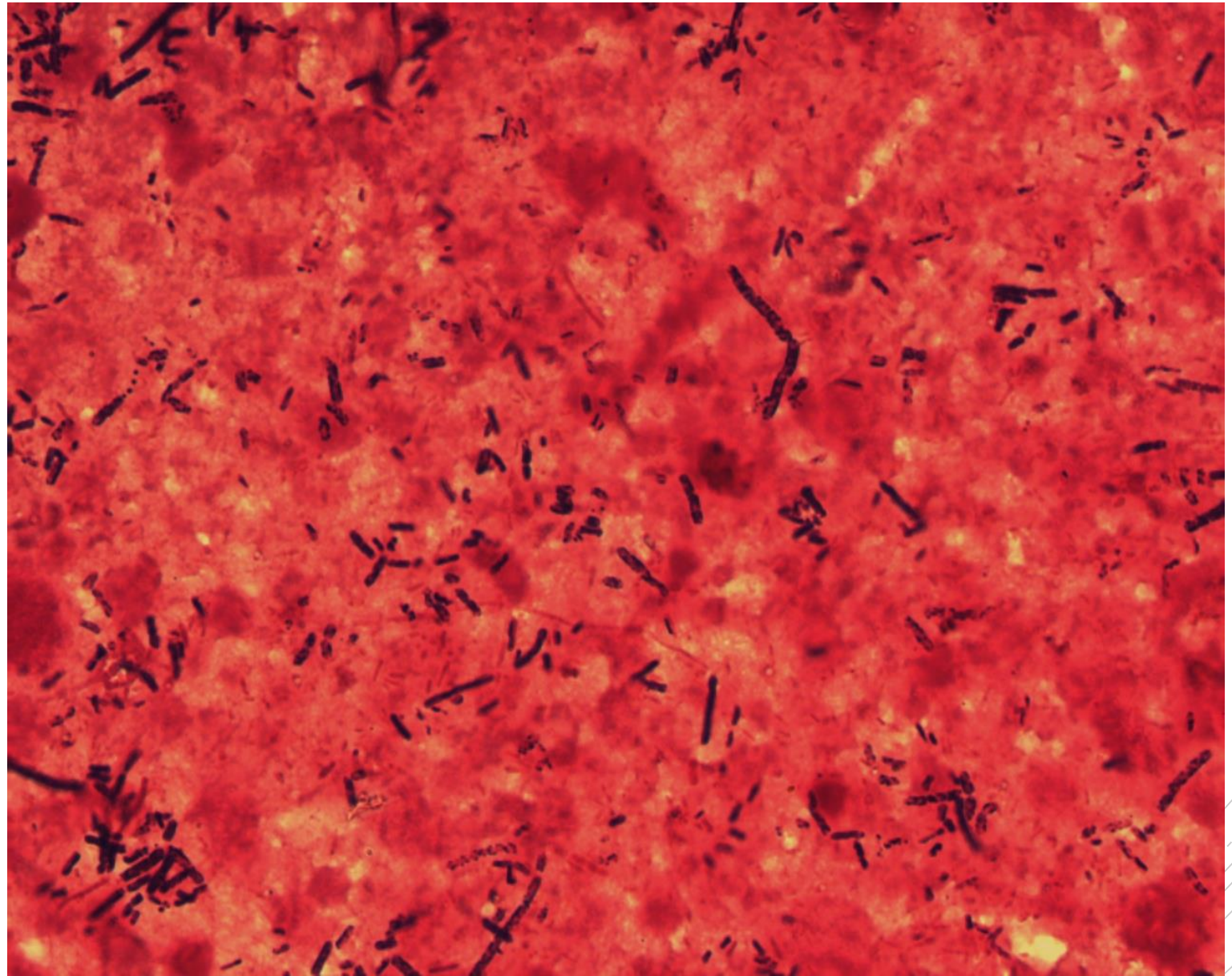
Clostridium perfringens

Specimen: liver puncture fluid

Patient: female, 80 years old

Dg.: liver abscess

Microscopy: Gram-positive
spore-forming rods



Author: MUDr. Alena Pířová

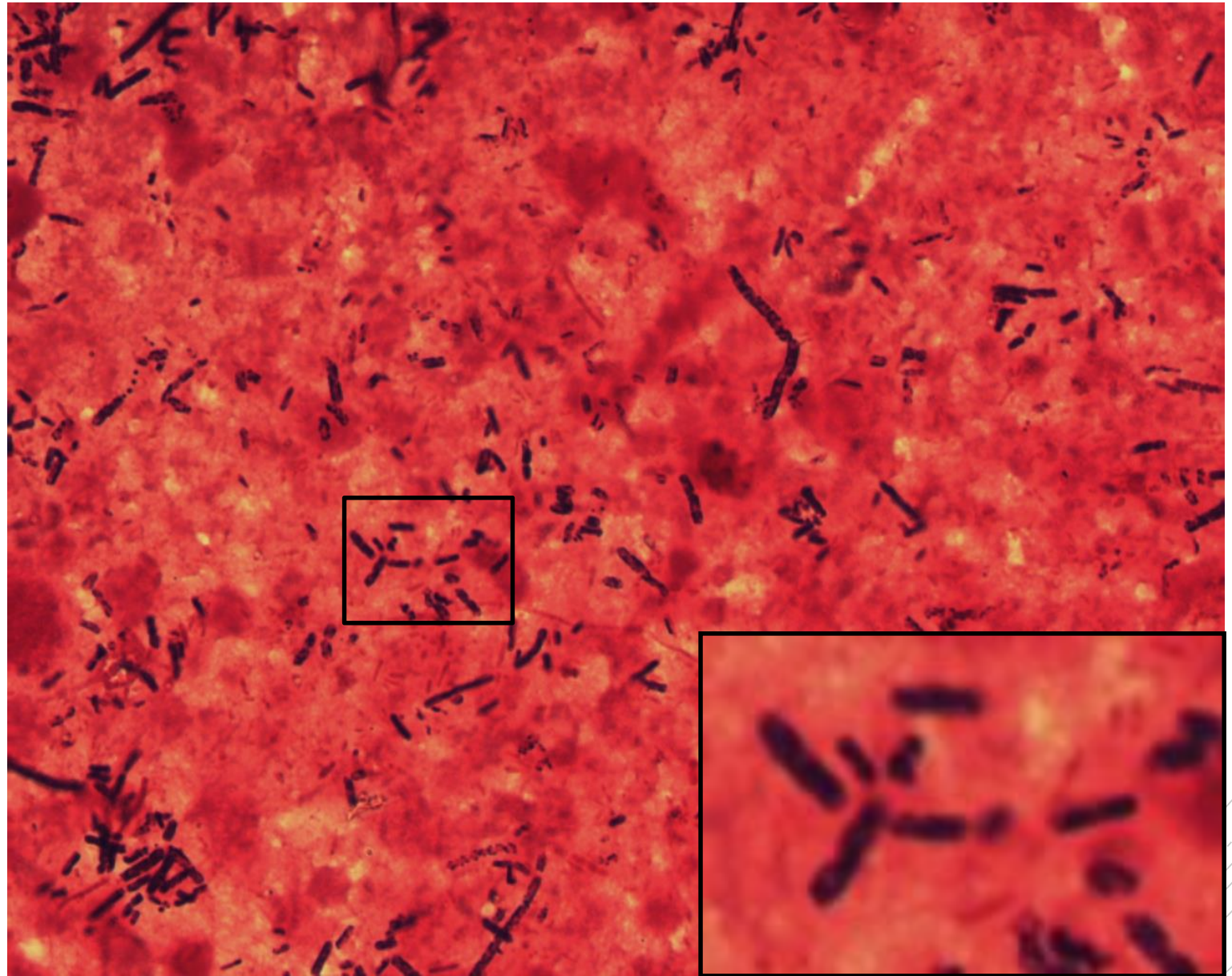


CHARLES UNIVERSITY
Second Faculty of Medicine

Slide No. 17

Clostridium perfringens

Specimen: liver puncture fluid
Patient: female, 80 years old
Dg.: liver abscess
Microscopy: Gram-positive
spore-forming rods



Author: MUDr. Alena Pířová



CHARLES UNIVERSITY
Second Faculty of Medicine

Slide No. 18

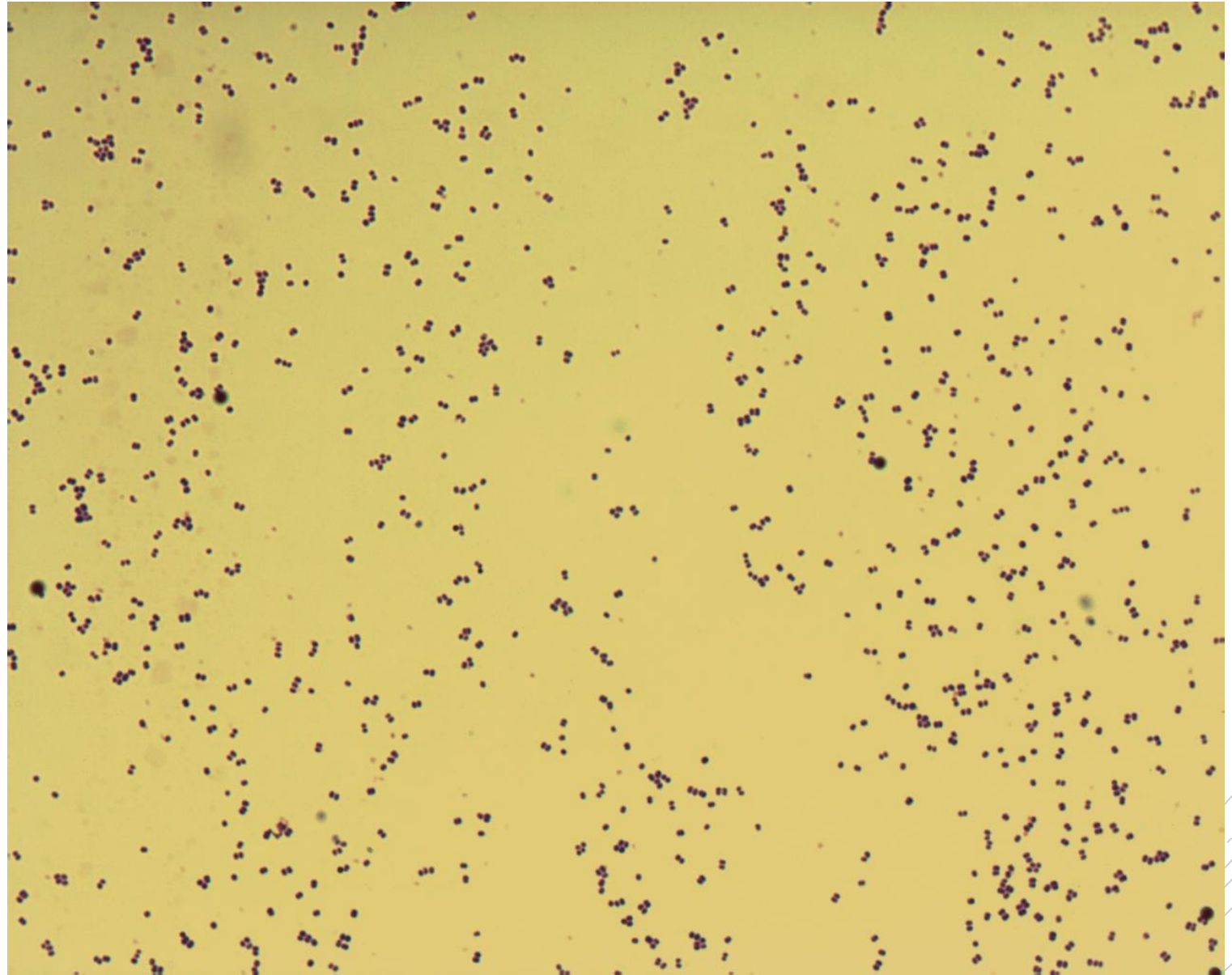
Staphylococcus epidermidis

Specimen: culture – heart valve

Patient: male, 52 years old

Dg.: endocarditis

Microscopy: Gram-positive cocci



Authors: Markéta Šolarová, Hana Nekvasilová



CHARLES UNIVERSITY
Second Faculty of Medicine

Slide No. 18


Staphylococcus epidermidis

Specimen: culture – heart valve

Patient: male, 52 years old

Dg.: endocarditis

Microscopy: Gram-positive cocci



Authors: Markéta Šolarová, Hana Nekvasilová



CHARLES UNIVERSITY
Second Faculty of Medicine

Slide No. 19

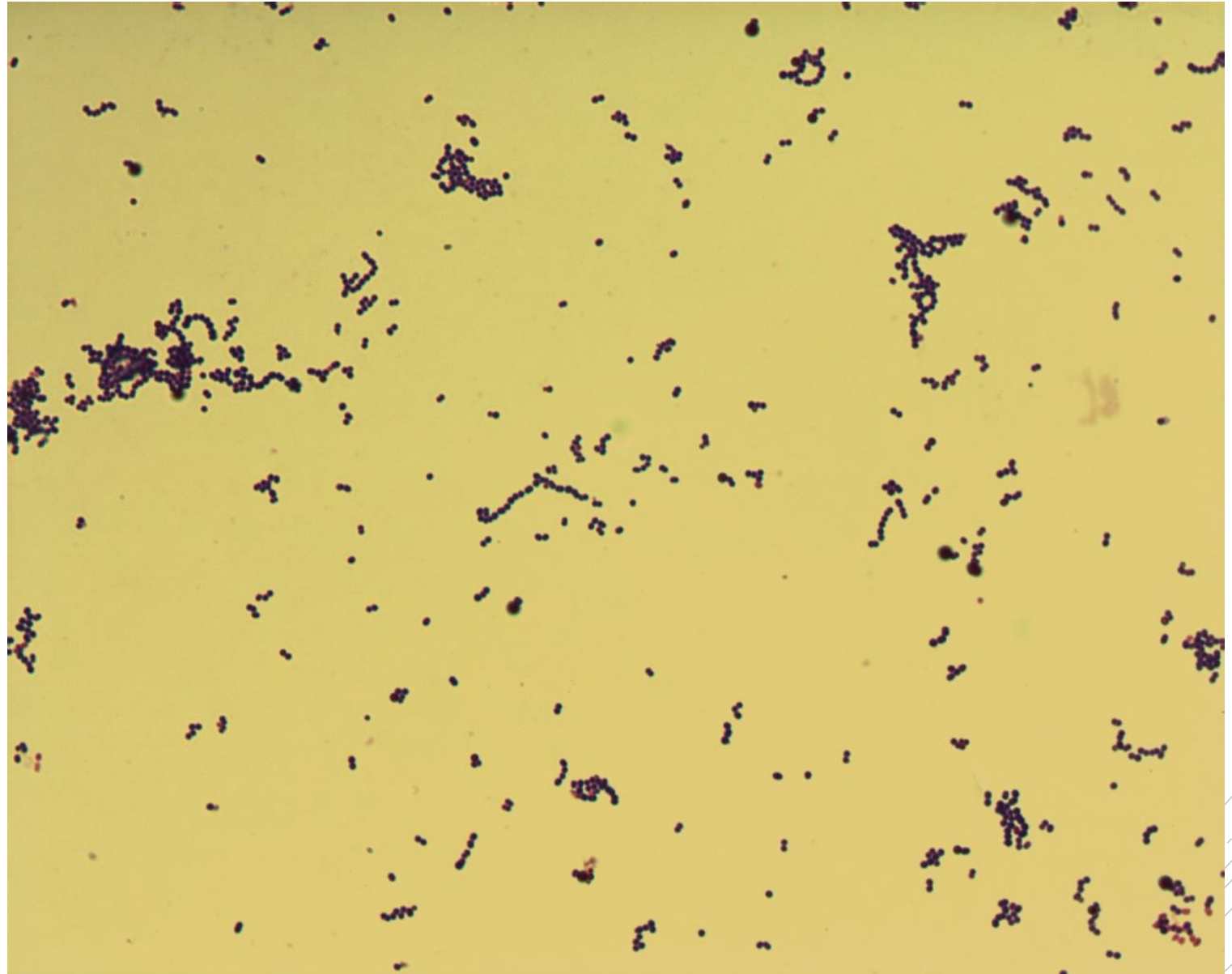
Streptococcus pyogenes

Specimen: culture – tissue biopsy

Patient: male, 40 years old

Dg.: necrotizing fasciitis

Microscopy: Gram-positive cocci
in chains



Authors: Markéta Šolarová, Hana Nekvasilová



CHARLES UNIVERSITY
Second Faculty of Medicine

Slide No. 19

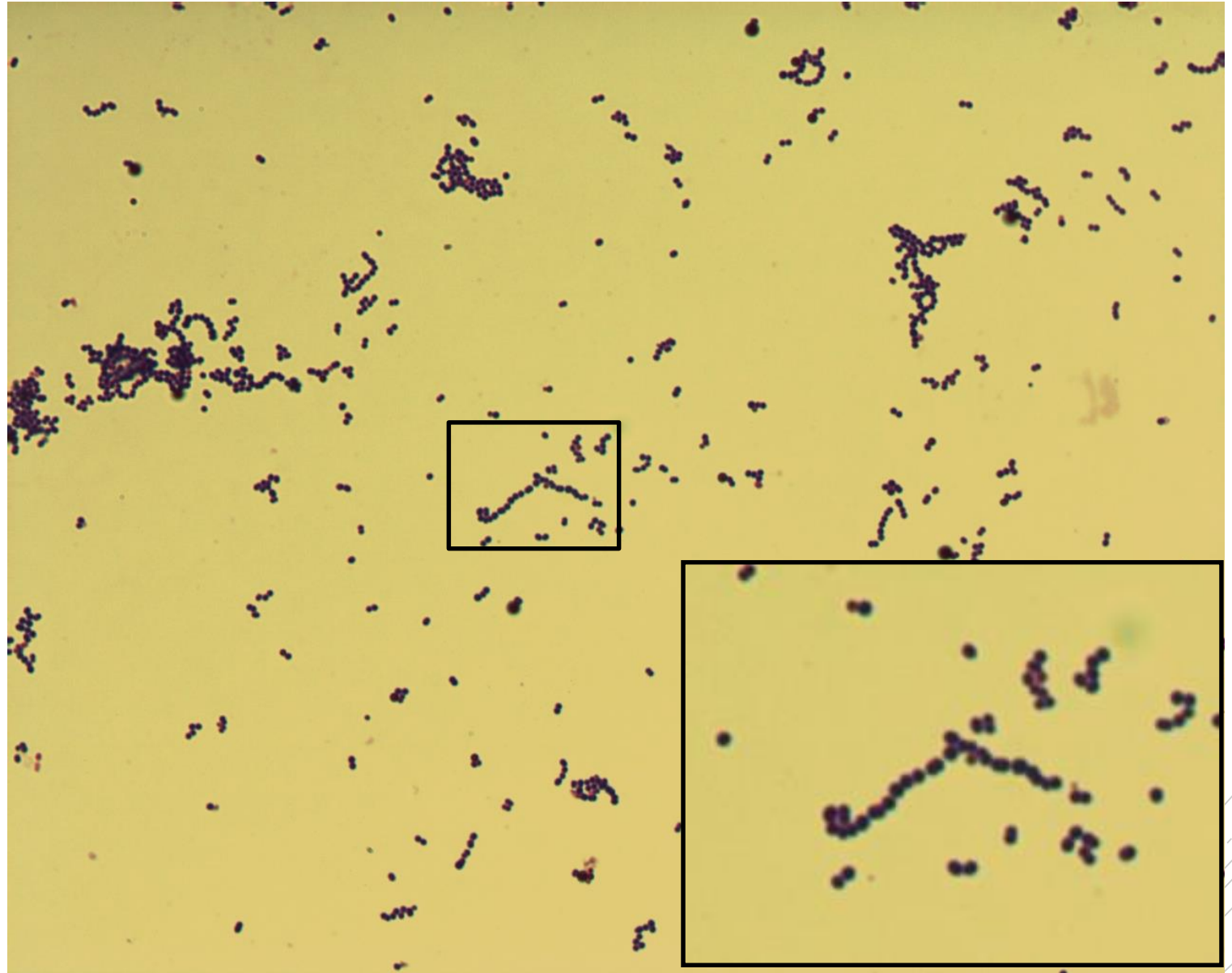
Streptococcus pyogenes

Specimen: culture – tissue biopsy

Patient: male, 40 years old

Dg.: necrotizing fasciitis

Microscopy: Gram-positive cocci
in chains



Authors: Markéta Šolarová, Hana Nekvasilová



CHARLES UNIVERSITY
Second Faculty of Medicine

Slide No. 20

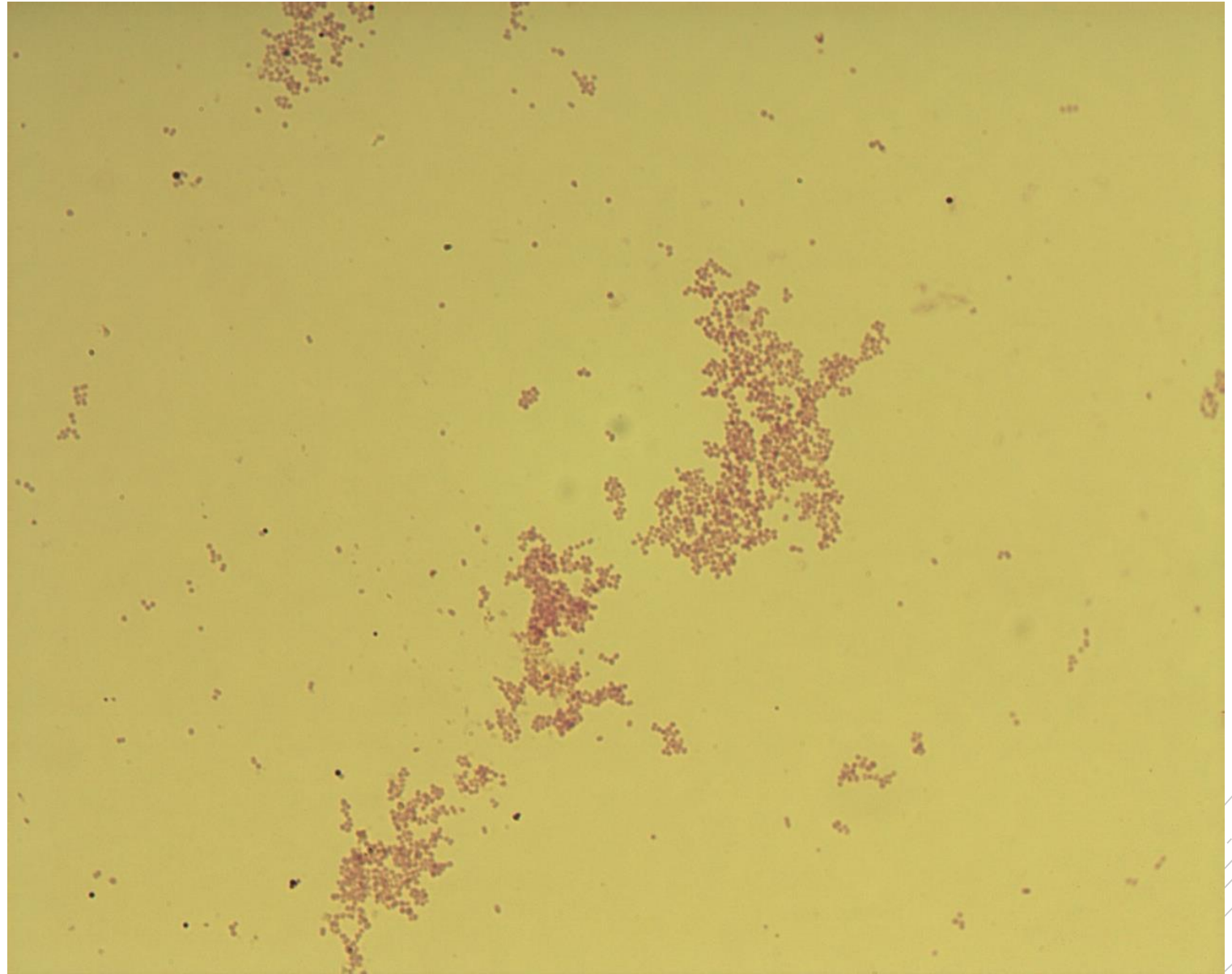
Branhamella catarrhalis

Specimen: culture – external ear swab

Patient: female, 7 years old

Dg.: acute otitis media

Microscopy: Gram-negative cocci
in couples, quartets and clusters



Authors: Markéta Šolarová, Hana Nekvasilová



CHARLES UNIVERSITY
Second Faculty of Medicine

Slide No. 20

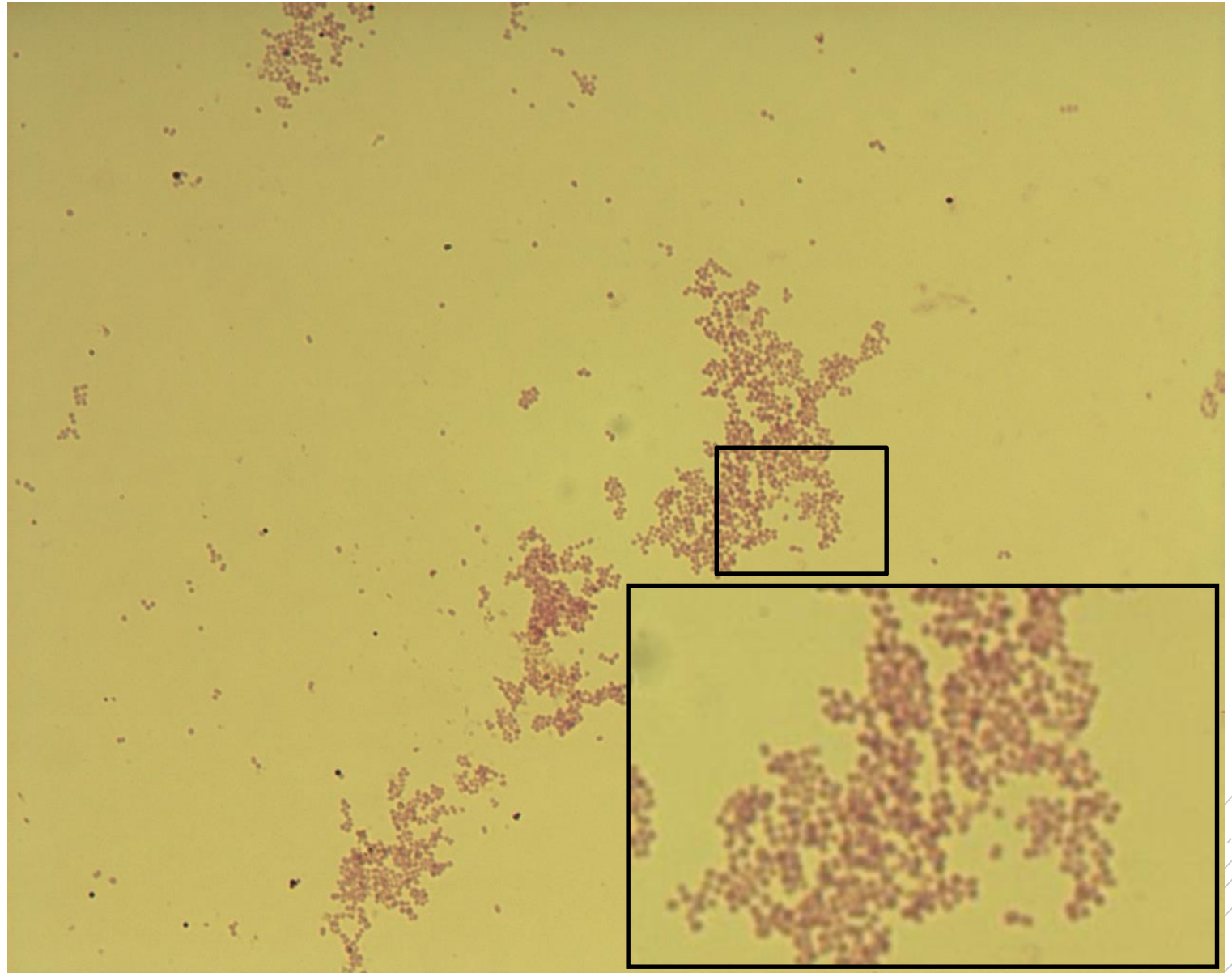
Branhamella catarrhalis

Specimen: culture – external ear swab

Patient: female, 7 years old

Dg.: acute otitis media

Microscopy: Gram-negative cocci
in couples, quartets and clusters



Authors: Markéta Šolarová, Hana Nekvasilová

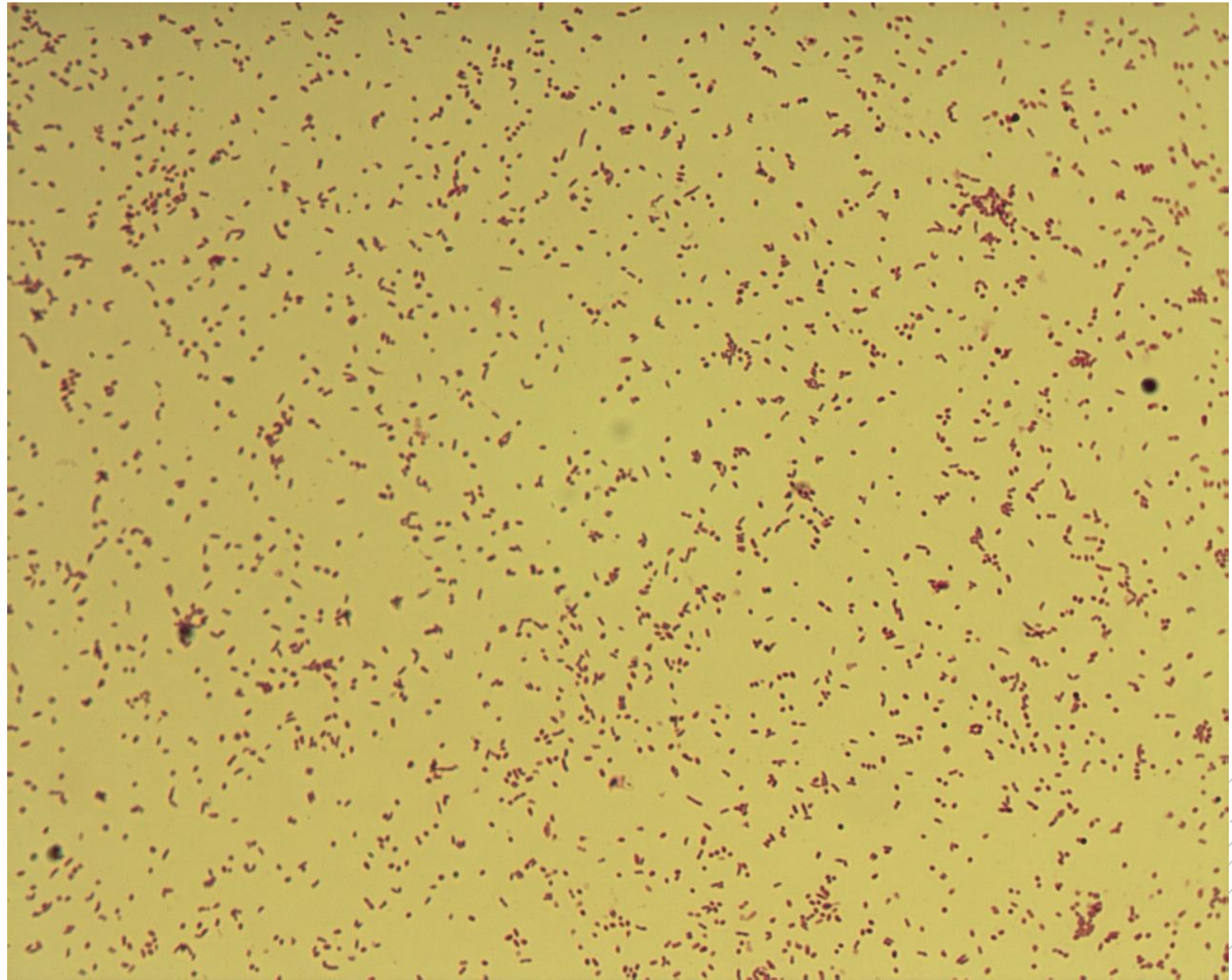


CHARLES UNIVERSITY
Second Faculty of Medicine

Slide No. 21

Haemophilus influenzae type b

Specimen: culture - CSF
Patient: male, 8 years old
Dg.: purulent meningitis
Microscopy: Gram-negative
coccobacilli



Authors: Markéta Šolarová, Hana Nekvasilová

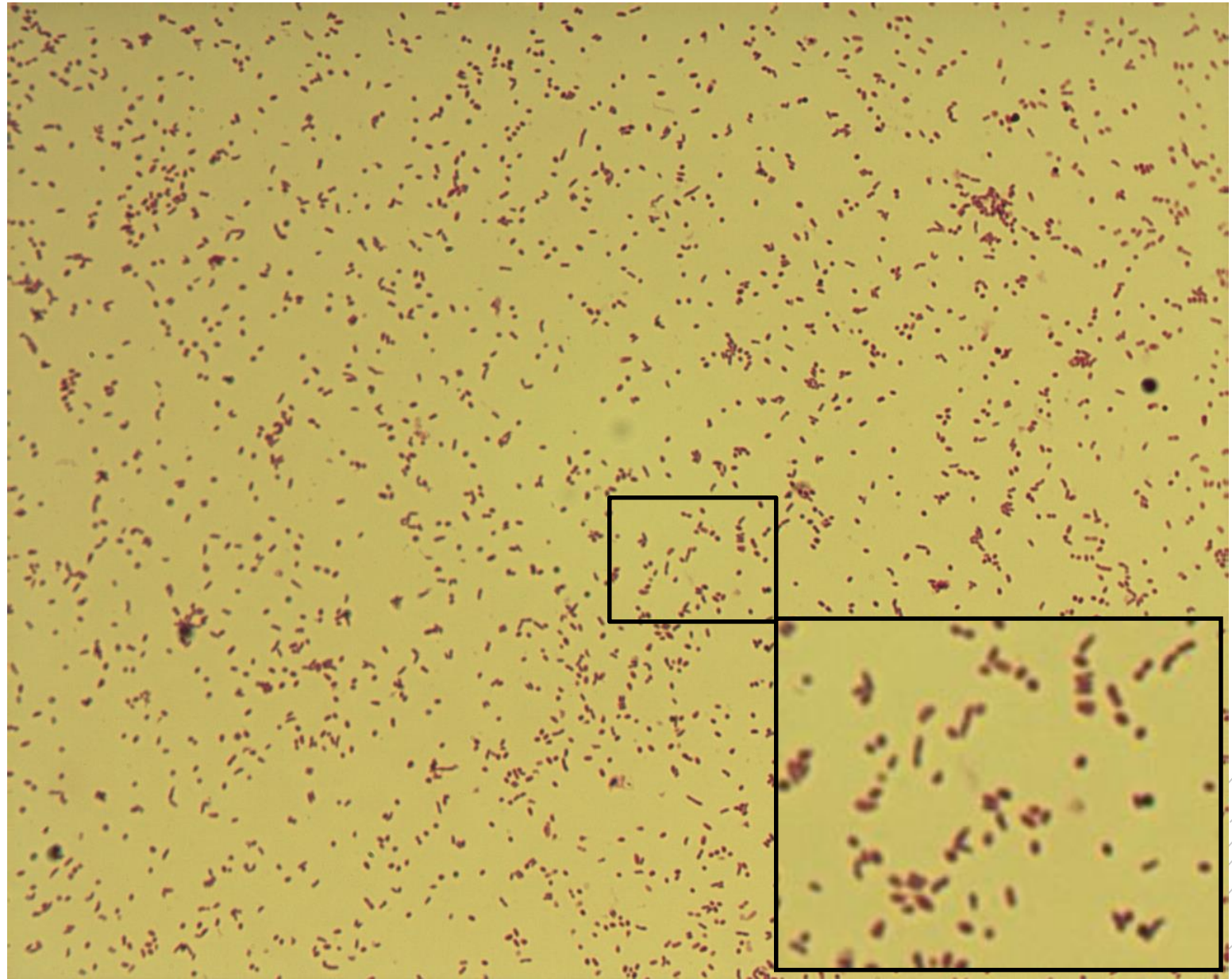


CHARLES UNIVERSITY
Second Faculty of Medicine

Slide No. 21

Haemophilus influenzae type b

Specimen: culture - CSF
Patient: male, 8 years old
Dg.: purulent meningitis
Microscopy: Gram-negative
coccobacilli



Authors: Markéta Šolarová, Hana Nekvasilová



CHARLES UNIVERSITY
Second Faculty of Medicine

Slide No. 22

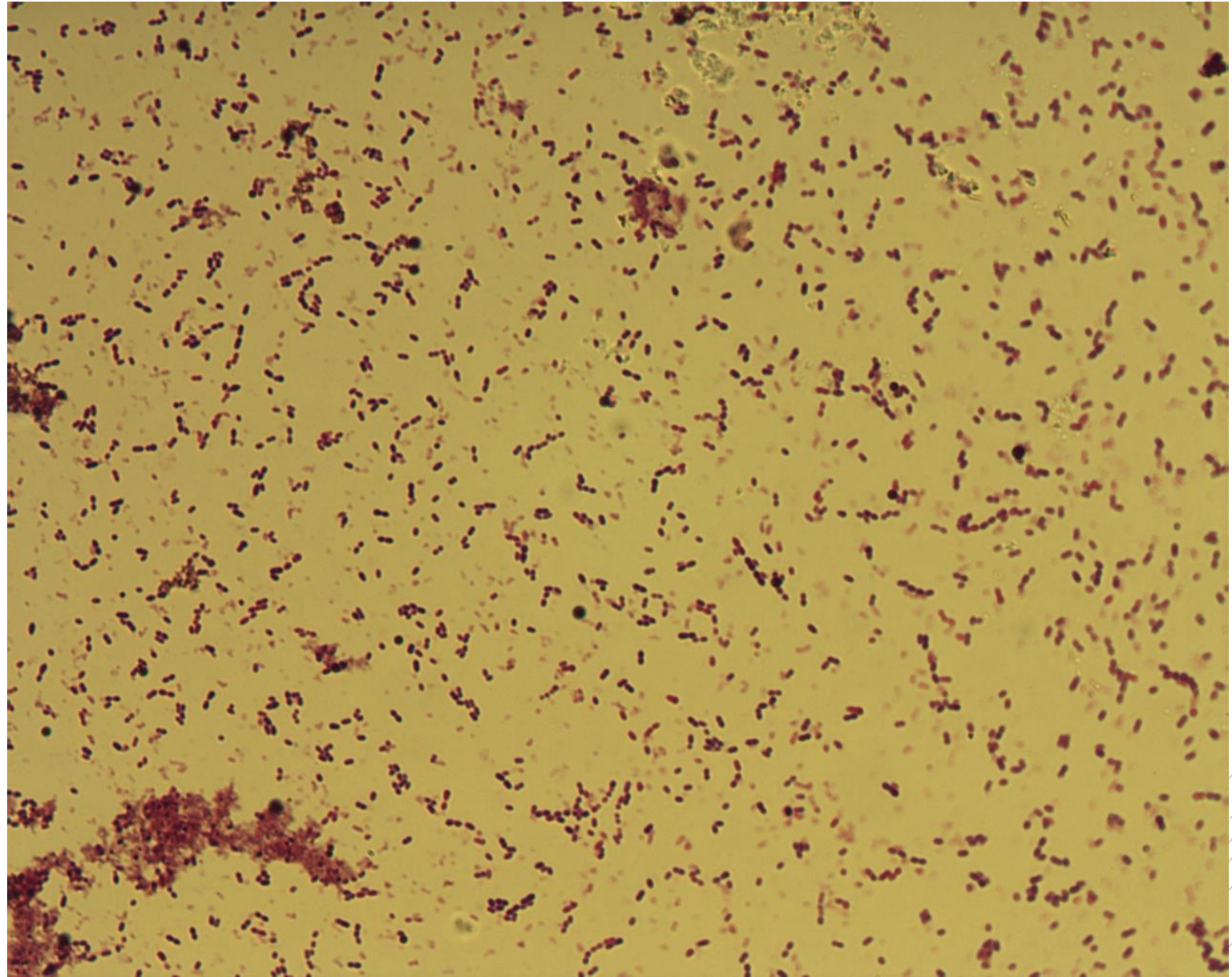
Streptococcus pneumoniae

Specimen: sputum

Patient: female, 75 years old

Dg.: community pneumonia

Microscopy: Gram-positive diplococci



Authors: Markéta Šolarová, Hana Nekvasilová



CHARLES UNIVERSITY
Second Faculty of Medicine

Slide No. 22

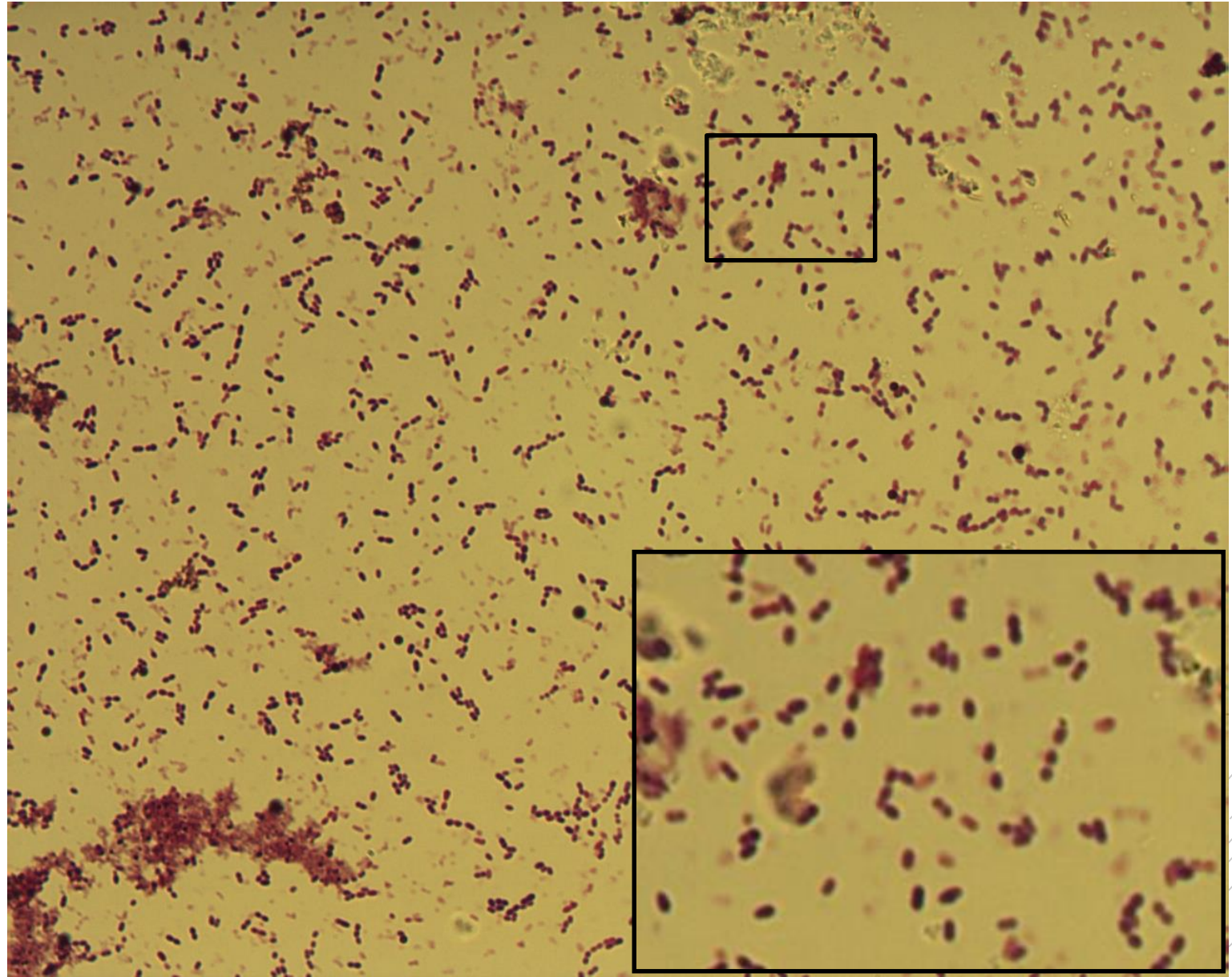
Streptococcus pneumoniae

Specimen: sputum

Patient: female 75 years old

Dg.: community pneumonia

Microscopy: Gram-positive diplococci



Authors: Markéta Šolarová, Hana Nekvasilová



CHARLES UNIVERSITY
Second Faculty of Medicine

Slide No. 23

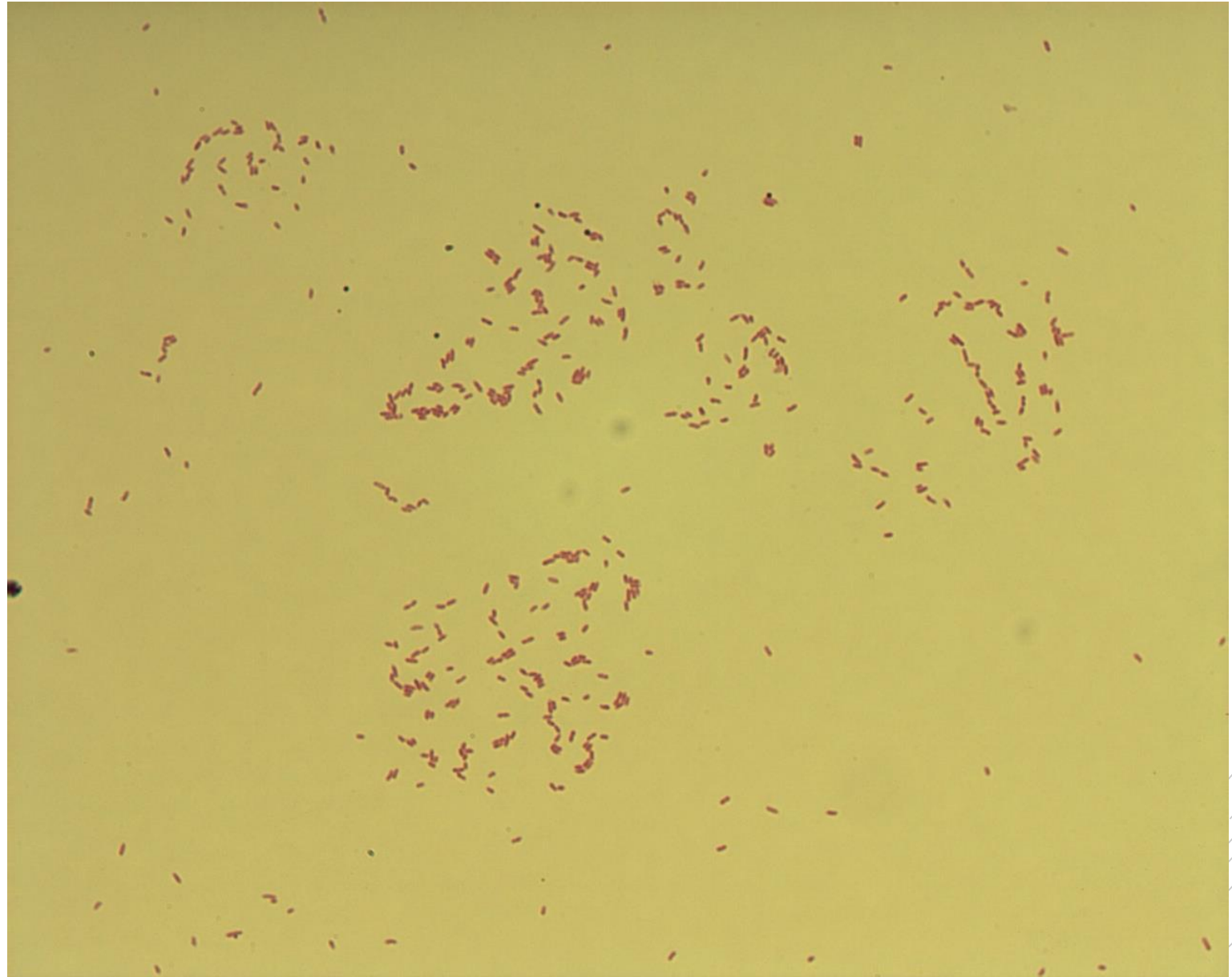
Pseudomonas aeruginosa

Specimen: culture – tissue

Patient: female, 2 years old

Dg.: ecthyma gangrenosum

Microscopy: thin Gram-negative rods



Authors: Markéta Šolarová, Hana Nekvasilová



CHARLES UNIVERSITY
Second Faculty of Medicine

Slide No. 23

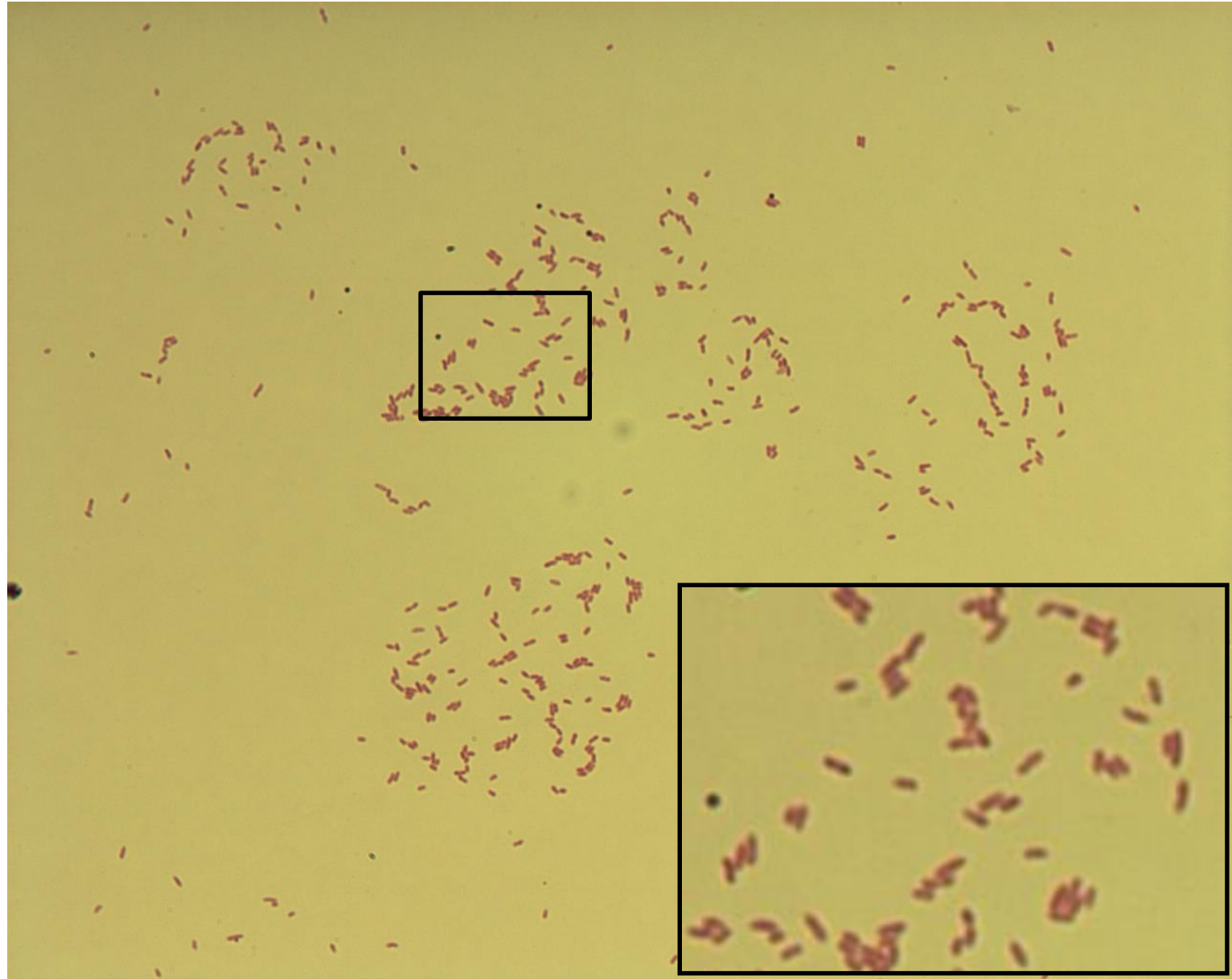
Pseudomonas aeruginosa

Specimen: culture - tissue

Patient: female, 2 years old

Dg.: ecthyma gangrenosum

Microscopy: thin Gram-negative rods



Authors: Markéta Šolarová, Hana Nekvasilová



CHARLES UNIVERSITY
Second Faculty of Medicine

Slide No. 24

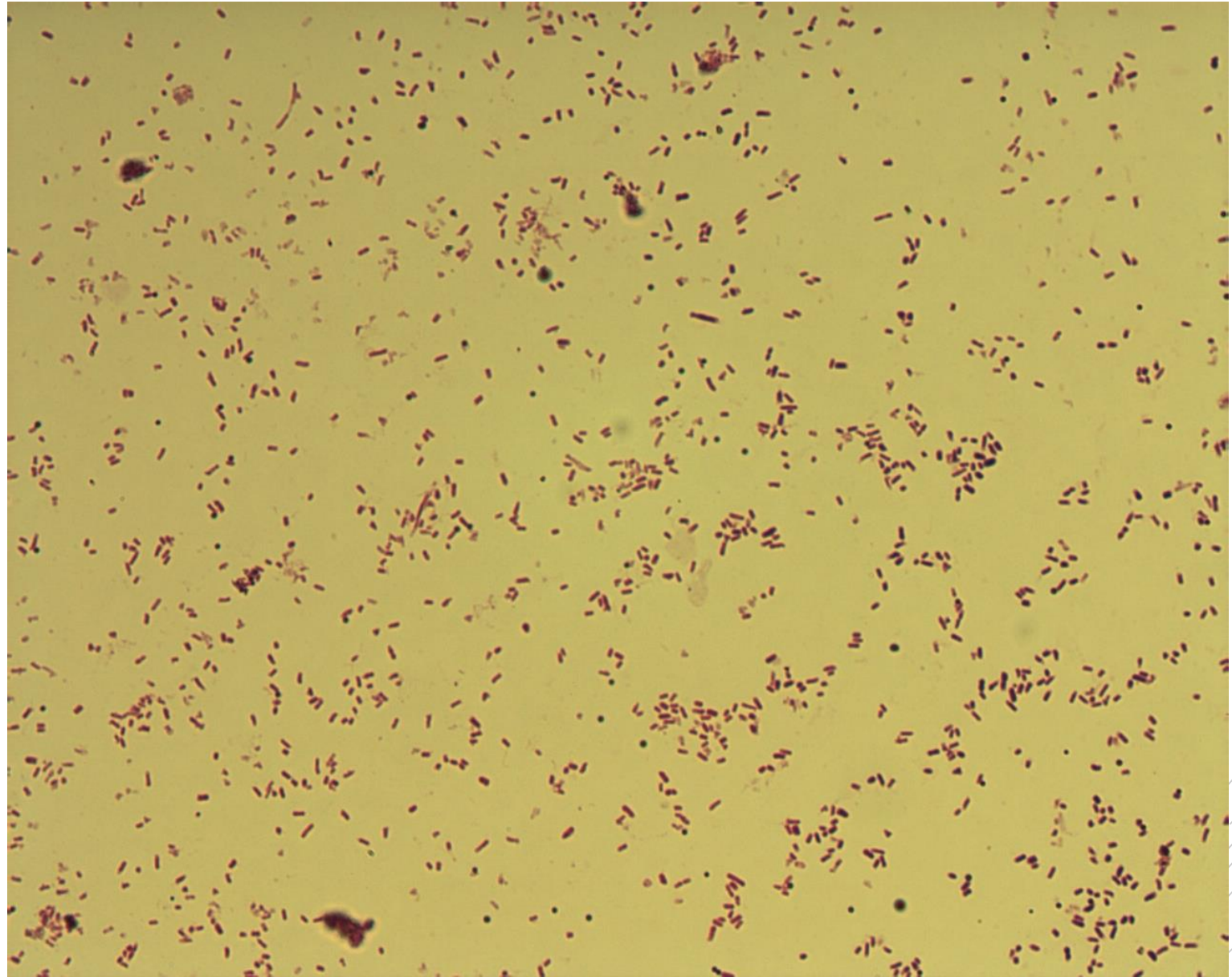
Escherichia coli

Specimen: culture - urine

Patient: female, 55 years old

Dg.: urinary tract infection

Microscopy: Gram-negative rods



Authors: Markéta Šolarová, Hana Nekvasilová



CHARLES UNIVERSITY
Second Faculty of Medicine

Slide No. 24


Escherichia coli

Specimen: culture - urine

Patient: female, 55 years old

Dg.: urinary tract infection

Microscopy: Gram-negative rods



Authors: Markéta Šolarová, Hana Nekvasilová



CHARLES UNIVERSITY
Second Faculty of Medicine

Slide No. 25

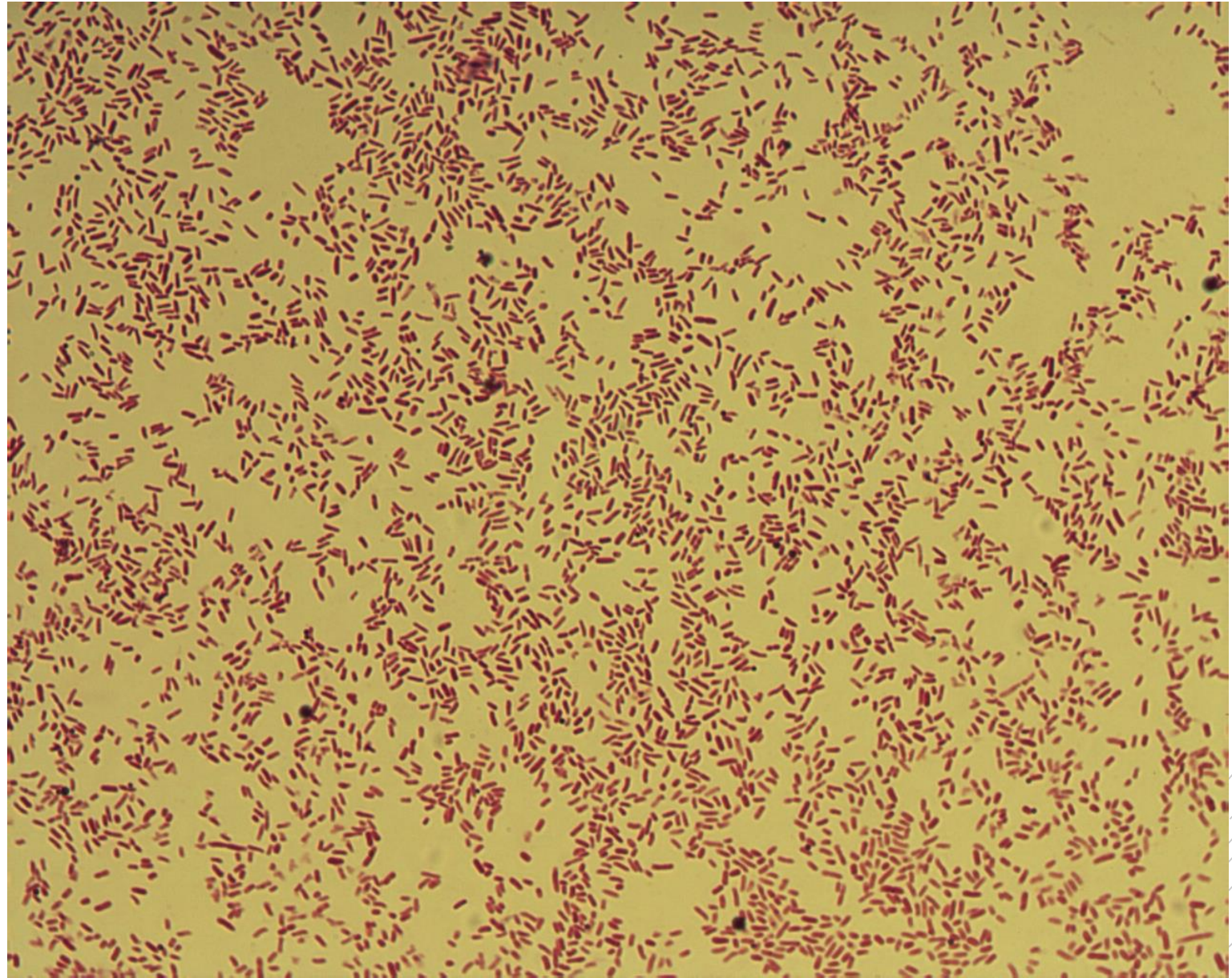
Salmonella Enteritidis

Specimen: culture - stools

Patient: male, 22 years old

Dg.: gastroenteritis

Microscopy: Gram-negative rods



Authors: Markéta Šolarová, Hana Nekvasilová



CHARLES UNIVERSITY
Second Faculty of Medicine

Slide No. 25

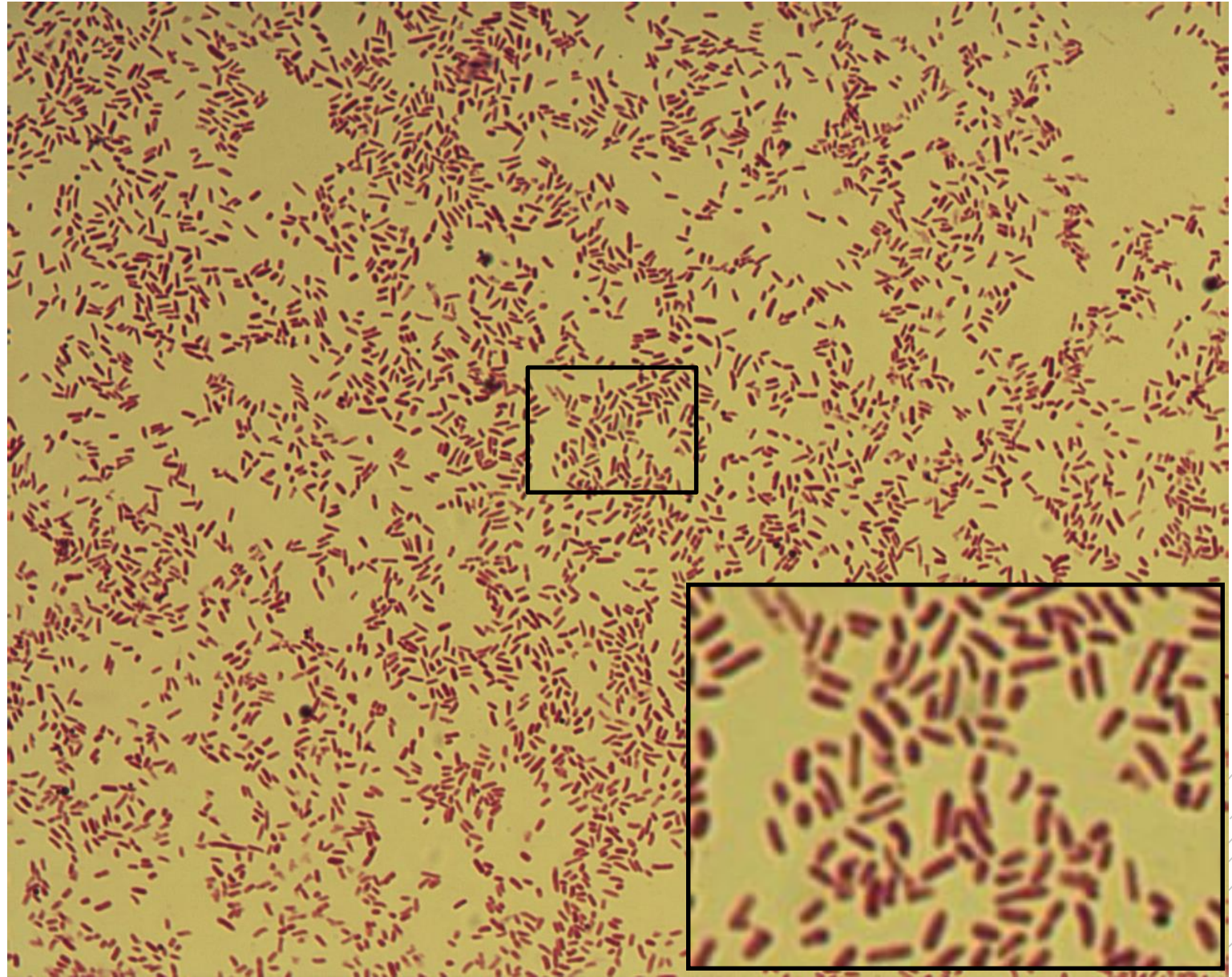
Salmonella Enteritidis

Specimen: culture - stools

Patient: male, 22 years old

Dg.: gastroenteritis

Microscopy: Gram-negative rods



Authors: Markéta Šolarová, Hana Nekvasilová



CHARLES UNIVERSITY
Second Faculty of Medicine

Slide No. 26

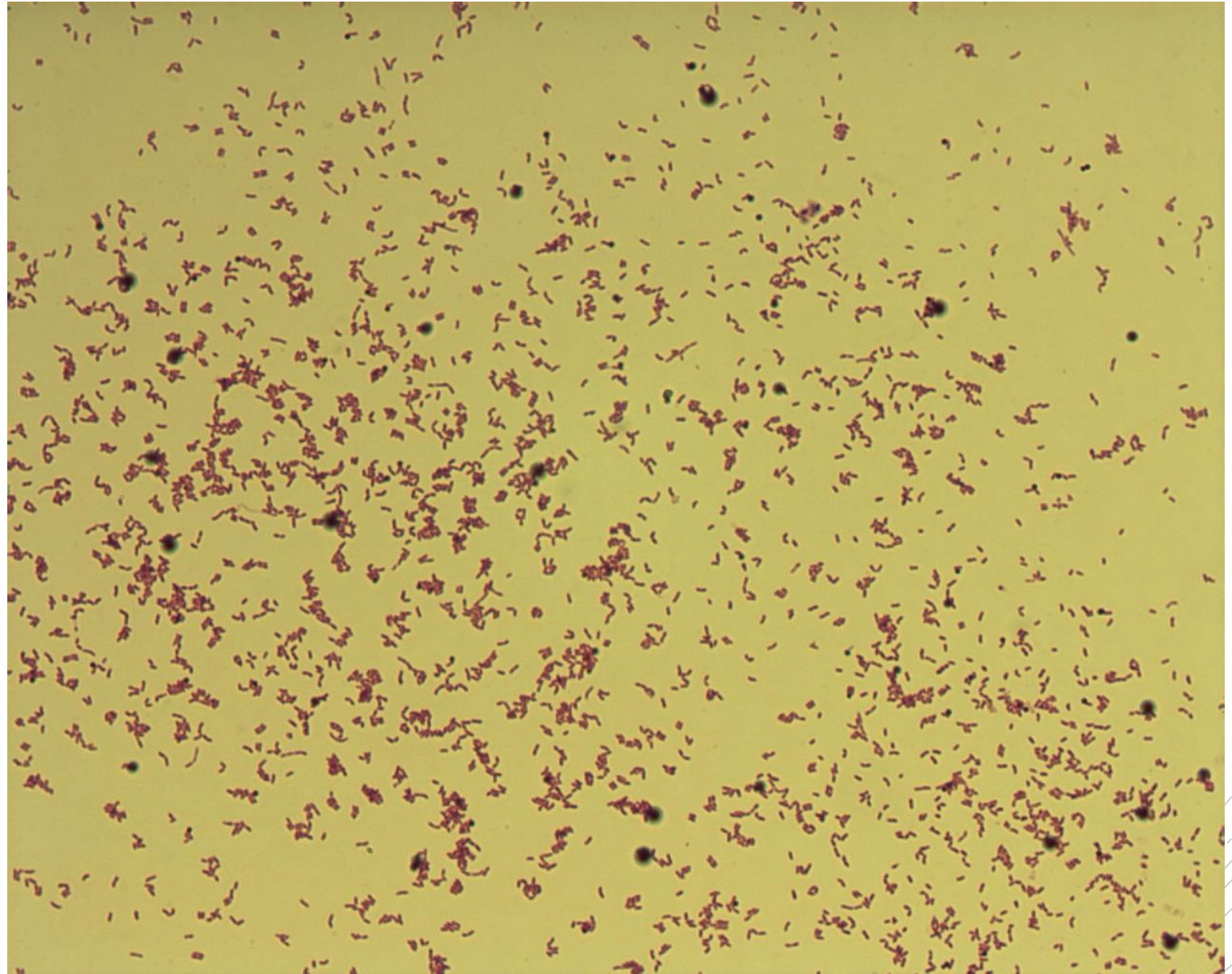
Arcanobacterium haemolyticum

Specimen: culture – throat swab

Patient: female 17 years old

Dg.: tonsillitis

Microscopy: Gram-positive rods



Authors: Markéta Šolarová, Hana Nekvasilová



CHARLES UNIVERSITY
Second Faculty of Medicine

Slide No. 26

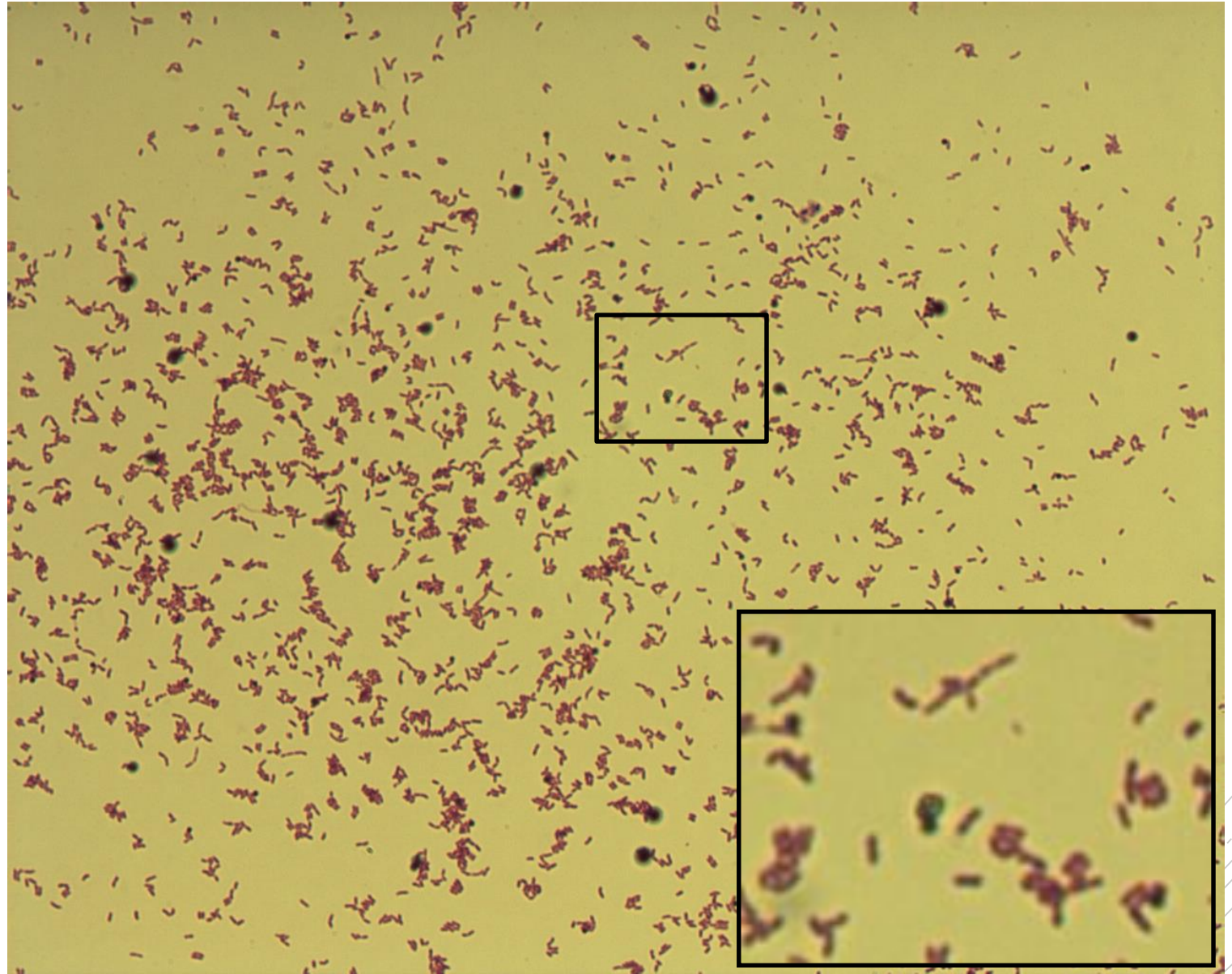
Arcanobacterium haemolyticum

Specimen: culture – throat swab

Patient: female, 17 years old

Dg.: tonsillitis

Microscopy: Gram-positive rods



Authors: Markéta Šolarová, Hana Nekvasilová



CHARLES UNIVERSITY
Second Faculty of Medicine

Slide No. 27

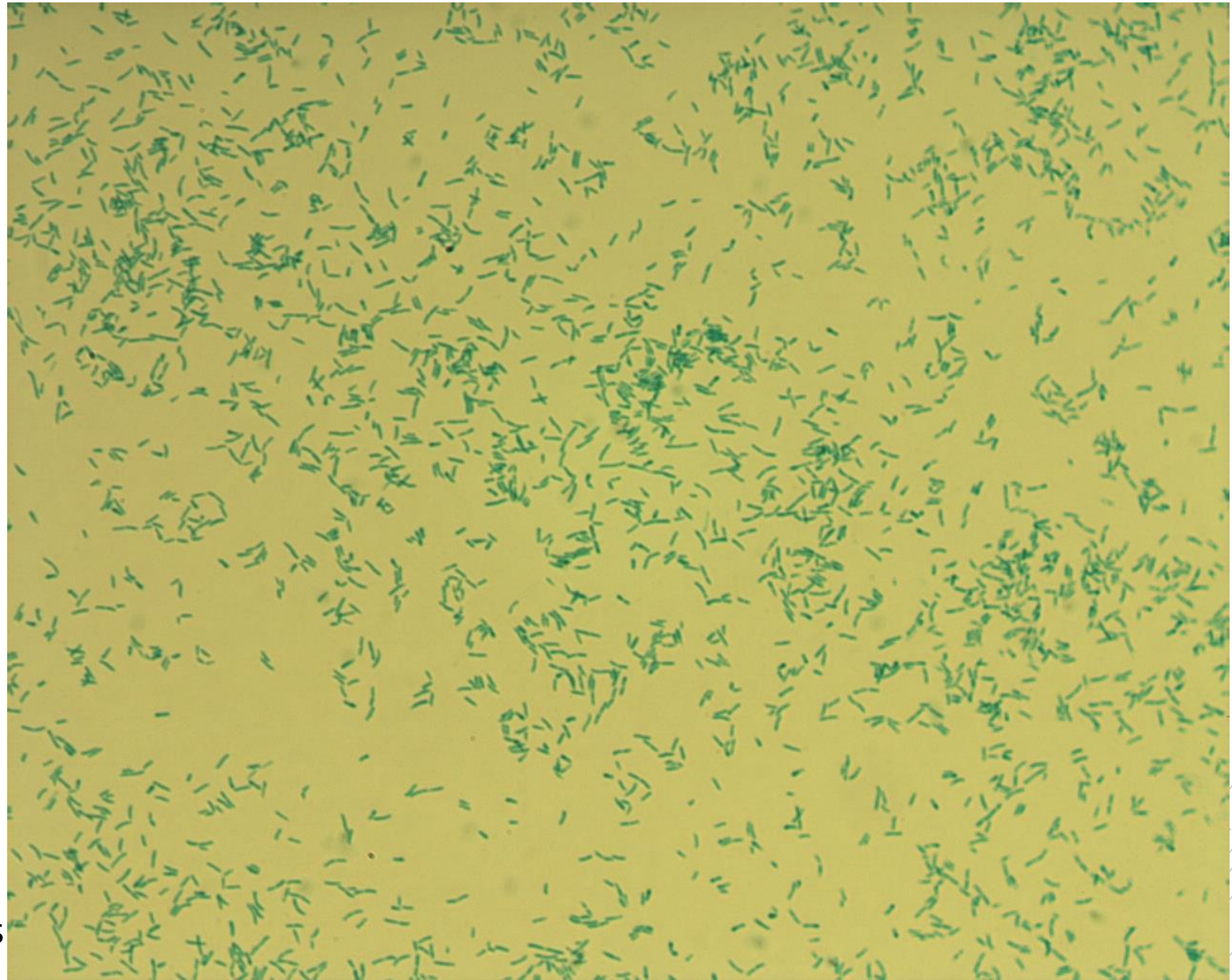
Corynebacterium diphtheriae

Specimen: culture – throat swab

Patient: male, 2 years old

Dg.: tonsilopharyngitis

Microscopy: Albert stain, club-like rods
with metachromatic granules



Authors: Markéta Šolarová, Hana Nekvasilová



CHARLES UNIVERSITY
Second Faculty of Medicine

Slide No. 27


Corynebacterium diphtheriae

Specimen: culture – throat swab

Patient: male, 2 years old

Dg.: tonsilopharyngitis

Microscopy: Albert stain, club-like rods
with metachromatic granules



Authors: Markéta Šolarová, Hana Nekvasilová



CHARLES UNIVERSITY
Second Faculty of Medicine

Slide No. 28

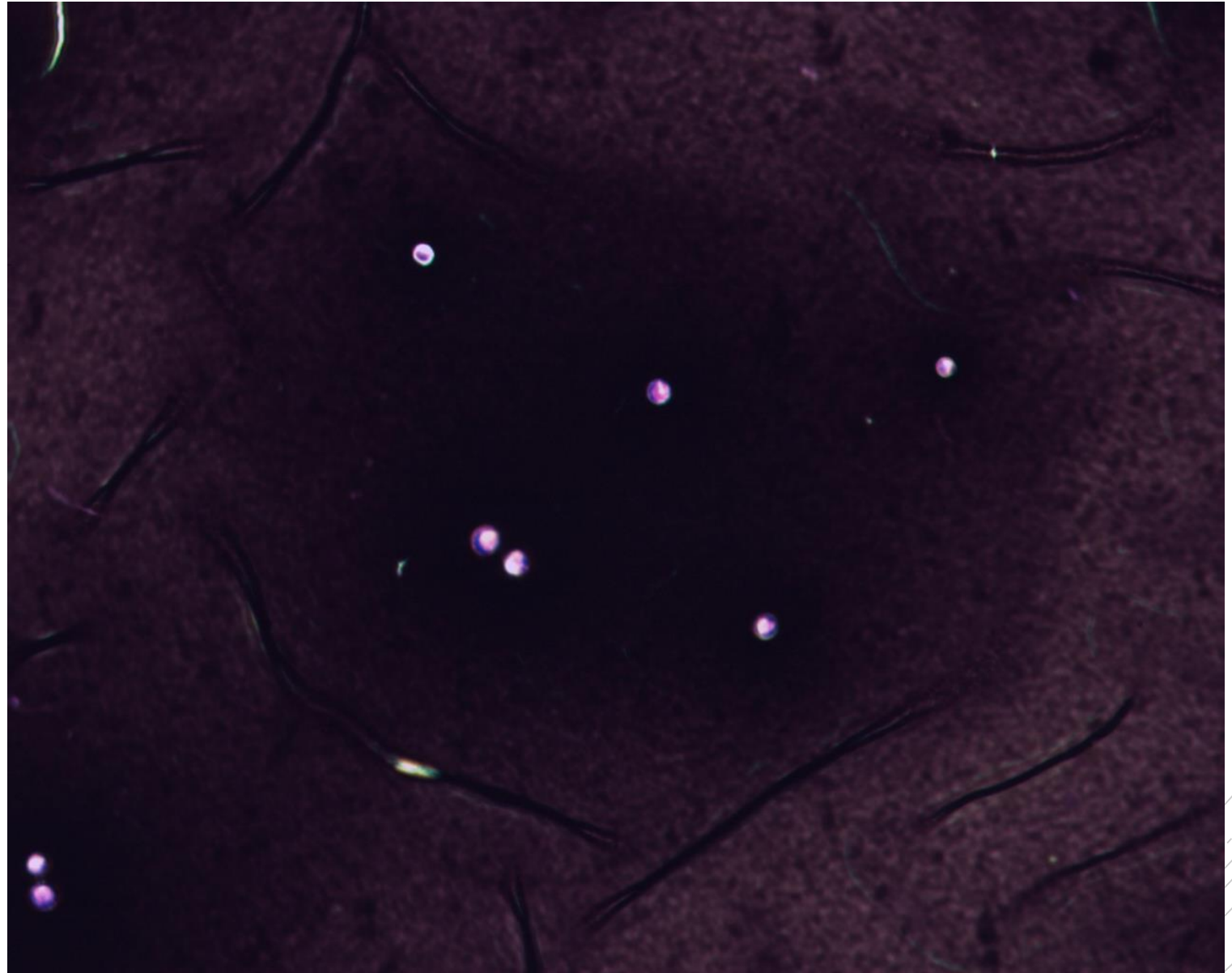
Cryptococcus neoformans

Specimen: sputum

Patient: male, 34 years old

Dg.: pneumonia

Microscopy: capsules in Burri stain



Authors: Markéta Šolarová, Hana Nekvasilová



CHARLES UNIVERSITY
Second Faculty of Medicine

Slide No. 28

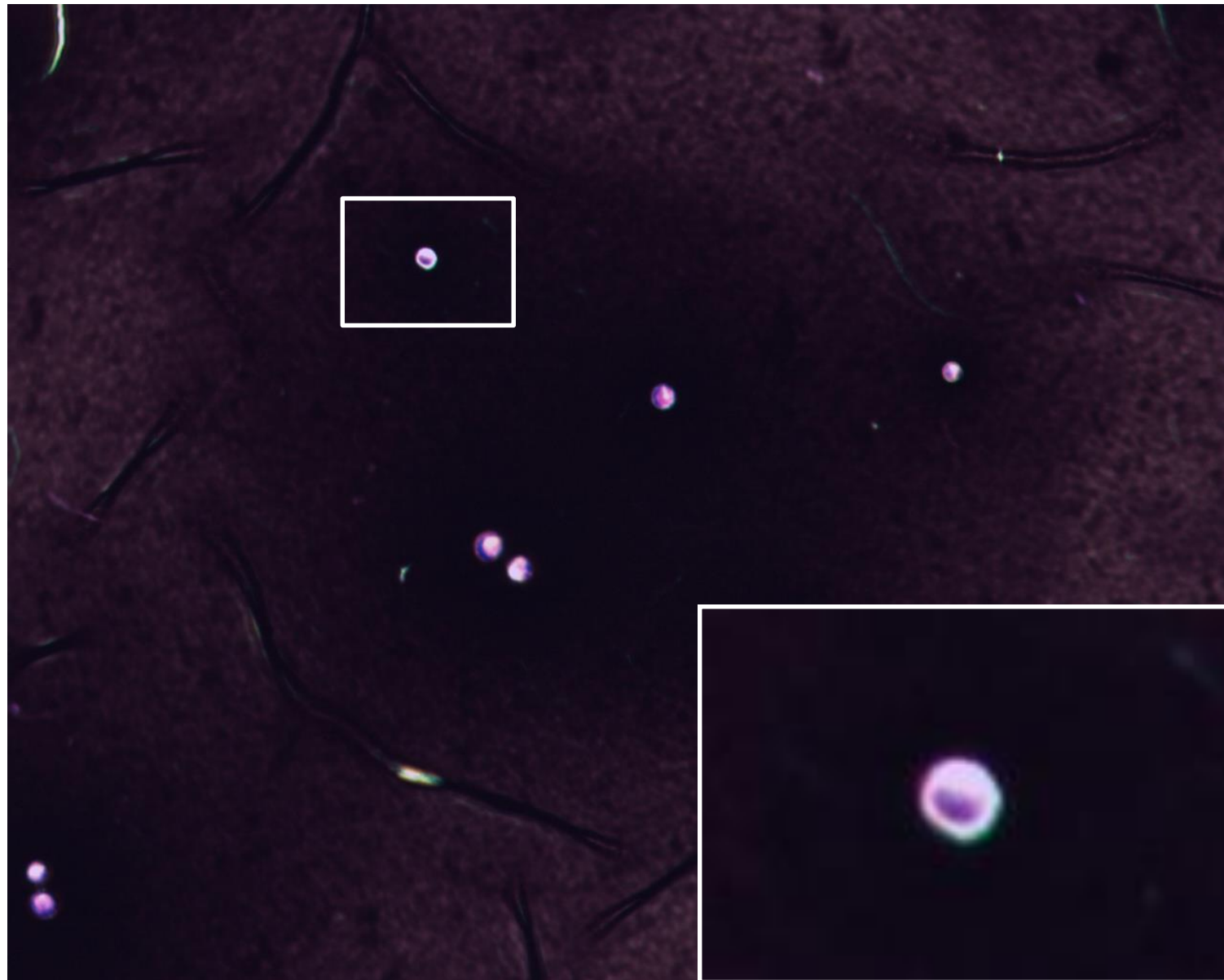
Cryptococcus neoformans

Specimen: sputum

Patient: male, 34 years old

Dg.: pneumonia

Microscopy: capsules in Burri stain



Authors: Markéta Šolarová, Hana Nekvasilová



CHARLES UNIVERSITY
Second Faculty of Medicine

Slide No. 29

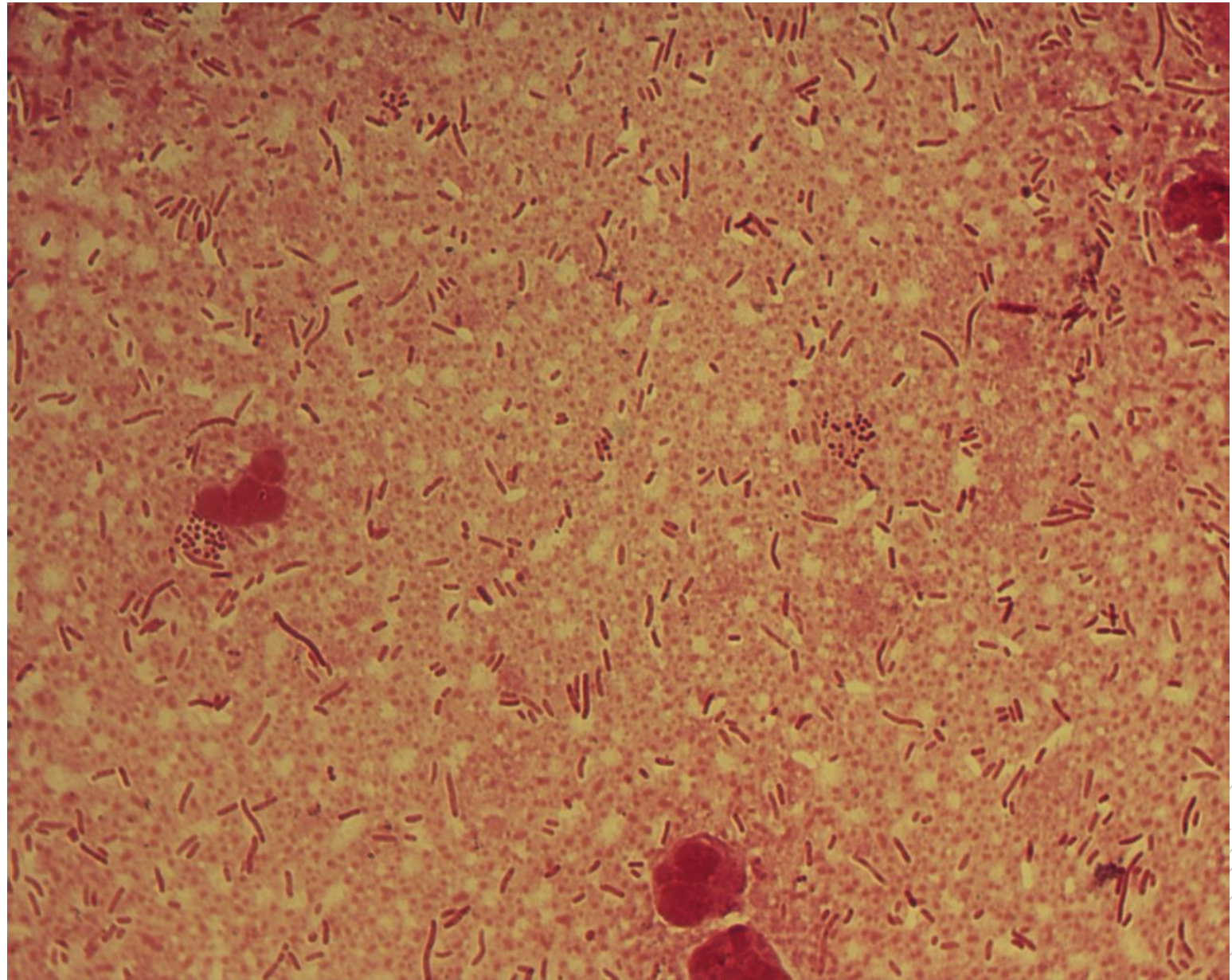
*Klebsiella
pneumoniae,
Enterococcus
faecium*

Specimen: pus

Patient: male, 80let

Dg.: gallbladder tumor

Microscopy: Gram-negative rods and
Gram-positive cocci



Author: MUDr. Alena Pířová



CHARLES UNIVERSITY
Second Faculty of Medicine

Slide No. 29

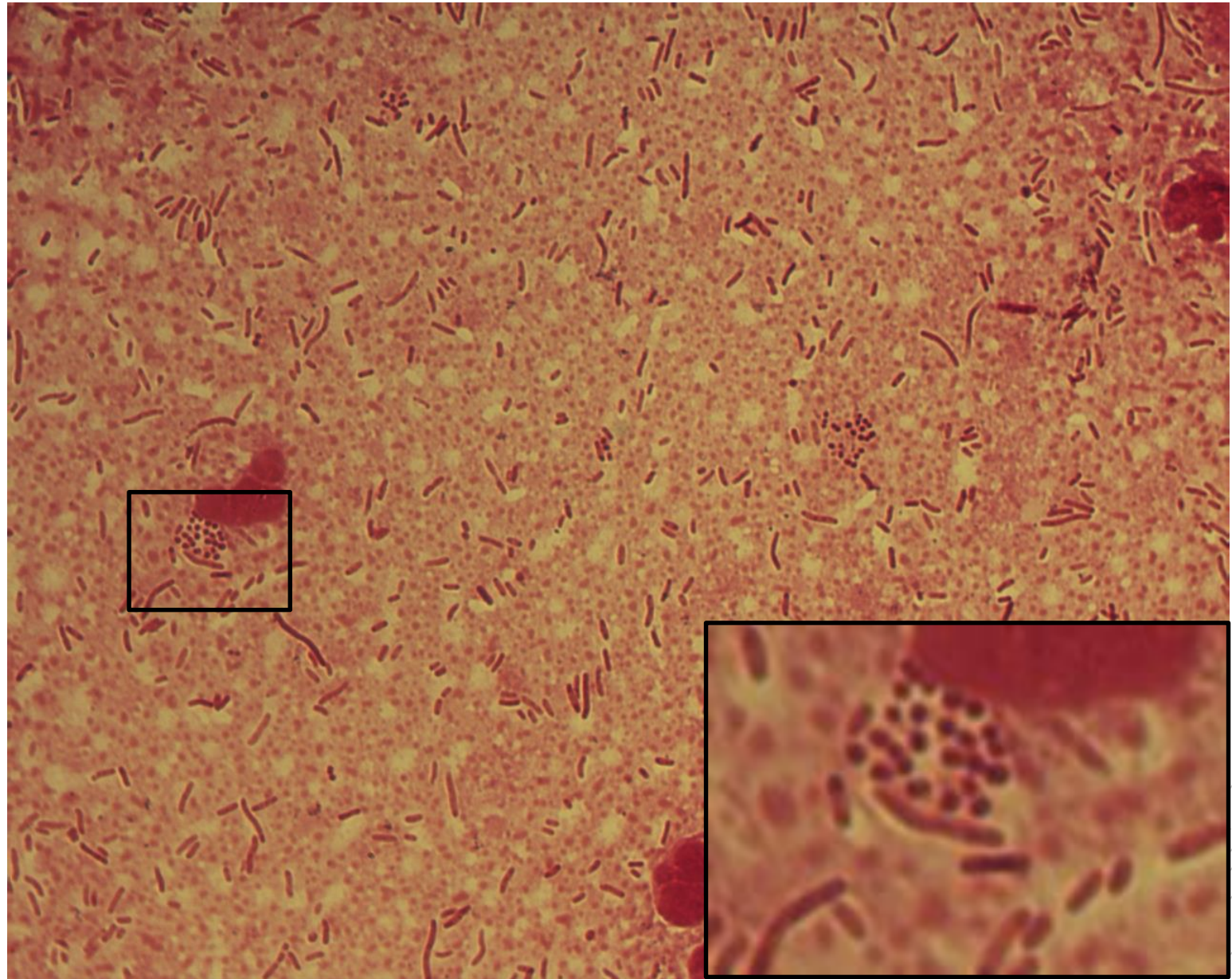
*Klebsiella
pneumoniae,
Enterococcus
faecium*

Specimen: pus

Patient: male, 80let

Dg.: gallbladder tumor

Microscopy: Gram-negative rods and
Gram-positive cocci



Author: MUDr. Alena Píšová



CHARLES UNIVERSITY
Second Faculty of Medicine

Slide No. 30


Salmonella Enteritidis

Specimen: blood culture

Patient: female, 68 years old

Dg.: bloodstream infection

Microscopy: Gram-negative rods



Authors: MUDr. Petra Kabelíková, Sandra Opálková



CHARLES UNIVERSITY
Second Faculty of Medicine

Slide No. 30


Salmonella Enteritidis

Specimen: blood culture

Patient: female, 68 years old

Dg.: bloodstream infection

Microscopy: Gram-negative rods



Authors: MUDr. Petra Kabelíková, Sandra Opálková



CHARLES UNIVERSITY
Second Faculty of Medicine

Slide No. 31

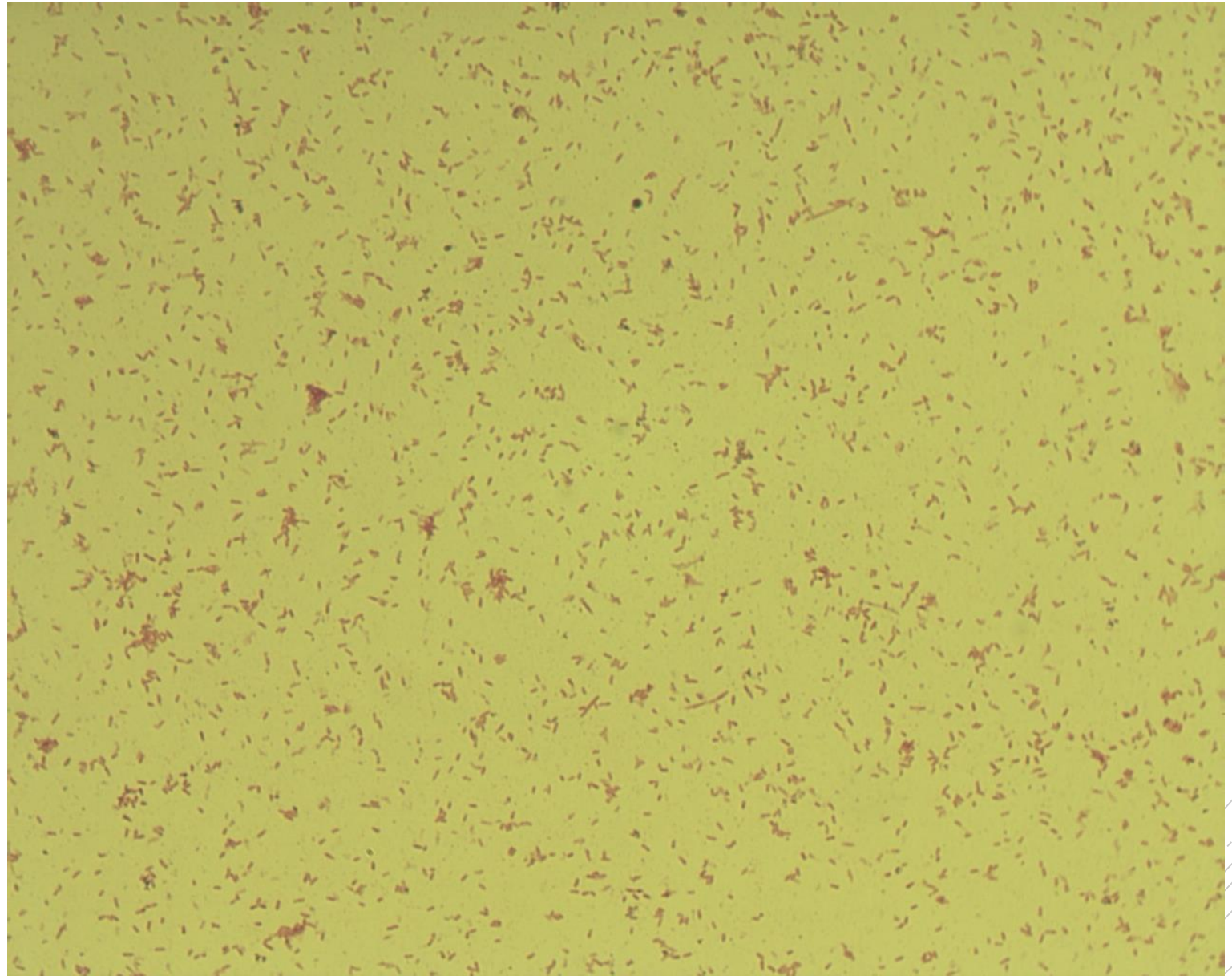
Bordetella pertussis

Specimen: throat swab

Patient: male, 11 years old

Dg.: pharyngitis

Microscopy: Gram-negative
coccobacilli



Authors: Markéta Šolarová, Hana Nekvasilová



CHARLES UNIVERSITY
Second Faculty of Medicine

Slide No. 31


Bordetella pertussis

Specimen: throat swab

Patient: male, 11 years old

Dg.: pharyngitis

Microscopy: Gram-negative
coccobacilli



Authors: Markéta Šolarová, Hana Nekvasilová



CHARLES UNIVERSITY
Second Faculty of Medicine

Slide No. 32

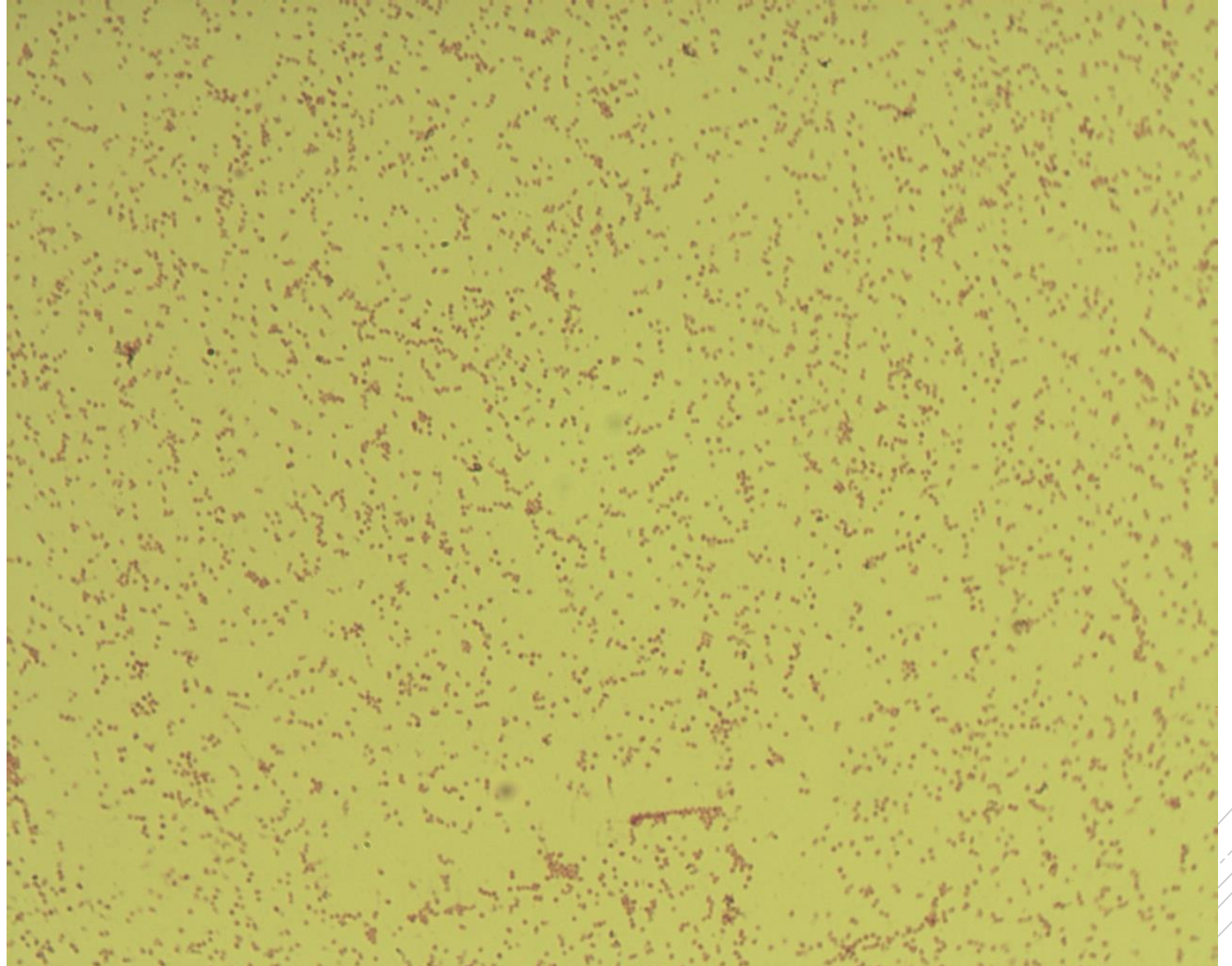
Bordetella parapertussis

Specimen: throat swab

Patient: female, 10 years old

Dg.: pharyngitis

Microscopy: Gram-negative
coccobacilli



Authors: Markéta Šolarová, Hana Nekvasilová



CHARLES UNIVERSITY
Second Faculty of Medicine

Slide No. 32


Bordetella parapertussis

Specimen: throat swab

Patient: female, 10 years old

Dg.: pharyngitis

Microscopy: Gram-negative cocco-rods



Authors: Markéta Šolarová, Hana Nekvasilová



CHARLES UNIVERSITY
Second Faculty of Medicine

Slide No. 33

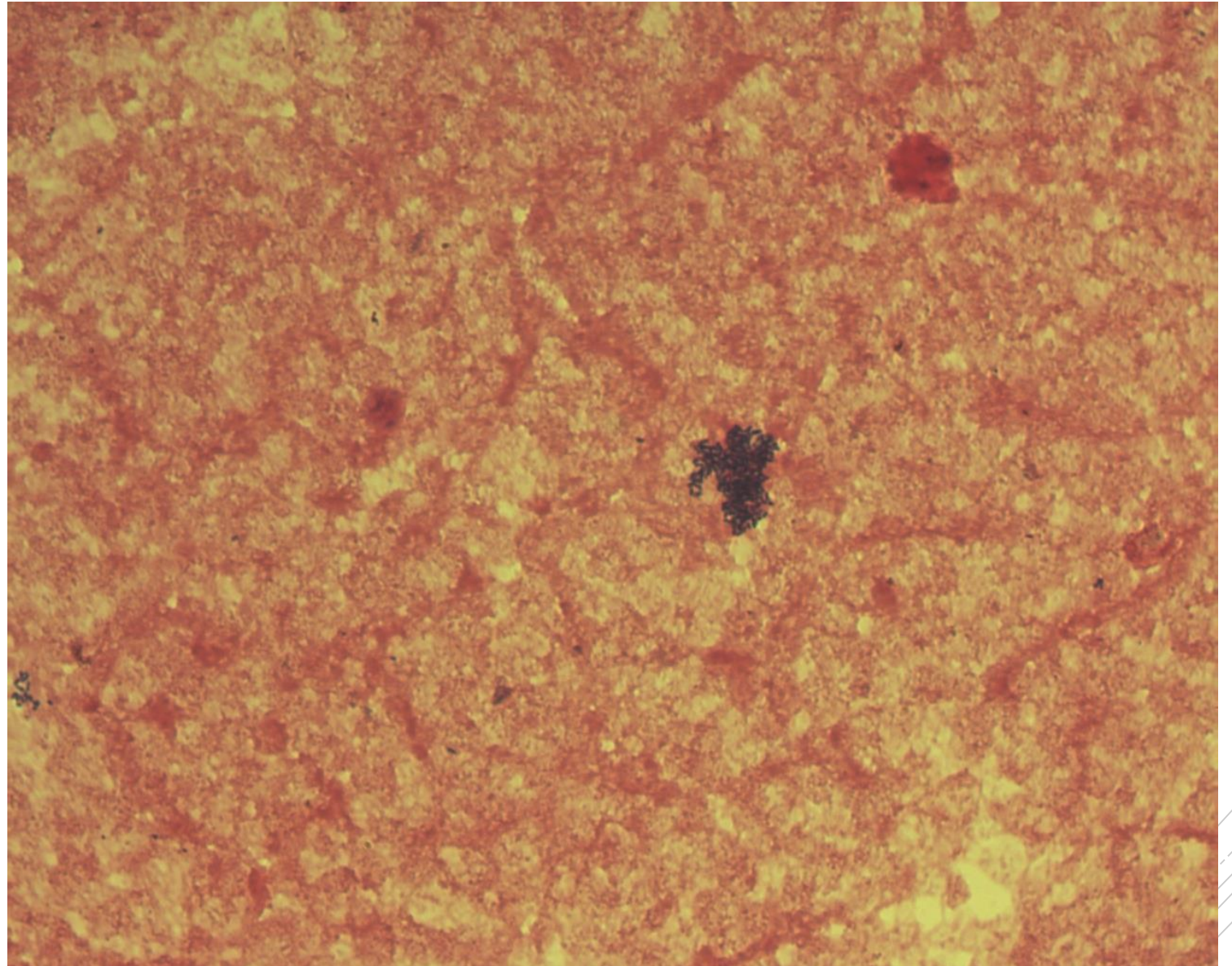
Listeria monocytogenes

Specimen: blood culture

Patient: male, 71 years old

Dg.: sepsis

Microscopy: Gram-positive rods



Authors: MUDr. Petra Kabelíková, Sandra Opálková



CHARLES UNIVERSITY
Second Faculty of Medicine

Slide No. 33

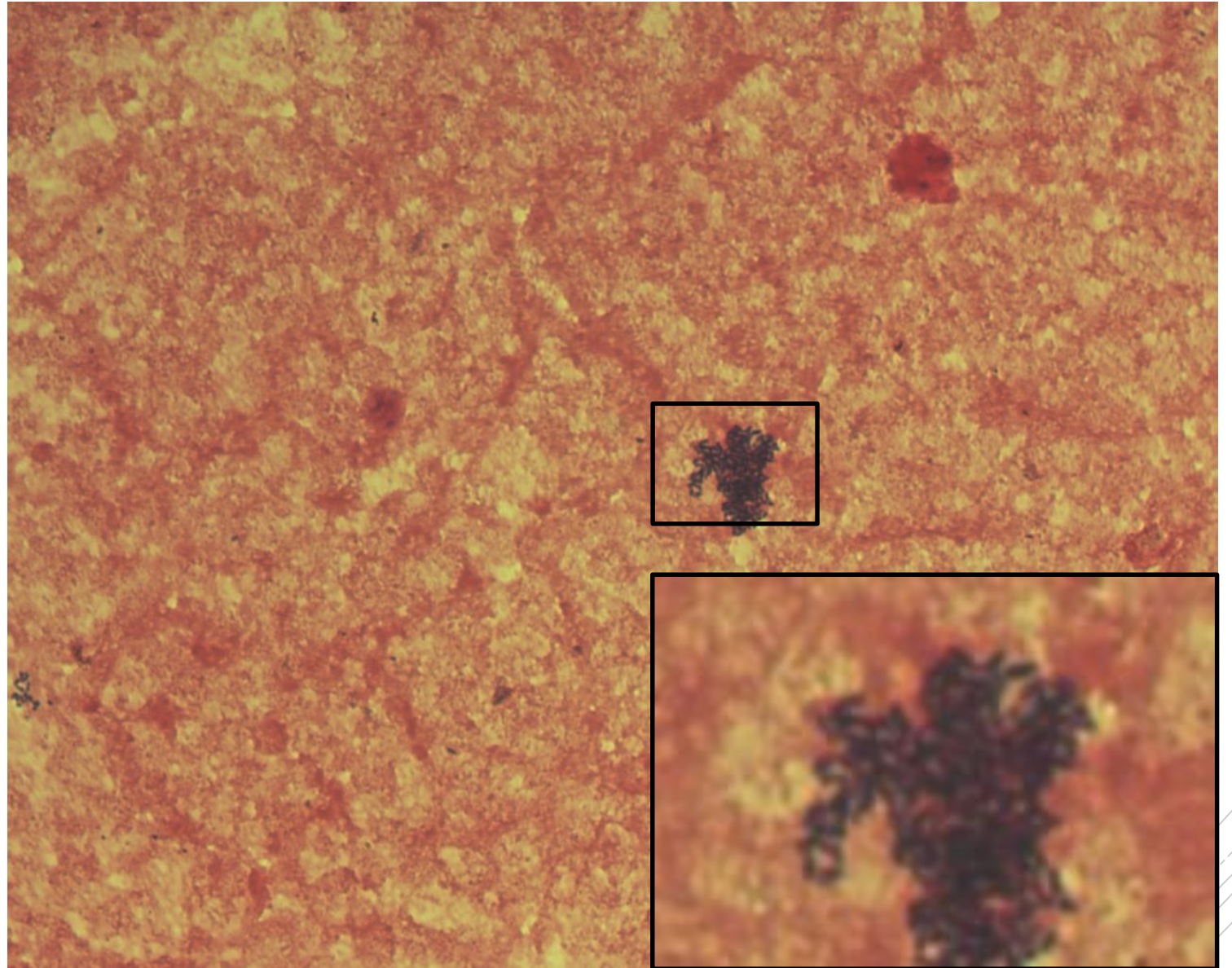
Listeria monocytogenes

Specimen: blood culture

Patient: male, 71 years old

Dg.: sepsis

Microscopy: Gram-positive rods



Authors: MUDr. Petra Kabelíková, Sandra Opálková



CHARLES UNIVERSITY
Second Faculty of Medicine

Slide No. 34

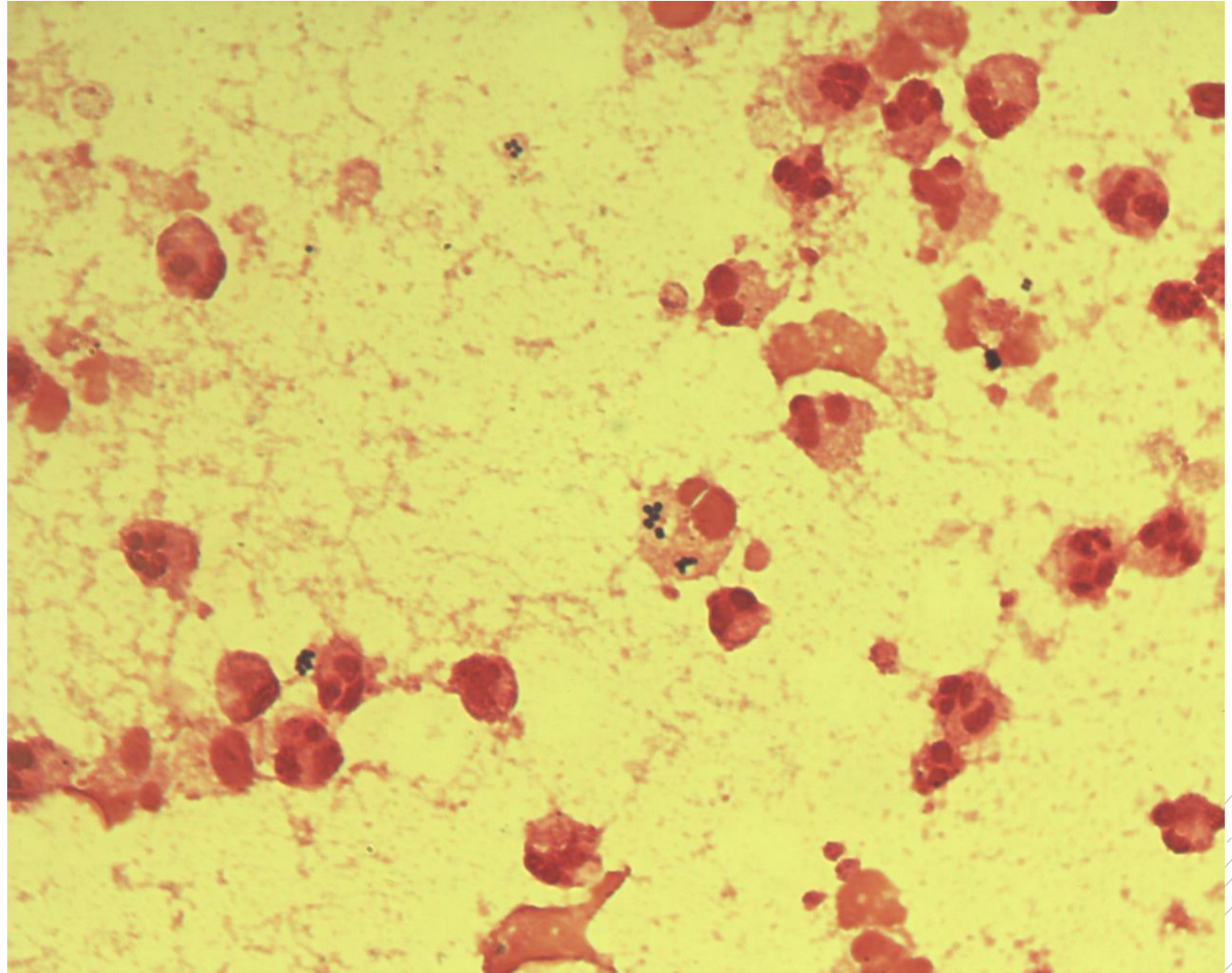
Staphylococcus aureus

Specimen: joint fluid

Patient: male, 30 years old

Dg.: infectious arthritis

Microscopy: Gram-positive cocci
in clusters



Author: doc. MVDr. Oto Melter, PhD.



CHARLES UNIVERSITY
Second Faculty of Medicine

Slide No. 34

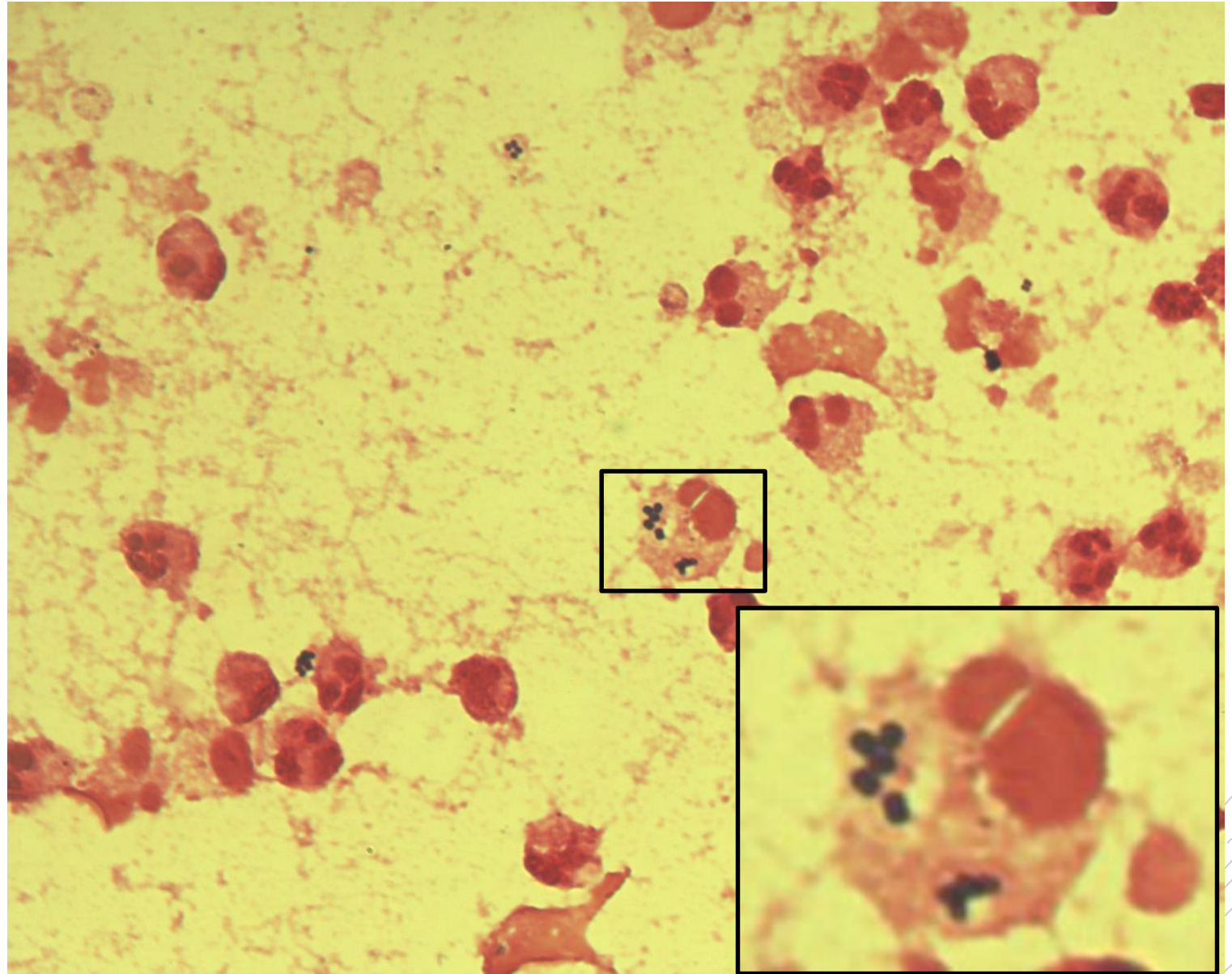
Staphylococcus aureus

Specimen: joint fluid

Patient: male, 30 years old

Dg.: infectious arthritis

Microscopy: Gram-positive cocci
in clusters



Author: doc. MVDr. Oto Melter, PhD.



CHARLES UNIVERSITY
Second Faculty of Medicine

Slide No. 35

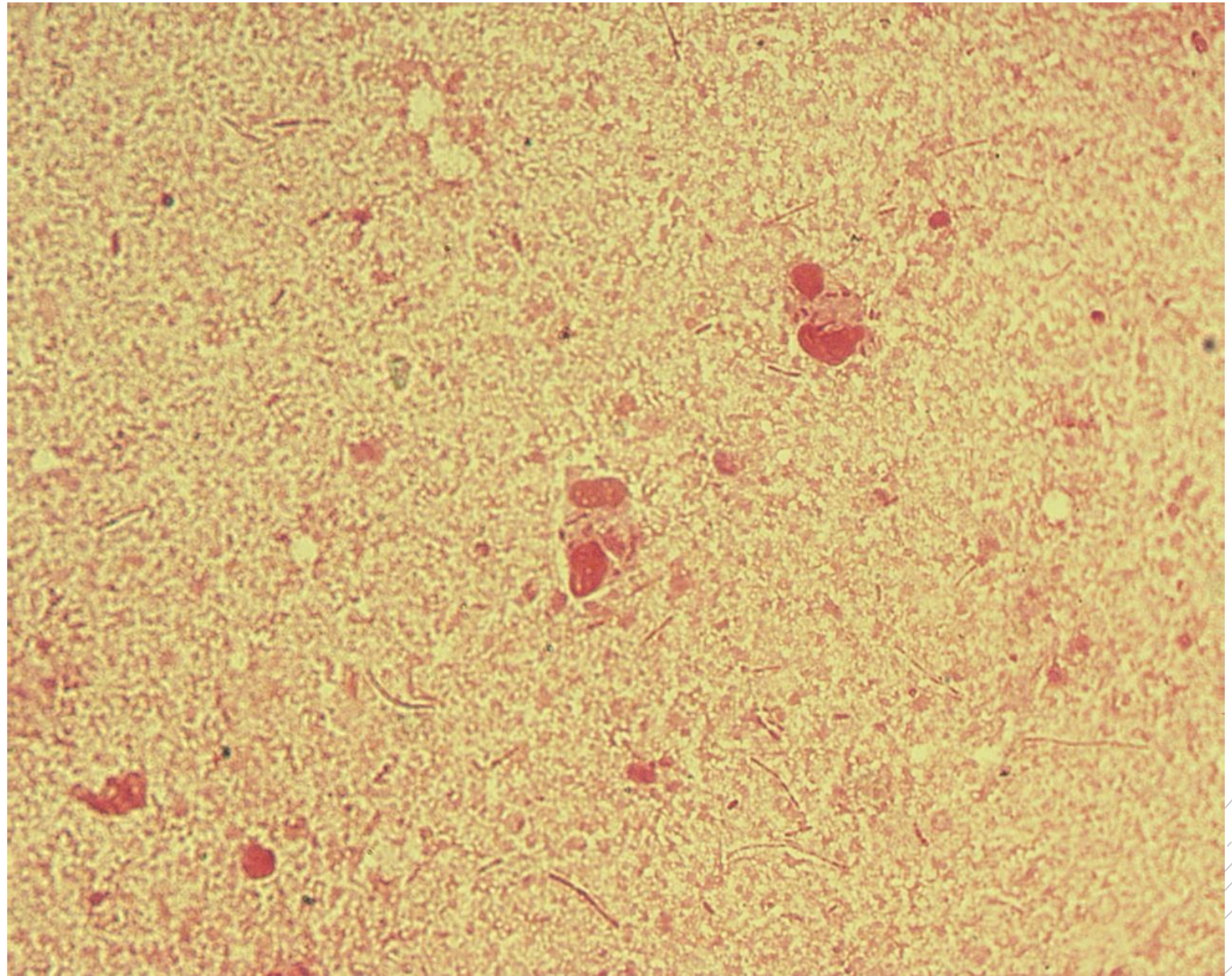
Burkholderia cepacia

Specimen: sputum

Patient: male, 16 years old

Dg.: cystic fibrosis (exacerbation)

Microscopy: Gram-negative rods



Author: doc. MVDr. Oto Melter, PhD.



CHARLES UNIVERSITY
Second Faculty of Medicine

Slide No. 35

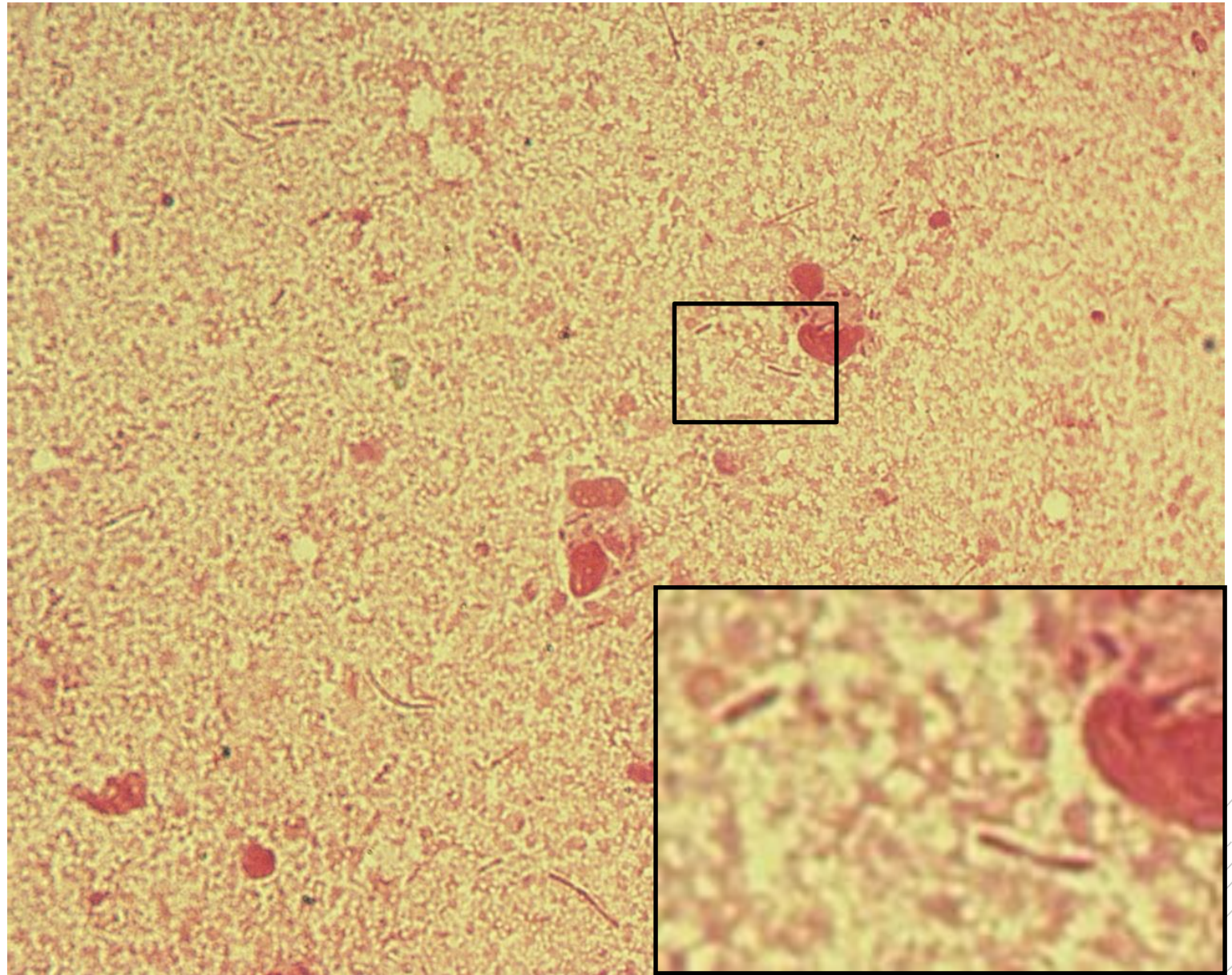
Burkholderia cepacia

Specimen: sputum

Patient: male, 16 years old

Dg.: cystic fibrosis (exacerbation)

Microscopy: Gram-negative rods



Author: doc. MVDr. Oto Melter, PhD.



CHARLES UNIVERSITY
Second Faculty of Medicine

Slide No. 36

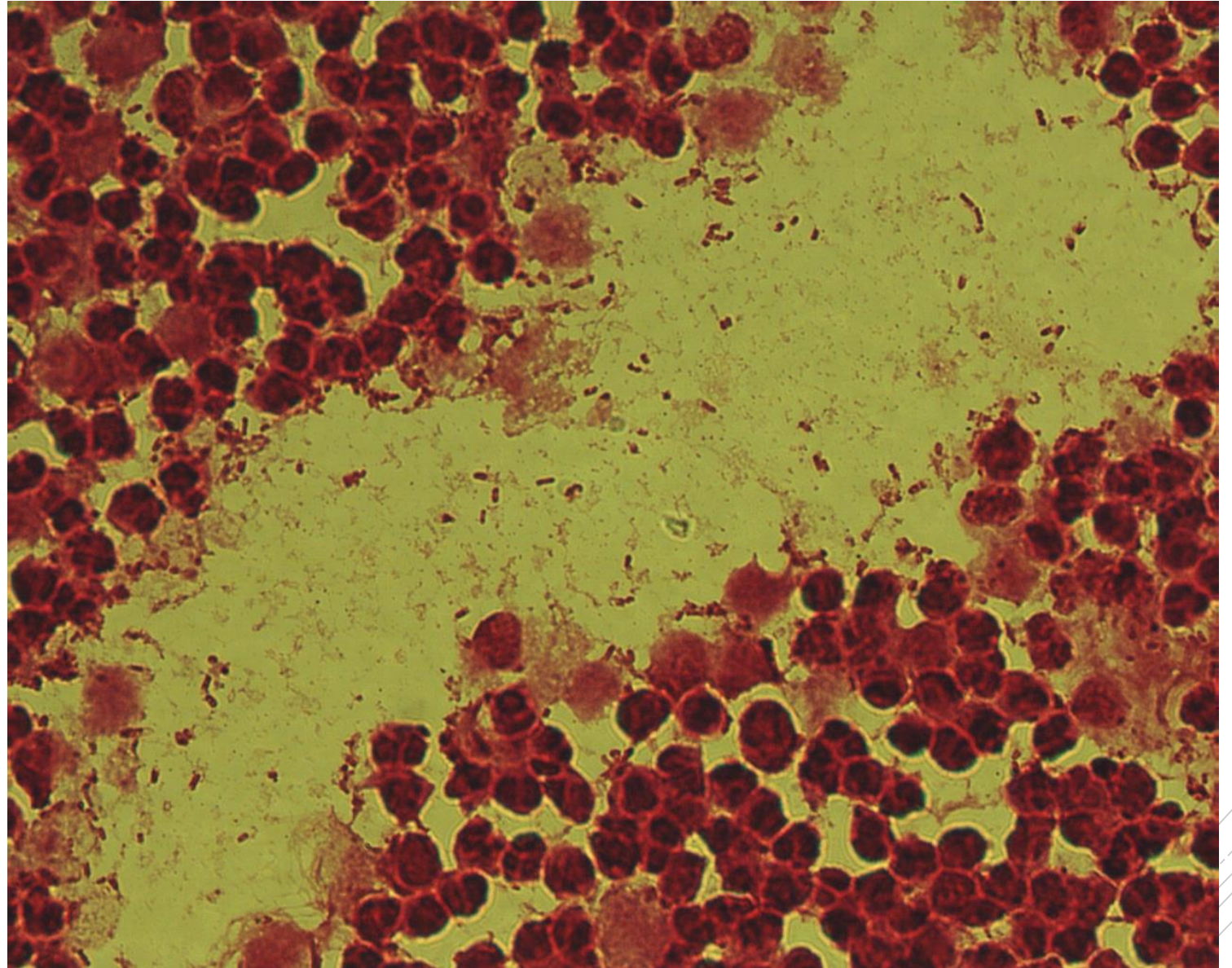
Escherichia coli

Specimen: kidney tissue

Patient: female, 54 years old

Dg.: kidney stones

Microscopy: Gram-negative rods



Author: MUDr. Alena Pířová



CHARLES UNIVERSITY
Second Faculty of Medicine

Slide No. 36

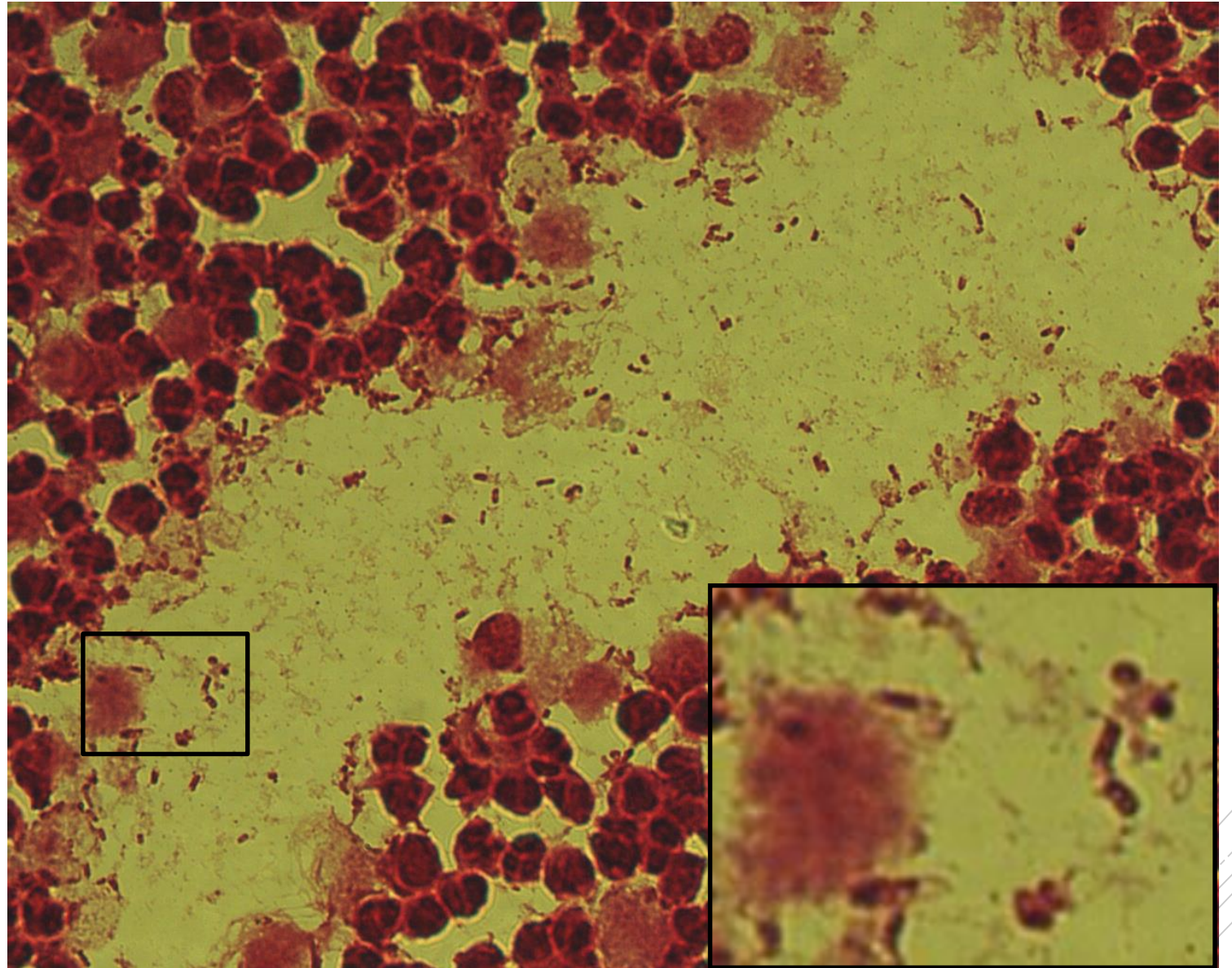
Escherichia coli

Specimen: kidney tissue

Patient: female, 54 years old

Dg.: kidney stones

Microscopy: Gram-negative rods



Author: MUDr. Alena Pířová



CHARLES UNIVERSITY
Second Faculty of Medicine

Slide No. 37

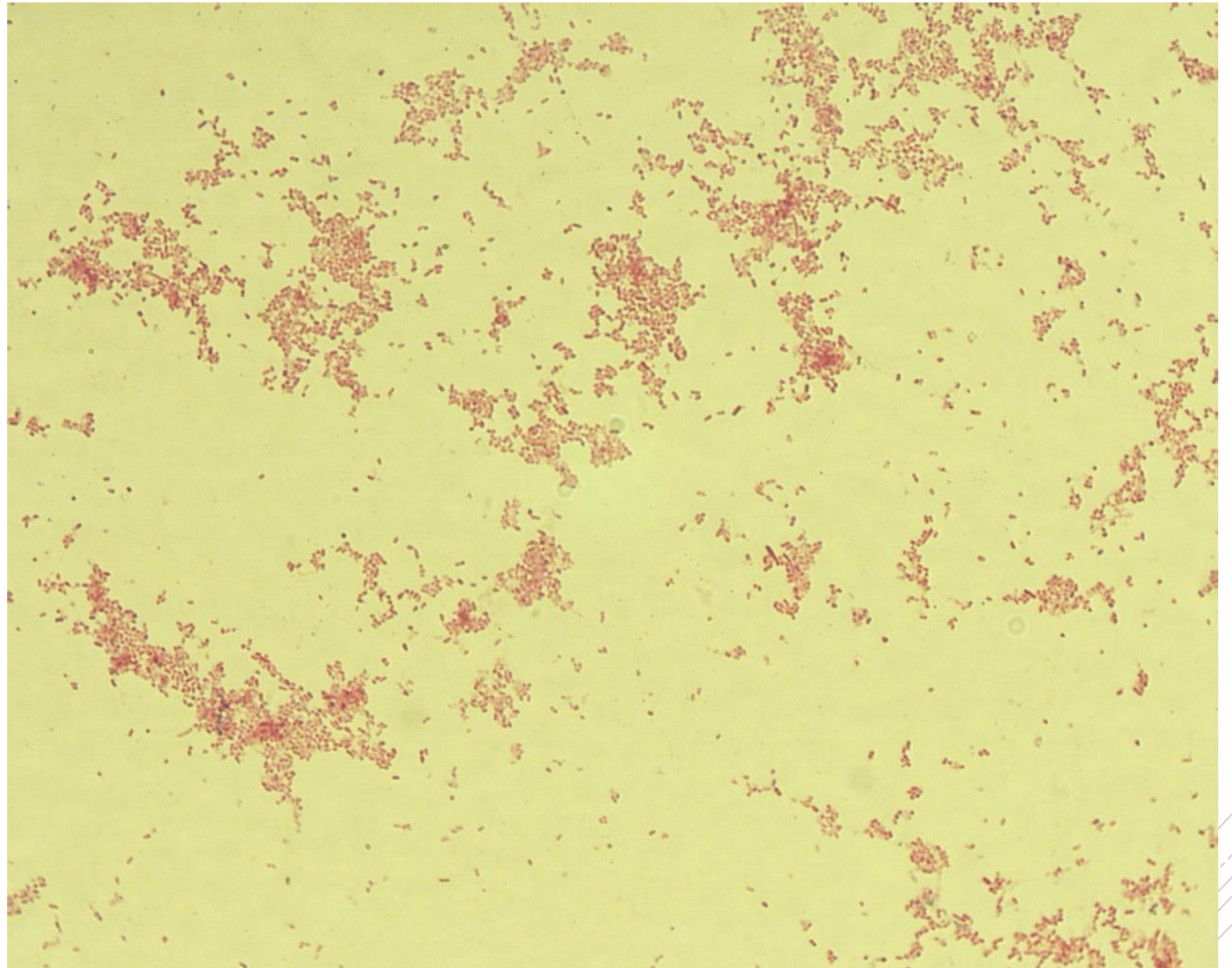
Yersinia enterocolitica

Specimen: culture

Patient: female, 22 years old

Dg.: enterocolitis

Microscopy: Gram-negative rods



Author: MUDr. Alena Pířová



CHARLES UNIVERSITY
Second Faculty of Medicine

Slide No. 37


Yersinia enterocolitica

Specimen: culture

Patient: female, 22 years old

Dg.: enterocolitis

Microscopy: Gram-negative rods



Author: MUDr. Alena Píšová



CHARLES UNIVERSITY
Second Faculty of Medicine

Slide No. 38

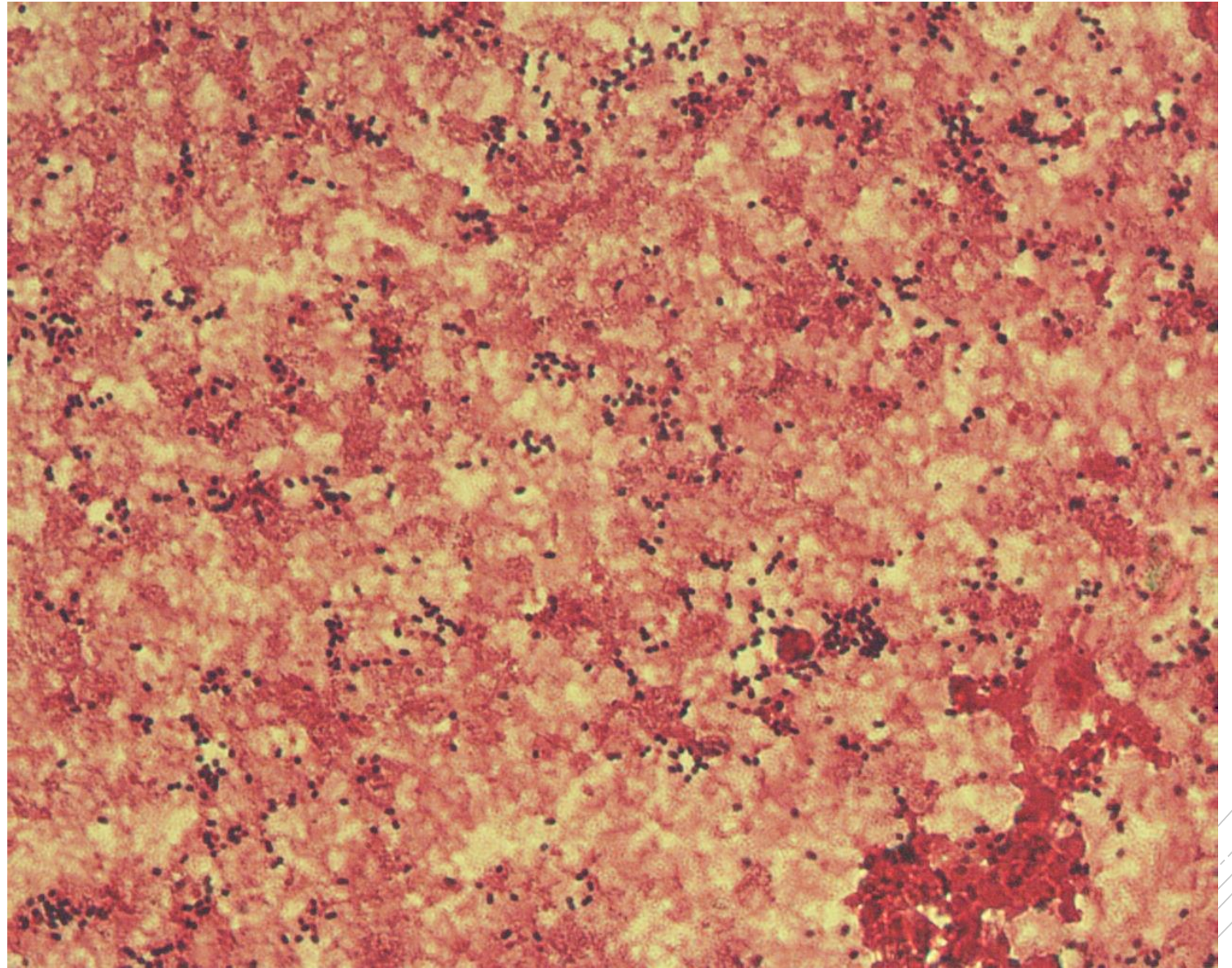
Streptococcus pneumoniae

Specimen: blood culture

Patient: female, 63 years old

Dg.: pneumonia

Microscopy: Gram-positive diplococci



Authors: MUDr. Petra Kabelíková, Sandra Opálková



CHARLES UNIVERSITY
Second Faculty of Medicine

Slide No. 38

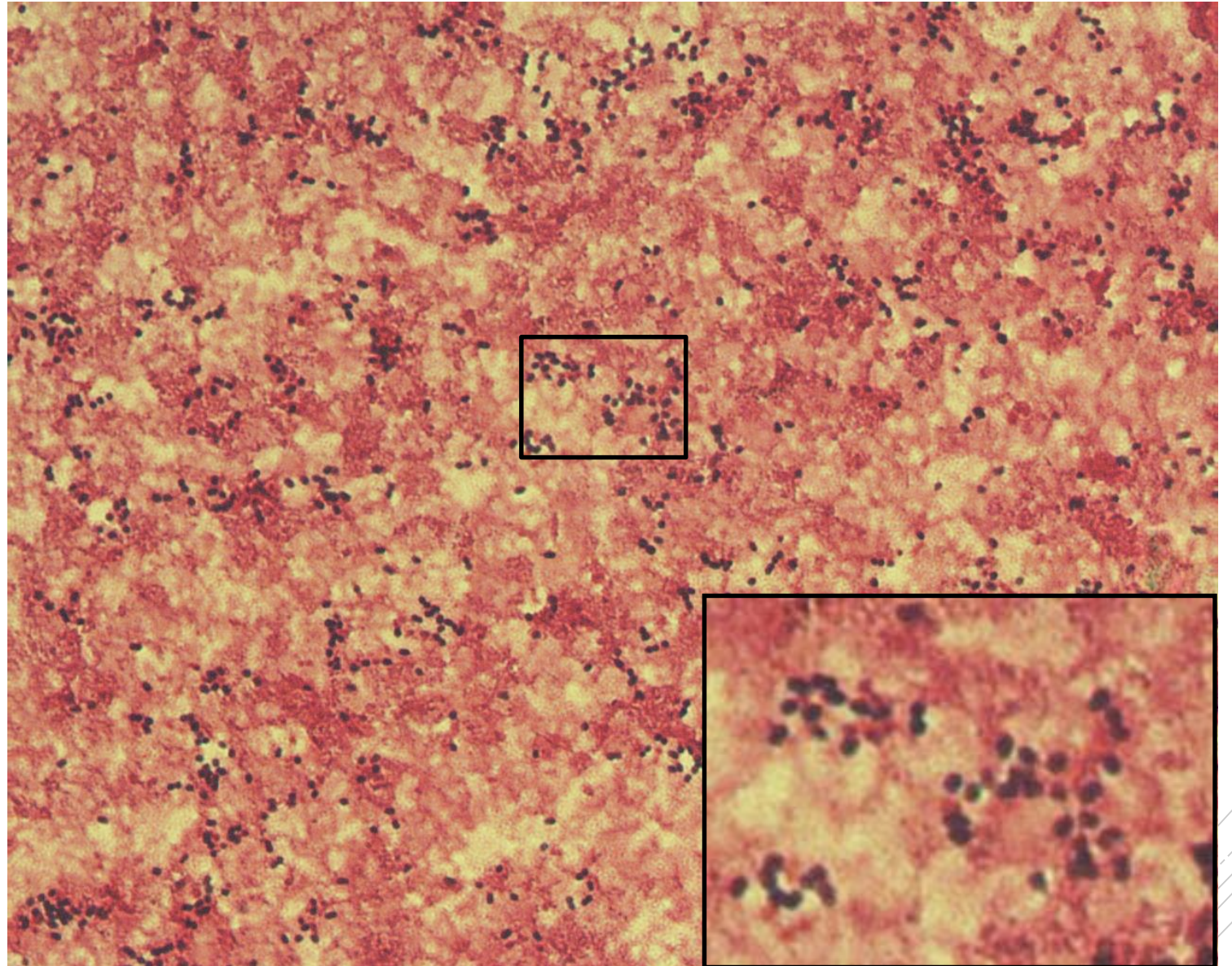
Streptococcus pneumoniae

Specimen: blood culture

Patient: female, 63 years old

Dg.: pneumonia

Microscopy: Gram-positive diplococci



Authors: MUDr. Petra Kabelíková, Sandra Opálková



CHARLES UNIVERSITY
Second Faculty of Medicine

Slide No. 39

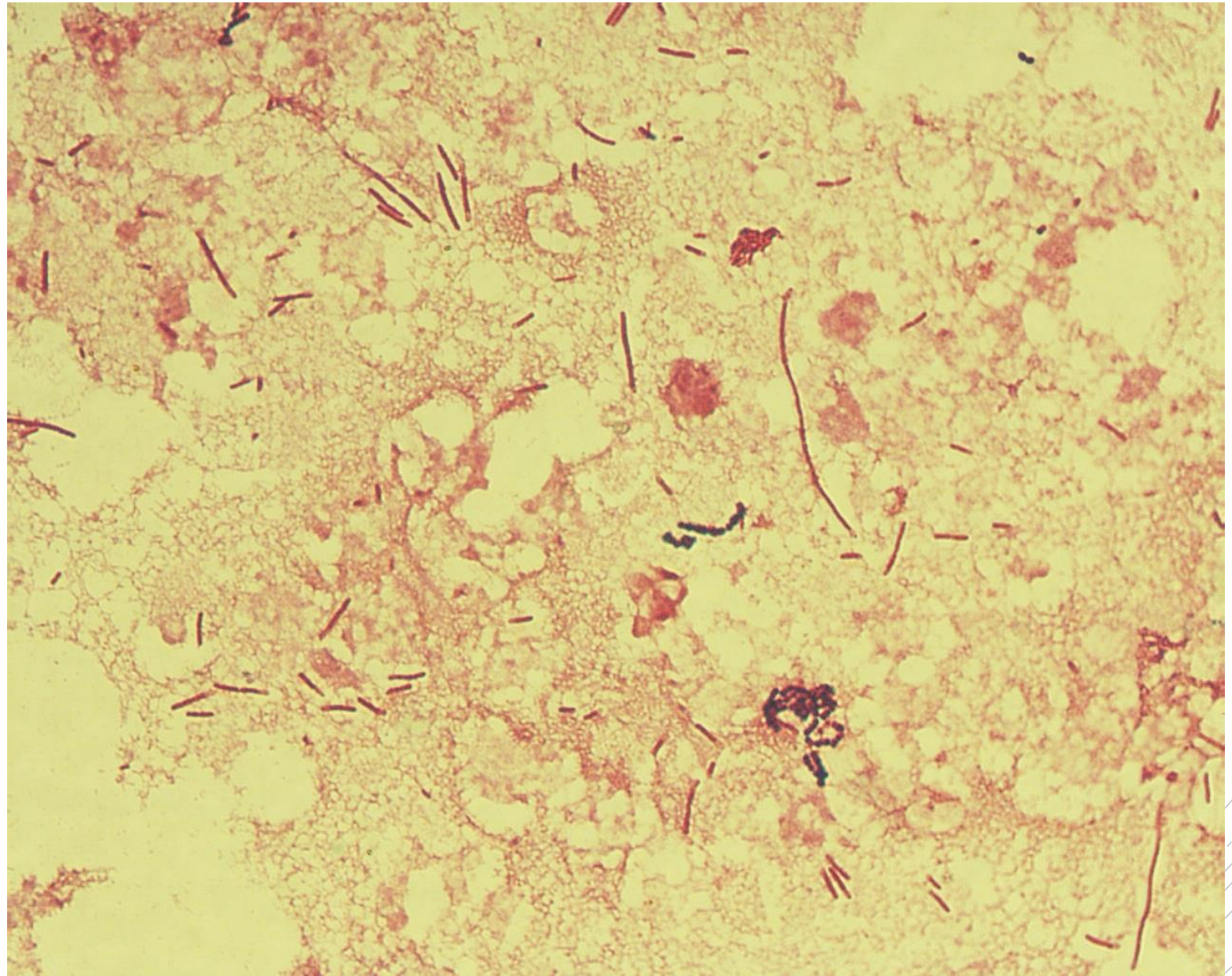
Citrobacter freundii

Specimen: Pus

Patient: male, 70 years old

Dg.: pancreatic cancer

Microscopy: Gram-negative rods



Author: MUDr. Alena Pířová



CHARLES UNIVERSITY
Second Faculty of Medicine

Slide No. 39

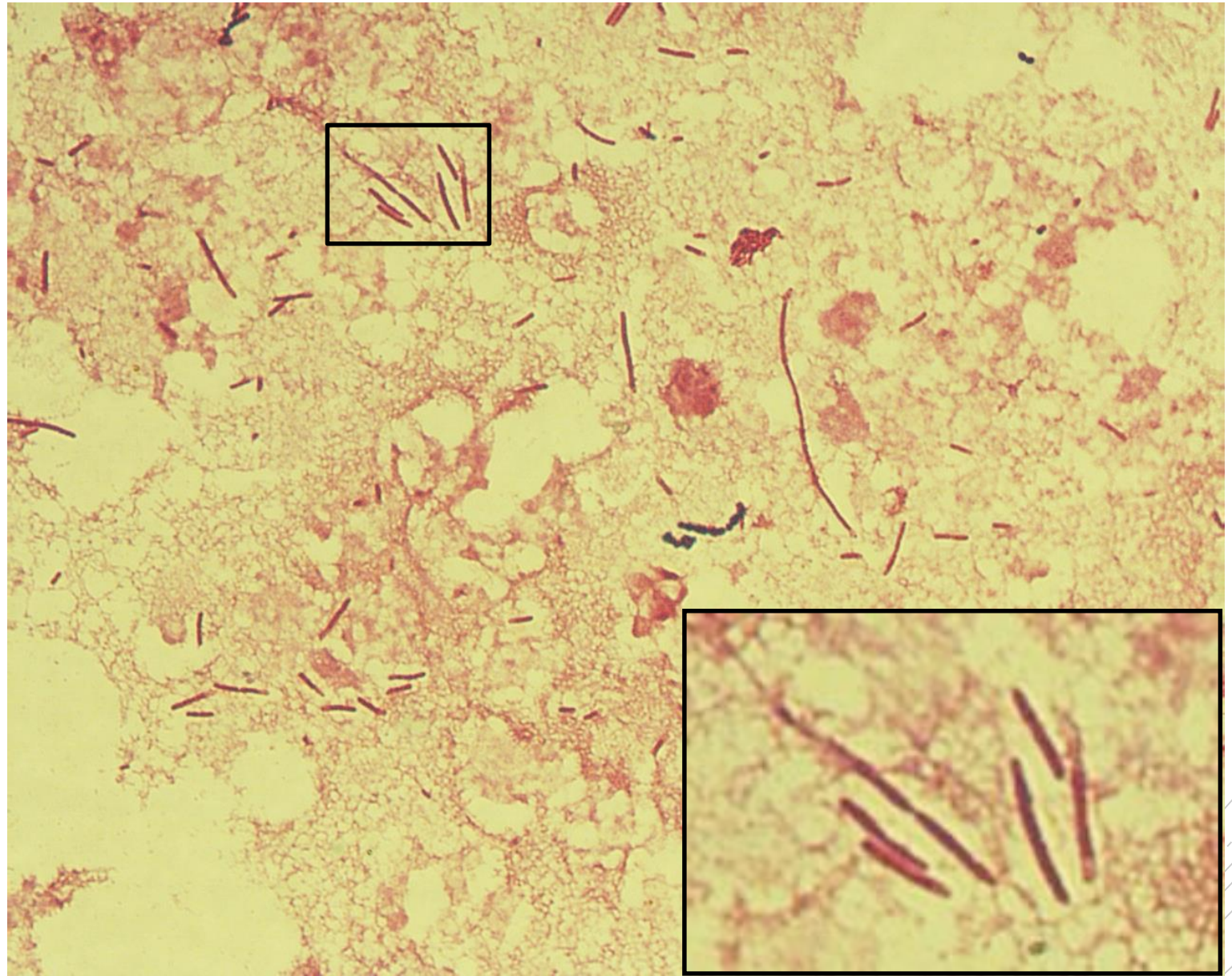
Citrobacter freundii

Specimen: Pus

Patient: male, 70 years old

Dg.: pancreatic cancer

Microscopy: Gram-negative rods



Author: MUDr. Alena Pířová



CHARLES UNIVERSITY
Second Faculty of Medicine

Slide No. 40

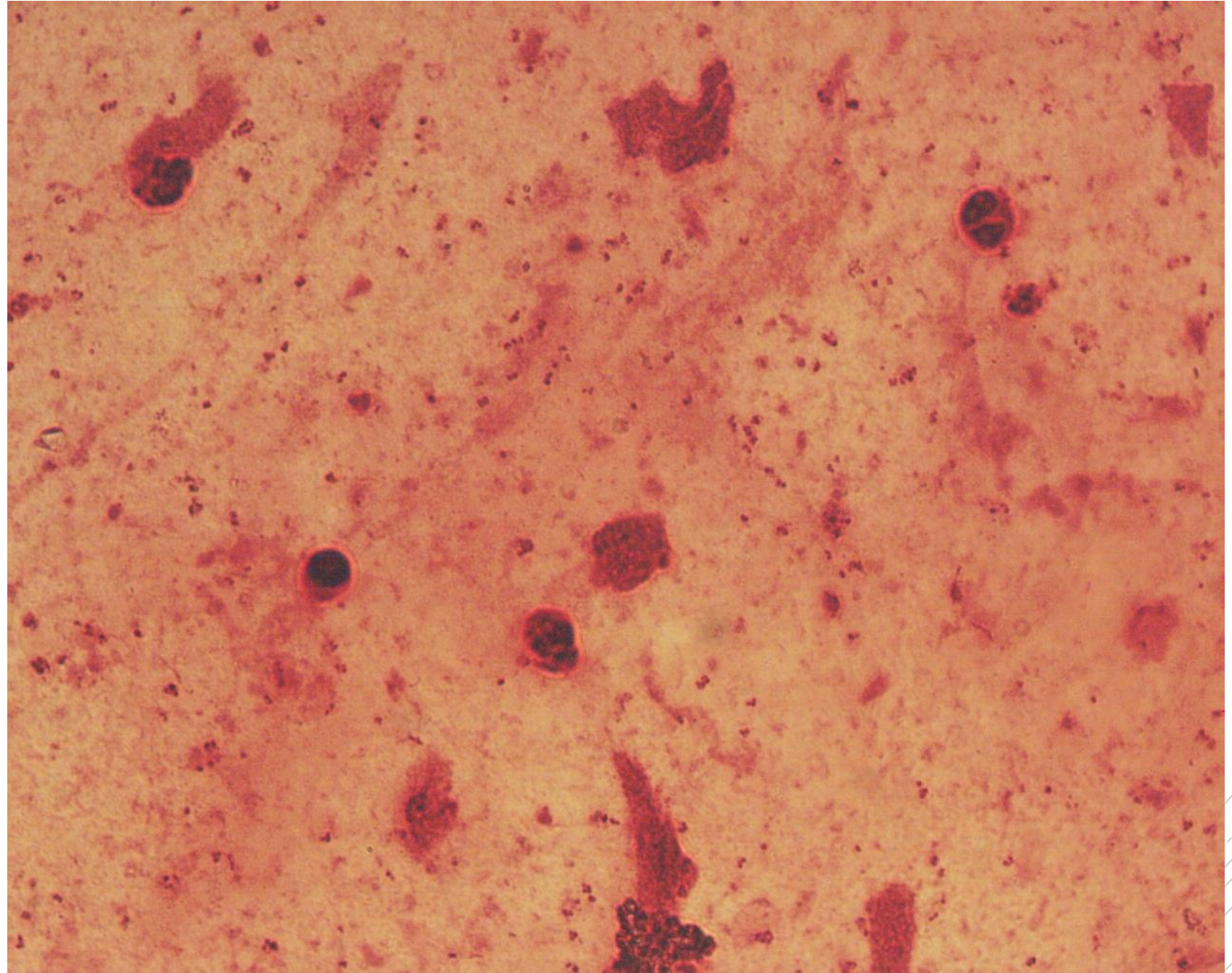
Neisseria meningitidis

Specimen: CSF

Patient: male, 25 years old

Dg.: purulent meningitis

Microscopy: Gram-negative diplococci



Author: MUDr. Alena Pířová



CHARLES UNIVERSITY
Second Faculty of Medicine

Slide No. 40

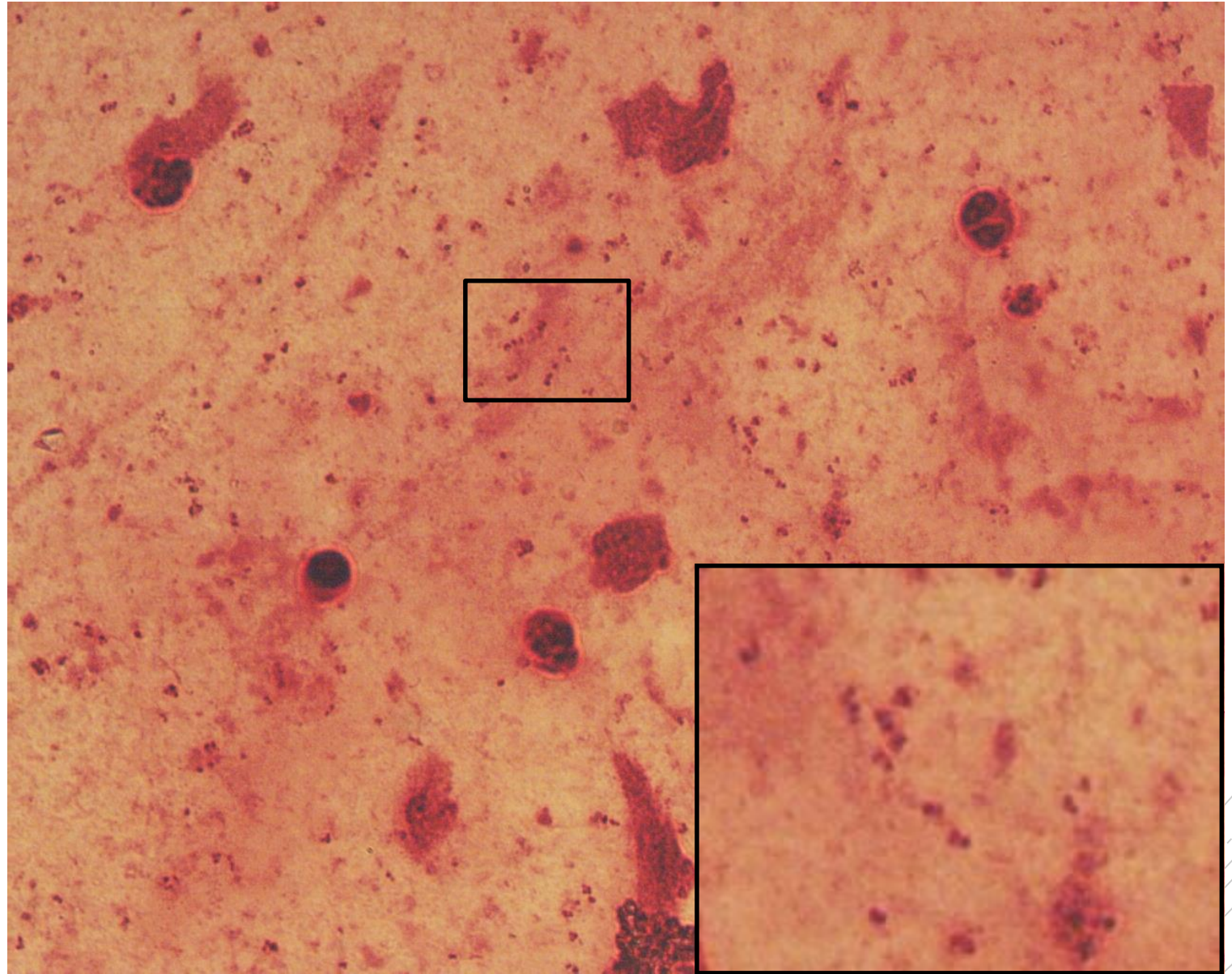
Neisseria meningitidis

Specimen: CSF

Patient: male, 25 years old

Dg.: purulent meningitis

Microscopy: Gram-negative diplococci



Author: MUDr. Alena Pířová



CHARLES UNIVERSITY
Second Faculty of Medicine

Slide No. 41

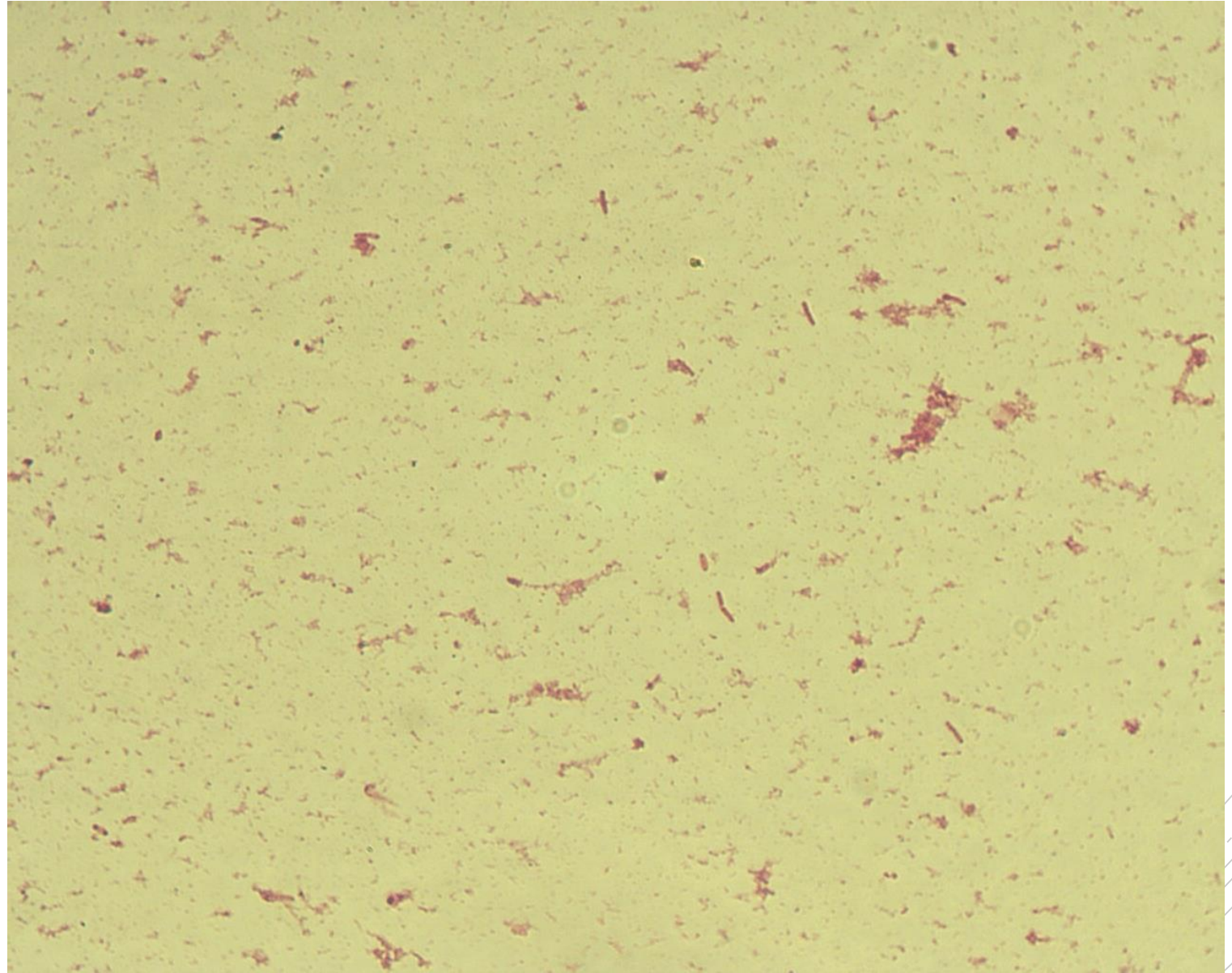
Salmonella Typhi

Specimen: blood culture

Patient: male, 25 years old

Dg.: typhoid fever

Microscopy: Gram-negative rods



Authors: MUDr. Petra Kabelíková, Sandra Opálková



CHARLES UNIVERSITY
Second Faculty of Medicine

Slide No. 41

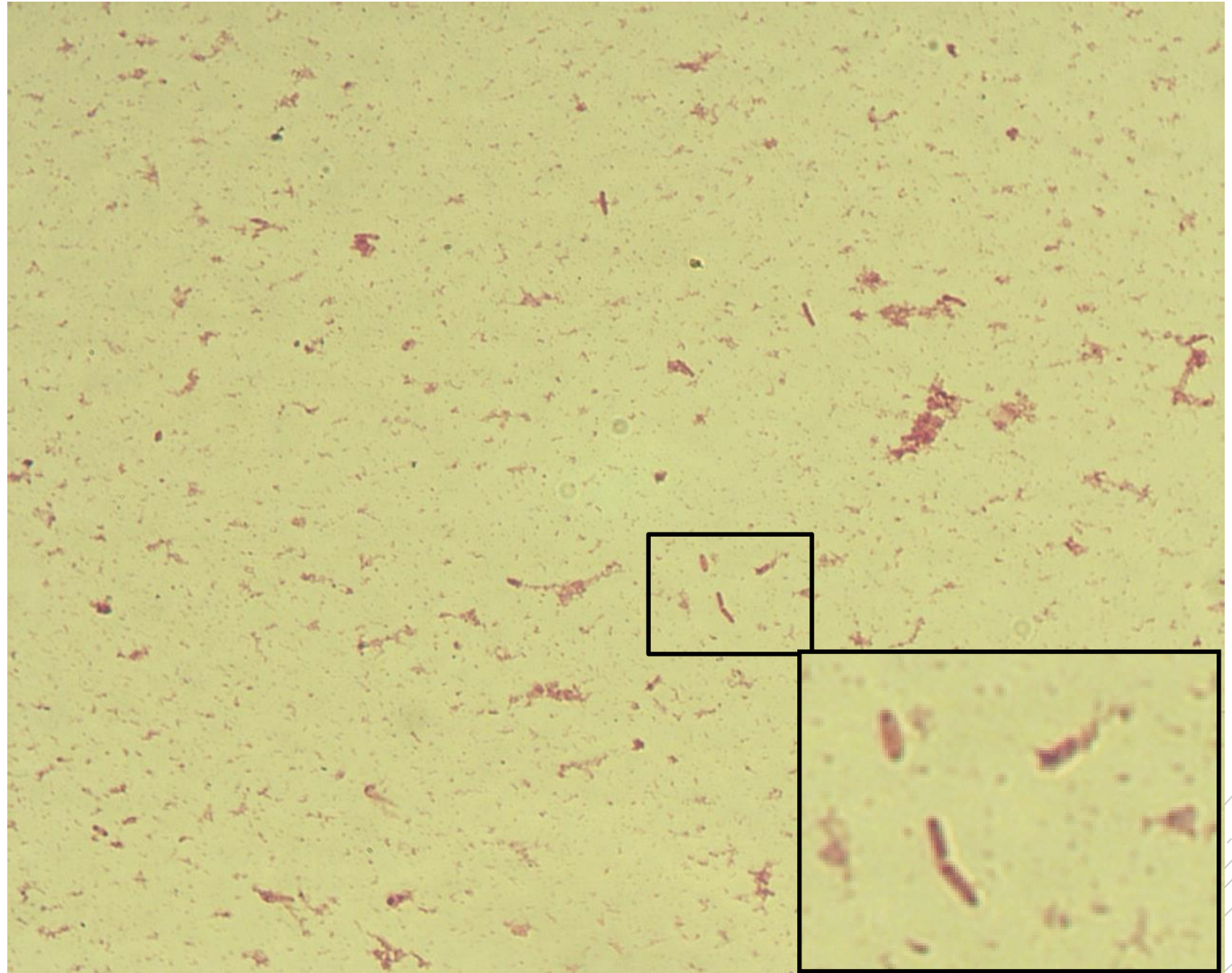
Salmonella Typhi

Specimen: blood culture

Patient: male, 25 years old

Dg.: typhoid fever

Microscopy: Gram-negative rods



Authors: MUDr. Petra Kabelíková, Sandra Opálková



CHARLES UNIVERSITY
Second Faculty of Medicine

Slide No. 42

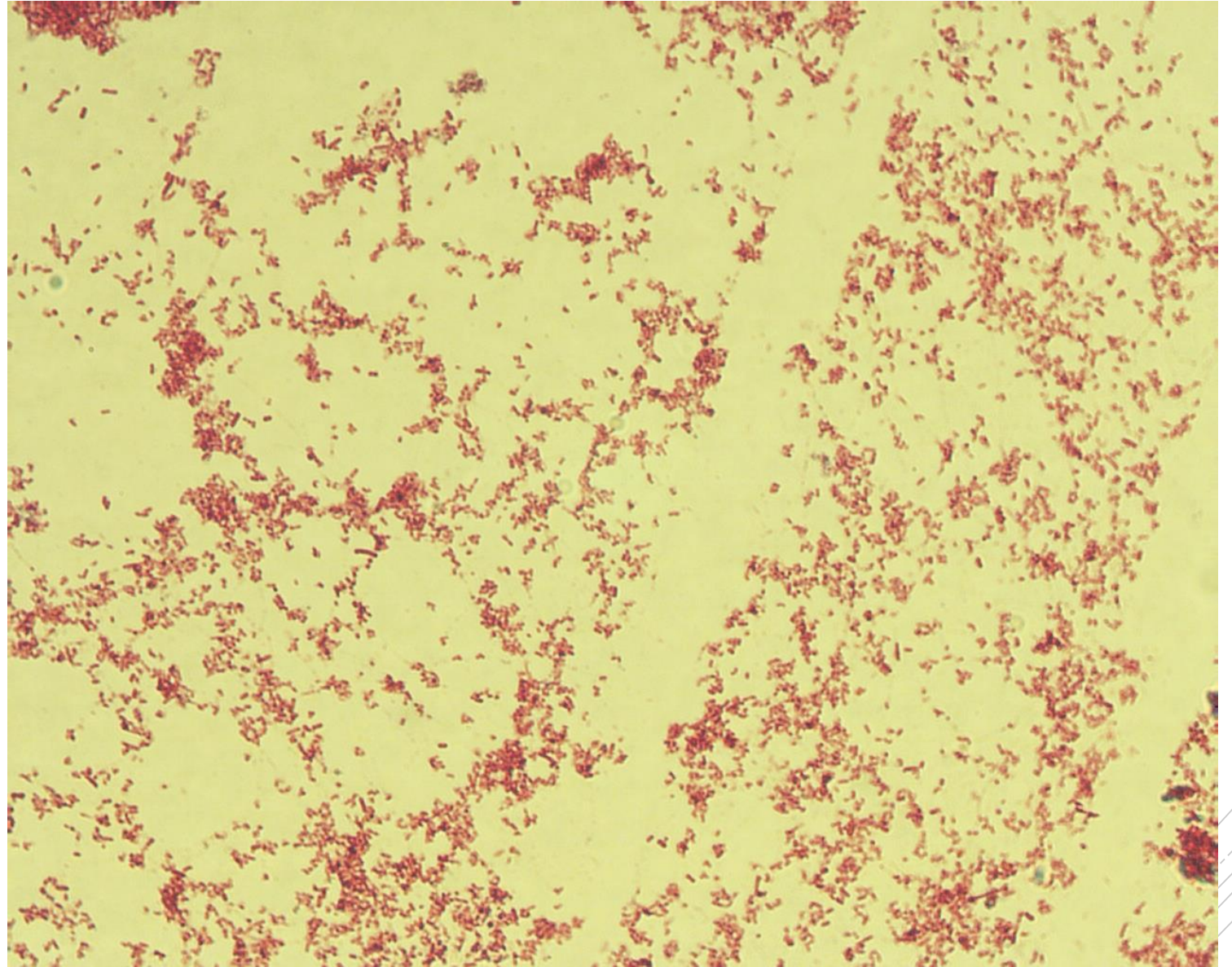
Salmonella Typhi

Specimen: culture - stools

Patient: male, 32 years old

Dg.: typhoid fever

Microscopy: Gram-negative rods



Author: MUDr. Lenka Tritová



CHARLES UNIVERSITY
Second Faculty of Medicine

Slide No. 42

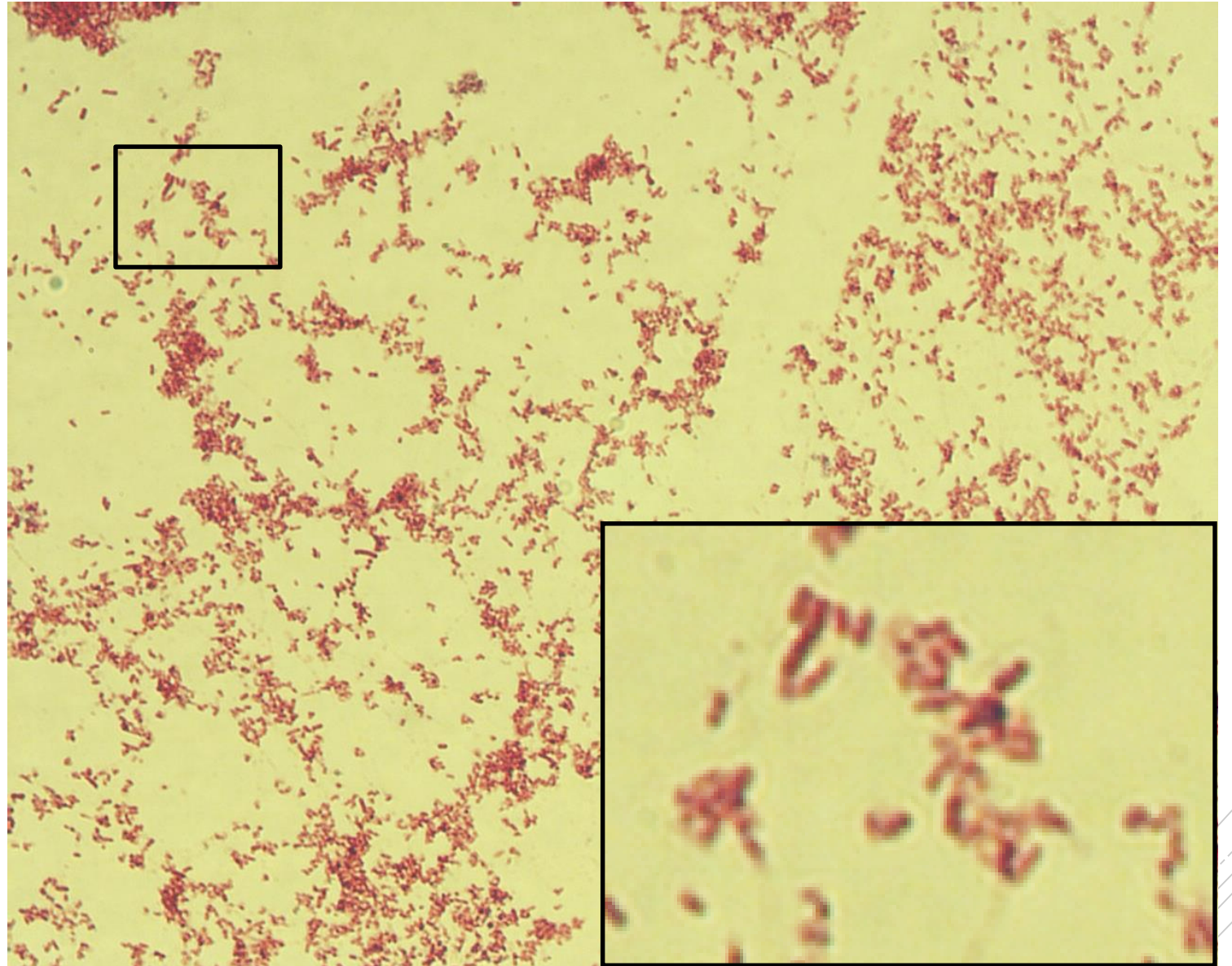
Salmonella Typhi

Specimen: culture - stools

Patient: male, 32 years old

Dg.: typhoid fever

Microscopy: Gram-negative rods



Author: MUDr. Lenka Tritová



CHARLES UNIVERSITY
Second Faculty of Medicine

Slide No. 43

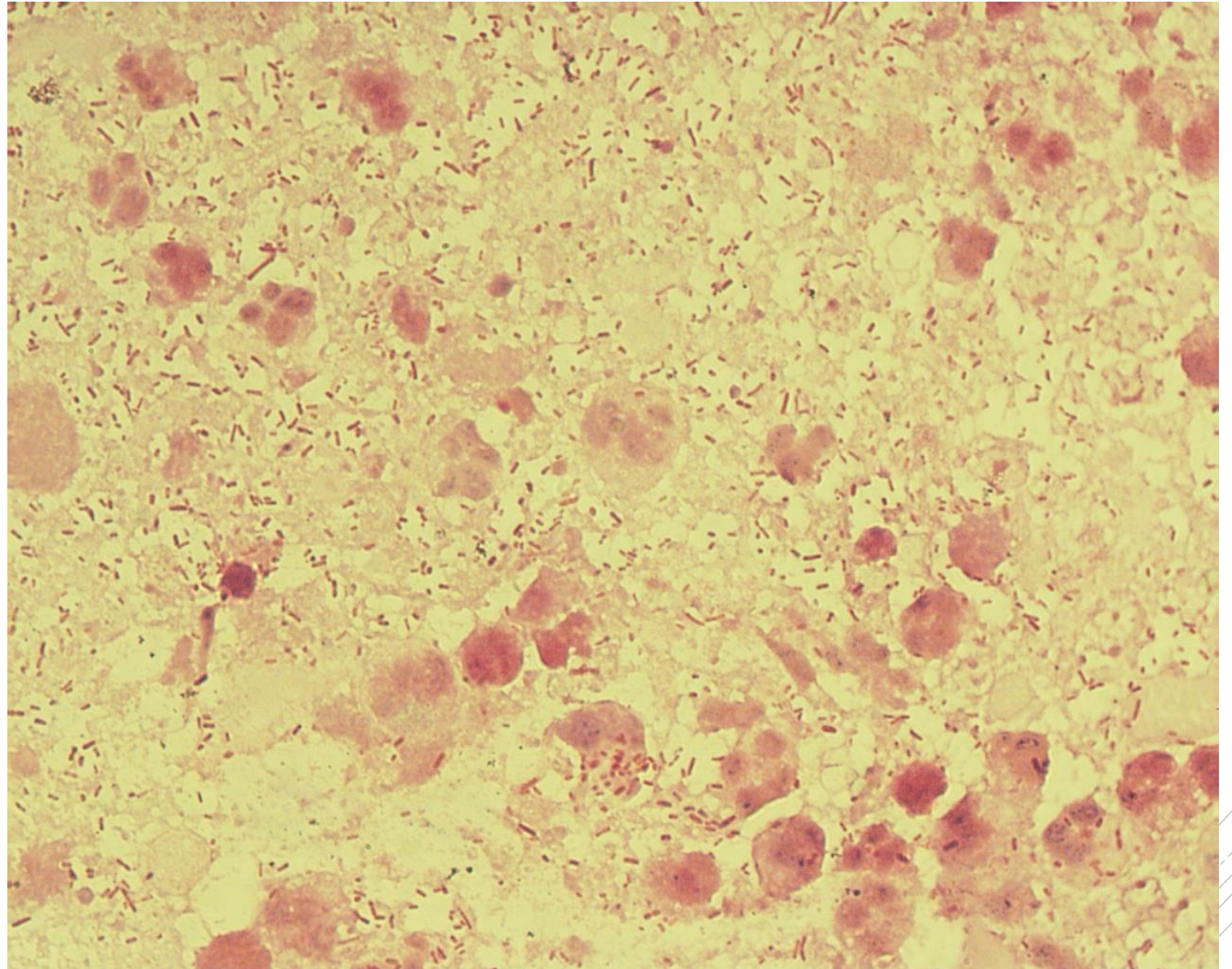
Escherichia coli

Specimen: abdominal fluid

Patient: female, 43 years old

Dg.: peritonitis

Microscopy: Gram-negative rods



Author: MUDr. Alena Pířová



CHARLES UNIVERSITY
Second Faculty of Medicine

Slide No. 43

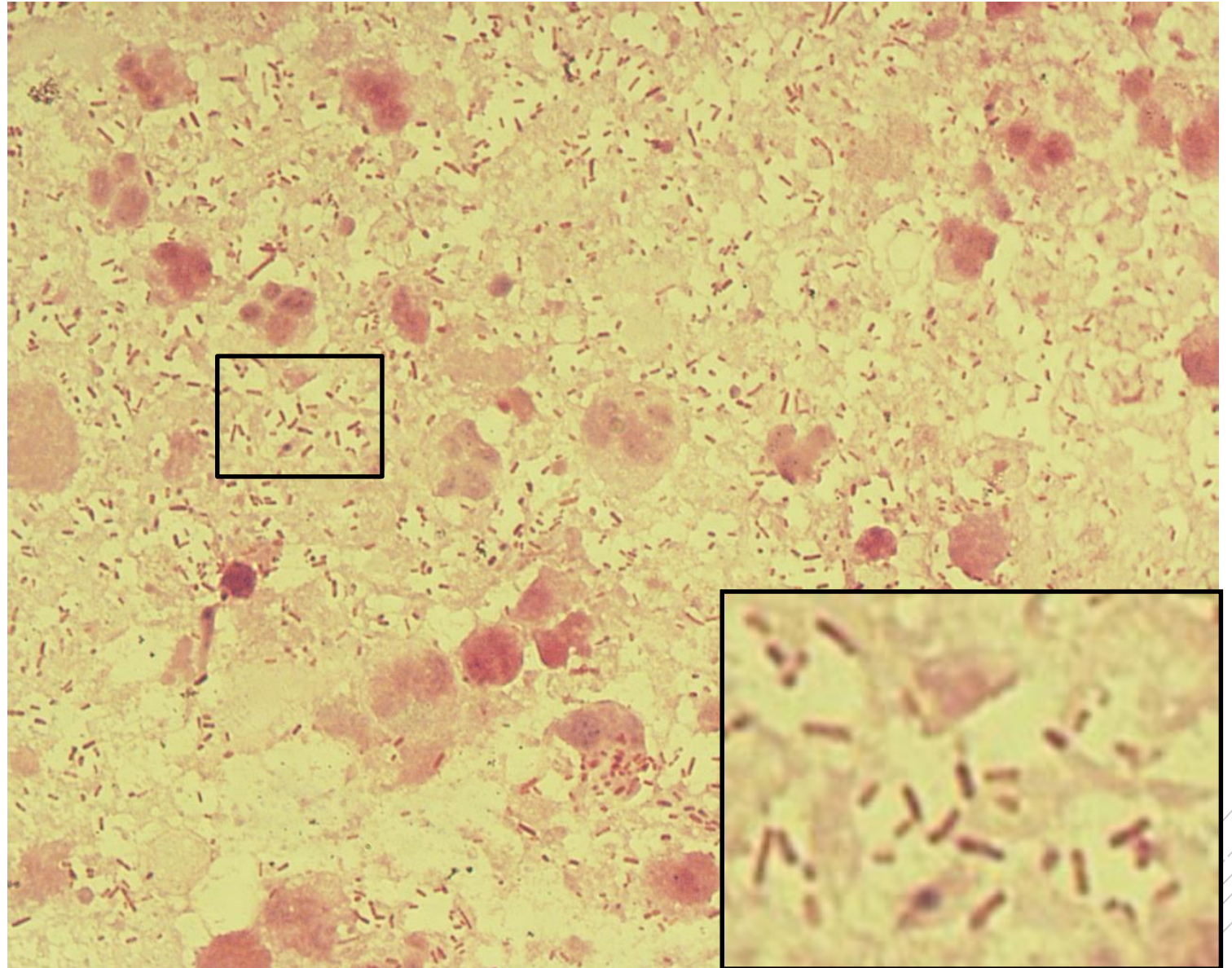
Escherichia coli

Specimen: abdominal fluid

Patient: female, 43 years old

Dg.: peritonitis

Microscopy: Gram-negative rods



Author: MUDr. Alena Pířová



CHARLES UNIVERSITY
Second Faculty of Medicine

Slide No. 44

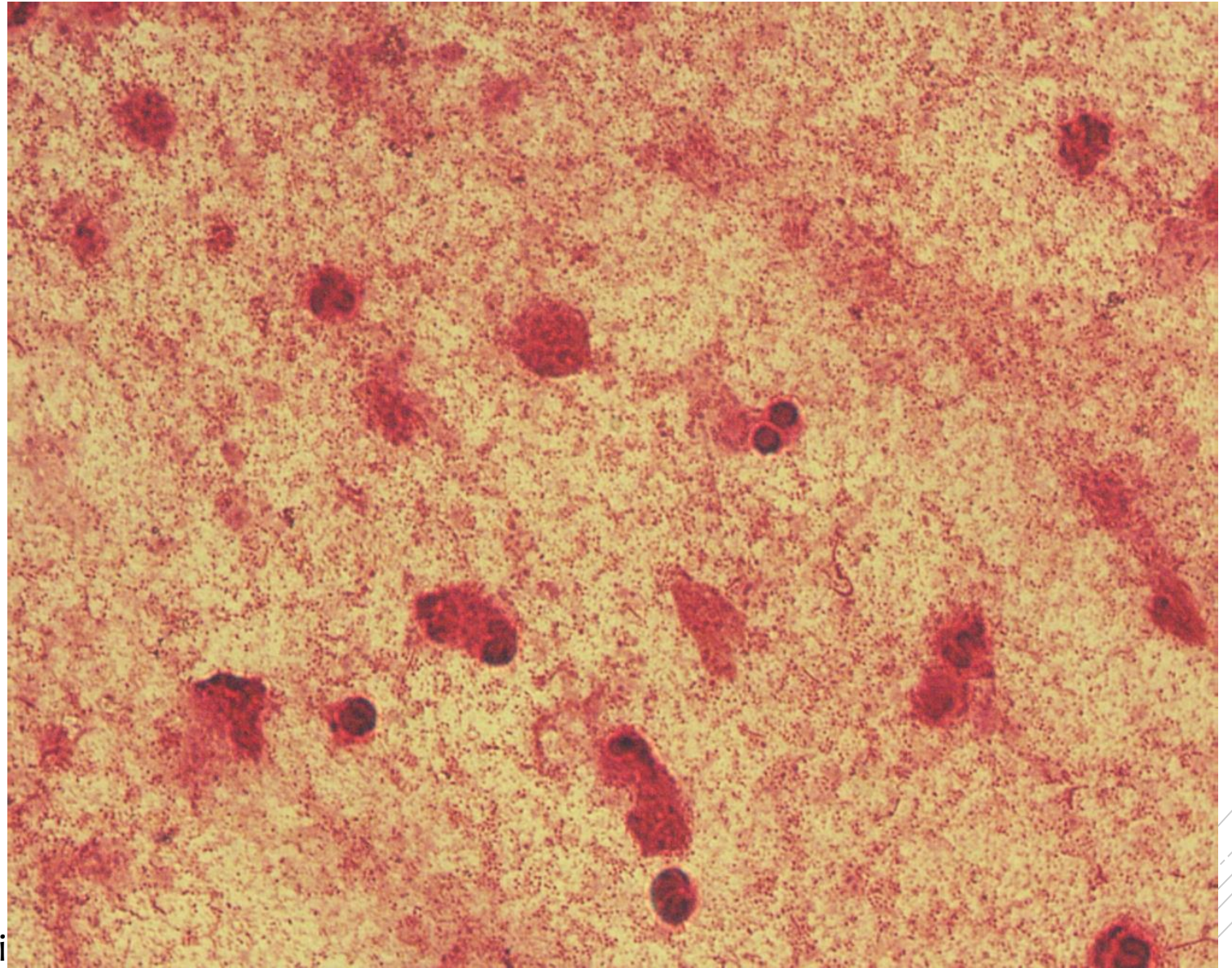
Pasteurella multocida

Specimen: sputum

Patient: male, 53 years old

Dg.: pneumonia

Microscopy: Gram-negative coccobacilli



Author: MUDr. Daniela Lžičarová



CHARLES UNIVERSITY
Second Faculty of Medicine

Slide No. 44

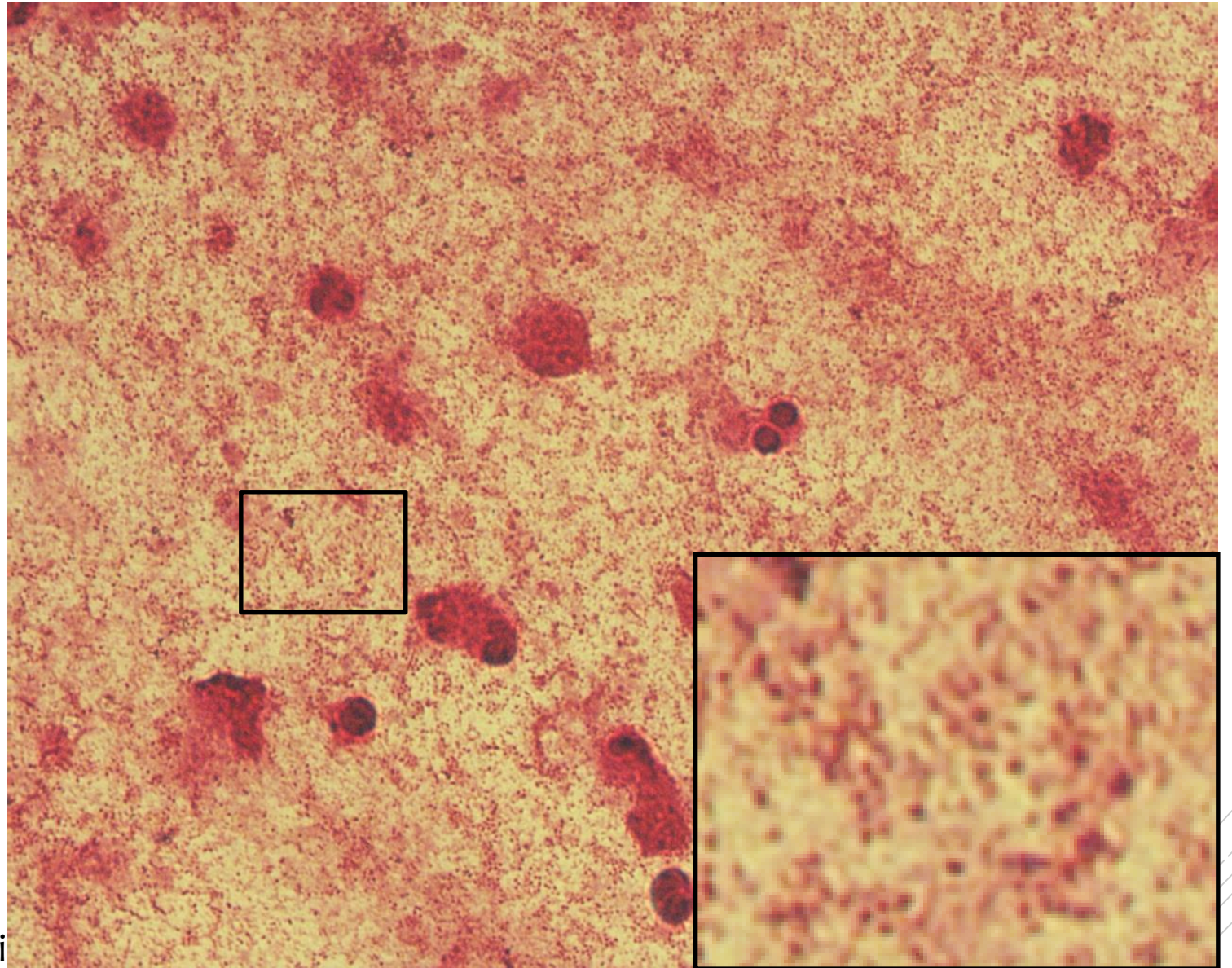
Pasteurella multocida

Specimen: sputum

Patient: male, 53 years old

Dg.: pneumonia

Microscopy: Gram-negative coccobacilli



Author: MUDr. Daniela Lžičarová



CHARLES UNIVERSITY
Second Faculty of Medicine

Slide No. 45

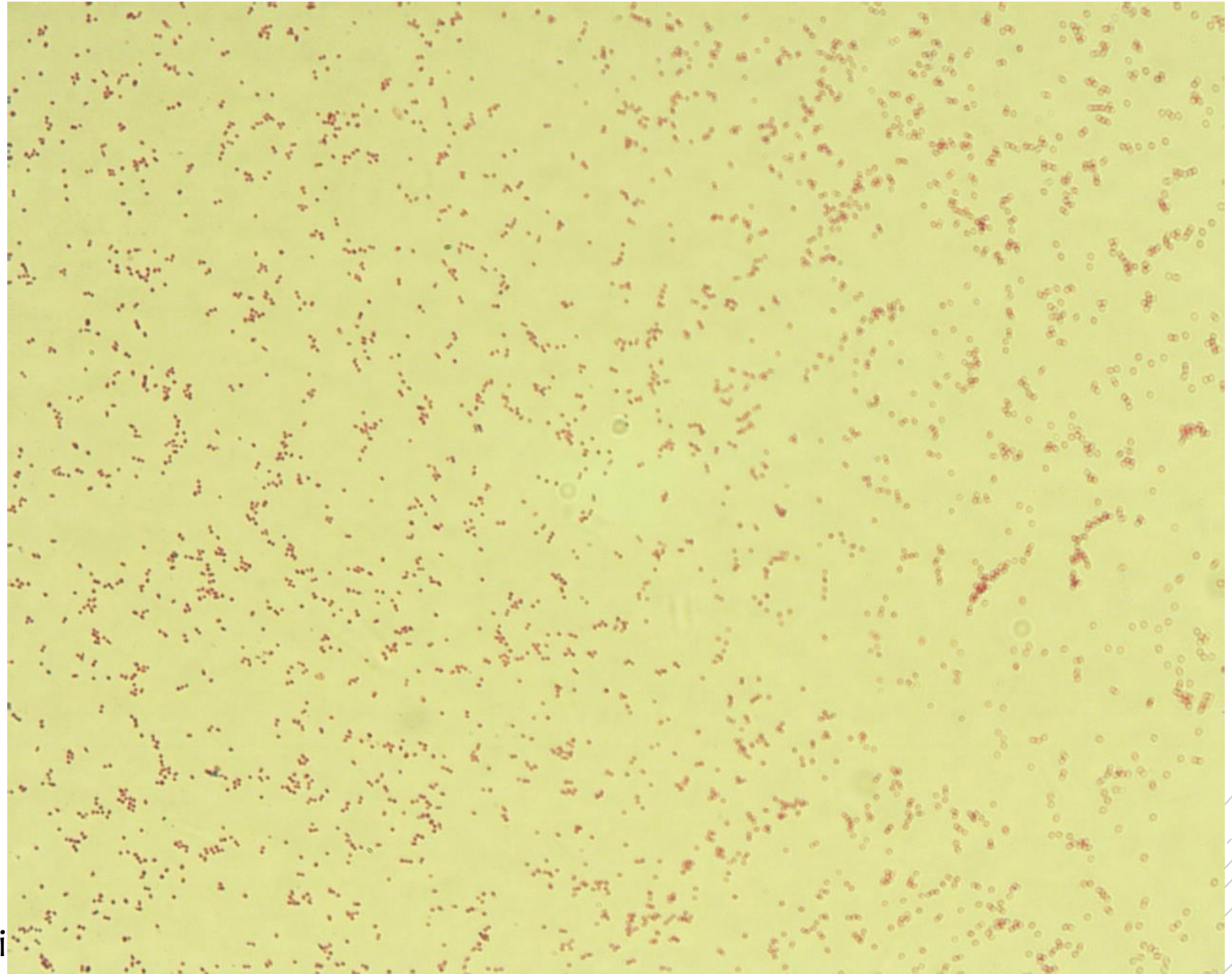
Pasteurella multocida

Specimen: culture - sputum

Patient: male, 53 years old

Dg.: pneumonia

Microscopy: Gram-negative coccobacilli



Author: MUDr. Daniela Lžičarová



CHARLES UNIVERSITY
Second Faculty of Medicine

Slide No. 45


Pasteurella multocida

Specimen: culture - sputum

Patient: male, 53 years old

Dg.: pneumonia

Microscopy: Gram-negative coccobacilli



Author: MUDr. Daniela Lžičarová



CHARLES UNIVERSITY
Second Faculty of Medicine

Slide No. 46

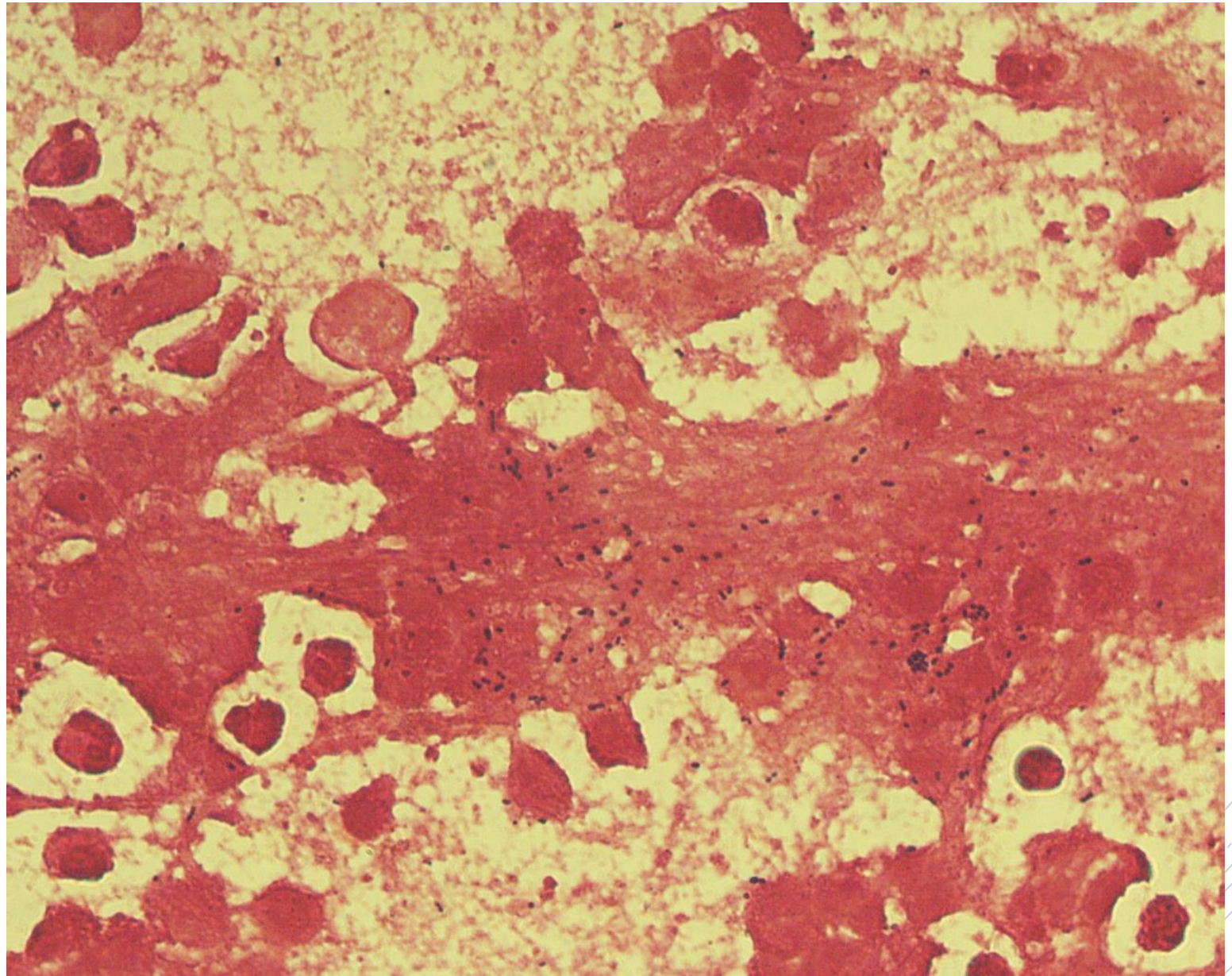
Streptococcus constellatus

Specimen: Pus

Patient: male, 65 years old

Dg.: liver abscess

Microscopy: Gram-positive cocci



Author: MUDr. Alena Pířová



CHARLES UNIVERSITY
Second Faculty of Medicine

Slide No. 46

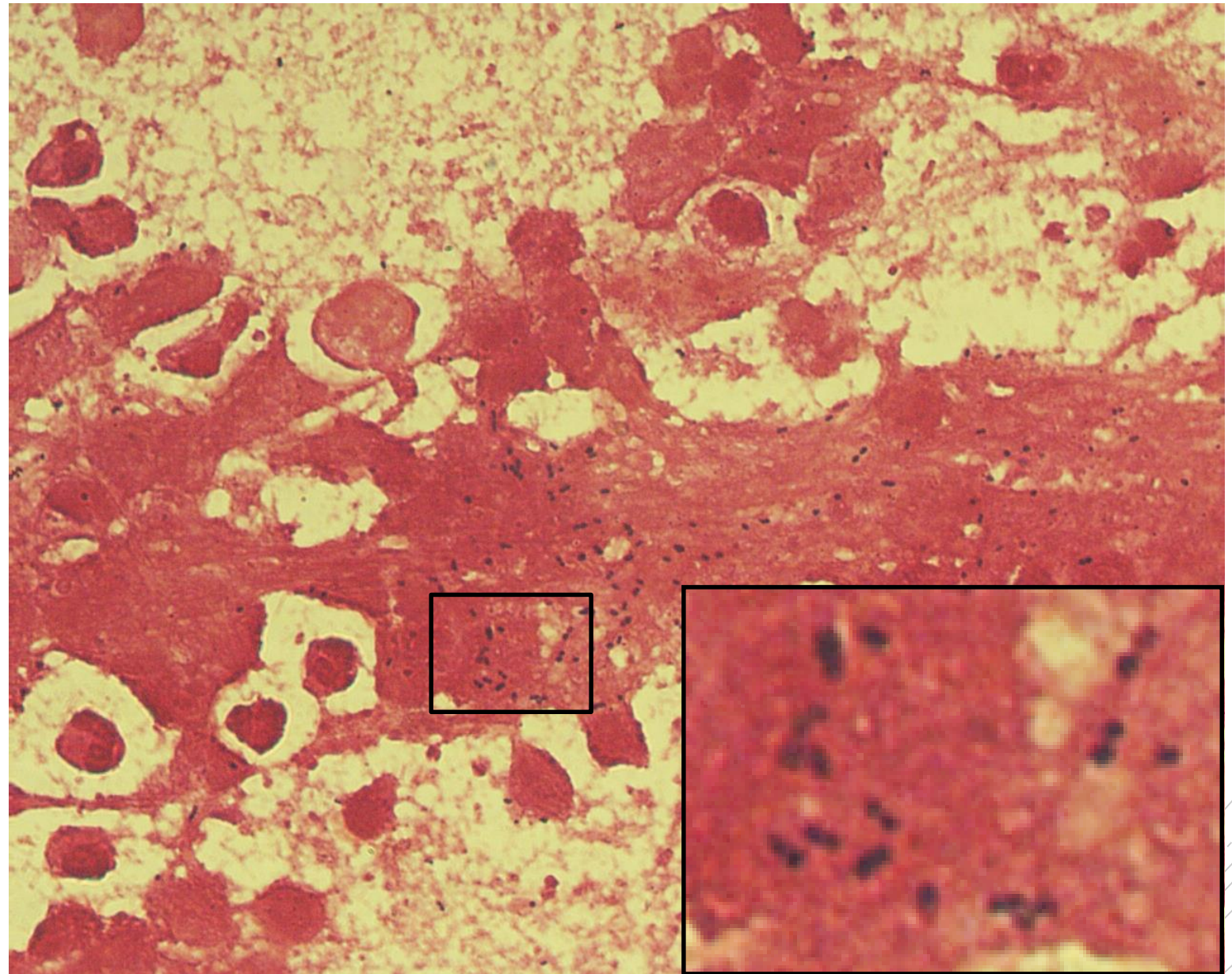
Streptococcus constellatus

Specimen: Pus

Patient: male, 65 years old

Dg.: liver abscess

Microscopy: Gram-positive cocci



Author: MUDr. Alena Pířová



CHARLES UNIVERSITY
Second Faculty of Medicine

Slide No. 47

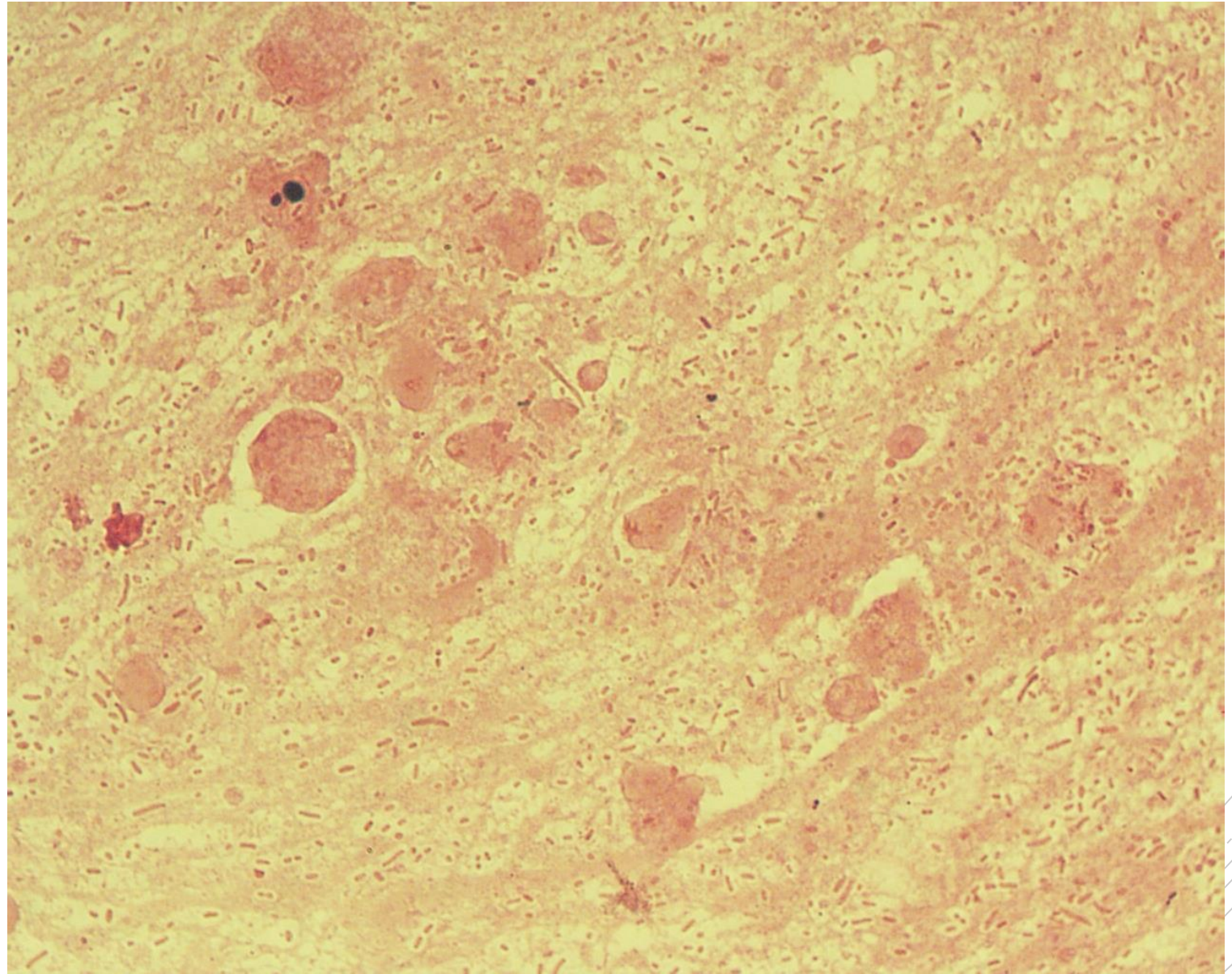
Klebsiella pneumoniae

Specimen: sputum

Patient: female, 85 years old

Dg.: pneumonia

Microscopy: Gram-negative rods



Author: MUDr. Vanda Chrenková



CHARLES UNIVERSITY
Second Faculty of Medicine

Slide No. 47

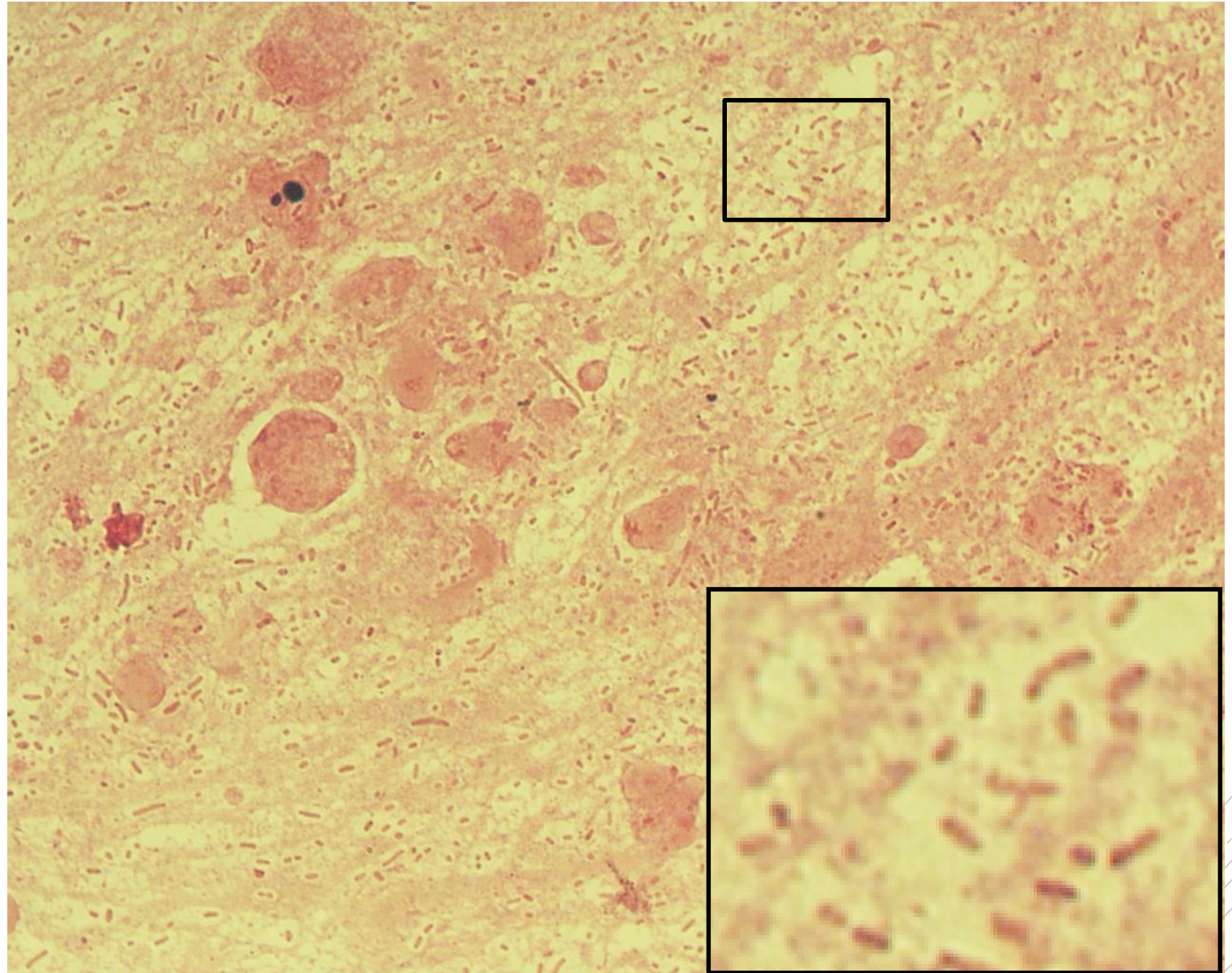
Klebsiella pneumoniae

Specimen: sputum

Patient: female, 85 years old

Dg.: pneumonia

Microscopy: Gram-negative rods



Author: MUDr. Vanda Chrenková



CHARLES UNIVERSITY
Second Faculty of Medicine

Slide No. 48

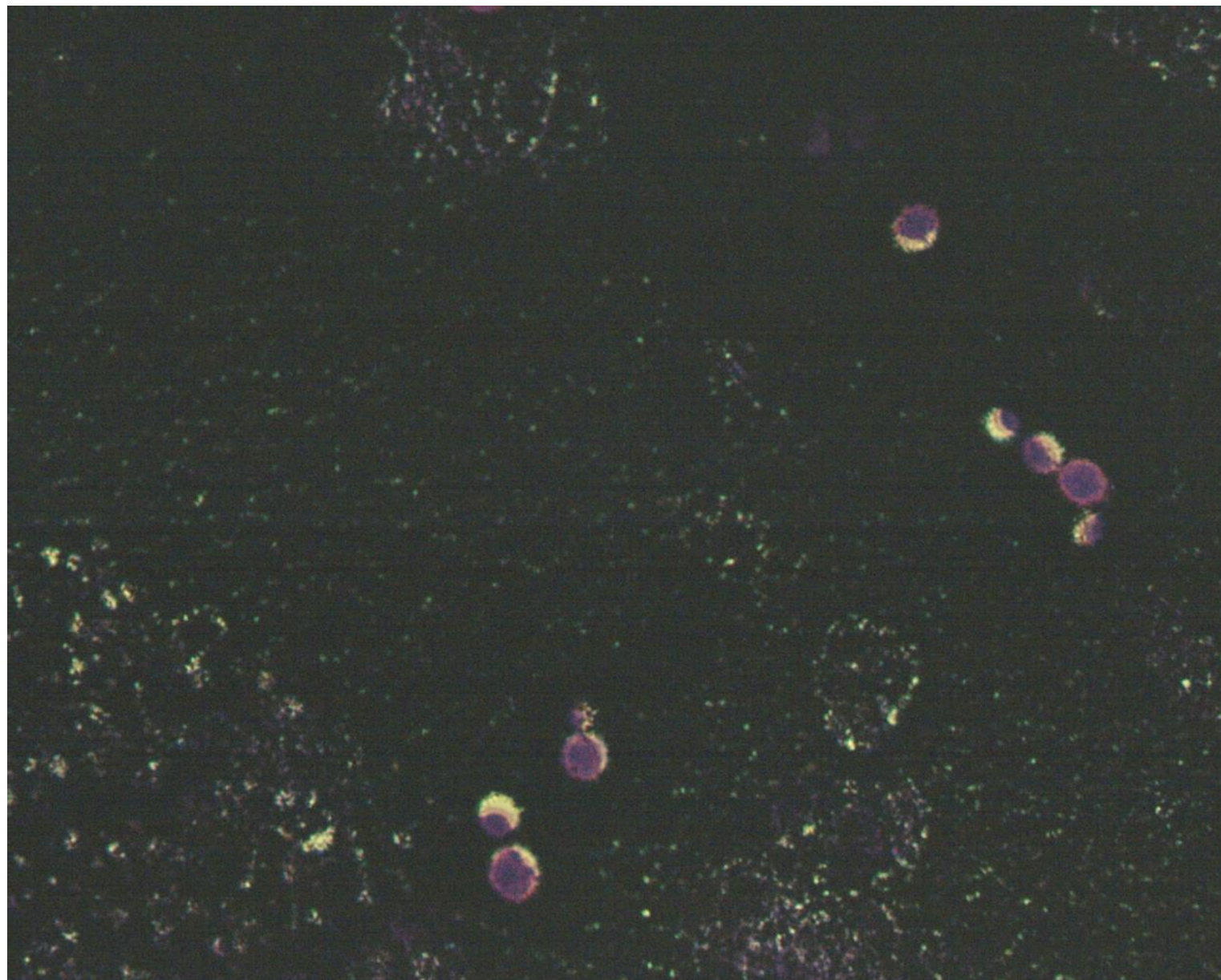
Cryptococcus neoformans

Specimen: blood culture

Patient: male, 37 years old

Dg.: meningitis in HIV/AIDS

Microscopy: capsules in Burri stain



Authors: Markéta Šolarová, Hana Nekvasilová



CHARLES UNIVERSITY
Second Faculty of Medicine

Slide No. 48

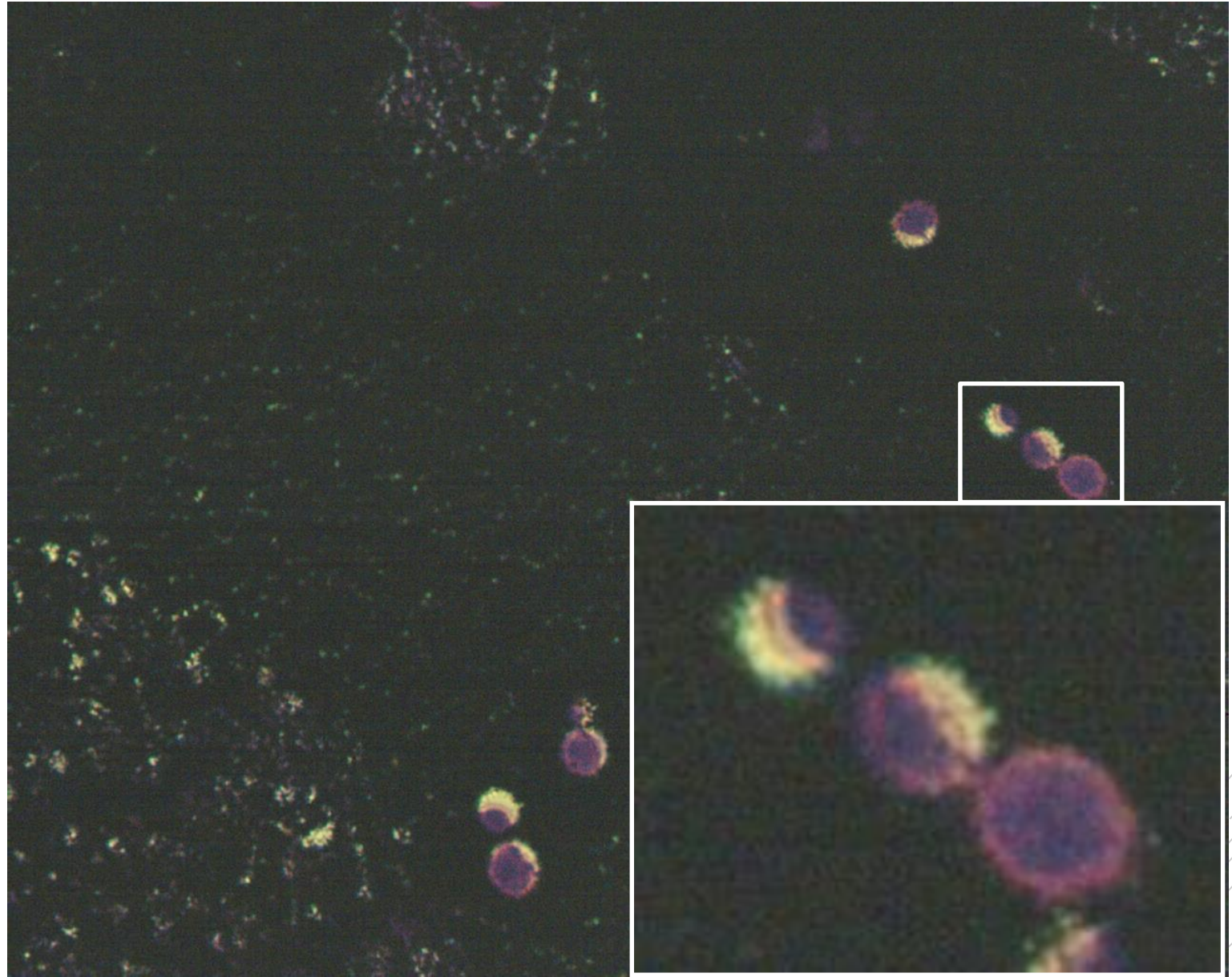
Cryptococcus neoformans

Specimen: blood culture

Patient: male, 37 years old

Dg.: meningitis in HIV/AIDS

Microscopy: capsules in Burri stain



Authors: Markéta Šolarová, Hana Nekvasilová



CHARLES UNIVERSITY
Second Faculty of Medicine

Slide No. 49

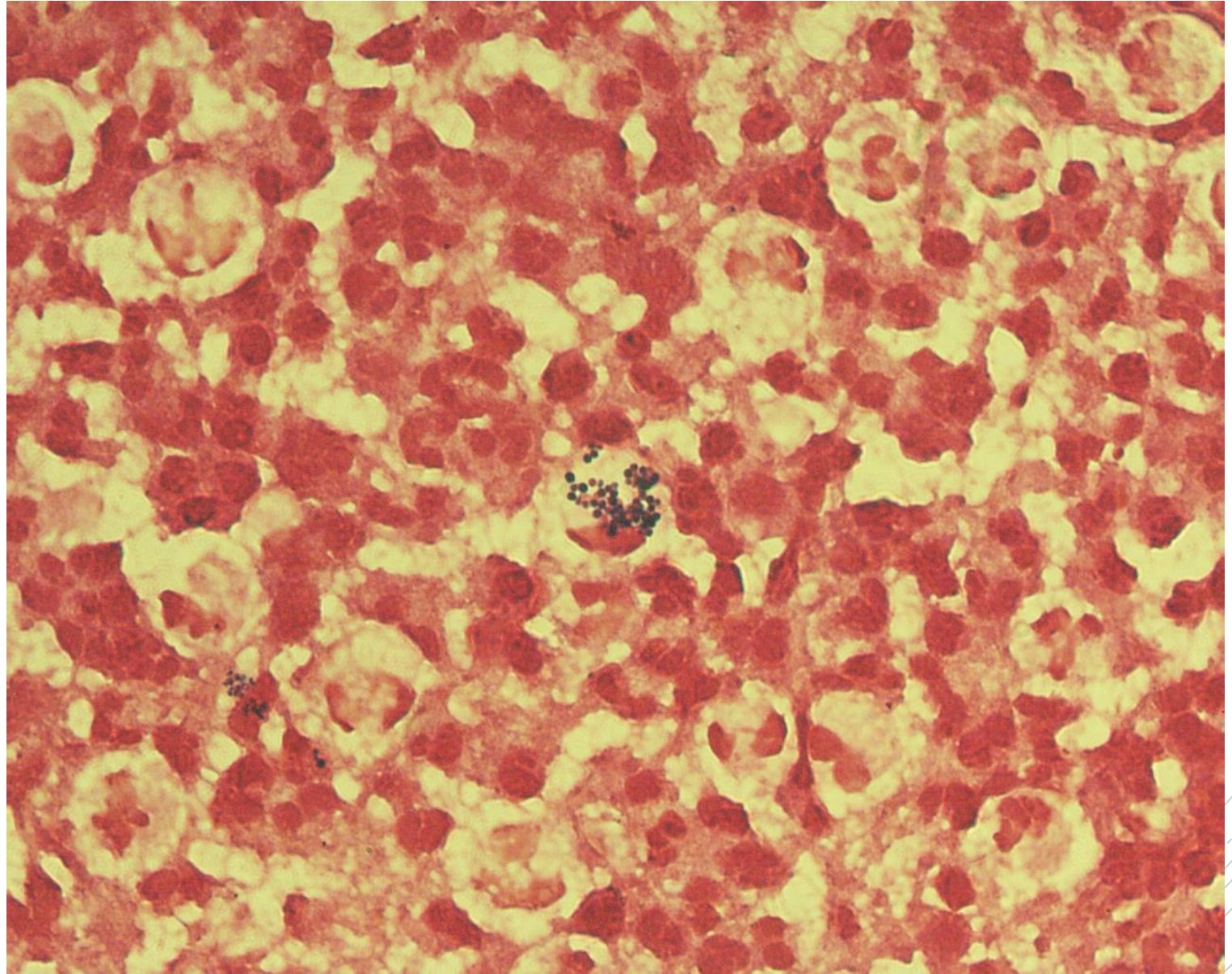
Staphylococcus aureus

Specimen: Pus/wound

Patient: female, 1 year old

Dg.: face lymph node inflammation

Microscopy: Gram-positive cocci
in clusters



Authors: MUDr. Petra Kabelíková, Sandra Opálková



CHARLES UNIVERSITY
Second Faculty of Medicine

Slide No. 49

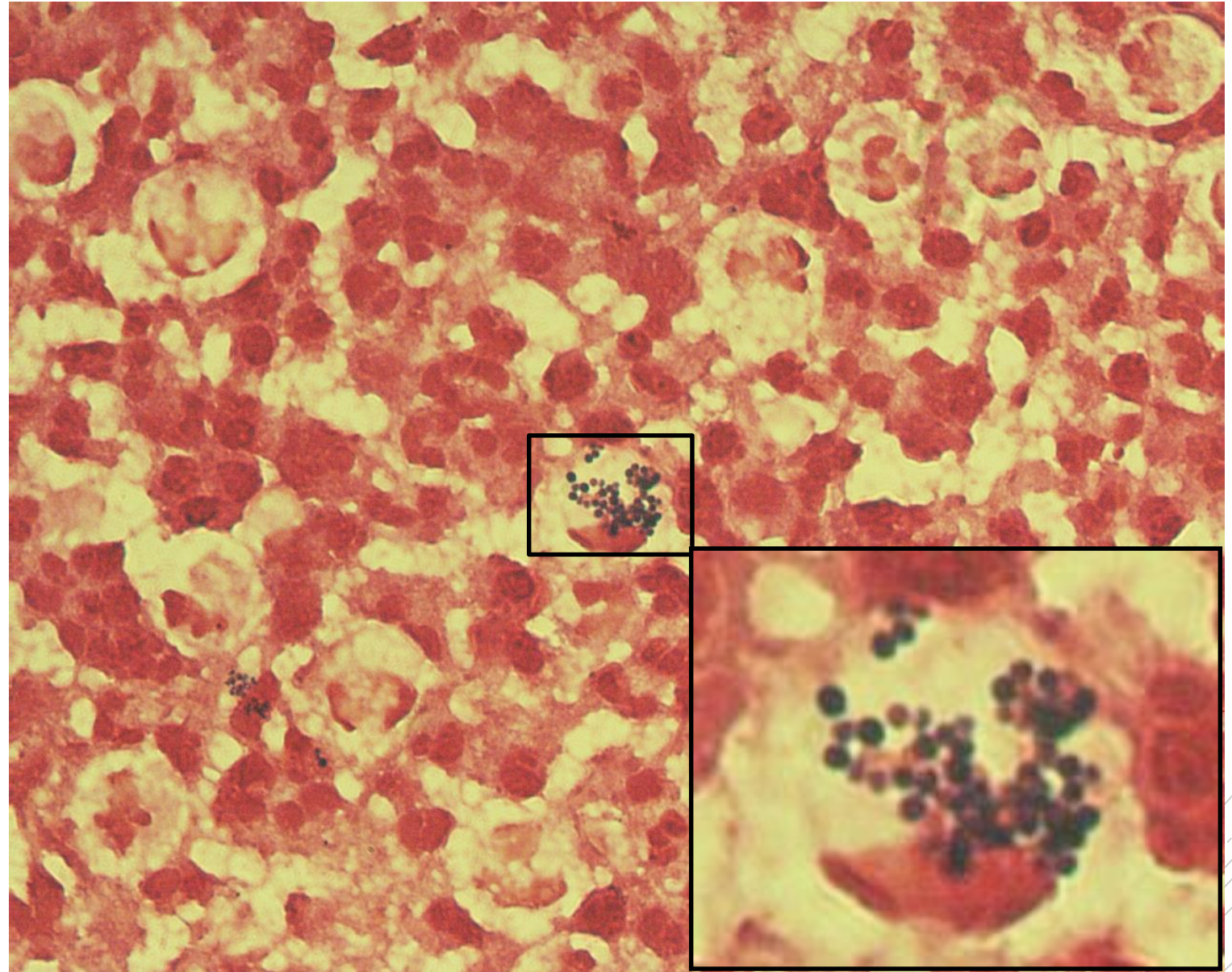
Staphylococcus aureus

Specimen: Pus/wound

Patient: female, 1 year old

Dg.: face lymph node inflammation

Microscopy: Gram-positive cocci
in clusters



Authors: MUDr. Petra Kabelíková, Sandra Opálková



CHARLES UNIVERSITY
Second Faculty of Medicine

Slide No. 50

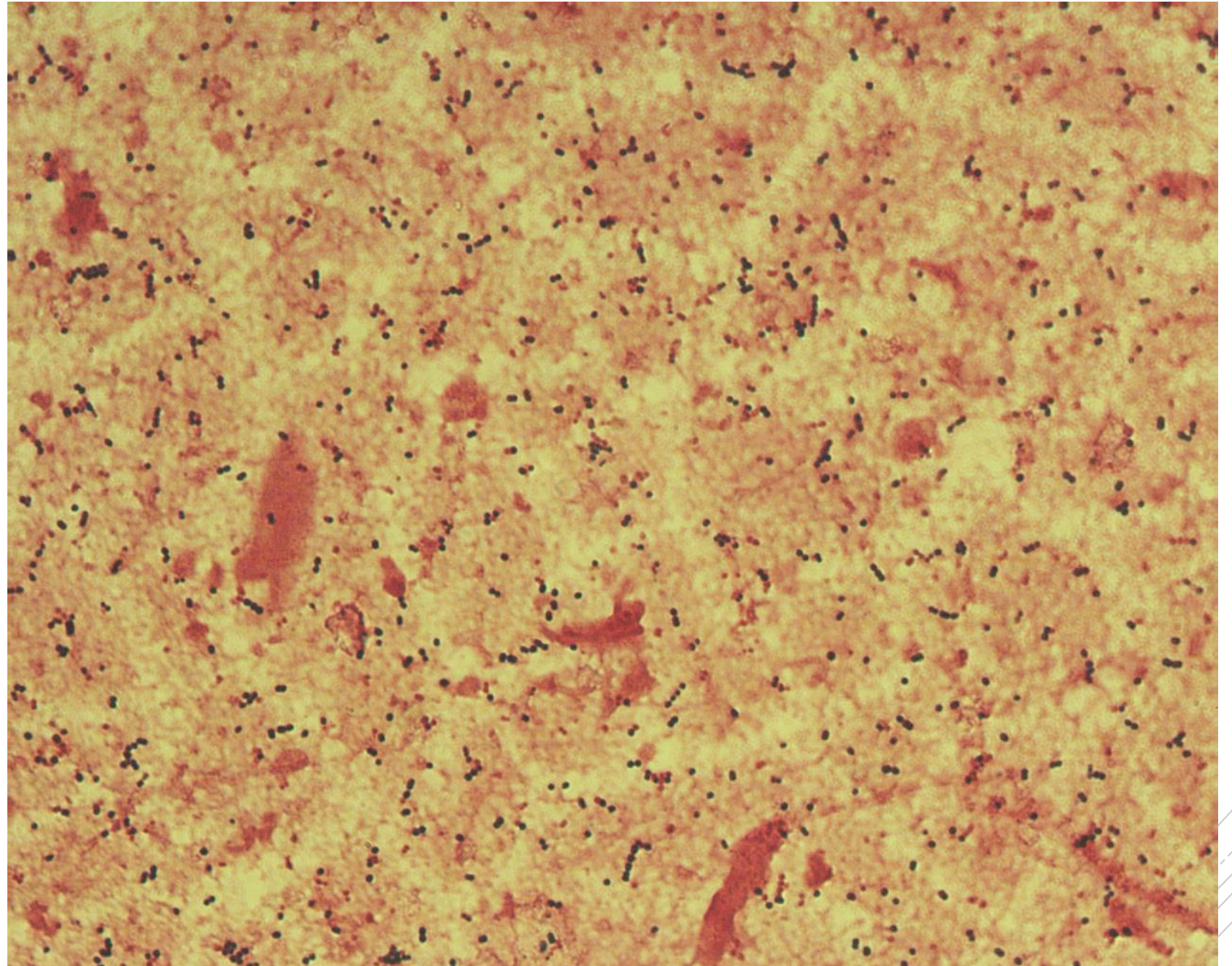
Streptococcus pyogenes

Specimen: muscle

Patient: male, 63 years old

Dg.: necrotizing fasciitis

Microscopy: Gram-positive cocci
in chains



Author: MUDr. Alena Pířová



CHARLES UNIVERSITY
Second Faculty of Medicine

Slide No. 50

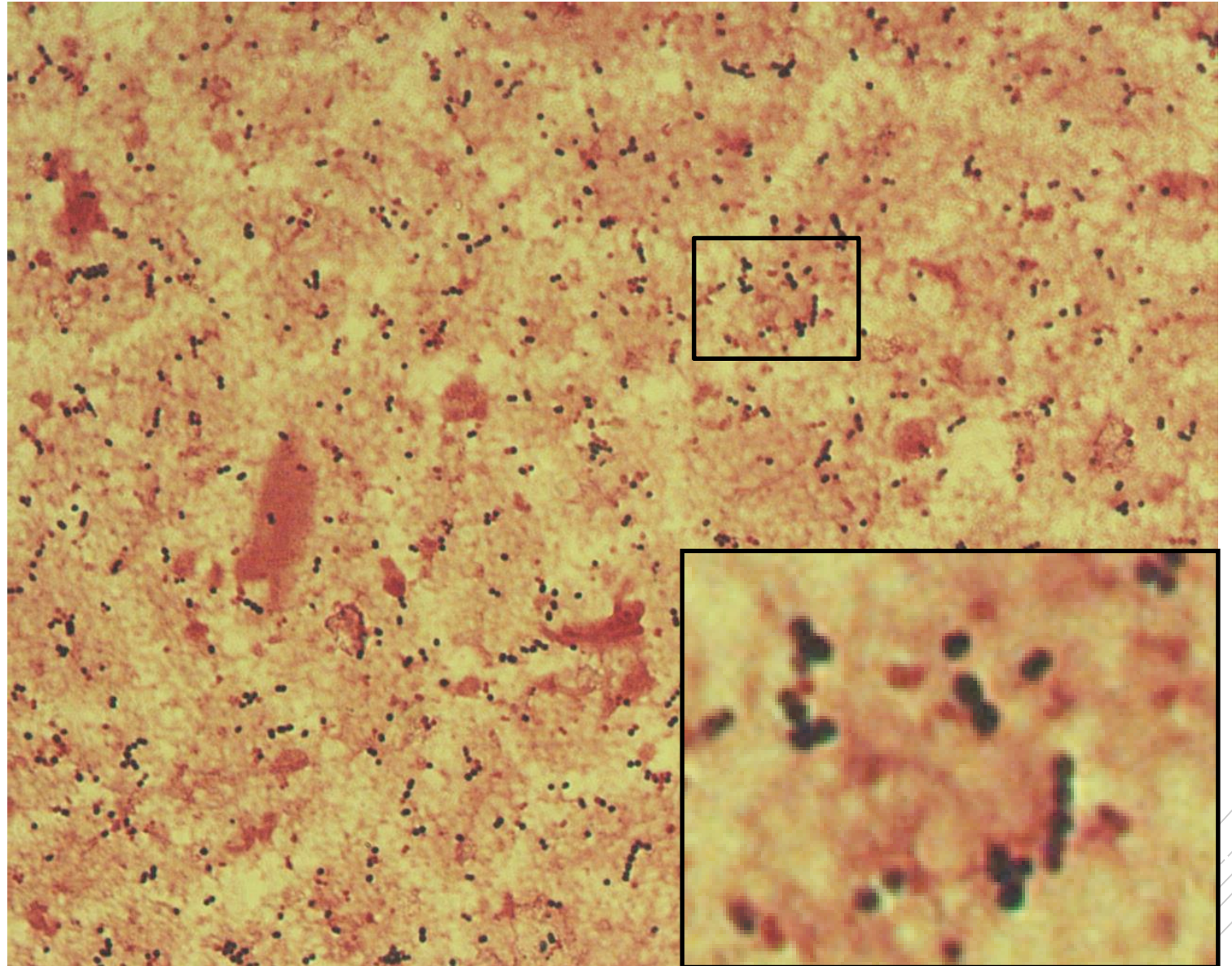
Streptococcus pyogenes

Specimen: muscle

Patient: male, 63 years old

Dg.: necrotizing fasciitis

Microscopy: Gram-positive cocci
in chains



Author: MUDr. Alena Píšová



CHARLES UNIVERSITY
Second Faculty of Medicine

Slide No. 51

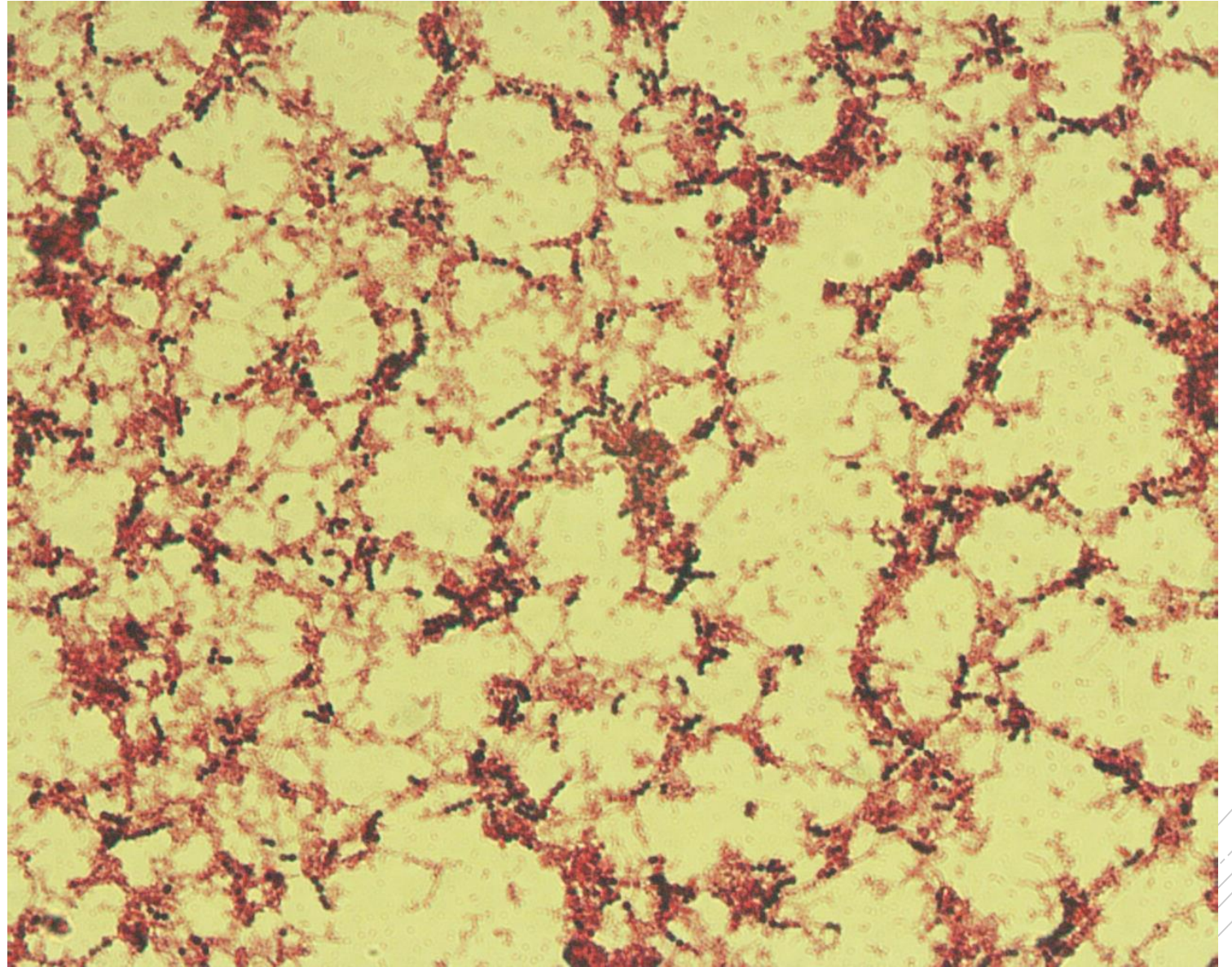
Streptococcus pyogenes

Specimen: blood culture

Patient: male, 63 years old

Dg.: sepsis

Microscopy: Gram-positive cocci
in chains



Authors: MUDr. Petra Kabelíková, Sandra Opálková



CHARLES UNIVERSITY
Second Faculty of Medicine

Slide No. 51

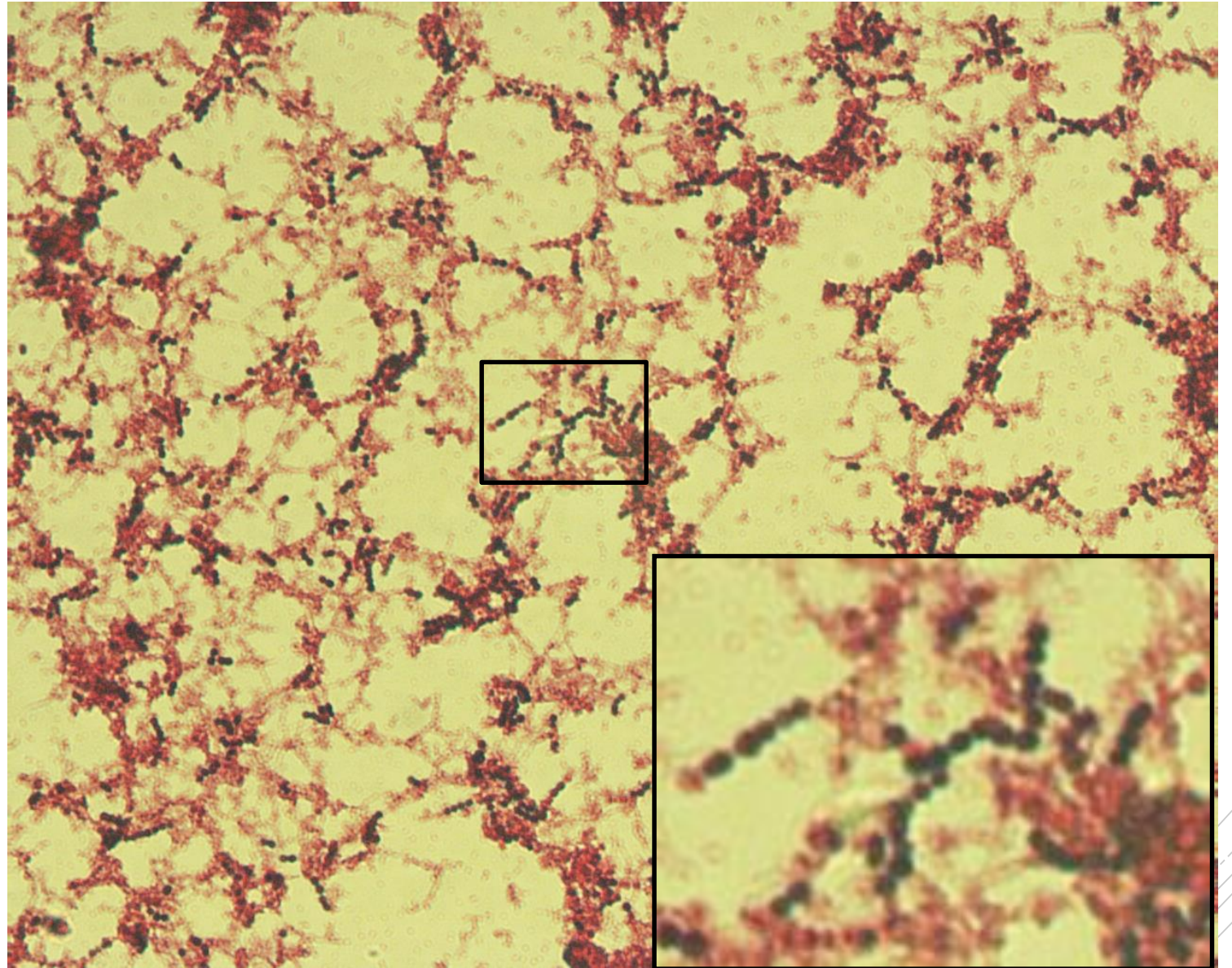
Streptococcus pyogenes

Specimen: blood culture

Patient: male, 63 years old

Dg.: sepsis

Microscopy: Gram-positive cocci
in chains



Authors: MUDr. Petra Kabelíková, Sandra Opálková



CHARLES UNIVERSITY
Second Faculty of Medicine

Slide No. 52

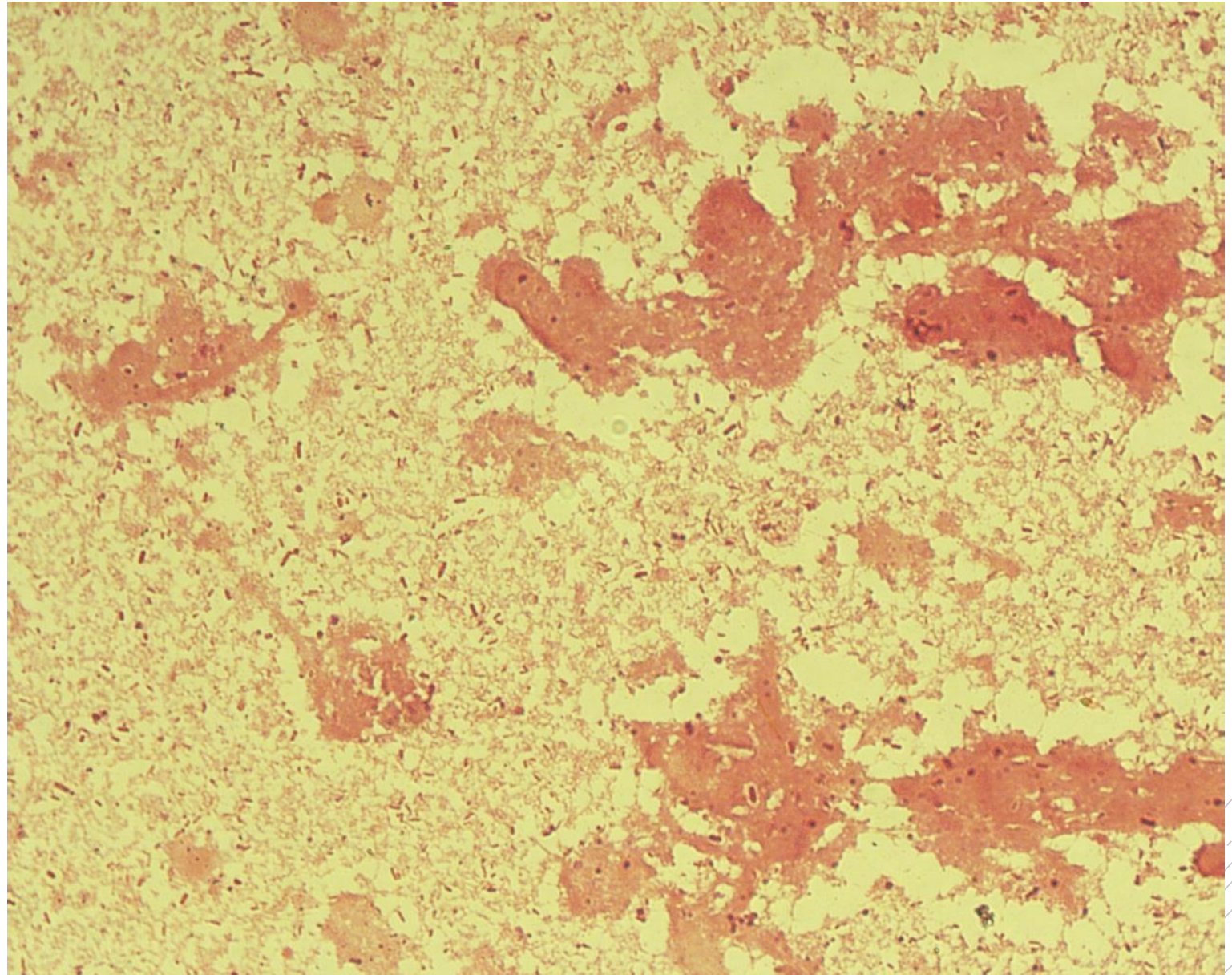
Bacteroides fragilis,
Klebsiella oxytoca,
Escherichia coli

Specimen: Pus

Patient: female, 44 years old

Dg.: liver abscess

Microscopy: Gram-negative rods



Author: MUDr. Alena Pířová



CHARLES UNIVERSITY
Second Faculty of Medicine

Slide No. 52

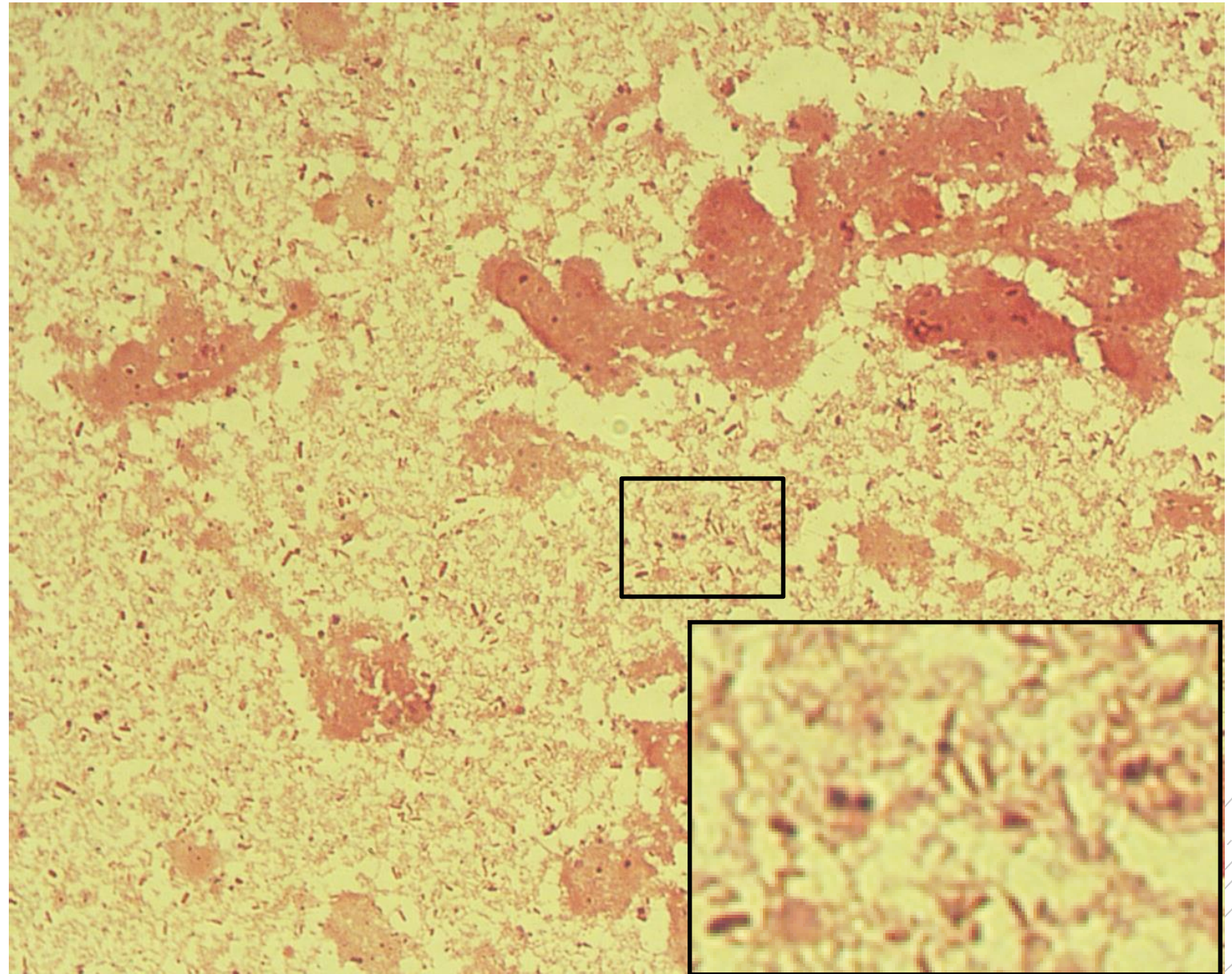
Bacteroides fragilis,
Klebsiella oxytoca,
Escherichia coli

Specimen: Pus

Patient: female, 44 years old

Dg.: liver abscess

Microscopy: Gram-negative rods



Author: MUDr. Alena Pířová



CHARLES UNIVERSITY
Second Faculty of Medicine

Slide No. 53

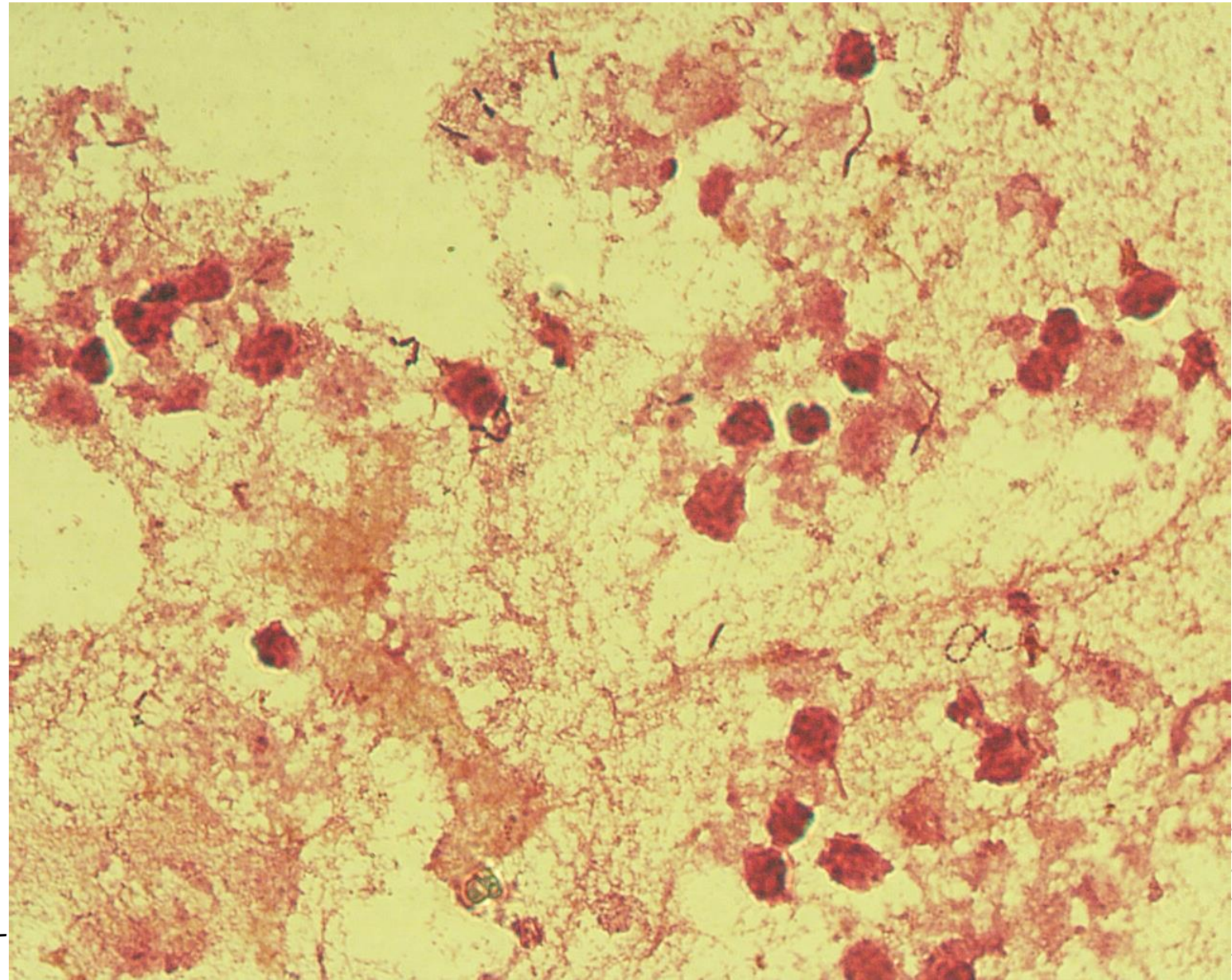
*Clostridium
perfringens,
Streptococcus
sanguis*

Specimen: pus

Patient: female, 71 years old

Dg.: liver abscess

Microscopy: Gram-positive rods, Gram-positive cocci in clusters



Author: MUDr. Alena Pířová



CHARLES UNIVERSITY
Second Faculty of Medicine

Slide No. 53

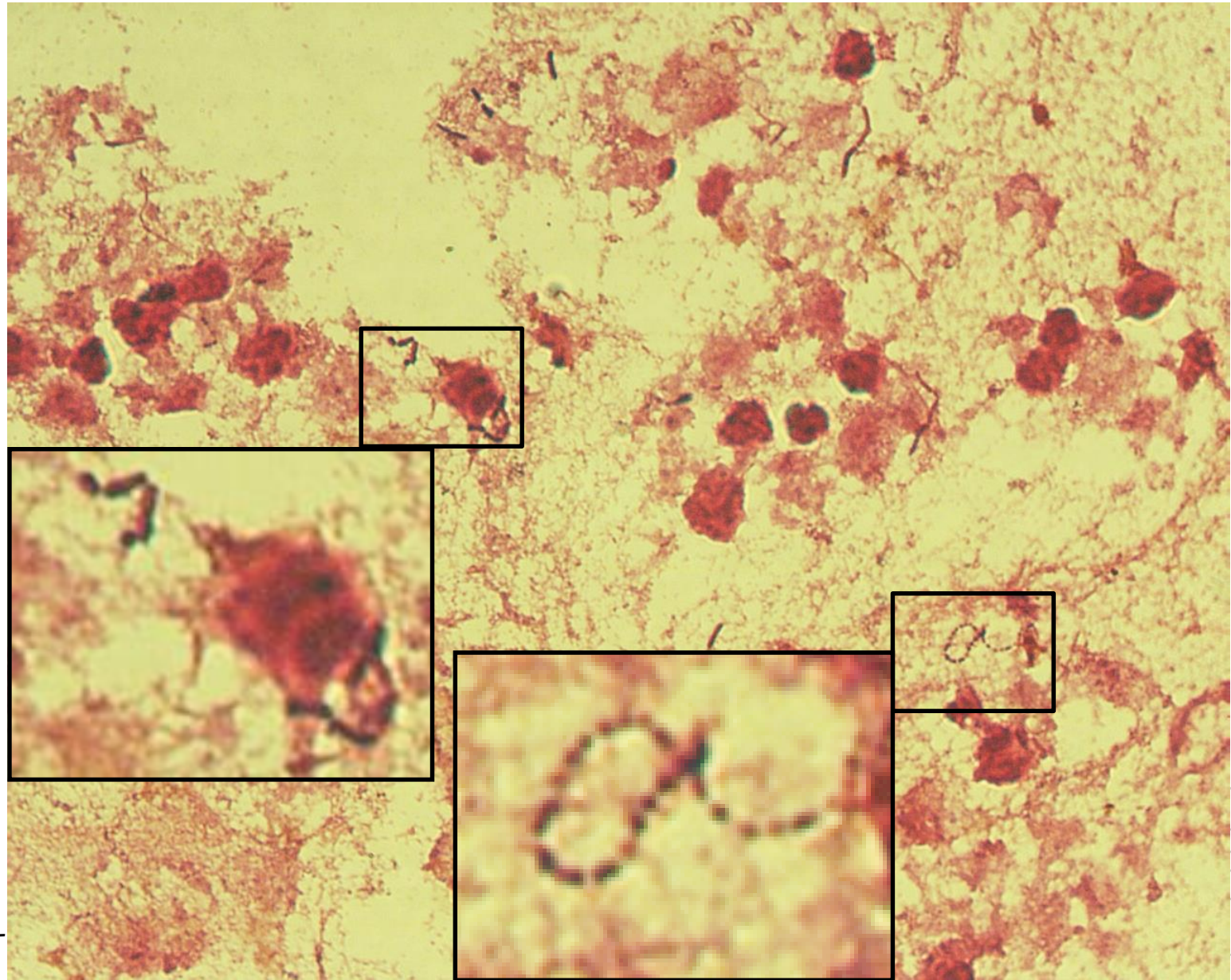
*Clostridium
perfringens,
Streptococcus
sanguis*

Specimen: pus

Patient: female, 71 years old

Dg.: liver abscess

Microscopy: Gram-positive rods, Gram-positive cocci in clusters



Author: MUDr. Alena Pířová



CHARLES UNIVERSITY
Second Faculty of Medicine

Slide No. 54

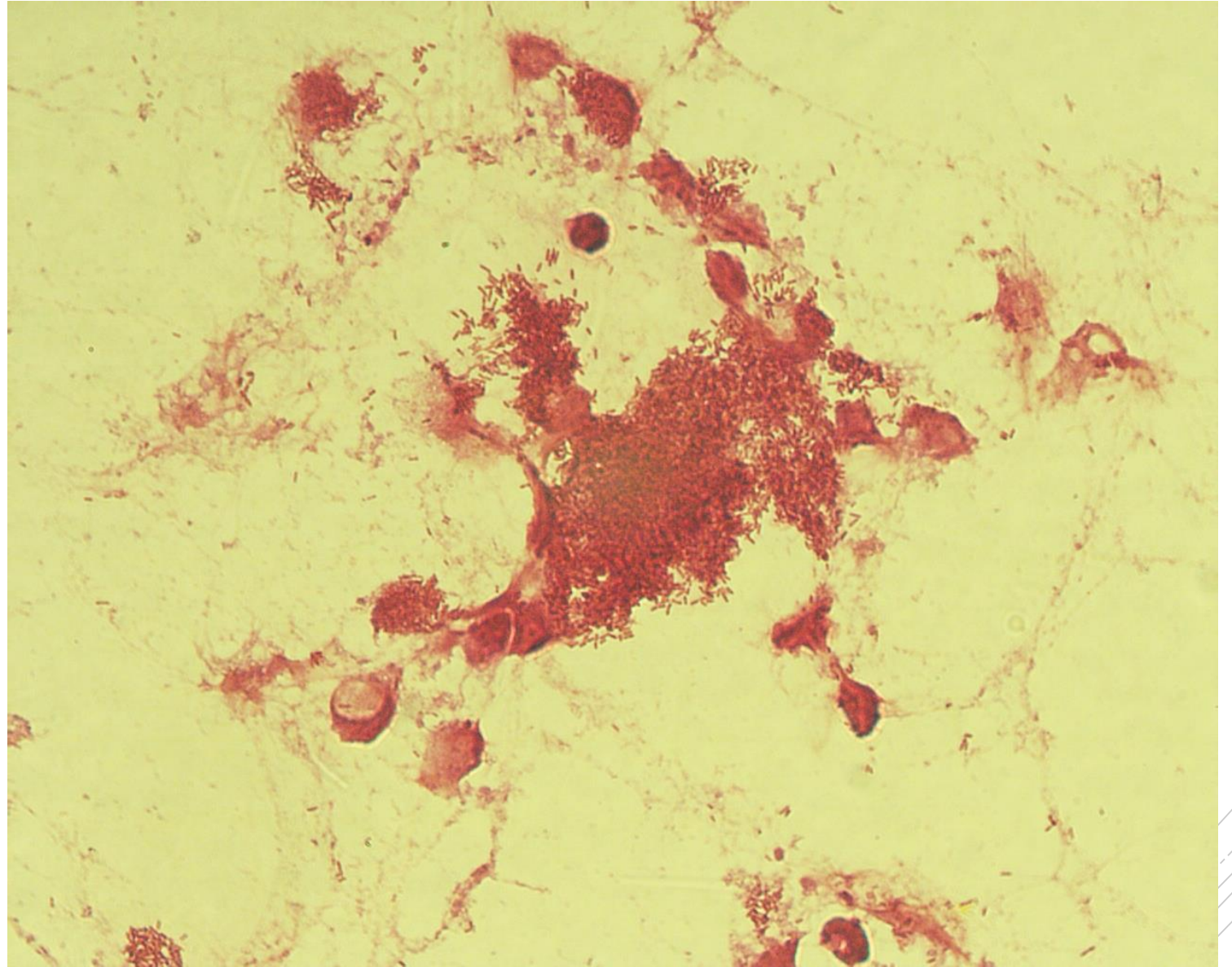
Stenotrophomonas maltophilia

Specimen: pus

Patient: male, 30 years old

Dg.: acute pancreatitis

Microscopy: Gram-negative rods



Author: MUDr. Alena Pířová



CHARLES UNIVERSITY
Second Faculty of Medicine

Slide No. 54

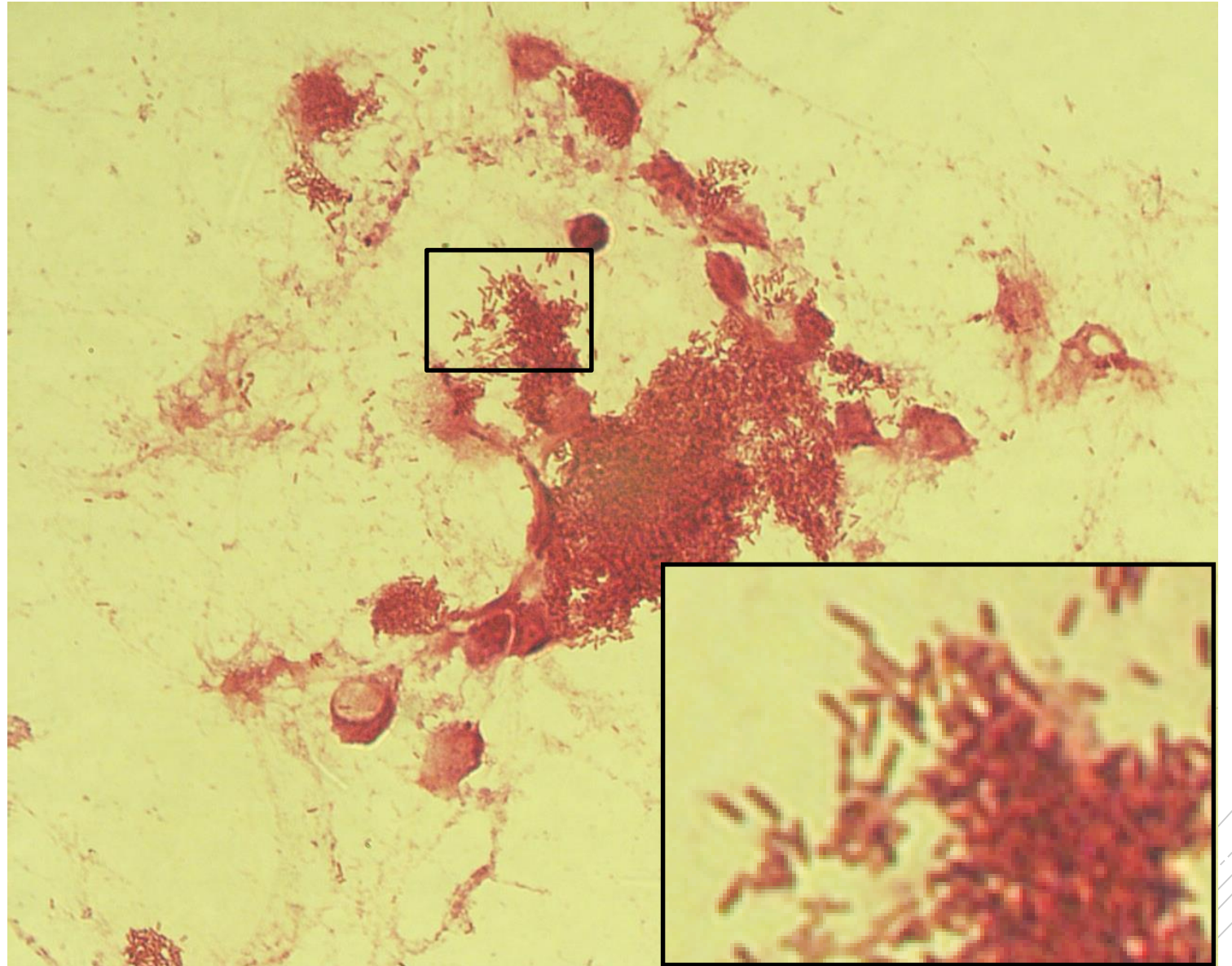
Stenotrophomonas maltophilia

Specimen: pus

Patient: male, 30 years old

Dg.: acute pancreatitis

Microscopy: Gram-negative rods



Author: MUDr. Alena Píšová



CHARLES UNIVERSITY
Second Faculty of Medicine

Slide No. 55

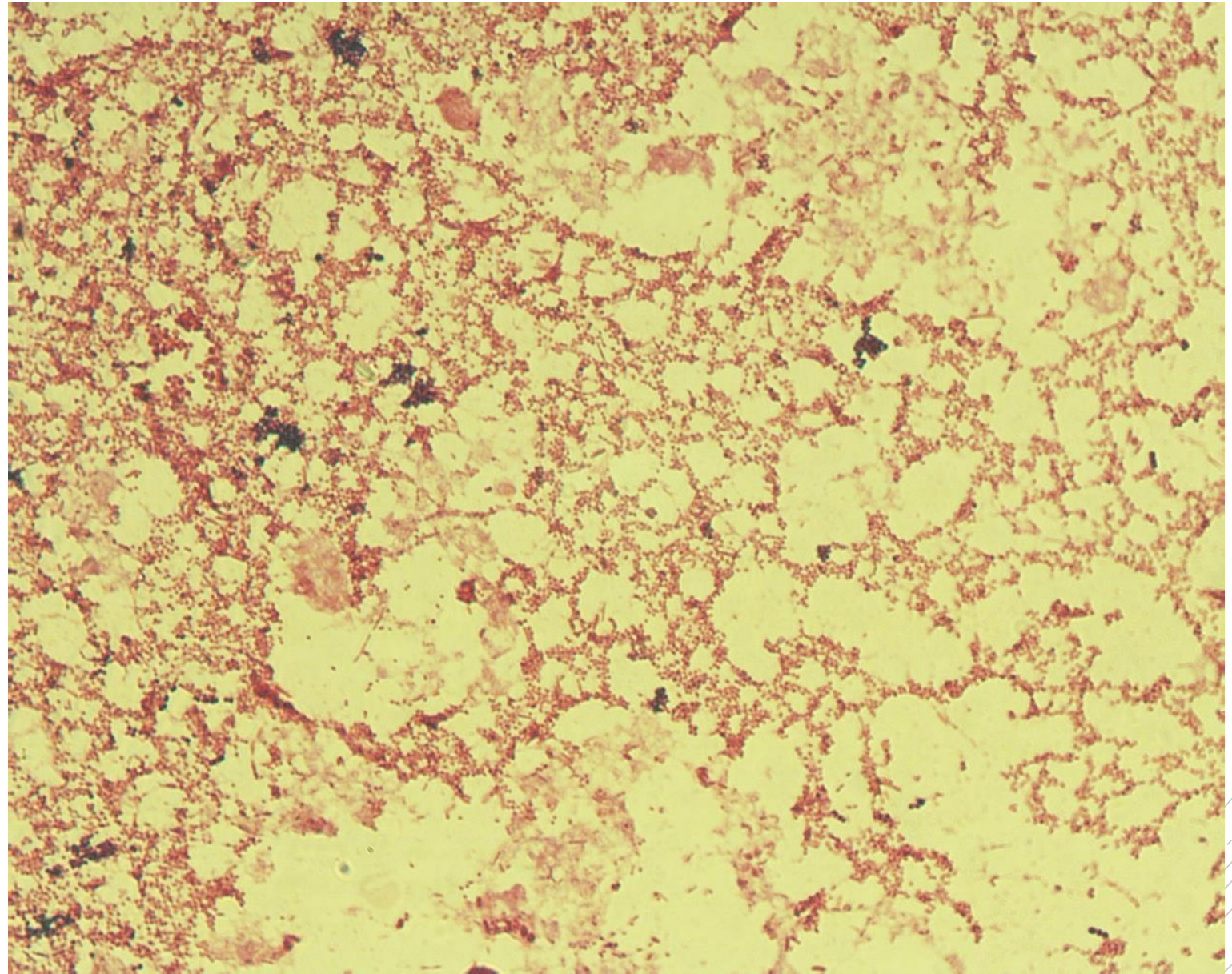
Proteus mirabilis,
Enterococcus
raffinosis

Specimen: Pus

Patient: female, 55 years old

Dg.: sepsis

Microscopy: Gram-negative rods,
Gram-positive cocci



Author: MUDr. Alena Pířová



CHARLES UNIVERSITY
Second Faculty of Medicine

Slide No. 55

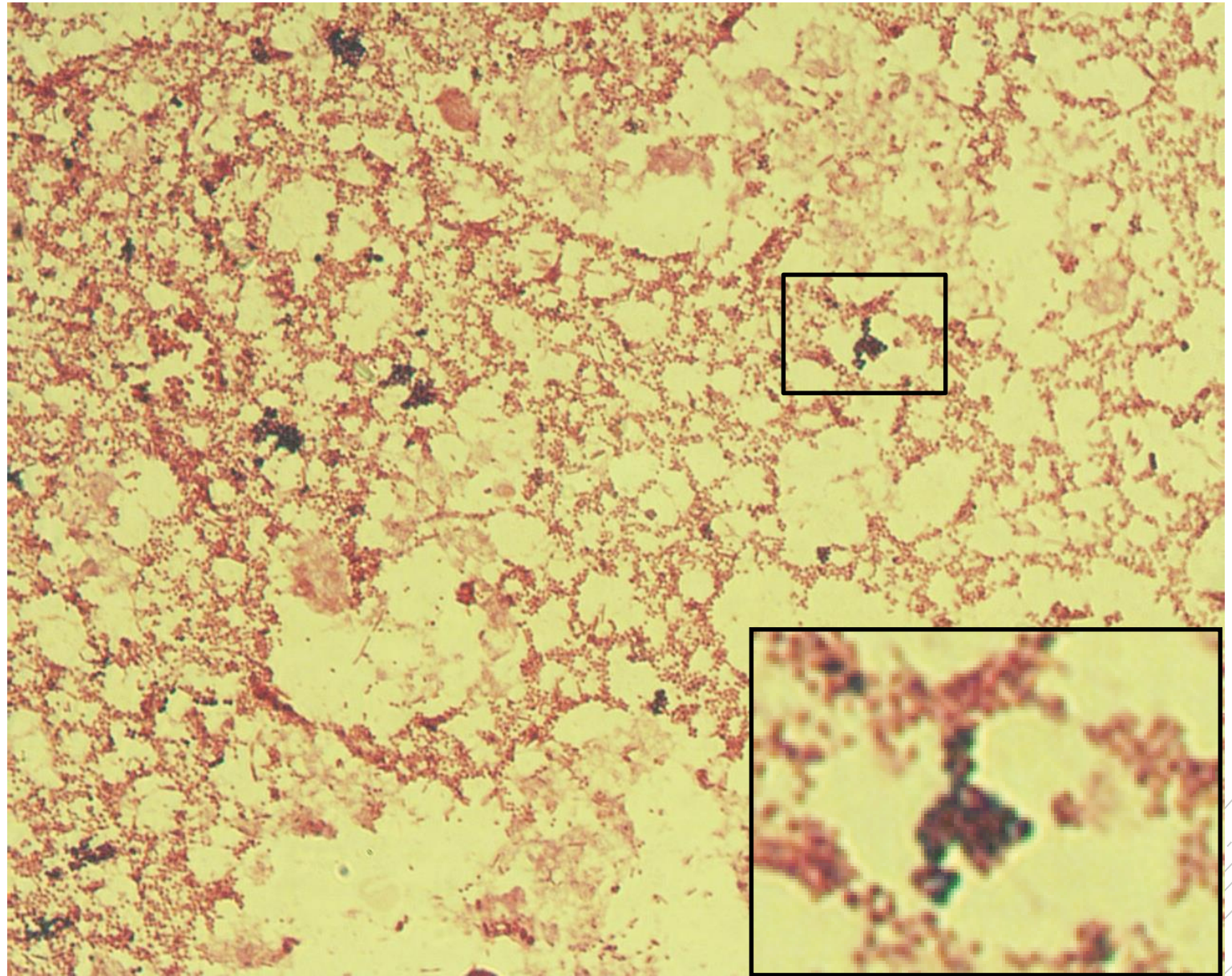
Proteus mirabilis,
Enterococcus
raffinosis

Specimen: Pus

Patient: female, 55 years old

Dg.: sepsis

Microscopy: Gram-negative rods,
Gram-positive cocci



Author: MUDr. Alena Pířová



CHARLES UNIVERSITY
Second Faculty of Medicine

Slide No. 56

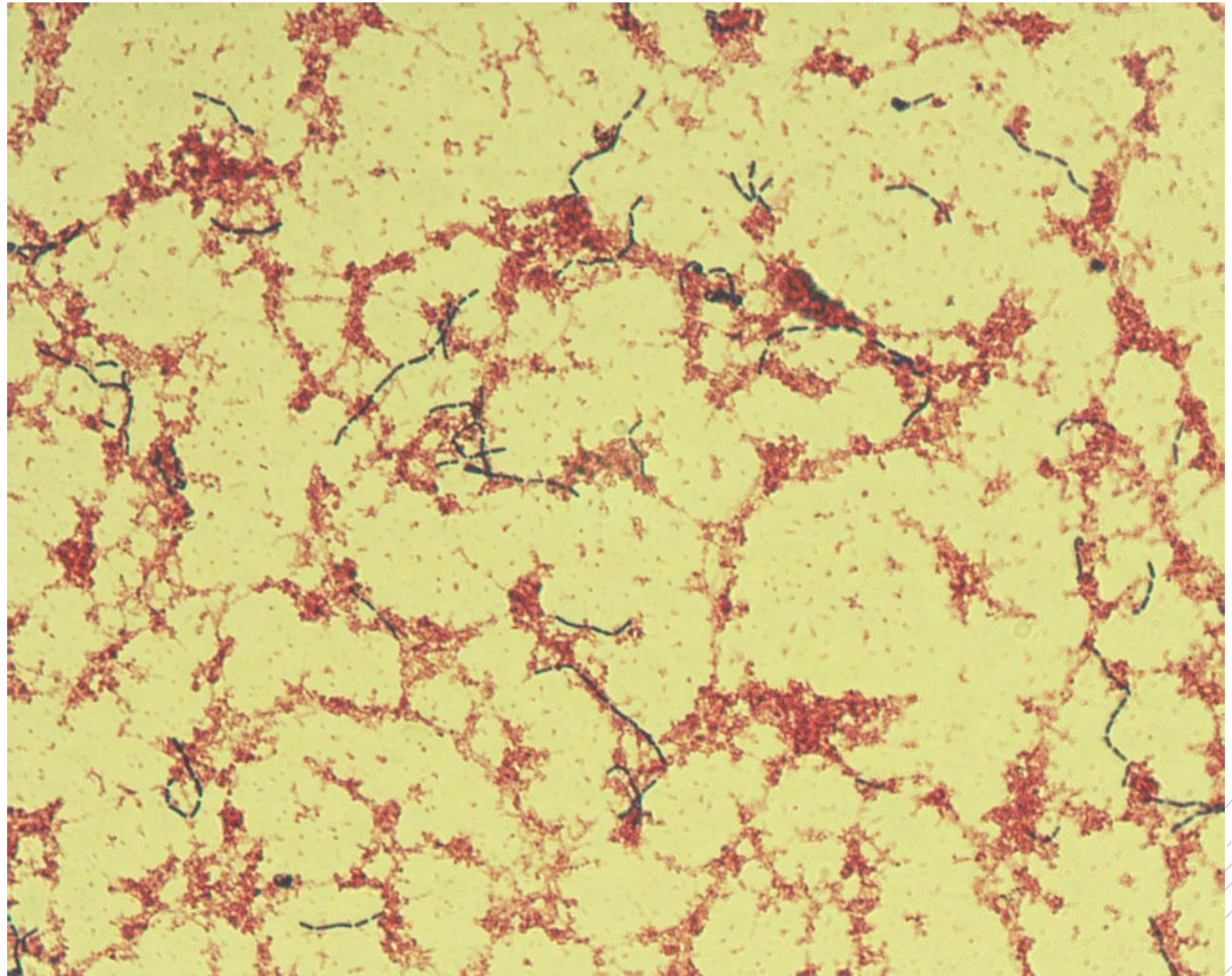
Lactobacillus rhamnosus

Specimen: blood culture

Patient: male, 67 years old

Dg.: acute pancreatitis

Microscopy: thin Gram-positive rods



Author: MUDr. Petra Kabelíková, Sandra Opálková



CHARLES UNIVERSITY
Second Faculty of Medicine

Slide No. 56a

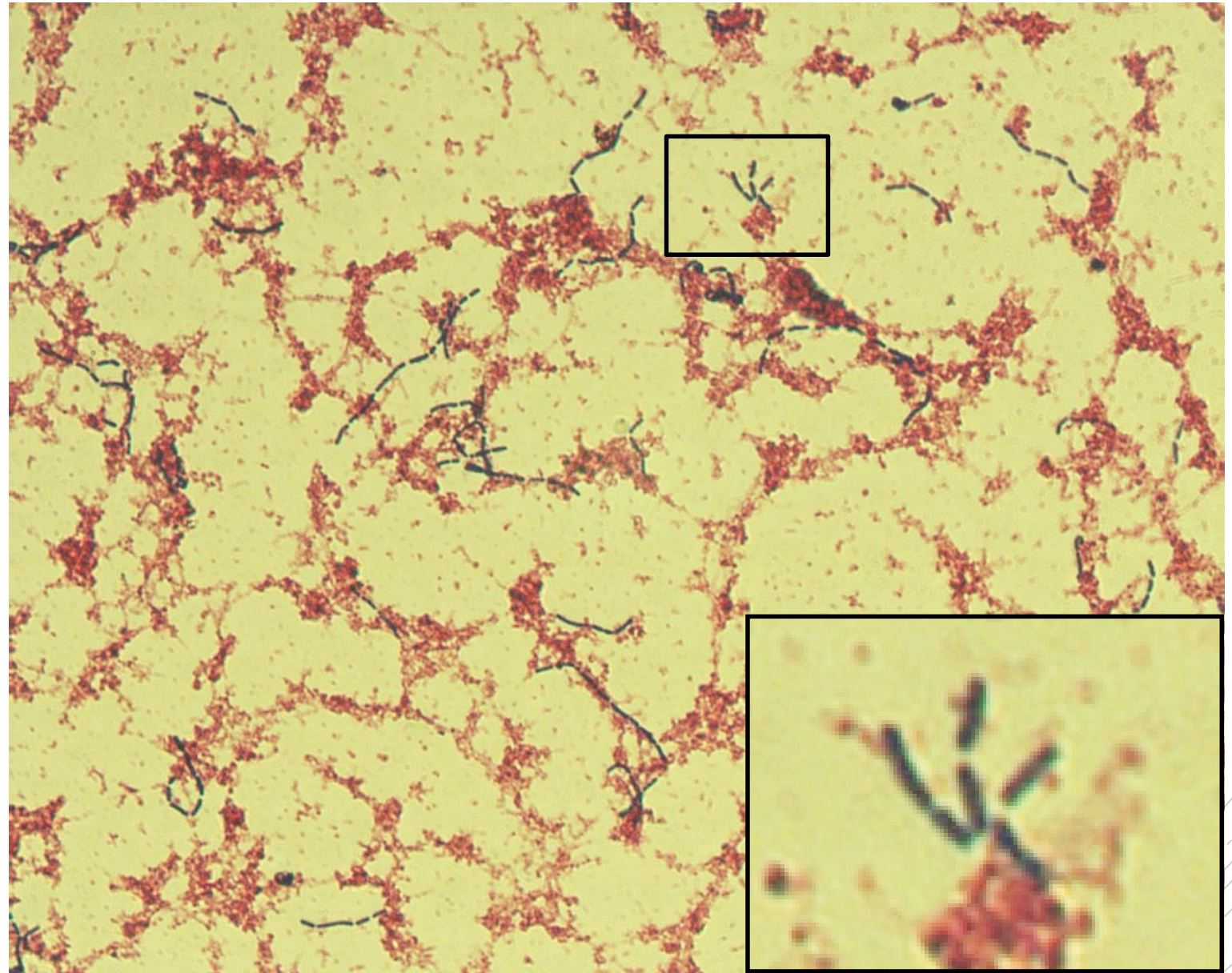
Lactobacillus rhamnosus

Specimen: blood culture

Patient: male, 67 years old

Dg.: acute pancreatitis

Microscopy: thin Gram-positive rods



Author: MUDr. Petra Kabelíková, Sandra Opálková



CHARLES UNIVERSITY
Second Faculty of Medicine

Slide No. 57

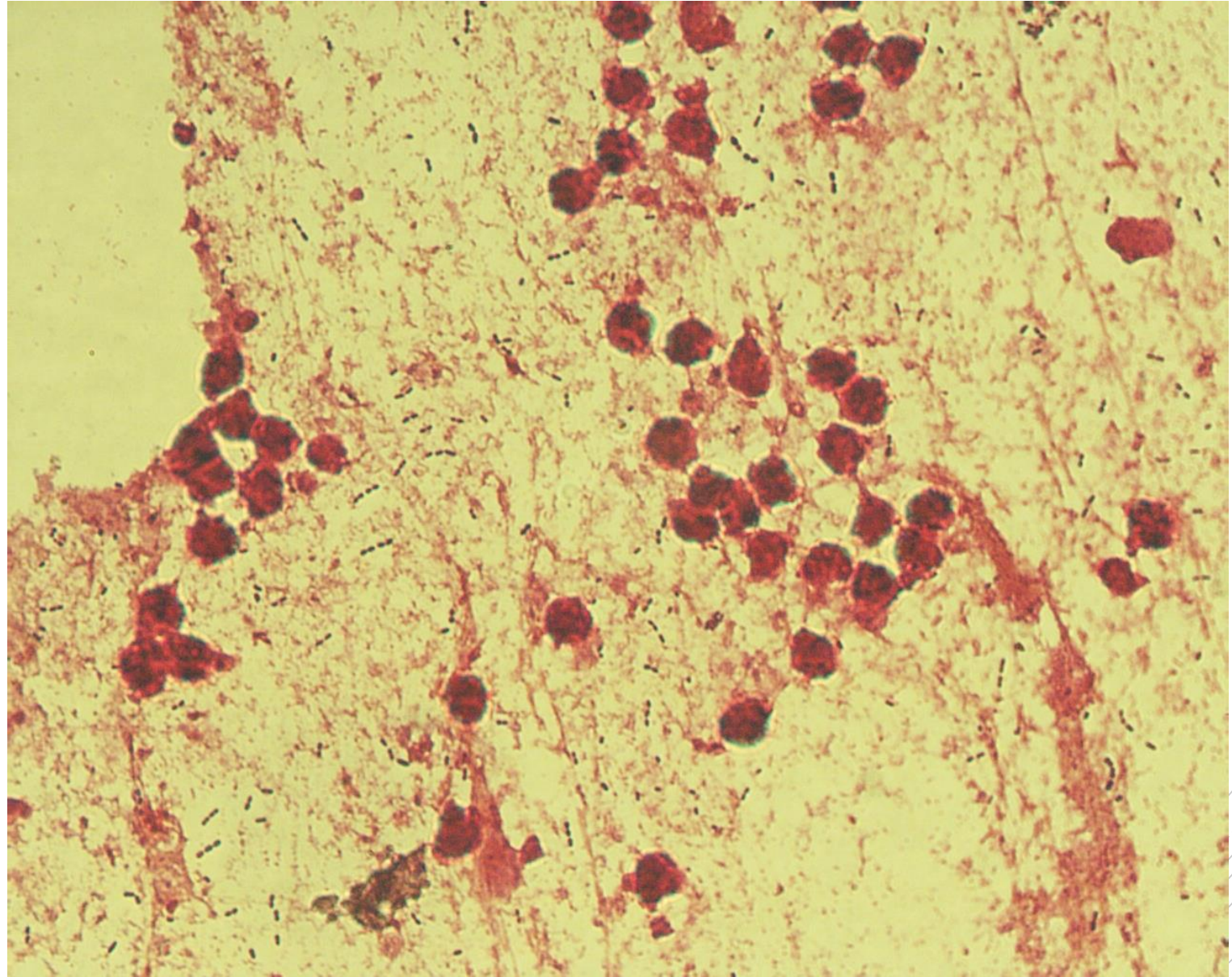
Streptococcus pneumoniae

Specimen: sputum

Patient: female, 16 years old

Dg.: purulent bronchitis

Microscopy: Gram-positive diplococci



Author: MUDr. Lenka Tritová



CHARLES UNIVERSITY
Second Faculty of Medicine

Slide No. 57

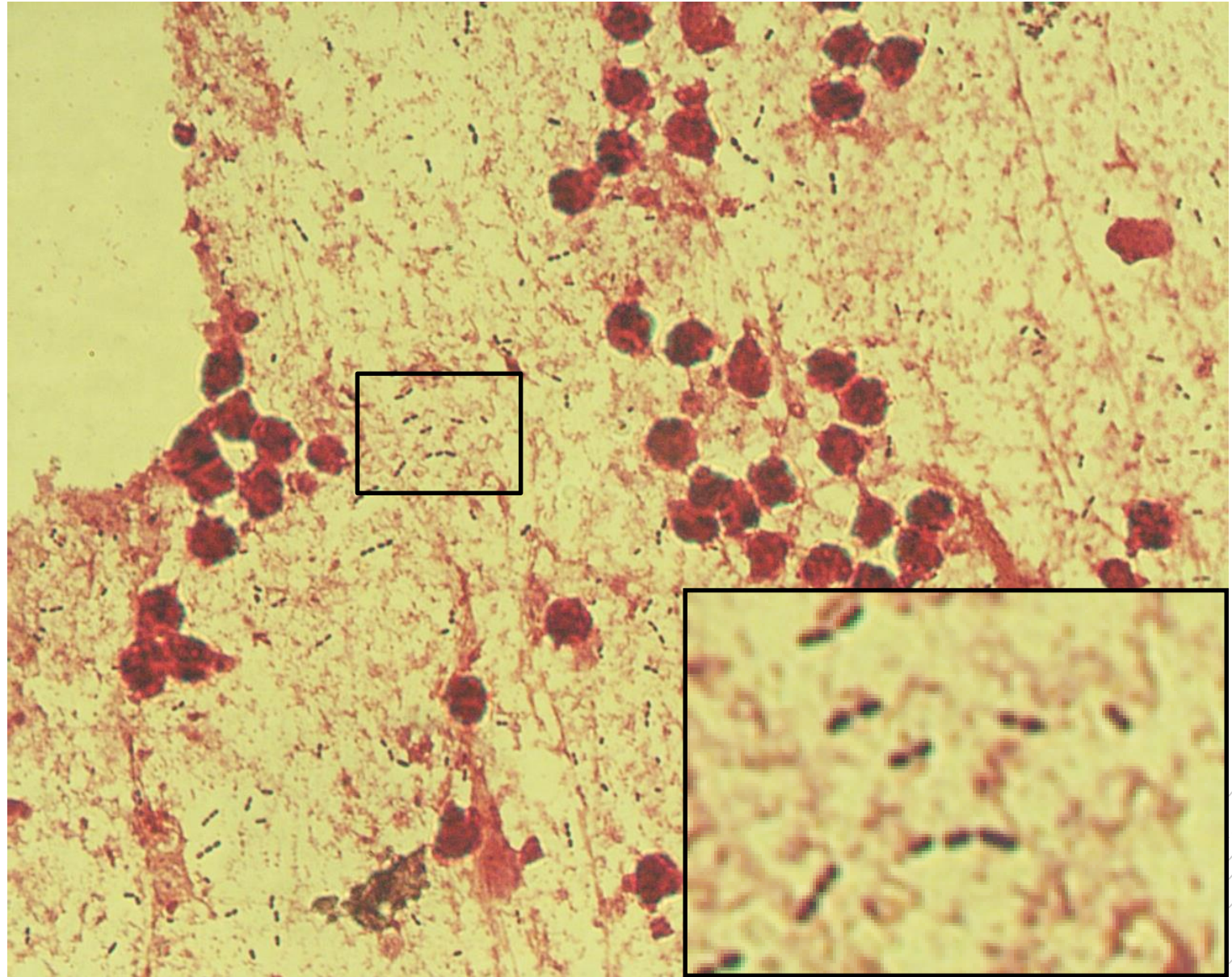
Streptococcus pneumoniae

Specimen: sputum

Patient: female, 16 years old

Dg.: purulent bronchitis

Microscopy: Gram-positive diplococci



Author: MUDr. Lenka Tritová



CHARLES UNIVERSITY
Second Faculty of Medicine

Slide No. 58

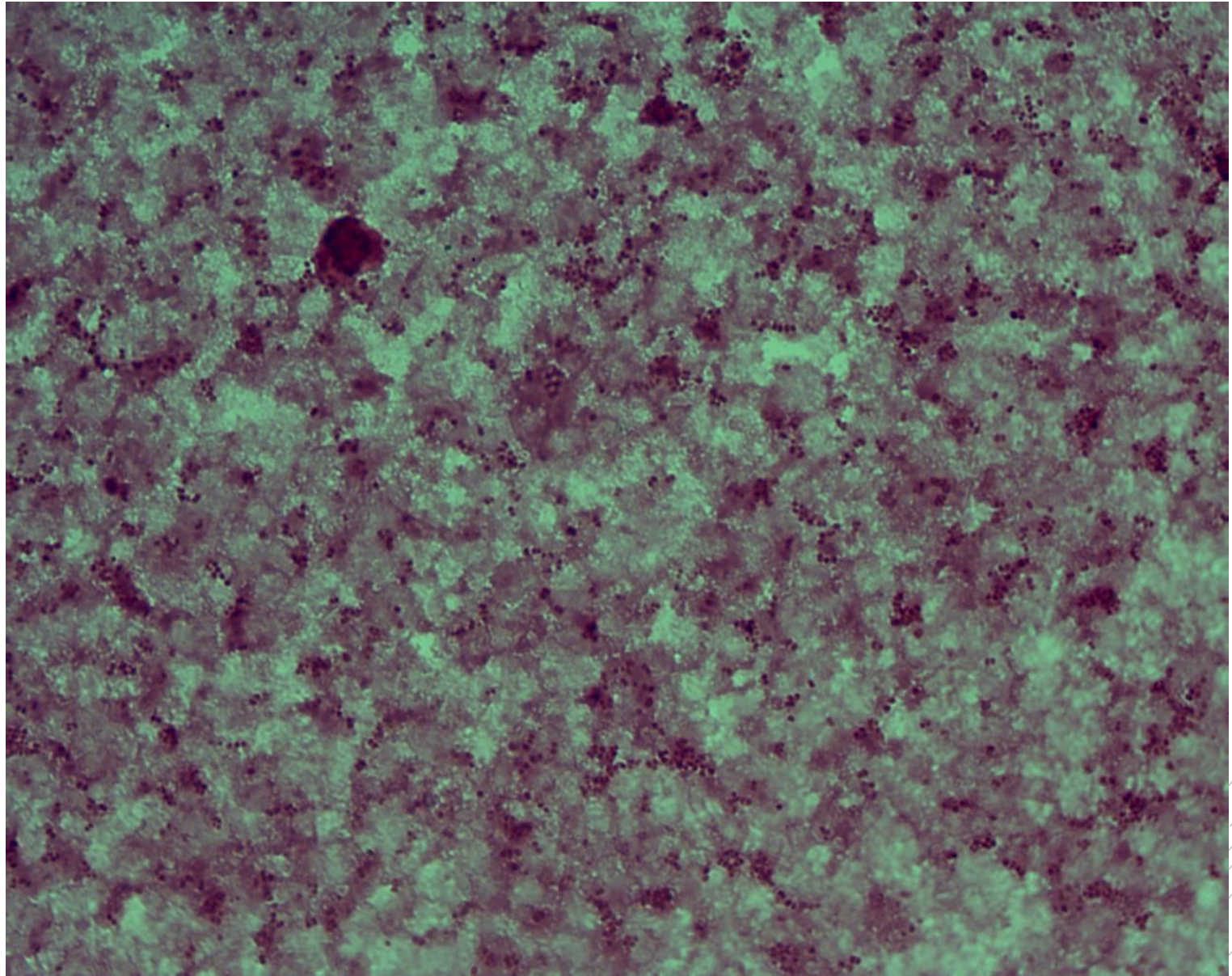
Neisseria meningitidis

Specimen: blood culture

Patient: male, 52 years old

Dg.: purulent meningitis

Microscopy: Gram-negative diplococci



Author: MUDr. Petra Kabelíková, Sandra Opálková



CHARLES UNIVERSITY
Second Faculty of Medicine

Slide No. 58


Neisseria meningitidis

Specimen: blood culture

Patient: male, 52 years old

Dg.: purulent meningitis

Microscopy: Gram-negative diplococci



Author: MUDr. Petra Kabelíková, Sandra Opálková



CHARLES UNIVERSITY
Second Faculty of Medicine

Slide No. 59

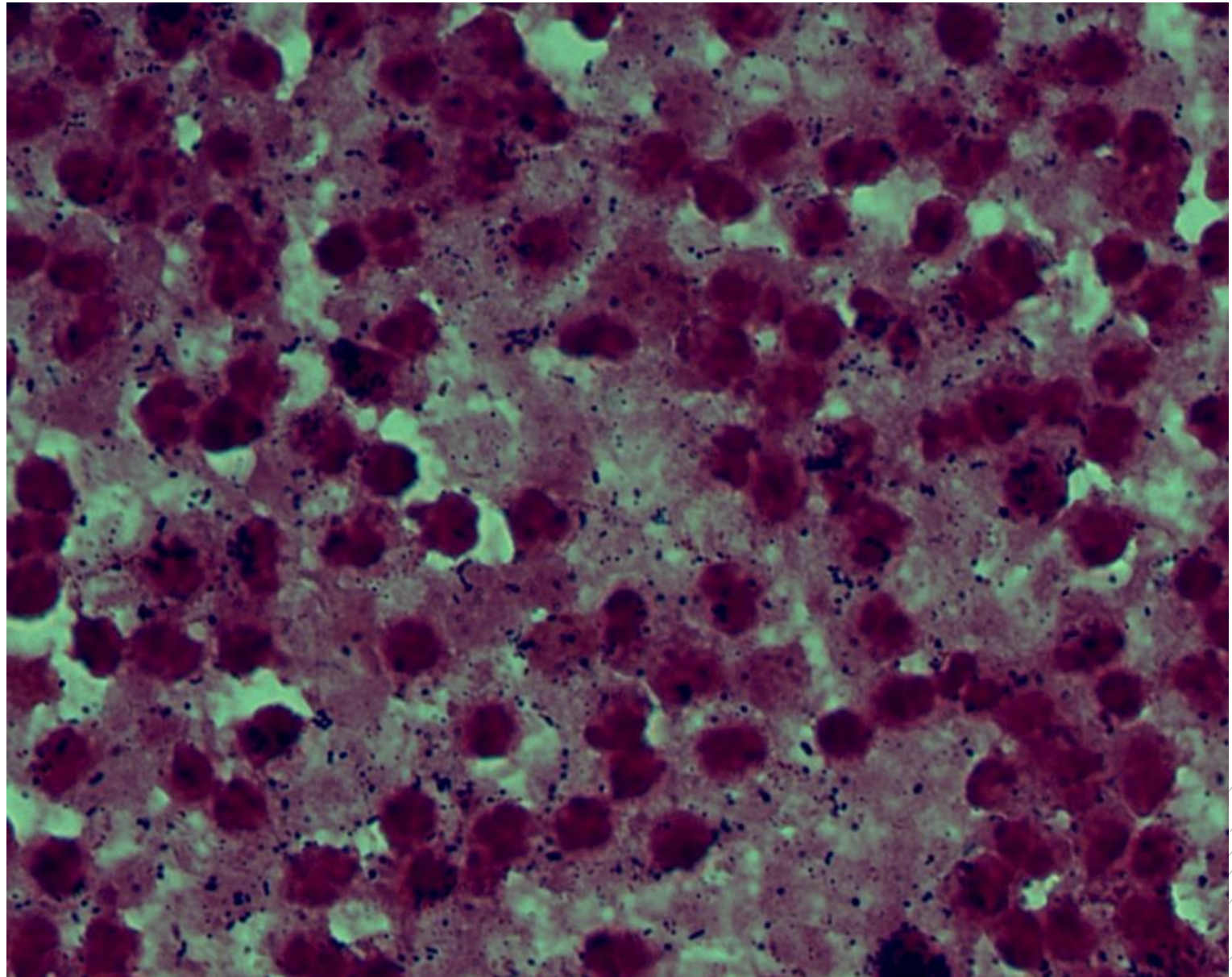
Streptococcus constellatus

Specimen: pus

Patient: female, 19 years old

Dg.: purulent otitis media

Microscopy: Gram-positive cocci



Author: MUDr. Lenka Tritová



CHARLES UNIVERSITY
Second Faculty of Medicine

Slide No. 59

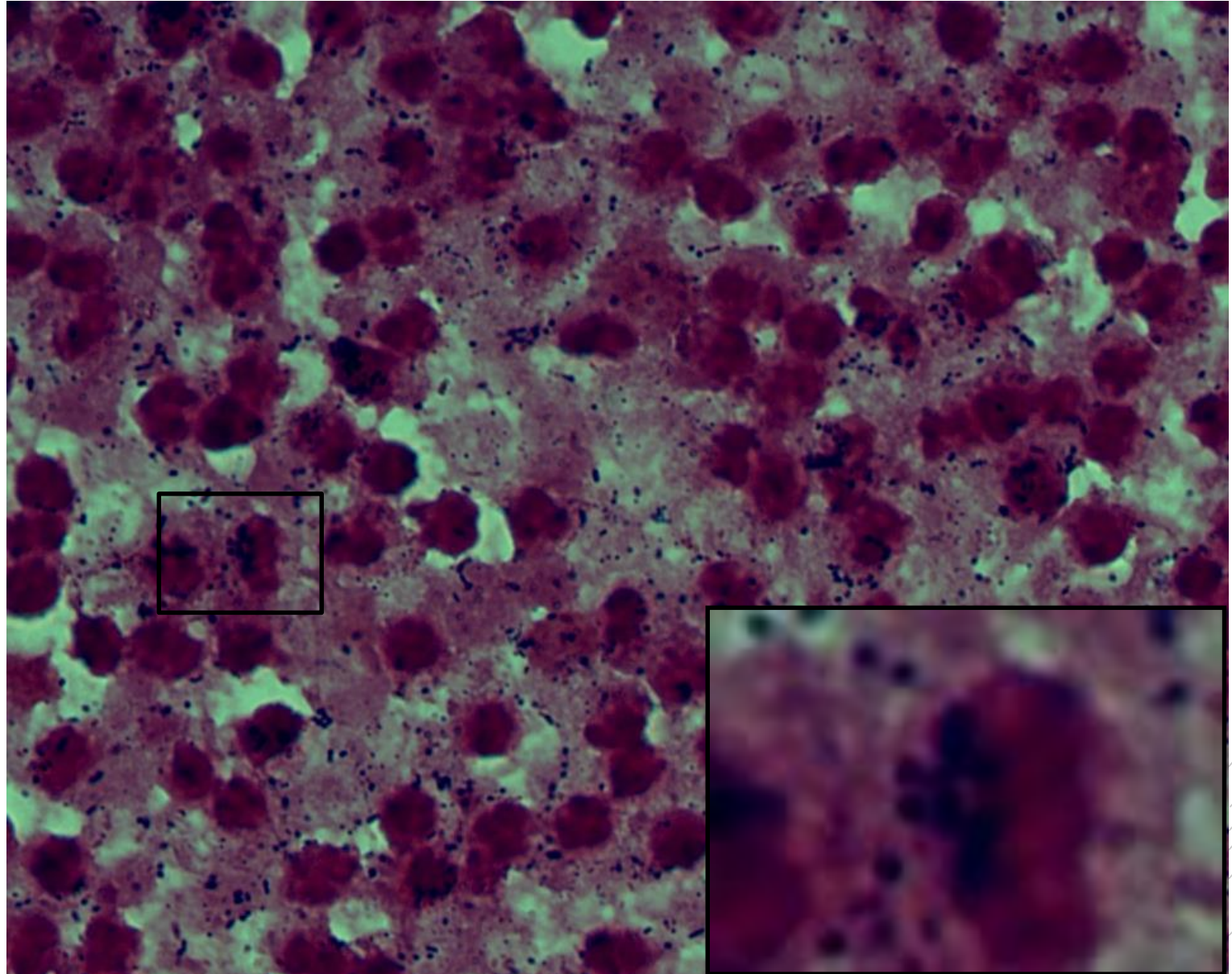
Streptococcus constellatus

Specimen: pus

Patient: female, 19 years old

Dg.: purulent otitis media

Microscopy: Gram-positive cocci



Author: MUDr. Lenka Tritová



CHARLES UNIVERSITY
Second Faculty of Medicine

Slide No. 60

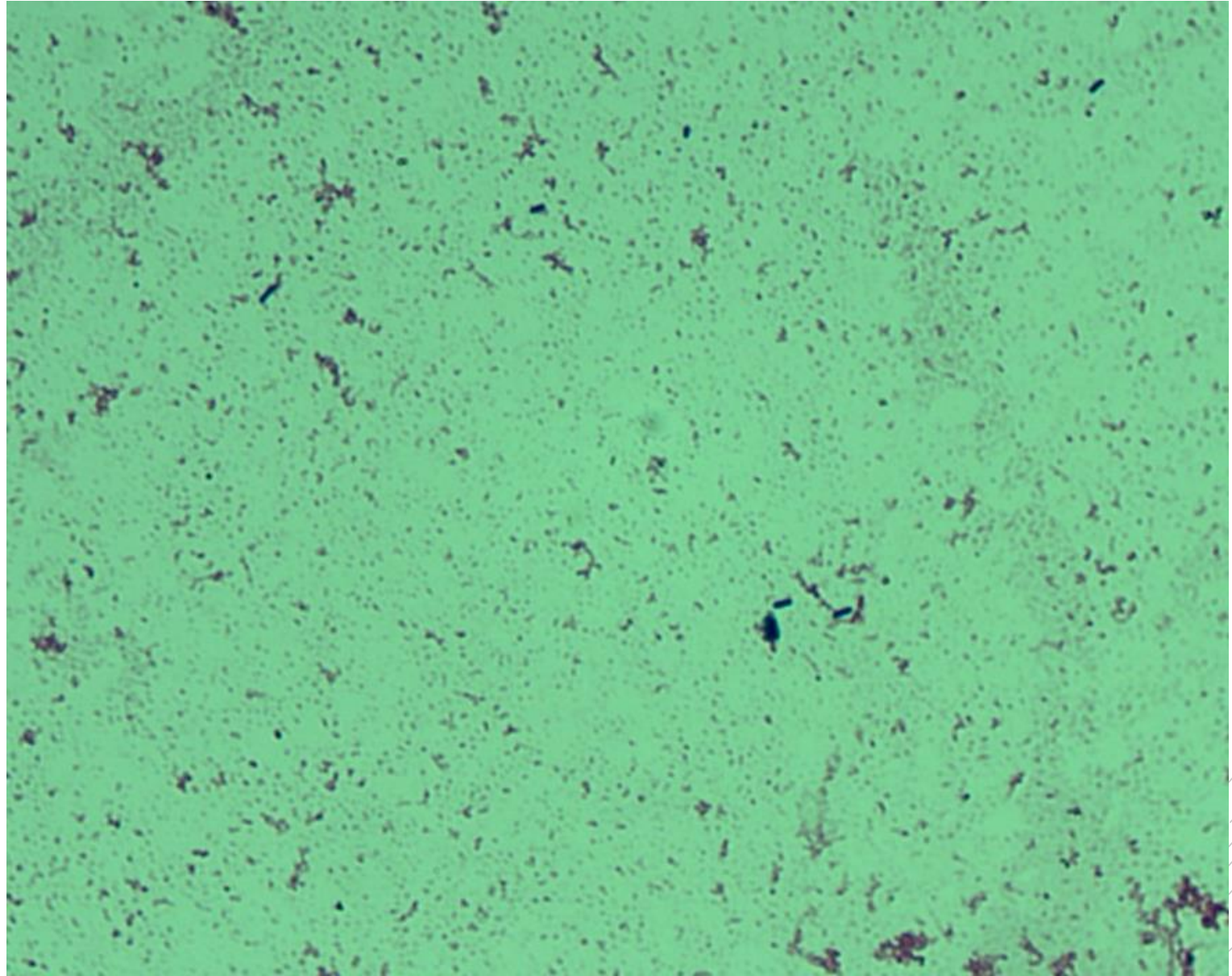
Listeria monocytogenes

Specimen: blood culture

Patient: female, 74 years old

Dg.: sepsis

Microscopy: Gram-positive rods



Author: MUDr. Petra Kabelíková, Sandra Opálková



CHARLES UNIVERSITY
Second Faculty of Medicine

Slide No. 60

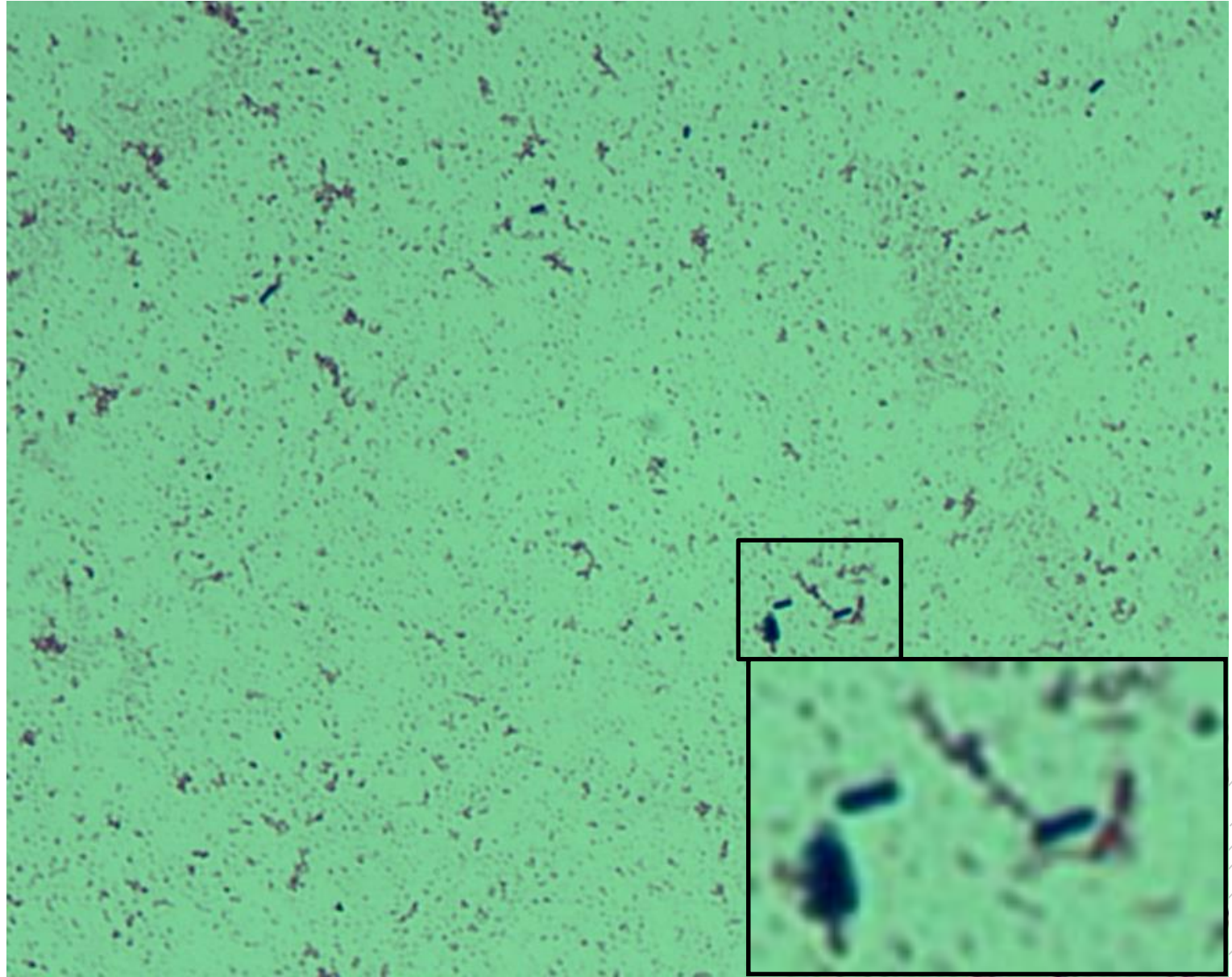
Listeria monocytogenes

Specimen: blood culture

Patient: female, 74 years old

Dg.: sepsis

Microscopy: Gram-positive rods



Author: MUDr. Petra Kabelíková, Sandra Opálková



CHARLES UNIVERSITY
Second Faculty of Medicine

Slide No. 61

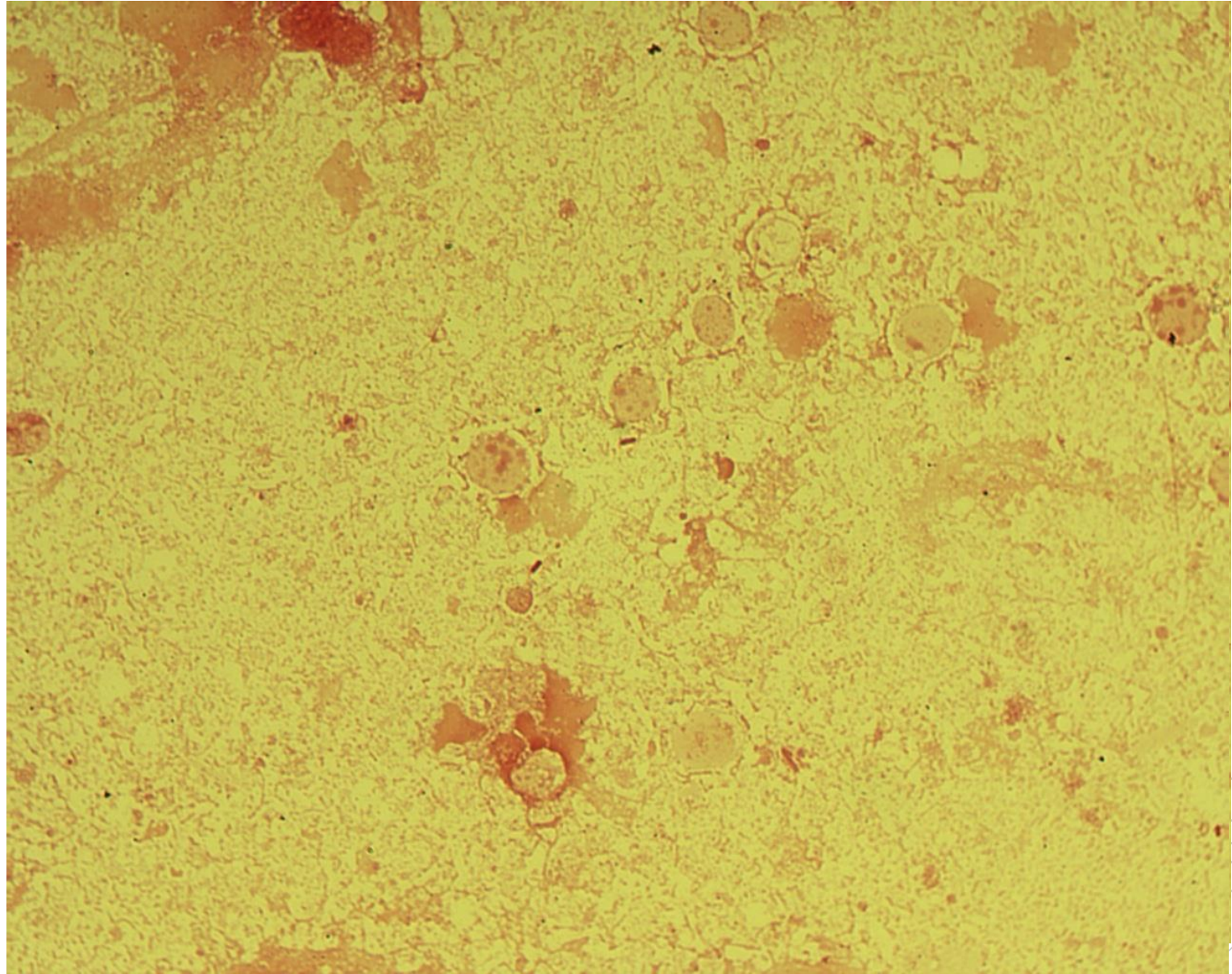
Pseudomonas aeruginosa

Specimen: abscess

Patient: male, 78 years old

Dg.: diabetic foot

Microscopy: Gram-negative rods



Author: MUDr. Alena Píšová



CHARLES UNIVERSITY
Second Faculty of Medicine

Slide No. 61


Pseudomonas aeruginosa

Specimen: abscess

Patient: male, 78 years old

Dg.: diabetic foot

Microscopy: Gram-negative rods



Author: MUDr. Alena Pířová



CHARLES UNIVERSITY
Second Faculty of Medicine

Slide No. 62

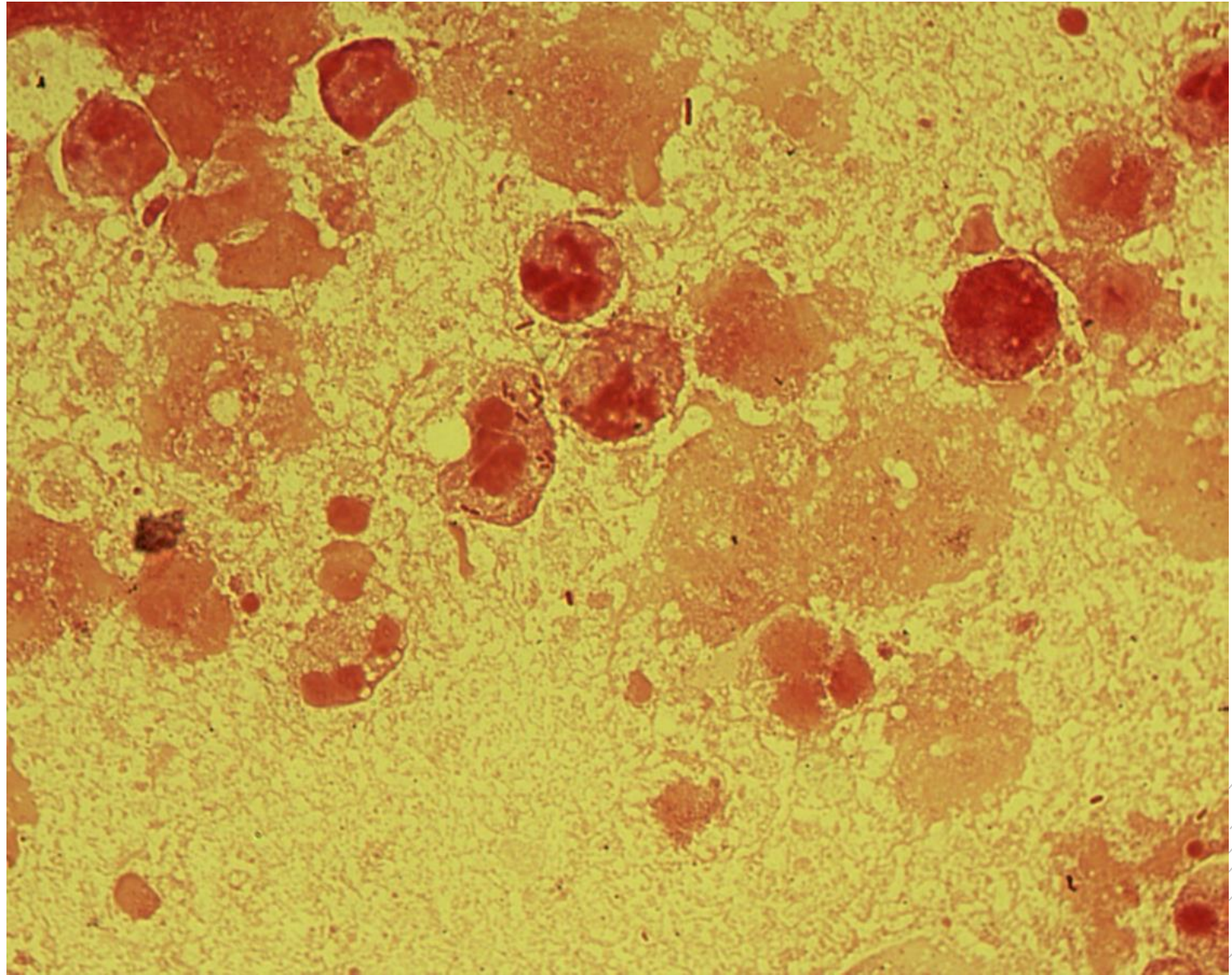
Escherichia coli

Specimen: pus

Patient: female, 65 years old

Dg.: periappendicular abscess

Microscopy: Gram-negative rods



Author: MUDr. Alena Píšová



CHARLES UNIVERSITY
Second Faculty of Medicine

Slide No. 62

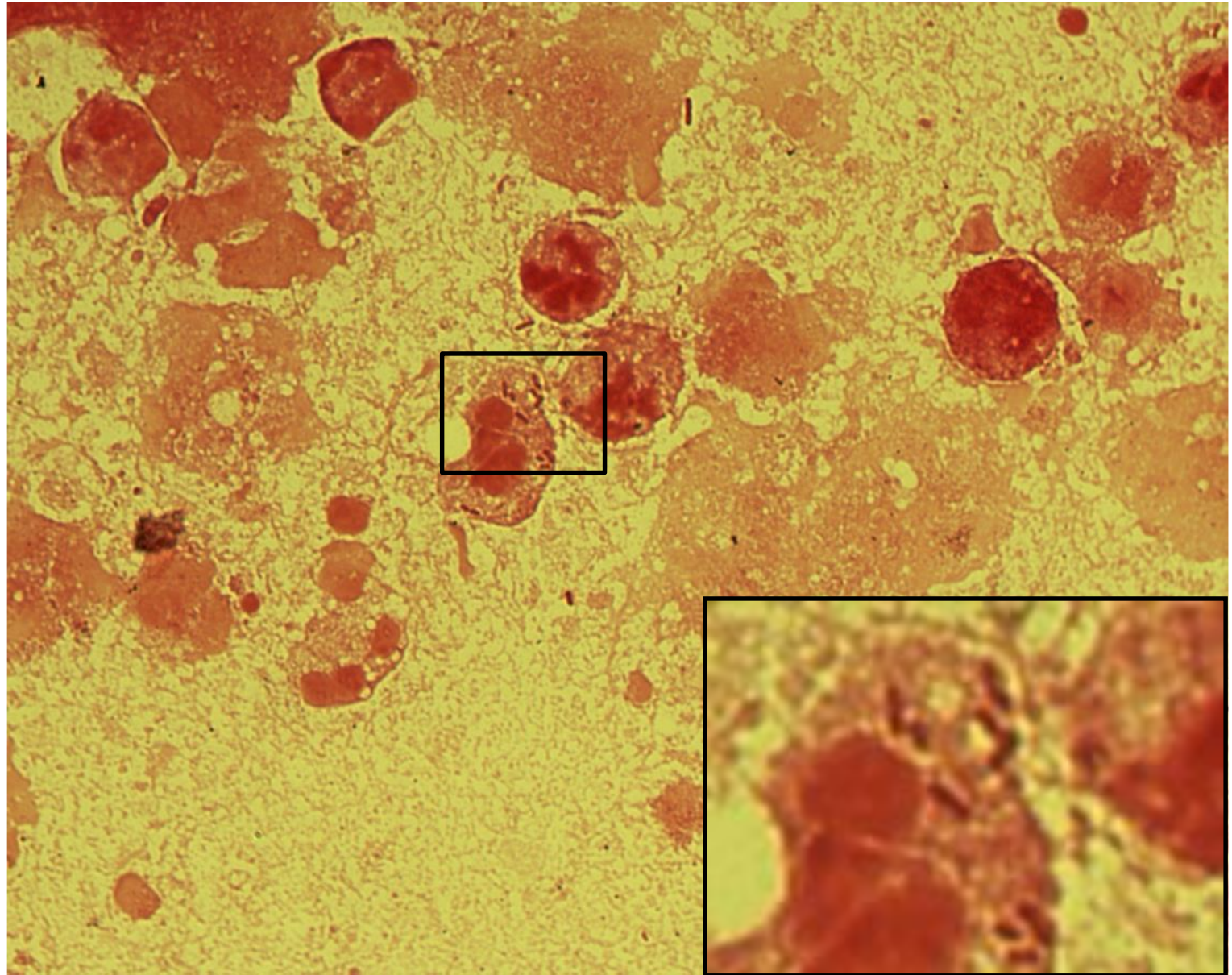
Escherichia coli

Specimen: pus

Patient: female, 65 years old

Dg.: periappendicular abscess

Microscopy: Gram-negative rods



Author: MUDr. Alena Pířová



CHARLES UNIVERSITY
Second Faculty of Medicine

Slide No. 63

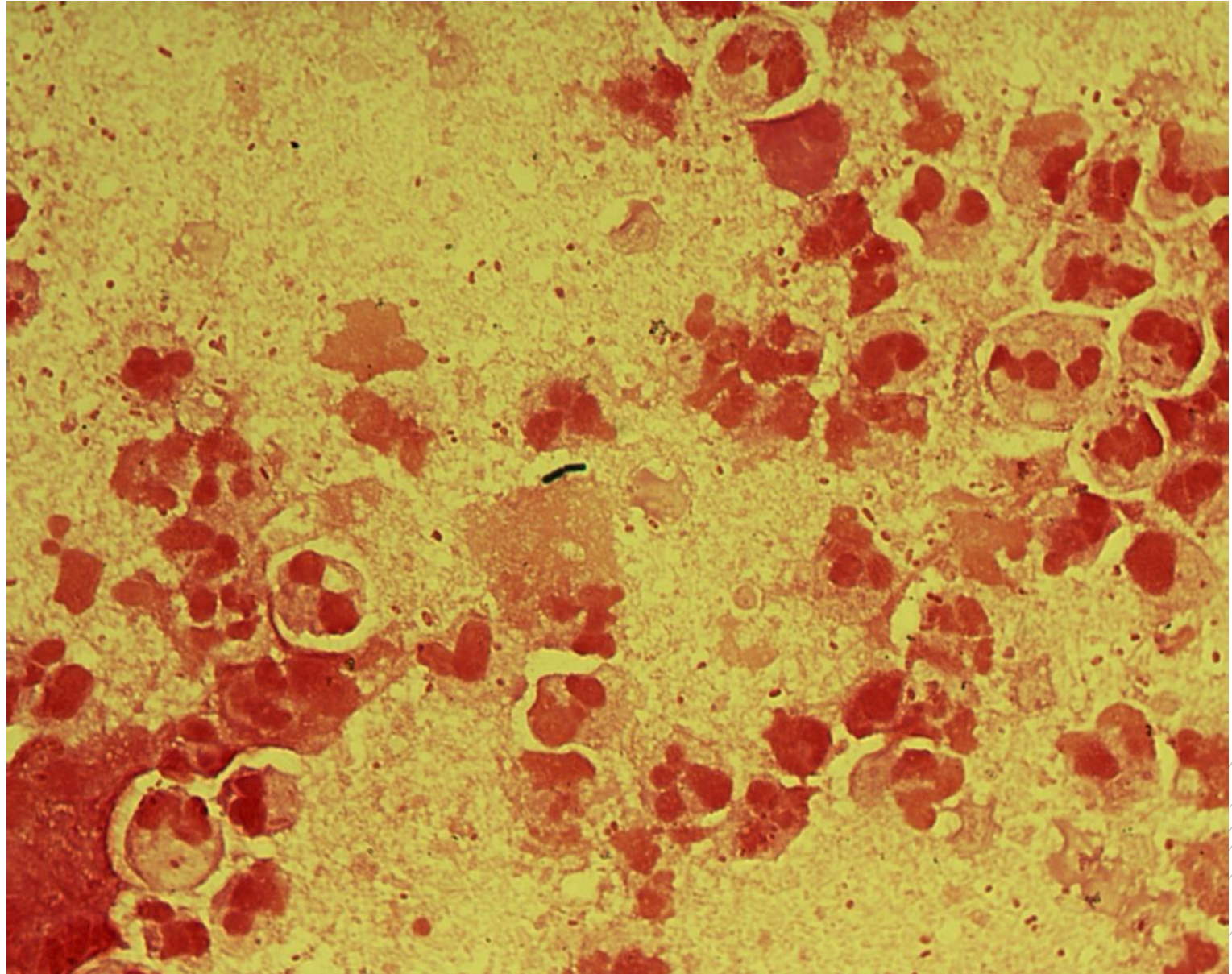
Escherichia coli

Specimen: pus

Patient: male, 39 years old

Dg.: periproctal abscess

Microscopy: Gram-negative rods



Author: MUDr. Alena Píšová



CHARLES UNIVERSITY
Second Faculty of Medicine

Slide No. 63

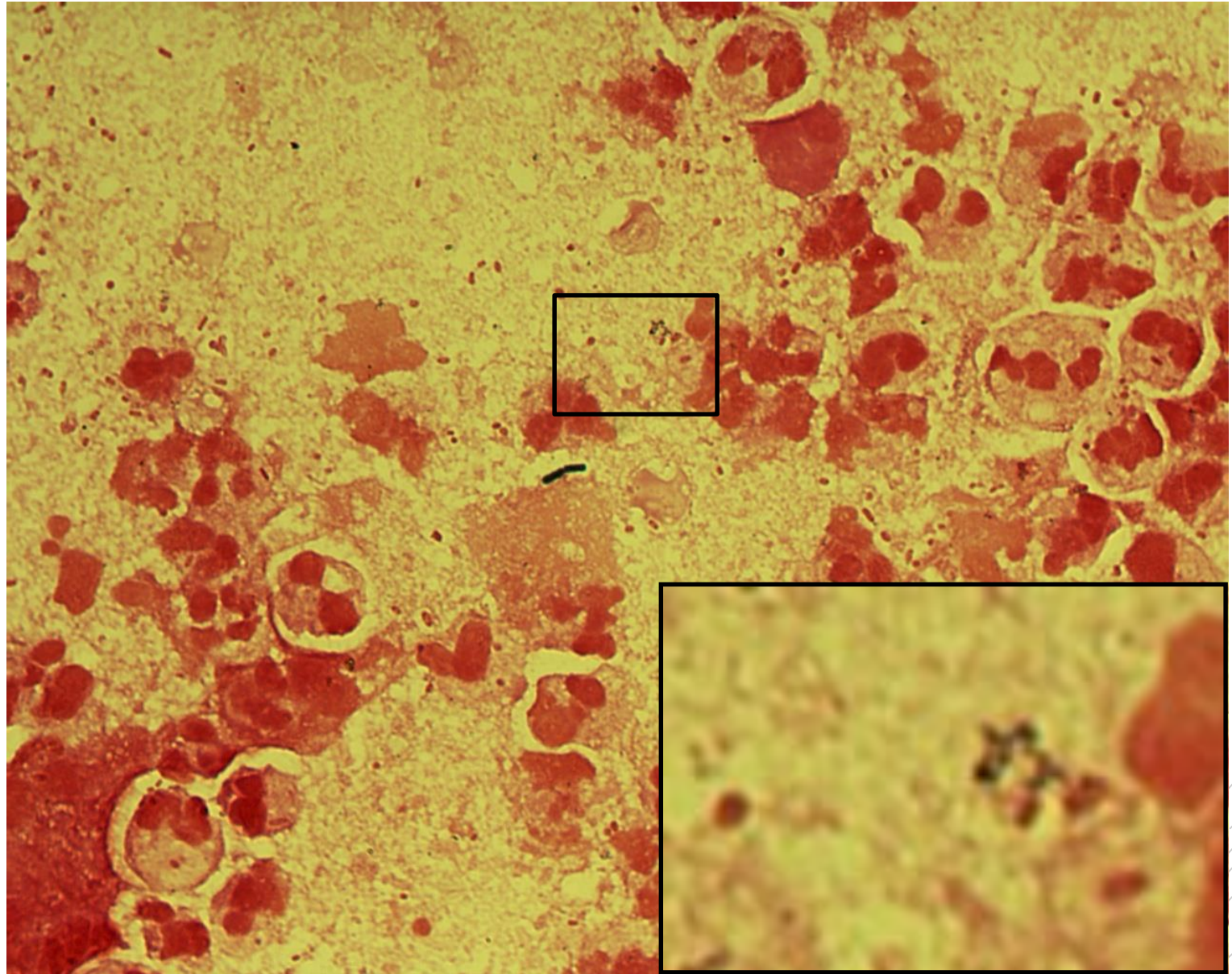
Escherichia coli

Specimen: pus

Patient: male, 39 years old

Dg.: periproctal abscess

Microscopy: Gram-negative rods



Author: MUDr. Alena Pířová



CHARLES UNIVERSITY
Second Faculty of Medicine

Slide No. 64

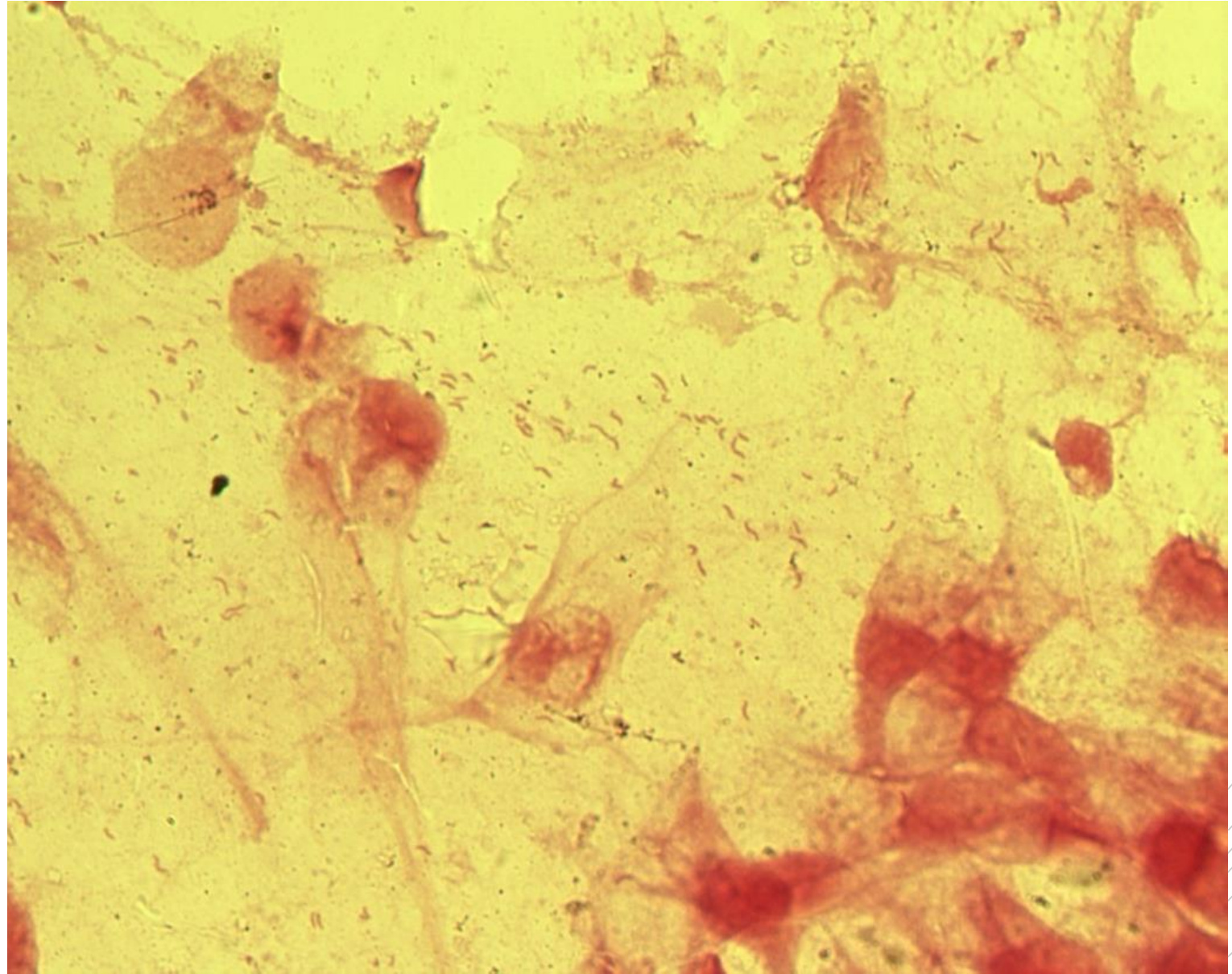
Helicobacter pylori

Specimen: biopsy

Patient: female, 35 years old

Dg.: stomach ulcer

Microscopy: spiral and „flying bird“-
shaped Gram-negative rods



Author: MUDr. Svojtková, MUDr. Šolarová



CHARLES UNIVERSITY
Second Faculty of Medicine

Slide No. 64

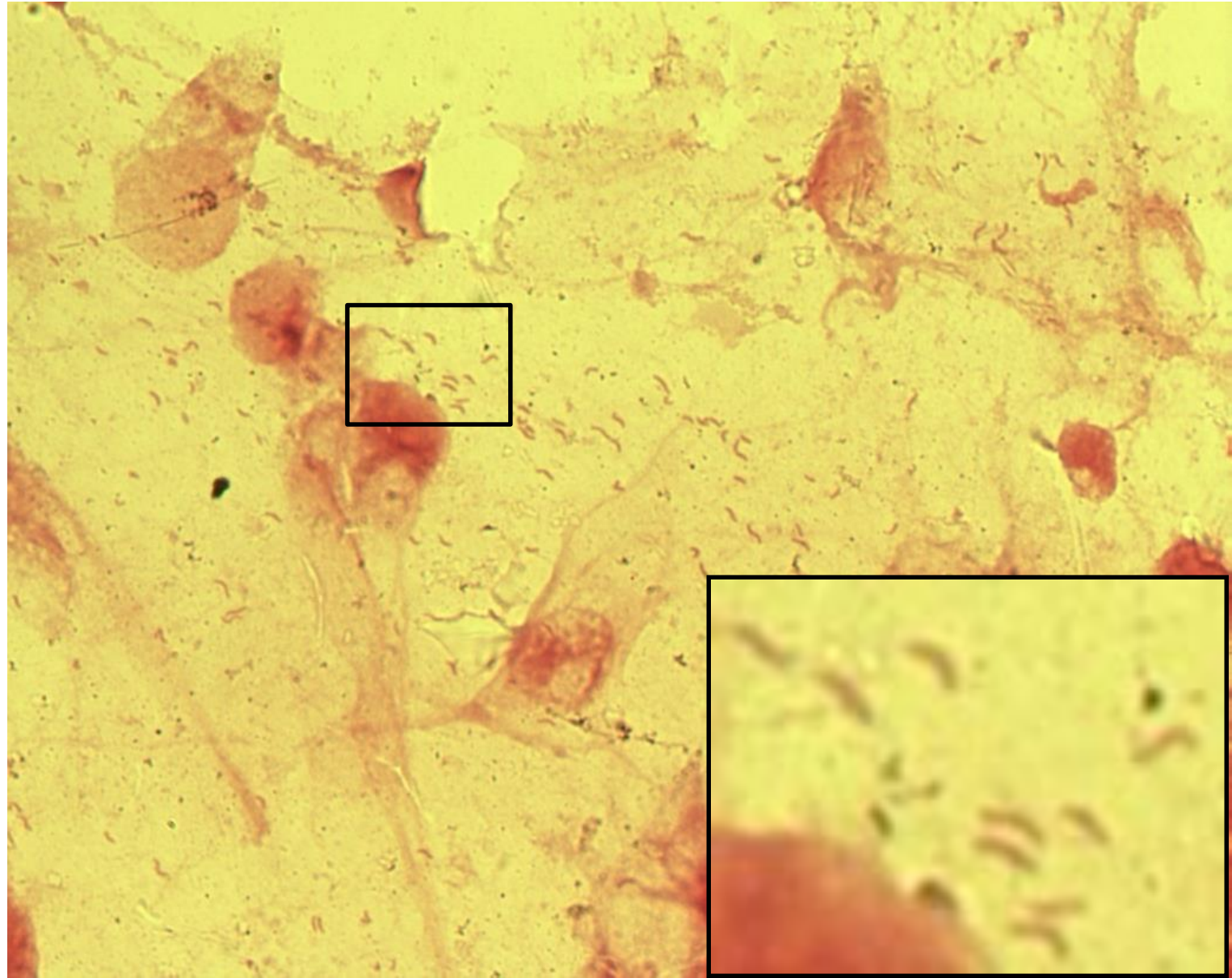
Helicobacter pylori

Specimen: biopsy

Patient: female, 35 years old

Dg.: stomach ulcer

Microscopy: spiral and „flying bird“-
shaped Gram-negative rods



Author: MUDr. Svojtková, MUDr. Šolarová



CHARLES UNIVERSITY
Second Faculty of Medicine

Slide No. 65

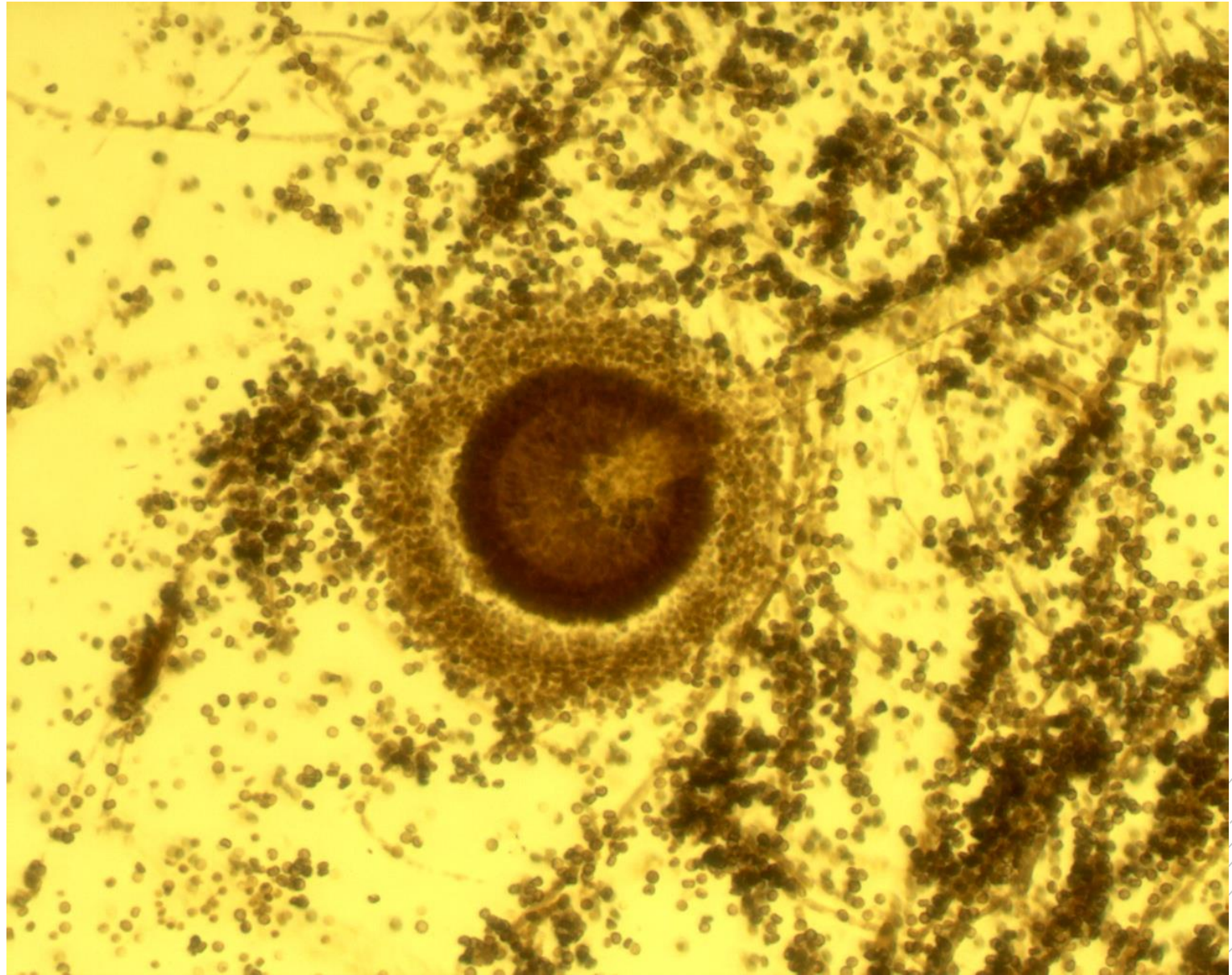
Aspergillus fumigatus

Specimen: culture

Patient: male, 85 years old

Dg.: lung aspergilloma

Microscopy: a conidiophore with a vesicle and numerous conidia



Author: MUDr. Svojtková, MUDr. Šolarová



CHARLES UNIVERSITY
Second Faculty of Medicine

Slide No. 65

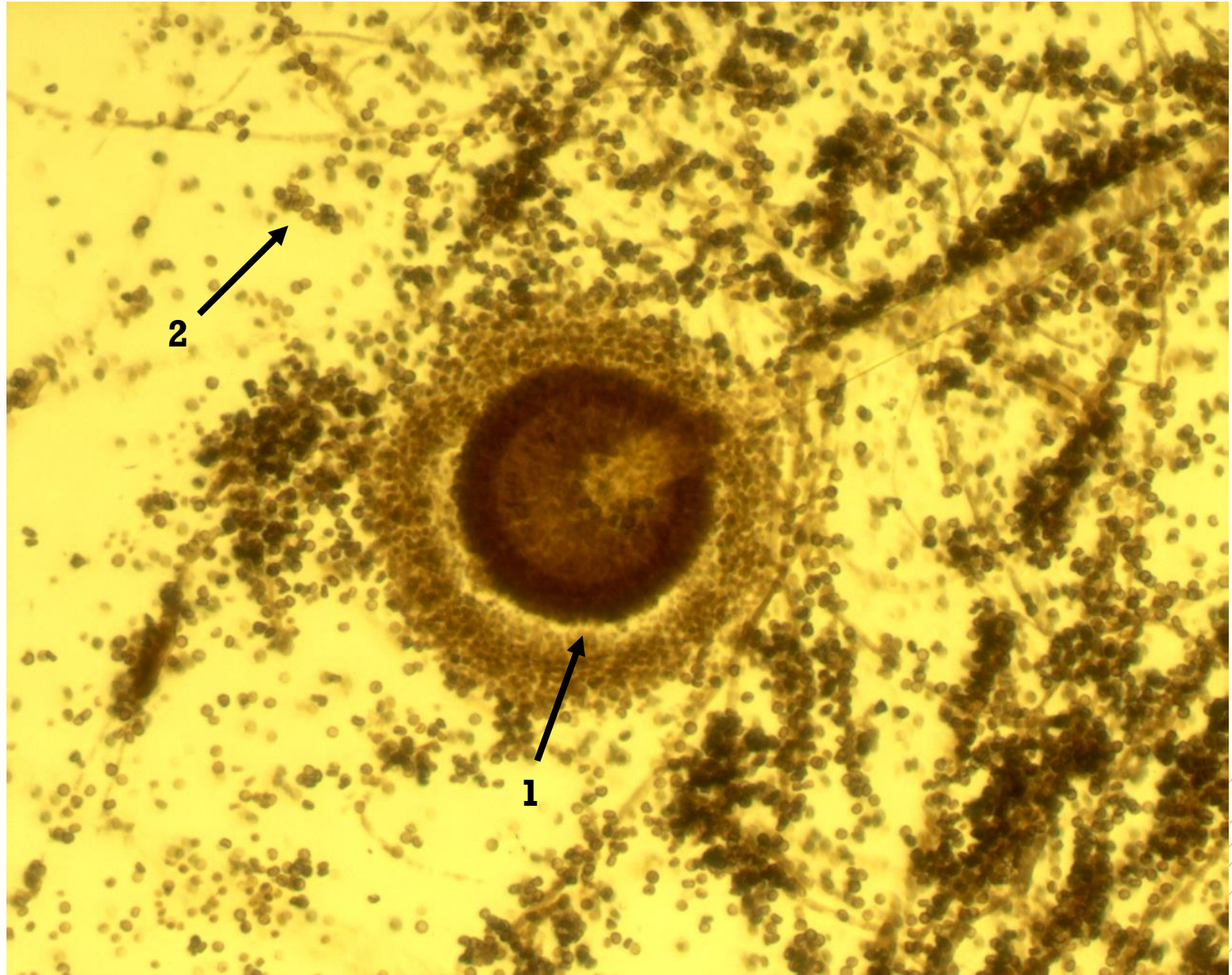
Aspergillus fumigatus

Specimen: culture

Patient: male, 85 years old

Dg.: lung aspergilloma

Microscopy: a conidiophore with a vesicle (1) and numerous conidia (2).



Author: MUDr. Svojtková, MUDr. Šolarová



CHARLES UNIVERSITY
Second Faculty of Medicine

Slide No. 66

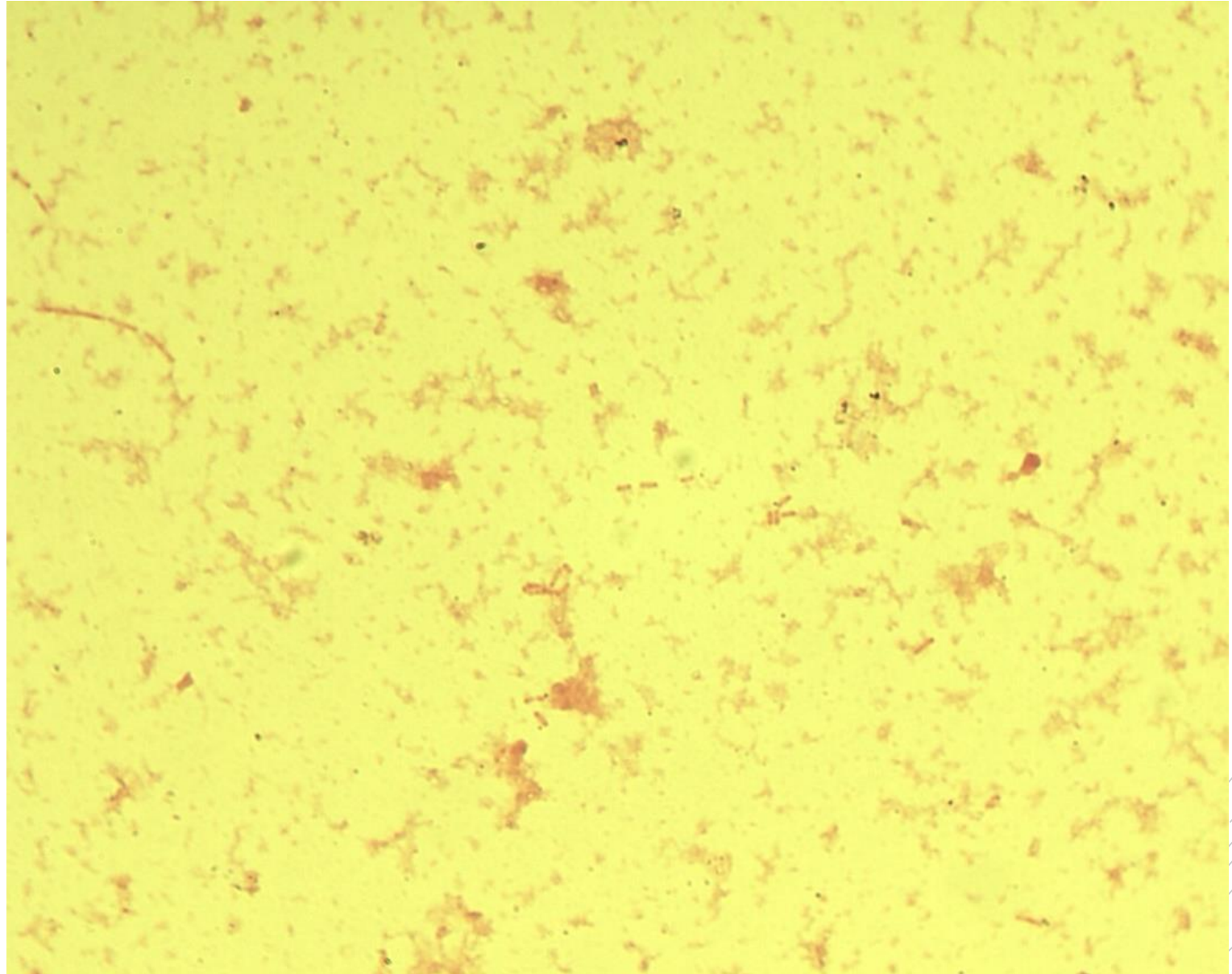
Escherichia coli

Specimen: pus

Patient: female, 64 years old

Dg.: stomach cancer

Microscopy: Gram-negative rods



Author: MUDr. Alena Píšová



CHARLES UNIVERSITY
Second Faculty of Medicine

Slide No. 66

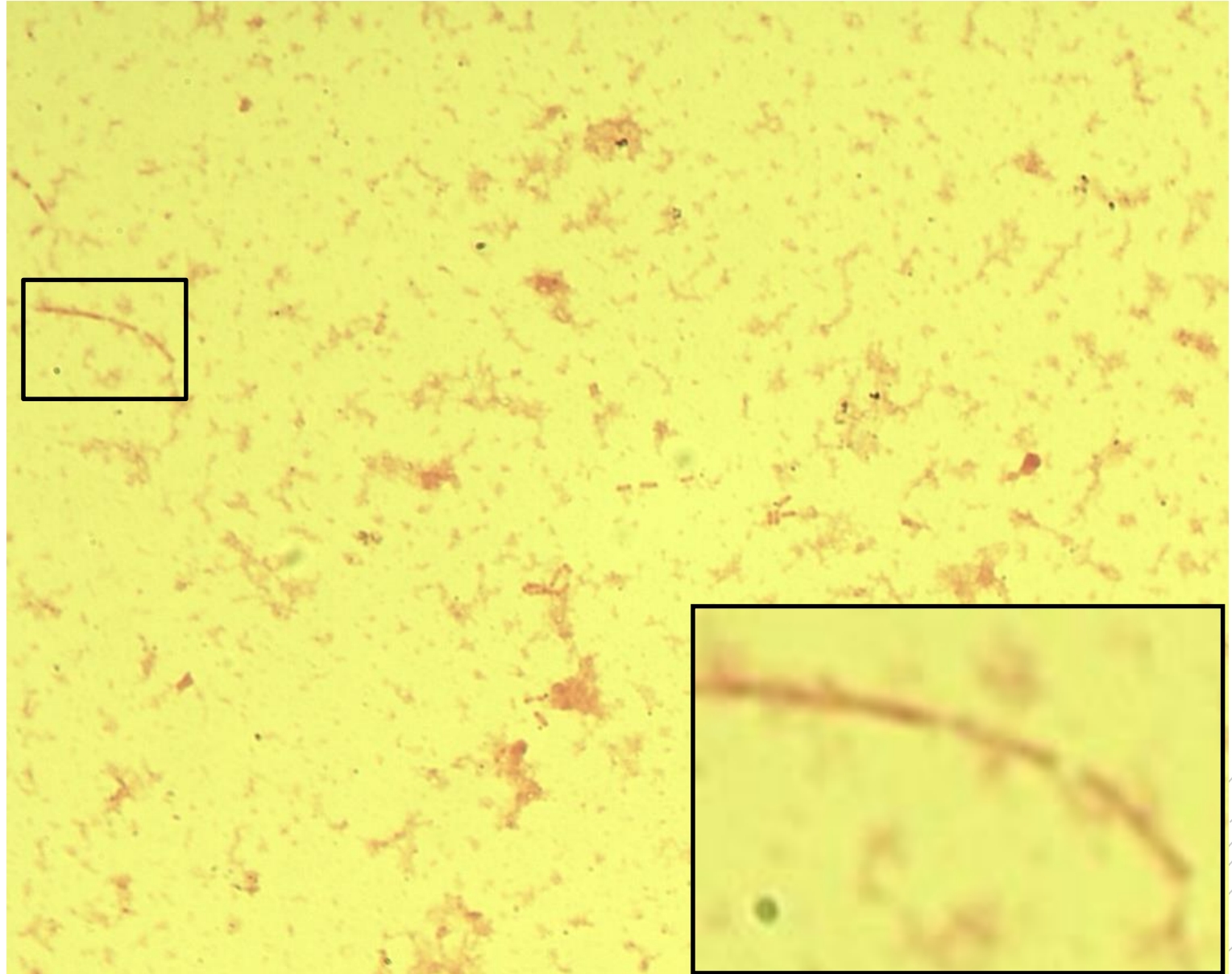
Escherichia coli

Specimen: pus

Patient: female, 64 years old

Dg.: stomach cancer

Microscopy: Gram-negative rods



Author: MUDr. Alena Píšová



CHARLES UNIVERSITY
Second Faculty of Medicine

Slide No. 67

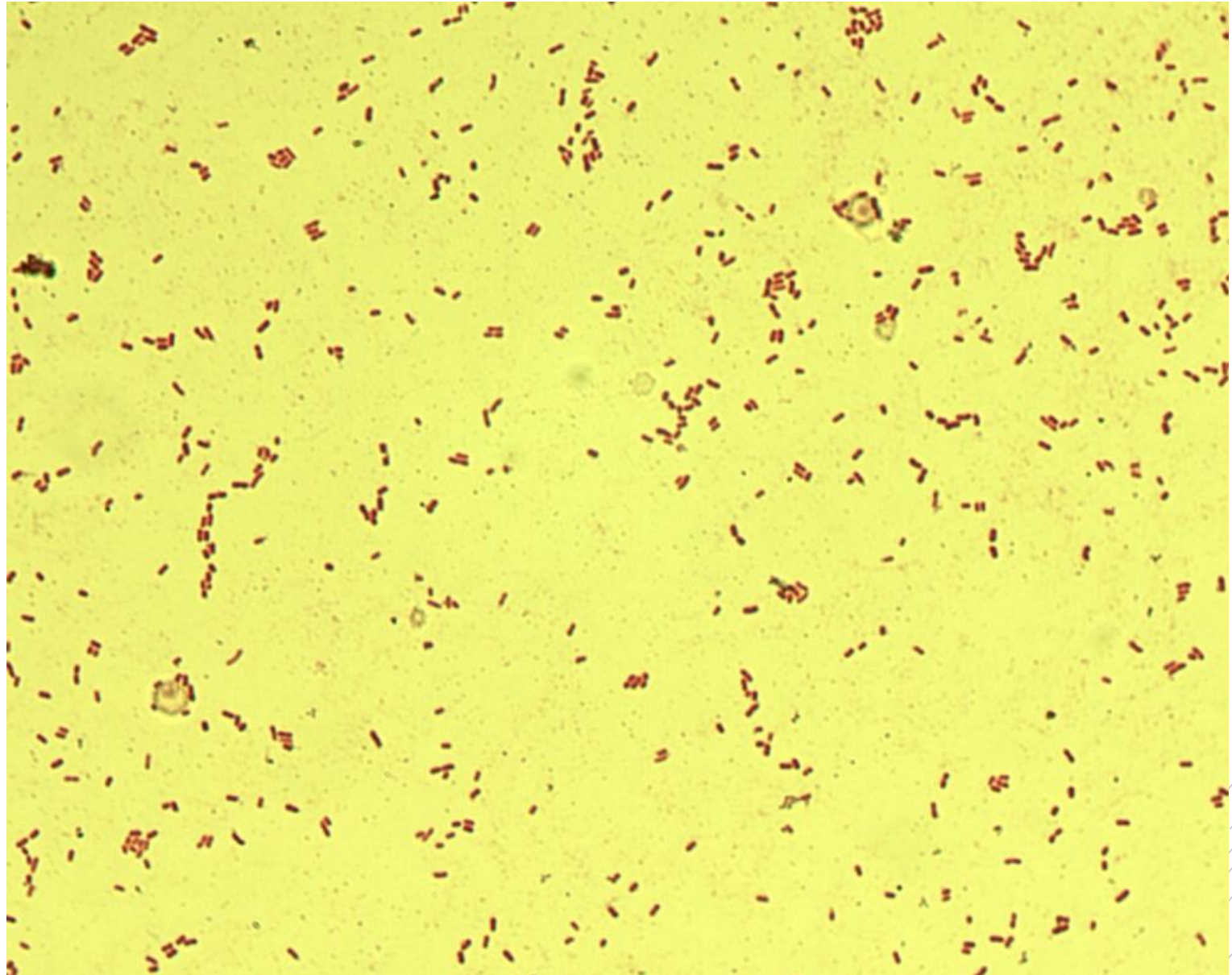
Klebsiella pneumoniae

Specimen: gall aspirate

Patient: female, 64 years old

Dg.: gallbladder ulcer

Microscopy: Gram-negative rods



Author: MUDr. Alena Píšová



CHARLES UNIVERSITY
Second Faculty of Medicine

Slide No. 67


Klebsiella pneumoniae

Specimen: gall aspirate

Patient: female, 64 years old

Dg.: gallbladder ulcer

Microscopy: Gram-negative rods



Author: MUDr. Alena Píšová



CHARLES UNIVERSITY
Second Faculty of Medicine

Slide No. 68

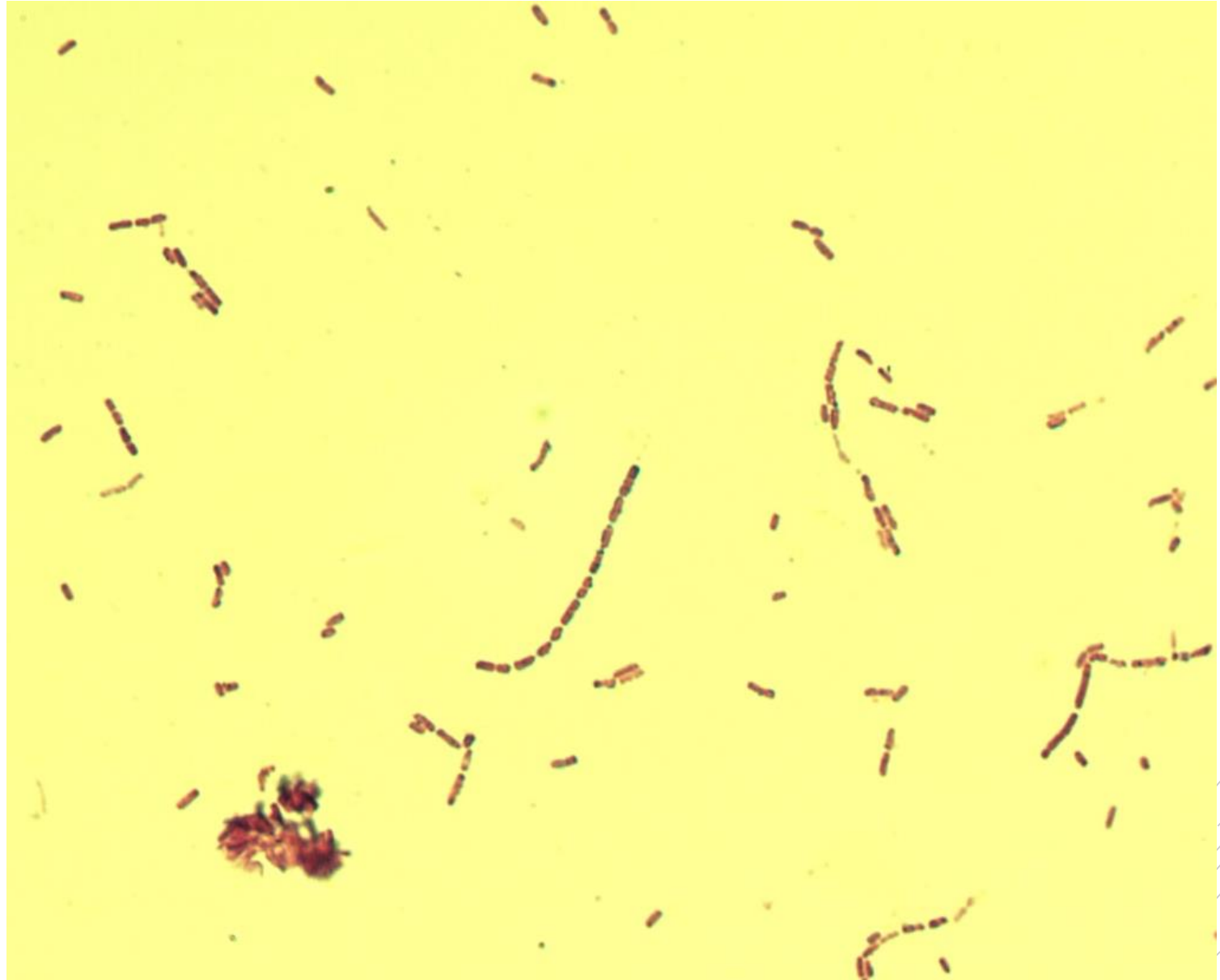
Bacillus cereus

Specimen: blood culture

Patient: newborn

Dg.: sepsis

Microscopy: Gram-positive rods



Author: MUDr. Svojtková, MUDr. Šolarová



CHARLES UNIVERSITY
Second Faculty of Medicine

Slide No. 68

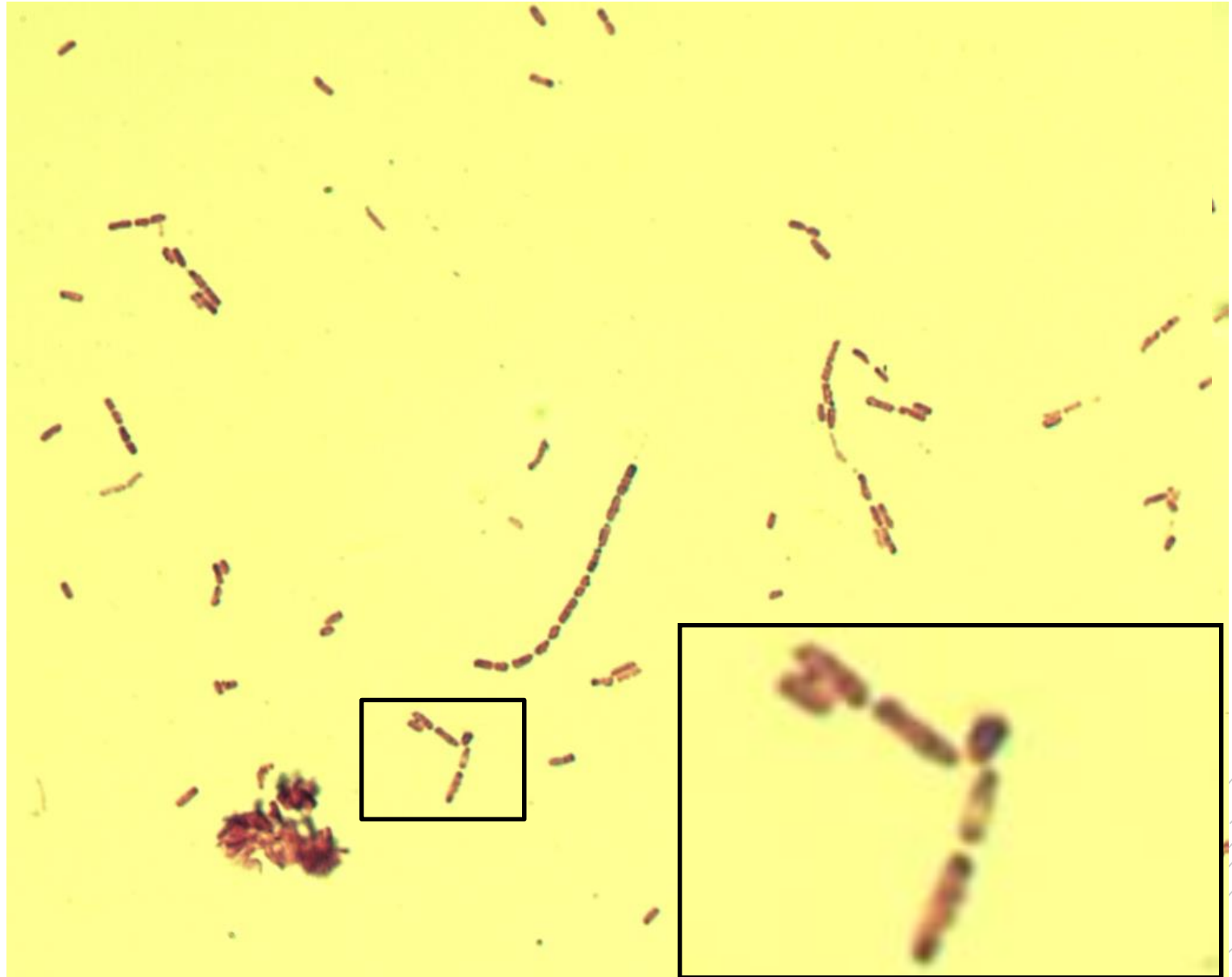
Bacillus cereus

Specimen: blood culture

Patient: newborn

Dg.: sepsis

Microscopy: Gram-positive rods



Author: MUDr. Svojková, MUDr. Šolarová



CHARLES UNIVERSITY
Second Faculty of Medicine

Slide No. 69

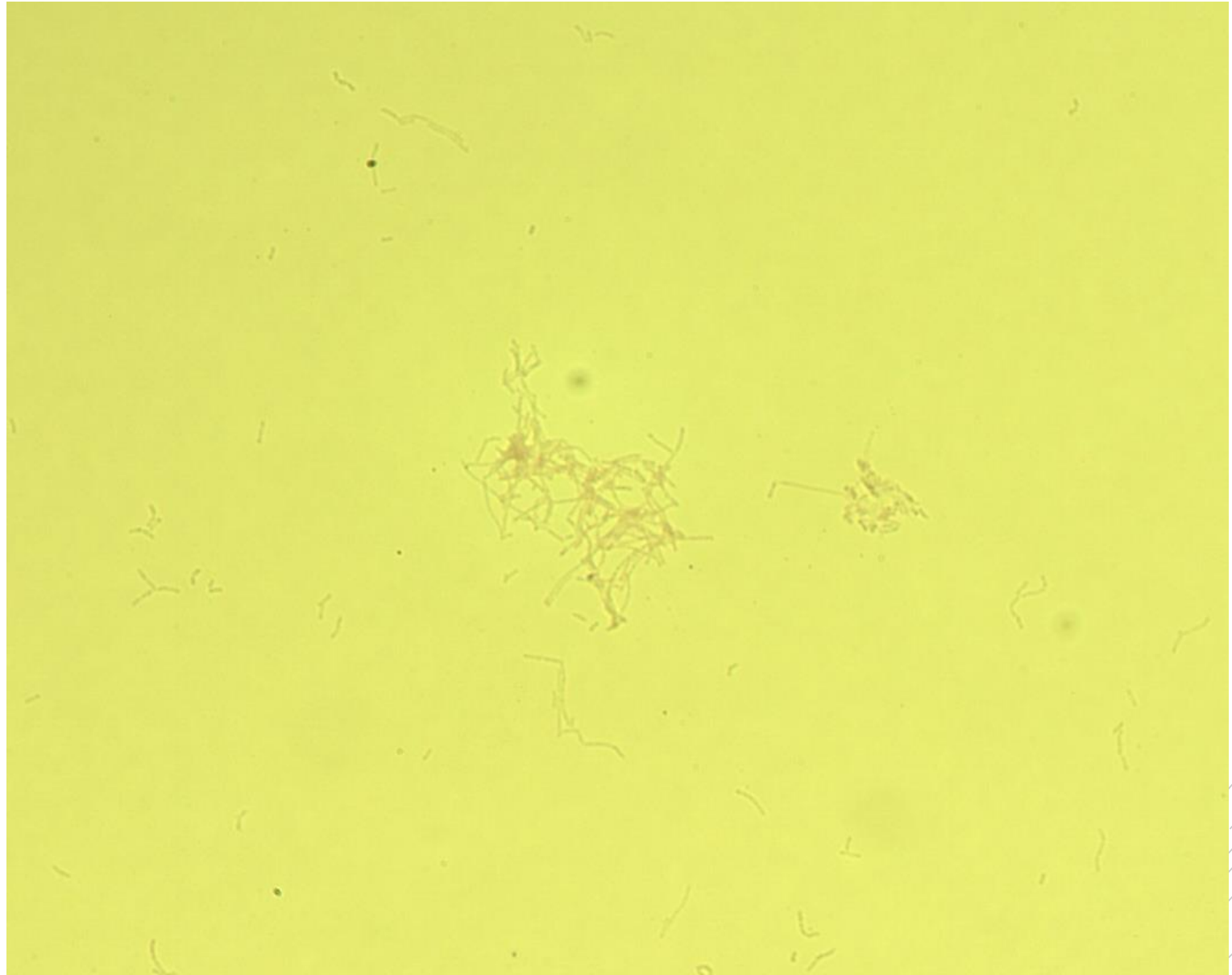
Nocardia faracinica

Specimen: culture

Patient: male, 18 years old

Dg.: lung nocardiosis

Microscopy: filamentous rods
(Ziehl-Neelsen stain)



Author: MUDr. Svojtková, MUDr. Šolarová



CHARLES UNIVERSITY
Second Faculty of Medicine

Slide No. 69


Nocardia faracinica

Specimen: culture

Patient: male, 18 years old

Dg.: lung nocardiosis

Microscopy: filamentous rods
(Ziehl-Neelsen stain)



Author: MUDr. Svojková, MUDr. Šolarová



CHARLES UNIVERSITY
Second Faculty of Medicine

Slide No. 70


Prevotella melaninogenica

Specimen: pus

Patient: male, 64 years old

Dg.: sinusitis

Microscopy: Gram-negative rods



Author: MUDr. Svojková, MUDr. Šolarová



CHARLES UNIVERSITY
Second Faculty of Medicine

Slide No. 70


Prevotella melaninogenica

Specimen: pus

Patient: male, 64 years old

Dg.: sinusitis

Microscopy: Gram-negative rods



Author: MUDr. Svojková, MUDr. Šolarová



CHARLES UNIVERSITY
Second Faculty of Medicine

Slide No. 71


Prevotella melaninogenica

Specimen: culture

Patient: male, 64 years old

Dg.: sinusitis

Microscopy: Gram-negative rods



Author: MUDr. Svojková, MUDr. Šolarová



CHARLES UNIVERSITY
Second Faculty of Medicine

Slide No. 71


Prevotella melaninogenica

Specimen: culture

Patient: male, 64 years old

Dg.: sinusitis

Microscopy: Gram-negative rods



Author: MUDr. Svojková, MUDr. Šolarová



CHARLES UNIVERSITY
Second Faculty of Medicine

Slide No. 72

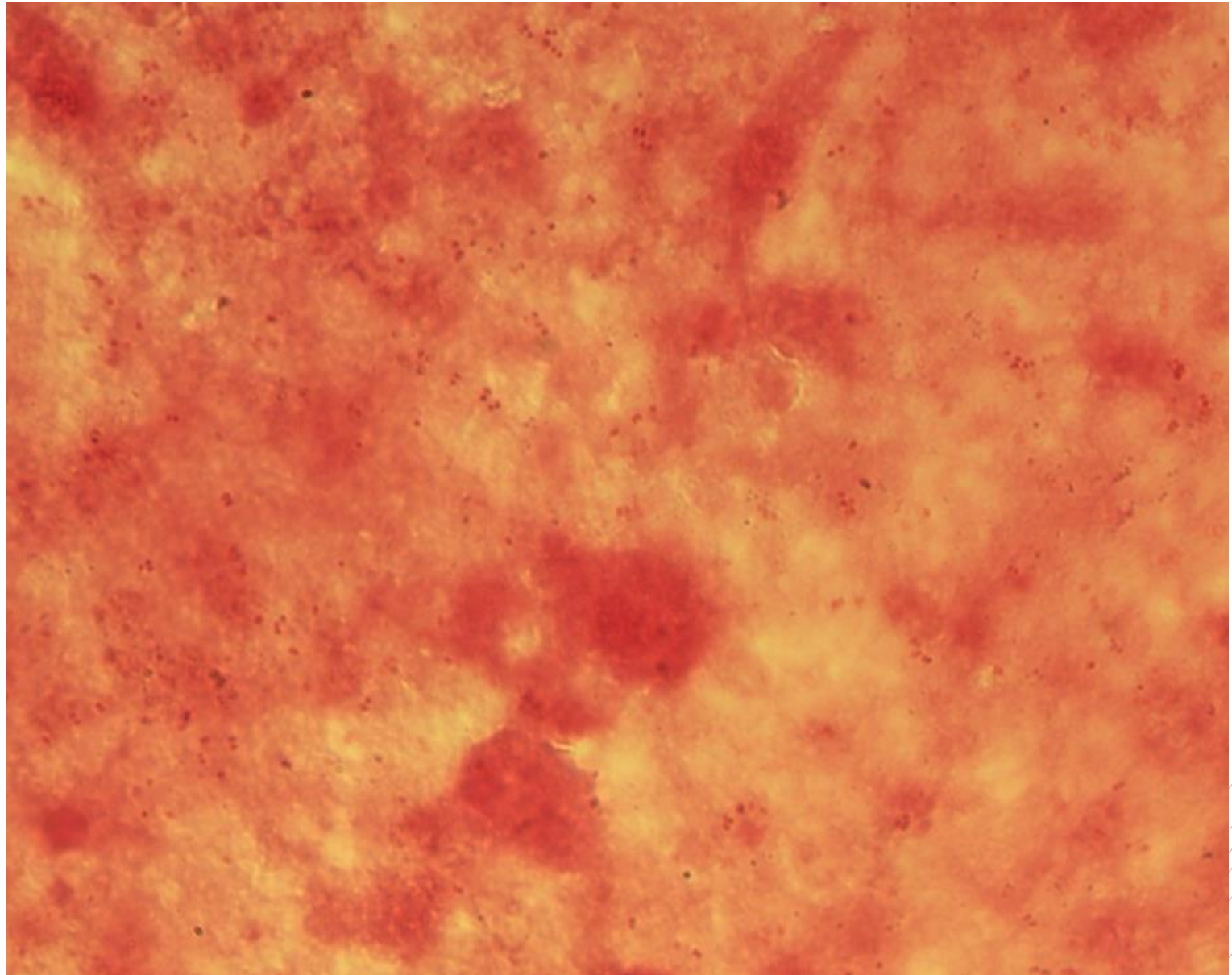
Neisseria gonorrhoeae

Specimen: pus

Patient: male, 20 years old

Dg.: urethritis

Microscopy: Gram-negative diplococci



Author: MUDr. Svojtková, MUDr. Šolarová



CHARLES UNIVERSITY
Second Faculty of Medicine

Slide No. 72


Neisseria gonorrhoeae

Specimen: pus

Patient: male, 20 years old

Dg.: urethritis

Microscopy: Gram-negative diplococci



Author: MUDr. Svojtková, MUDr. Šolarová



CHARLES UNIVERSITY
Second Faculty of Medicine

Slide No. 73


Neisseria gonorrhoeae

Specimen: culture

Patient: male, 20 years old

Dg.: urethritis

Microscopy: Gram-negative diplococci



Author: MUDr. Svojtková, MUDr. Šolarová



CHARLES UNIVERSITY
Second Faculty of Medicine

Slide No. 73

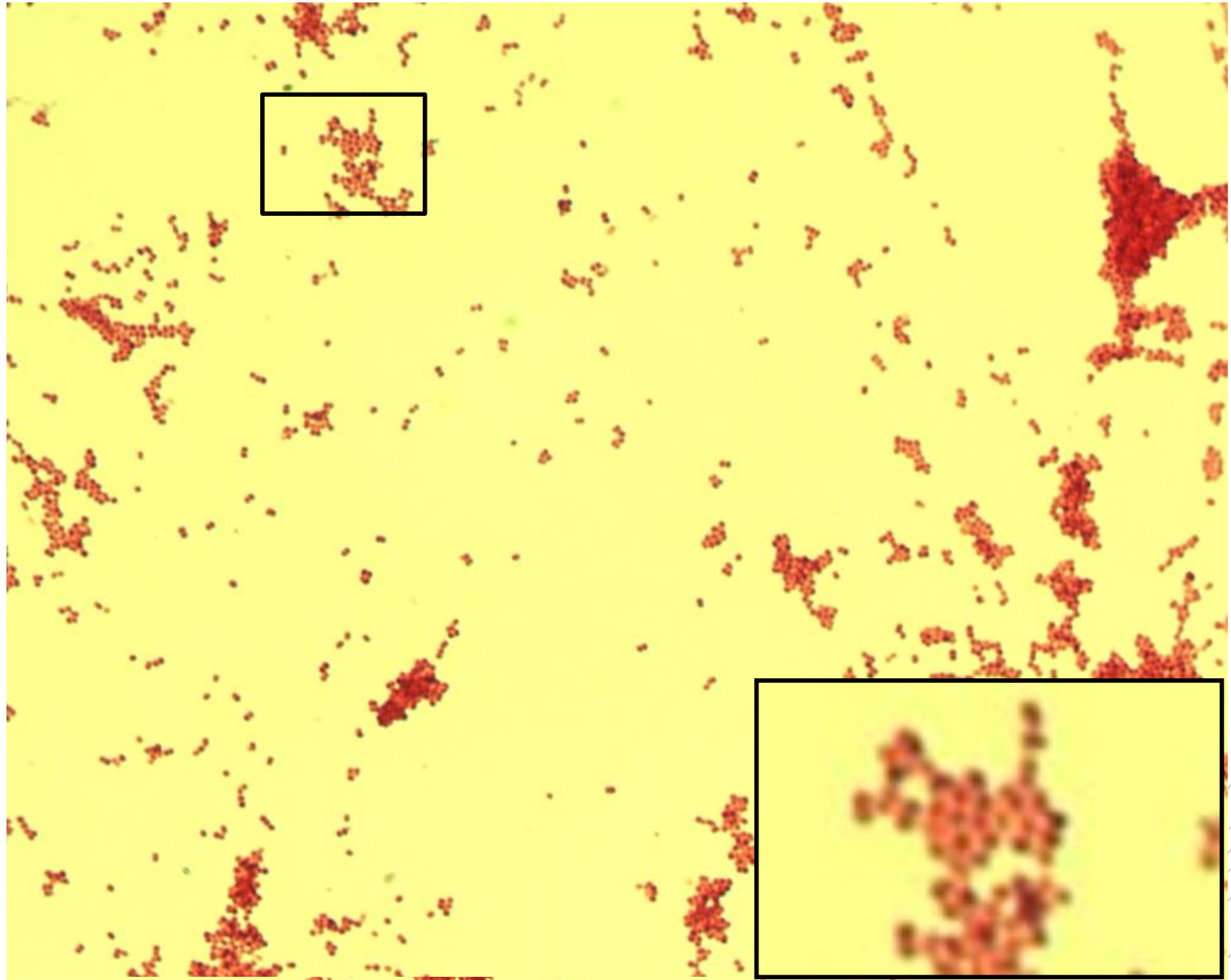
Neisseria gonorrhoeae

Specimen: culture

Patient: male, 20 years old

Dg.: urethritis

Microscopy: Gram-negative diplococci



Author: MUDr. Svojtková, MUDr. Šolarová



CHARLES UNIVERSITY
Second Faculty of Medicine

Slide No. 74


Bacteroides fragilis

Specimen: pus

Patient: female, 73 years old

Dg.: gallbladder inflammation

Microscopy: Gram-negative rods



Author: MUDr. Svojtková, MUDr. Šolarová



CHARLES UNIVERSITY
Second Faculty of Medicine

Slide No. 74


Bacteroides fragilis

Specimen: pus

Patient: female, 73 years old

Dg.: gallbladder inflammation

Microscopy: Gram-negative rods



Author: MUDr. Svojtková, MUDr. Šolarová



CHARLES UNIVERSITY
Second Faculty of Medicine

Slide No. 75

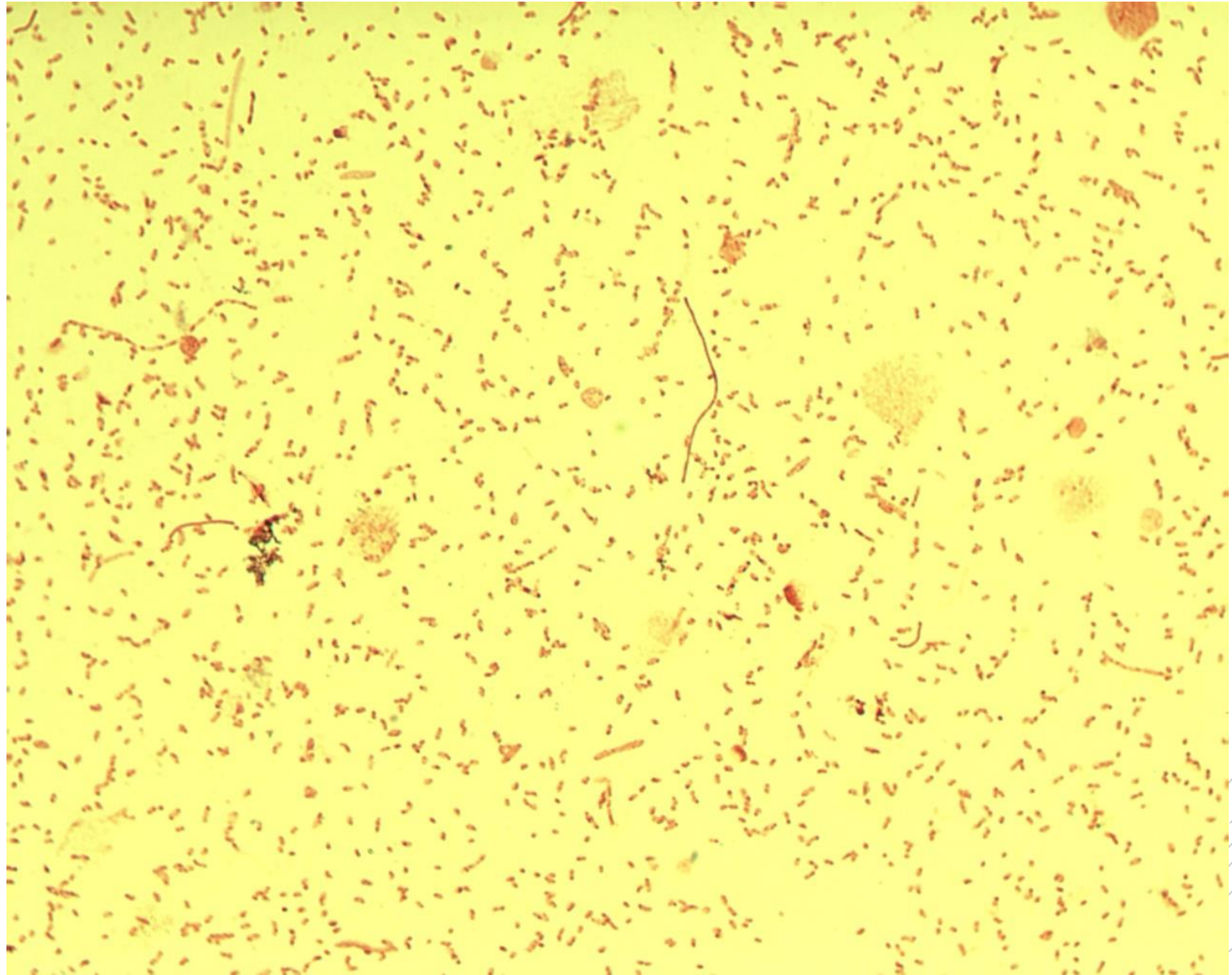
Bacteroides fragilis

Specimen: culture

Patient: female, 73 years old

Dg.: gallbladder inflammation

Microscopy: Gram-negative coccobacilli and rods



Author: MUDr. Svojtková, MUDr. Šolarová



CHARLES UNIVERSITY
Second Faculty of Medicine

Slide No. 75


Bacteroides fragilis

Specimen: culture

Patient: female, 73 years old

Dg.: gallbladder inflammation

Microscopy: Gram-negative coccobacilli and rods



Author: MUDr. Svojková, MUDr. Šolarová



CHARLES UNIVERSITY
Second Faculty of Medicine

Slide No. 76

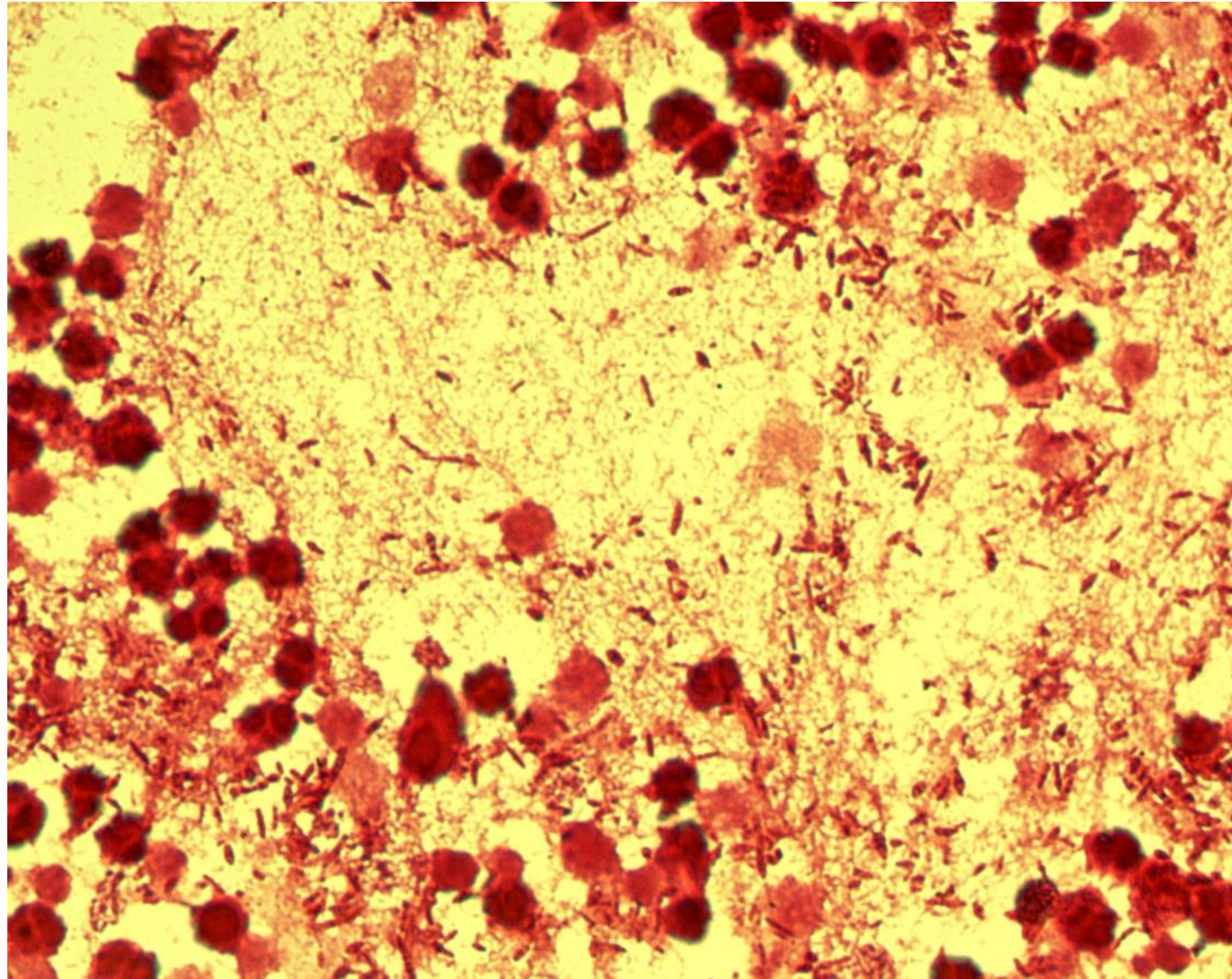
Proteus mirabilis

Specimen: gall

Patient: female, 27 years old

Dg.: gallbladder inflammation

Microscopy: Gram-negative rods



Author: MUDr. Alena Pířová



CHARLES UNIVERSITY
Second Faculty of Medicine

Slide No. 76

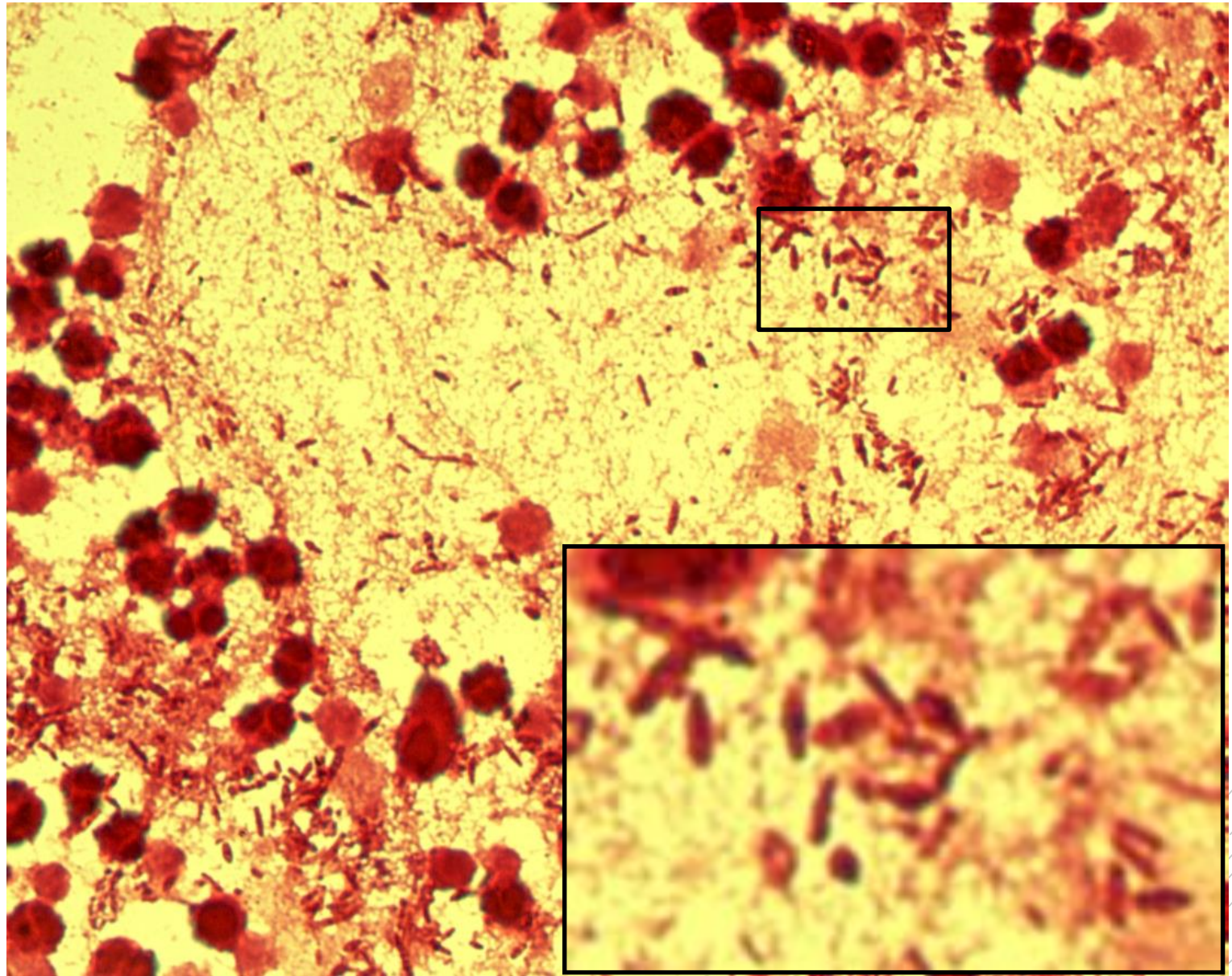
Proteus mirabilis

Specimen: gall

Patient: female, 27 years old

Dg.: gallbladder inflammation

Microscopy: Gram-negative rods



Author: MUDr. Alena Pířová



CHARLES UNIVERSITY
Second Faculty of Medicine

Slide No. 77

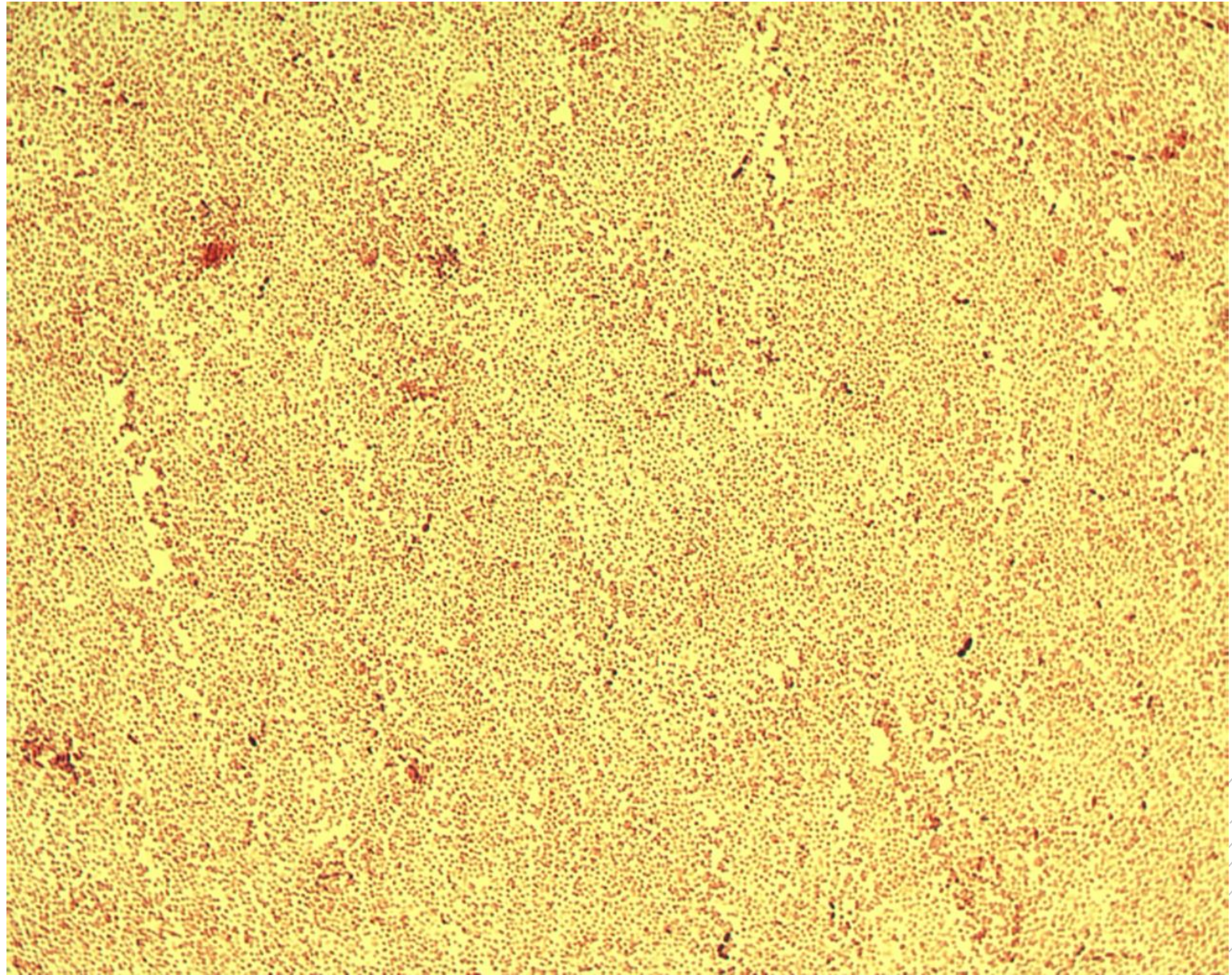
Pasteurella multocida

Specimen: bronchial secretion

Patient: male, 10 years old

Dg.: pneumonia

Microscopy: Gram-negative coccobacilli



Author: MUDr. Lenka Tritová



CHARLES UNIVERSITY
Second Faculty of Medicine

Slide No. 77

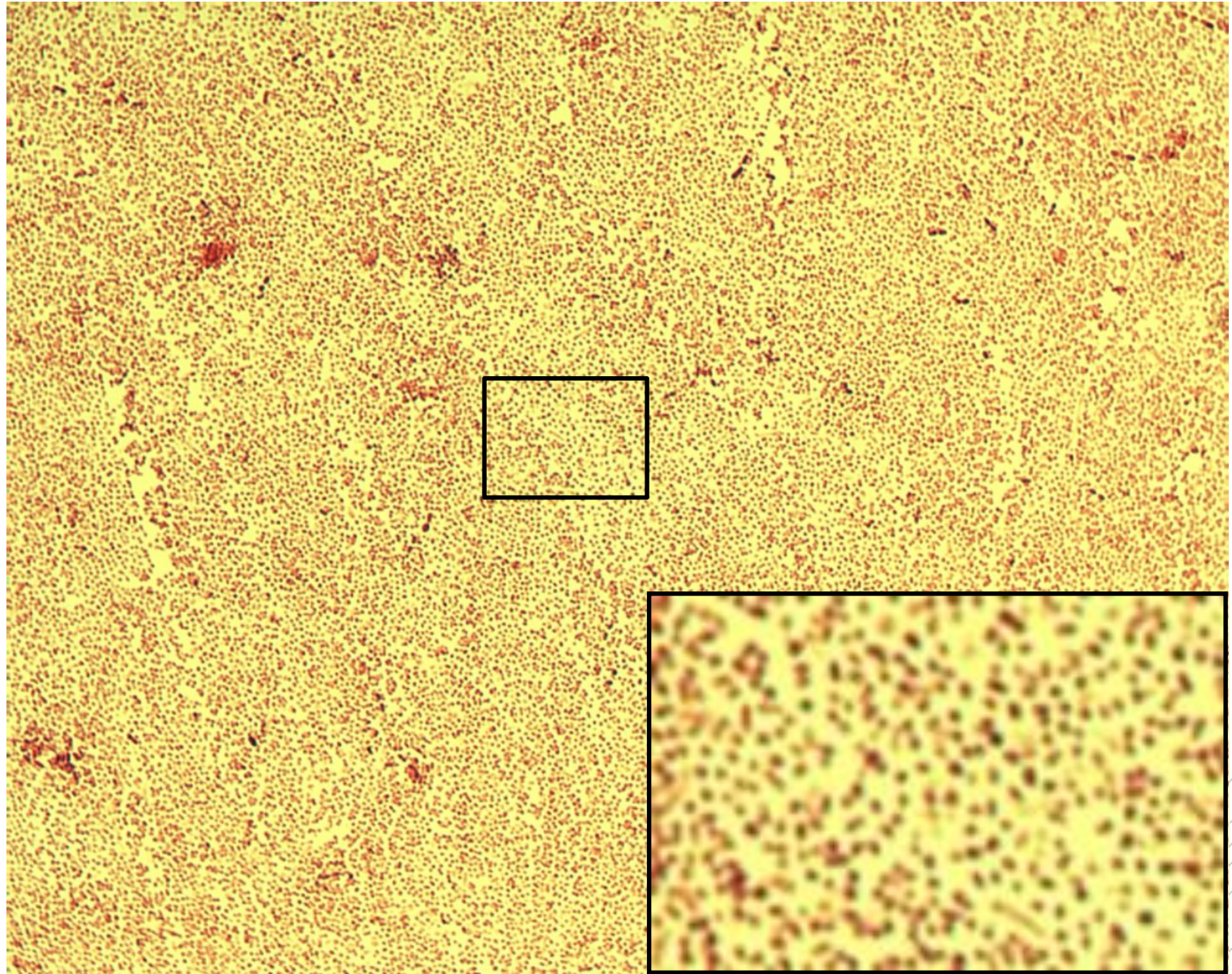
Pasteurella multocida

Specimen: bronchial secretion

Patient: male, 10 years old

Dg.: pneumonia

Microscopy: Gram-negative coccobacilli



Author: MUDr. Lenka Tritová



CHARLES UNIVERSITY
Second Faculty of Medicine

Slide No. 78

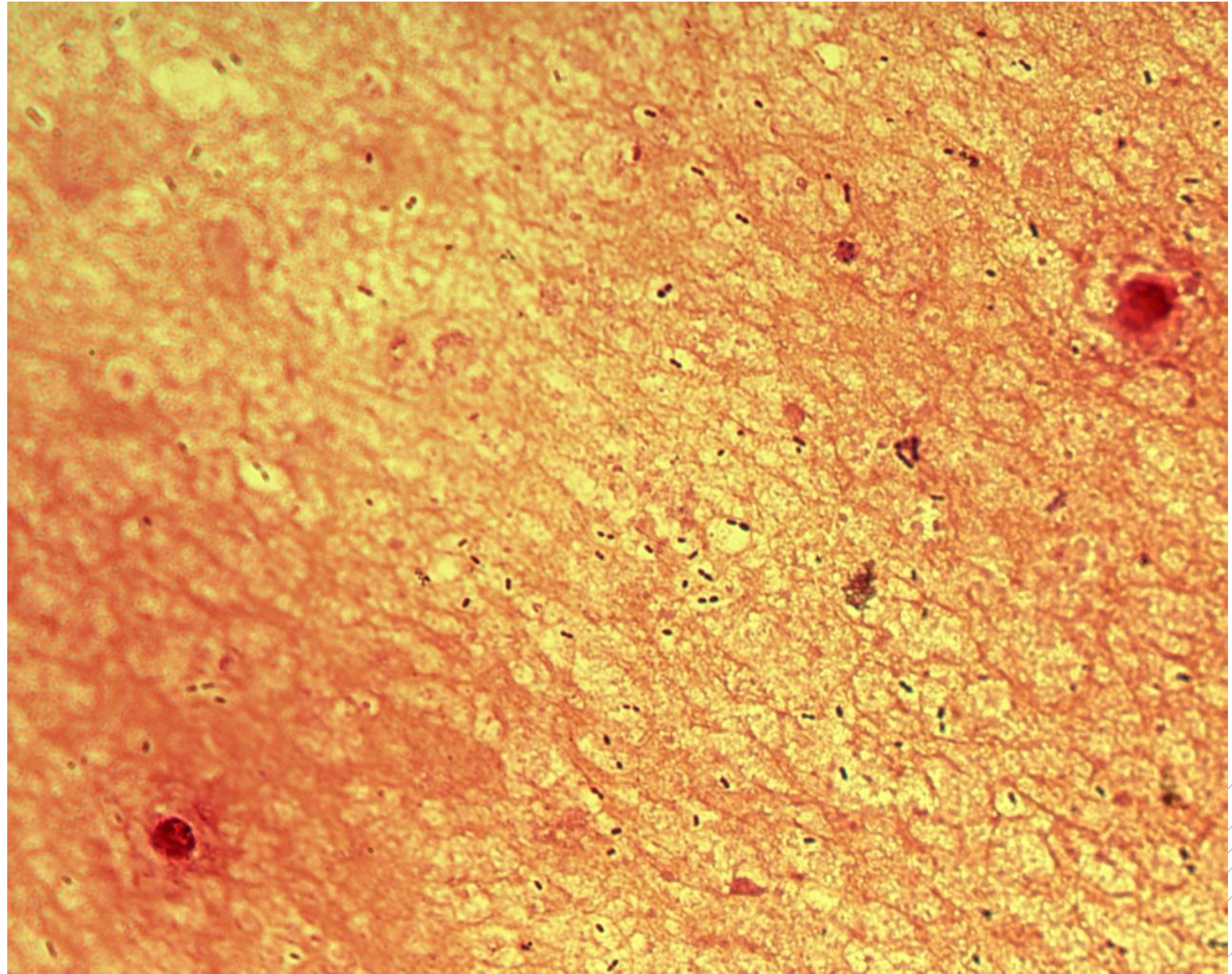
Streptococcus pneumoniae

Specimen: sputum

Patient: female, 28 years old

Dg.: pneumonia

Microscopy: encapsulated
Gram-positive diplococci



Author: MUDr. Svojtková, MUDr. Šolarová



CHARLES UNIVERSITY
Second Faculty of Medicine

Slide No. 78

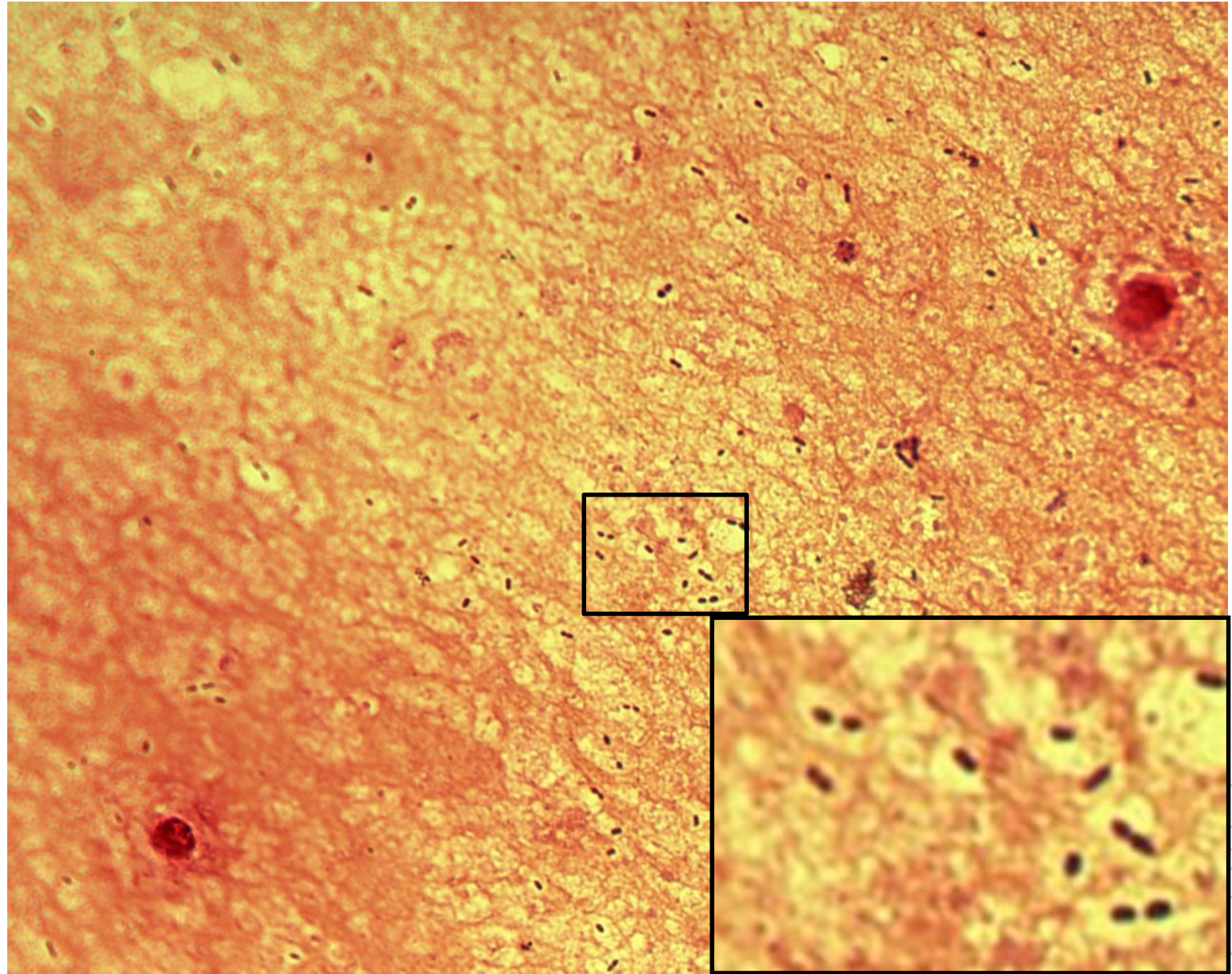
Streptococcus pneumoniae

Specimen: sputum

Patient: female, 28 years old

Dg.: pneumonia

Microscopy: encapsulated
Gram-positive diplococci



Author: MUDr. Svojtková, MUDr. Šolarová



CHARLES UNIVERSITY
Second Faculty of Medicine

Slide No. 79

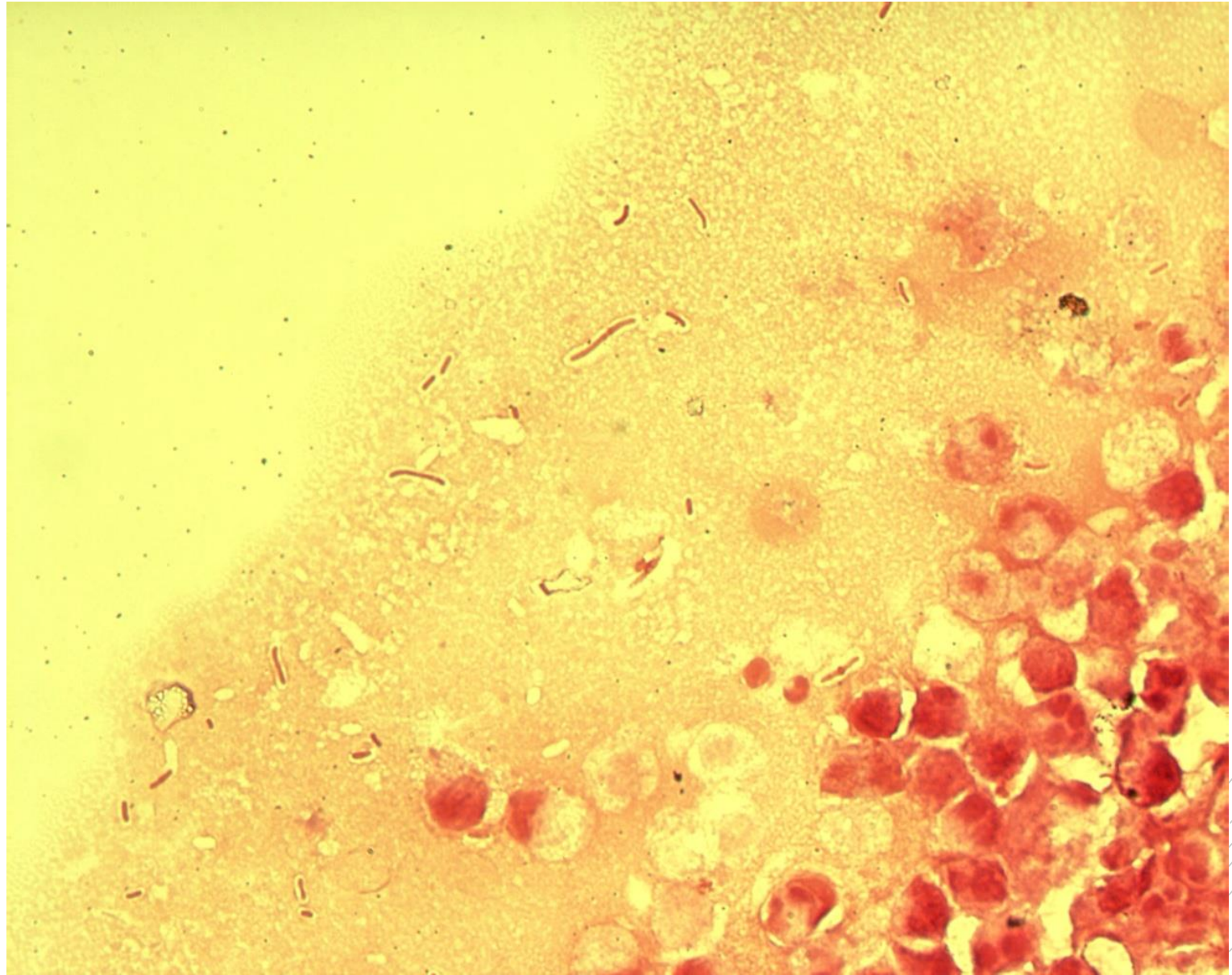
Klebsiella pneumoniae

Specimen: gall

Patient: female, 62 years old

Dg.: gallbladder inflammation

Microscopy: Gram-negative rods



Author: MUDr. Alena Pířová



CHARLES UNIVERSITY
Second Faculty of Medicine

Slide No. 79

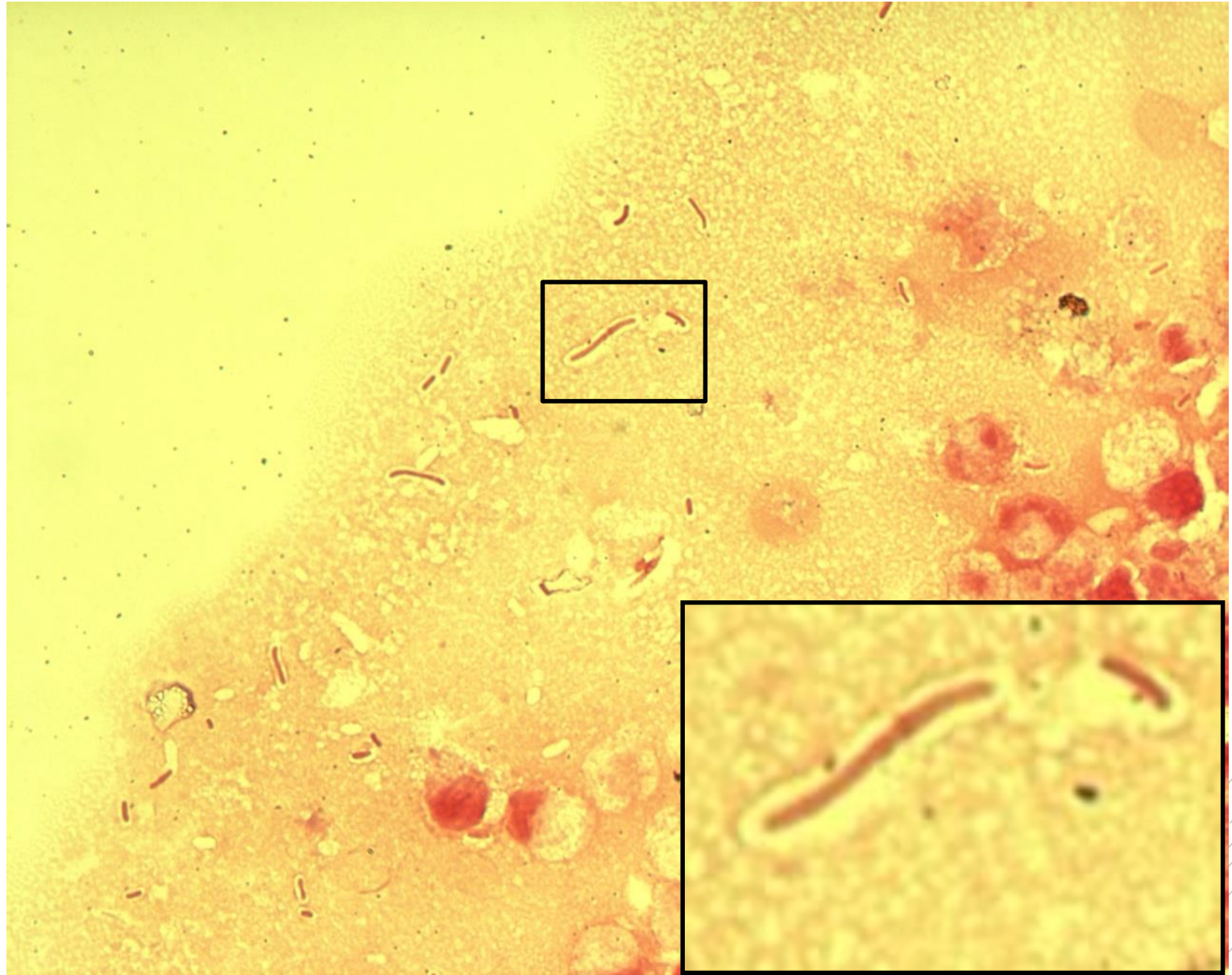
Klebsiella pneumoniae

Specimen: gall

Patient: female, 62 years old

Dg.: gallbladder inflammation

Microscopy: Gram-negative rods



Author: MUDr. Alena Pířová



CHARLES UNIVERSITY
Second Faculty of Medicine

Slide No. 80

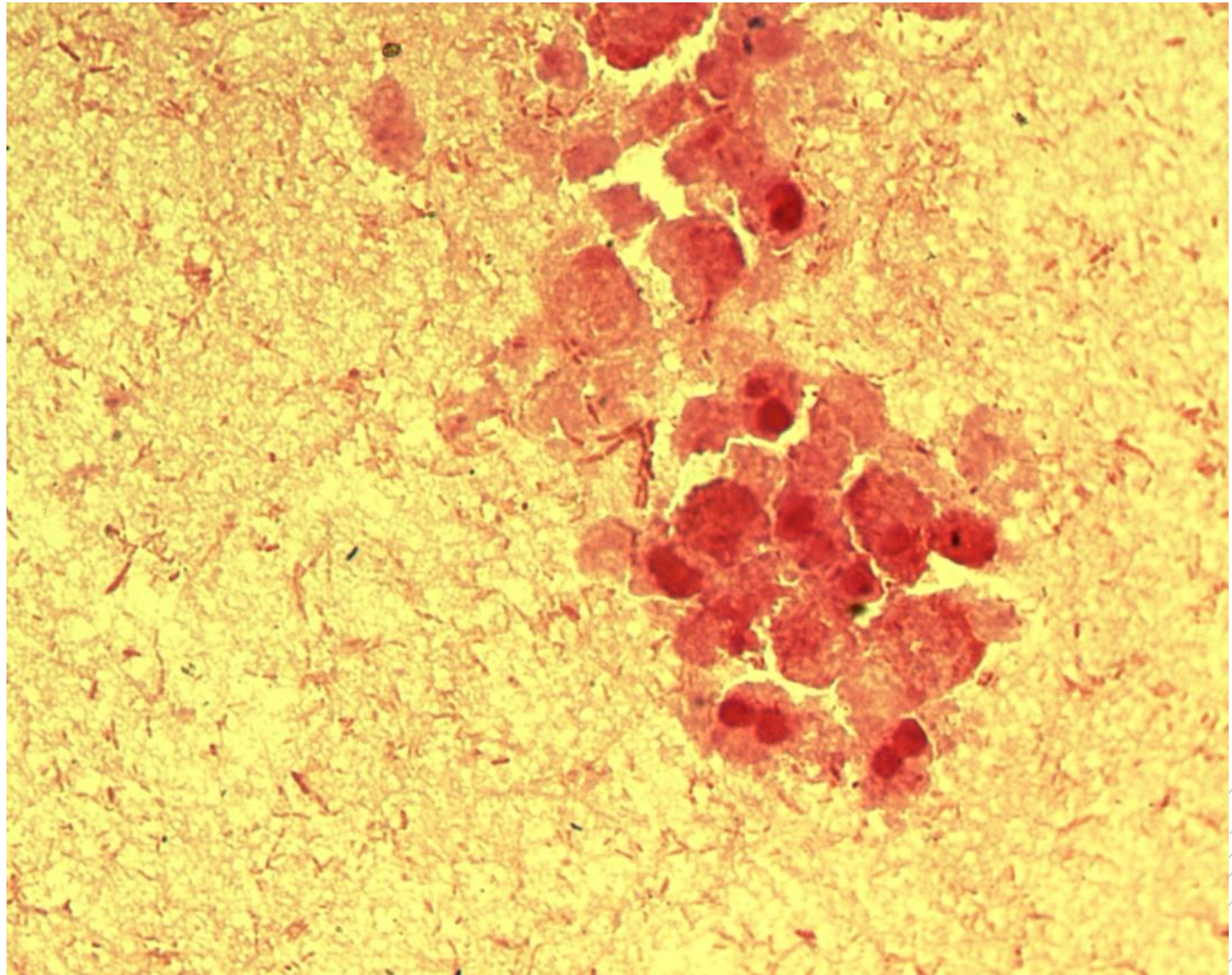
Morganella morganii

Specimen: pus

Patient: male, 86 years old

Dg.: acute peritonitis

Microscopy: Gram-negative rods



Author: MUDr. Alena Píšová



CHARLES UNIVERSITY
Second Faculty of Medicine

Slide No. 80

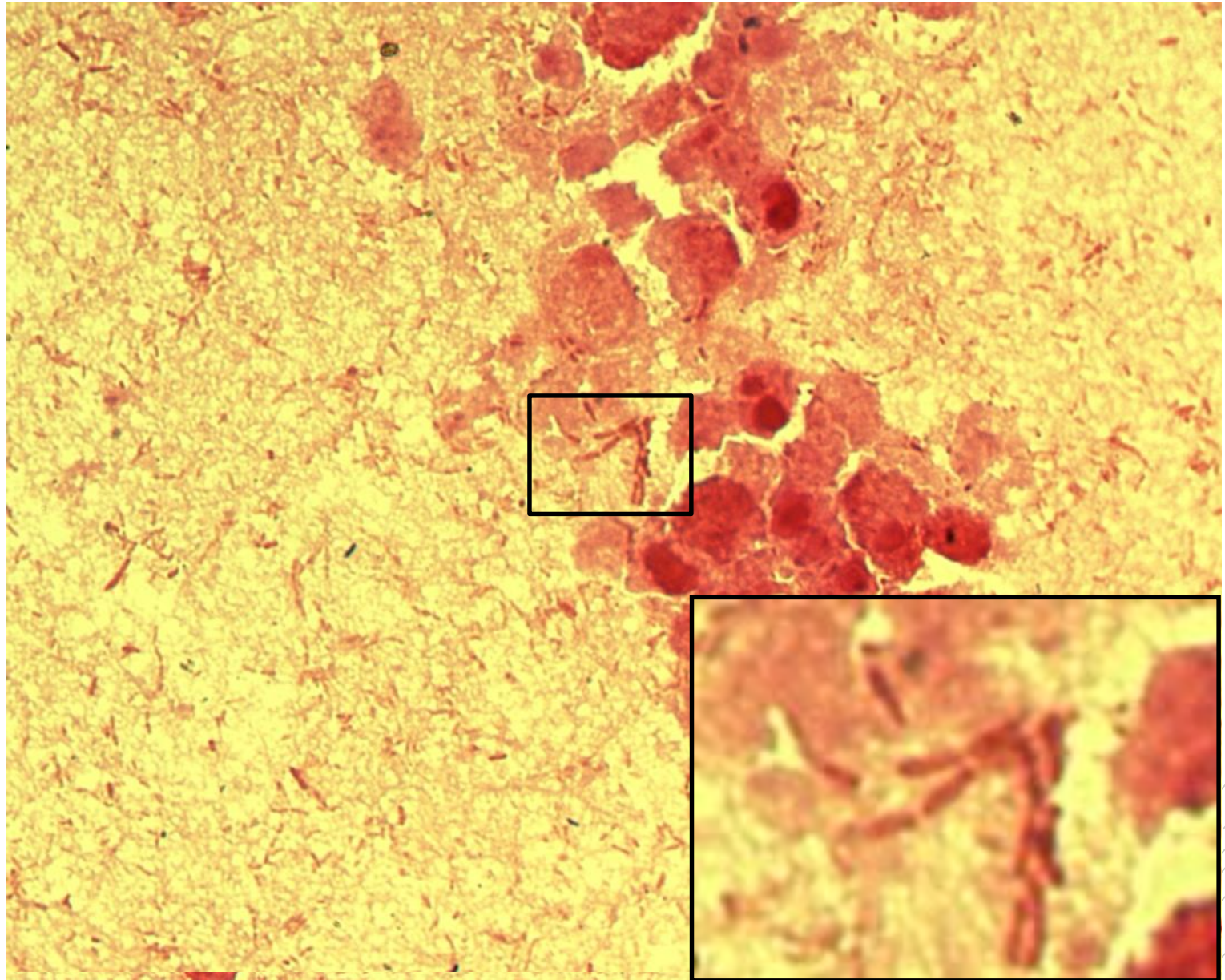
Morganella morganii

Specimen: pus

Patient: male, 86 years old

Dg.: acute peritonitis

Microscopy: Gram-negative rods



Author: MUDr. Alena Pířová

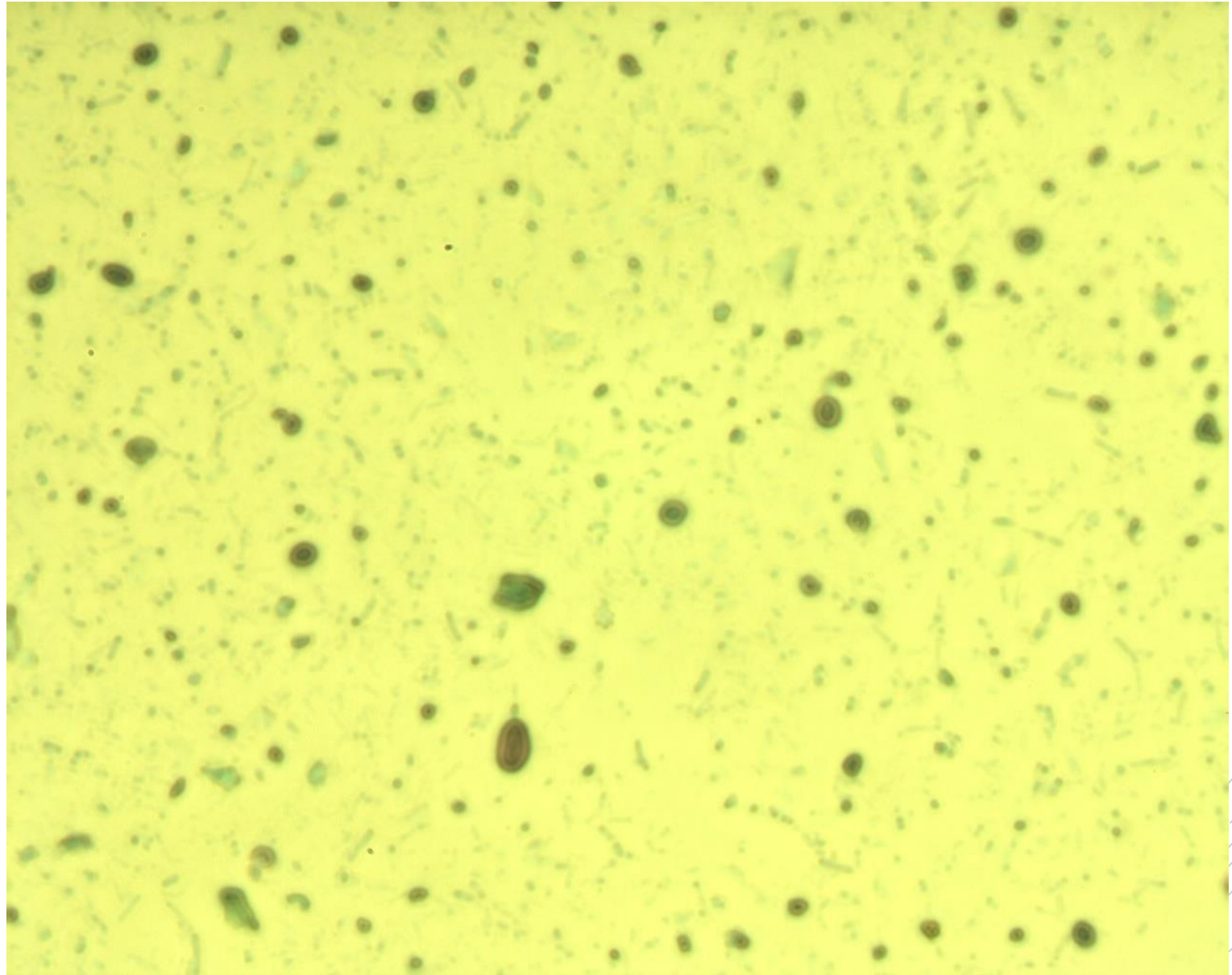


CHARLES UNIVERSITY
Second Faculty of Medicine

Slide No. 81

Cryptosporidium *spp.*

Specimen: stools
Patient: female, 28 years old
Dg.: gastroenteritis
Microscopy: oocysts



Author: MUDr. Kamila Dundrová

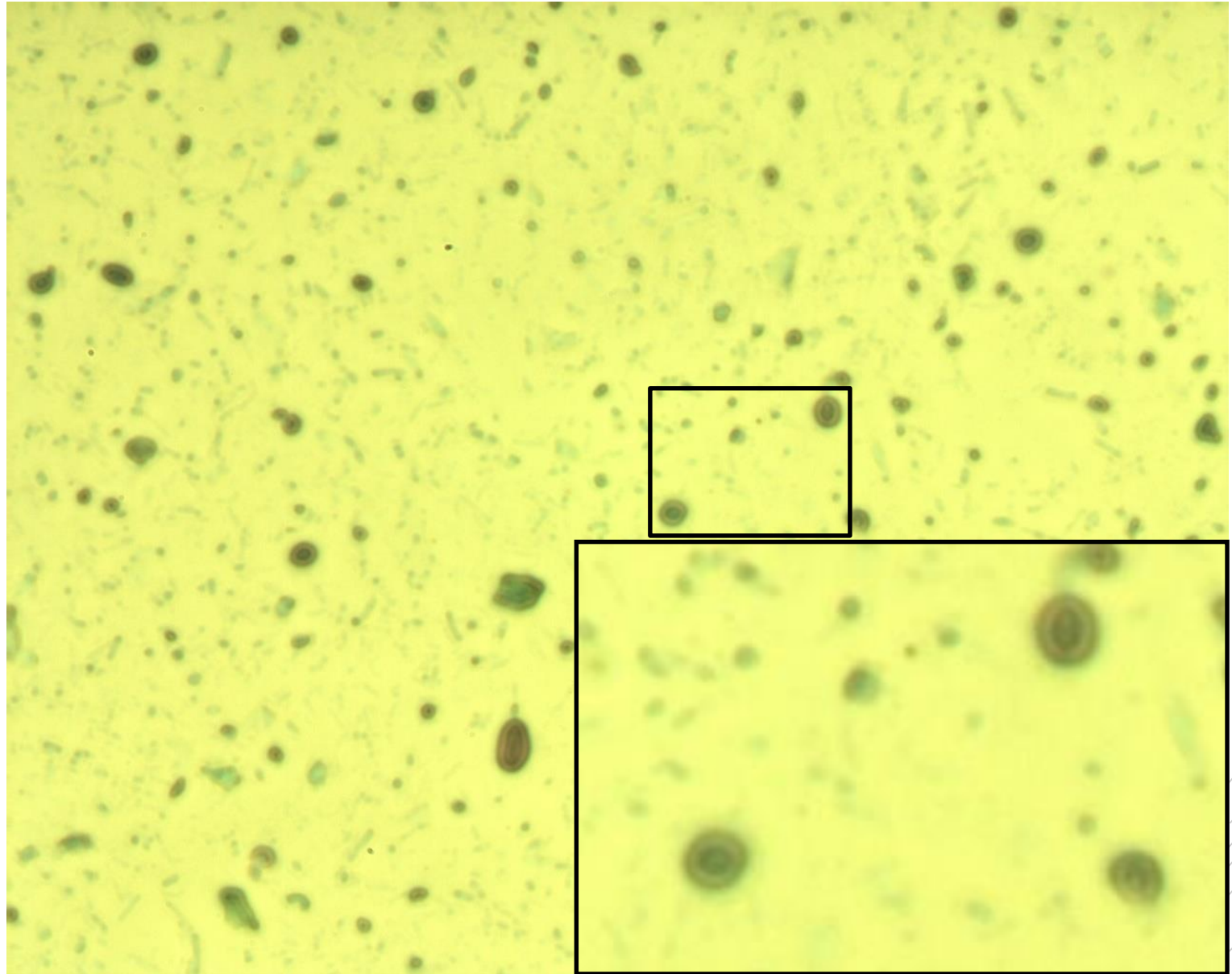


CHARLES UNIVERSITY
Second Faculty of Medicine

Slide No. 81

Cryptosporidium *spp.*

Specimen: stools
Patient: female, 28 years old
Dg.: gastroenteritis
Microscopy: oocysts



Author: MUDr. Kamila Dundrová



CHARLES UNIVERSITY
Second Faculty of Medicine

Slide No. 82

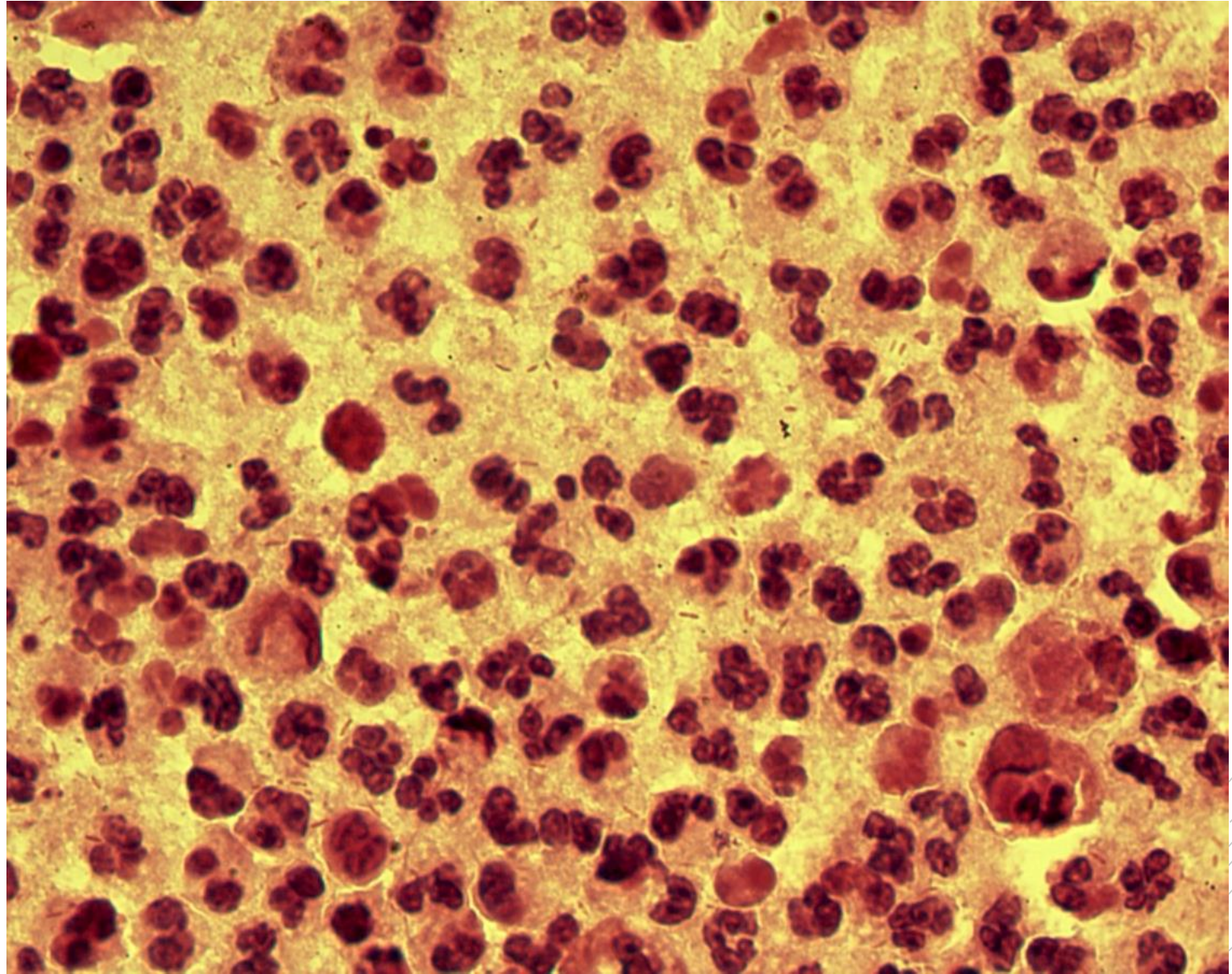
Bacteroides fragilis

Specimen: pus

Patient: female, 39 years old

Dg.: rectal abscess

Microscopy: Gram-negative rods



Author: MUDr. Alena Pířová



CHARLES UNIVERSITY
Second Faculty of Medicine

Slide No. 82

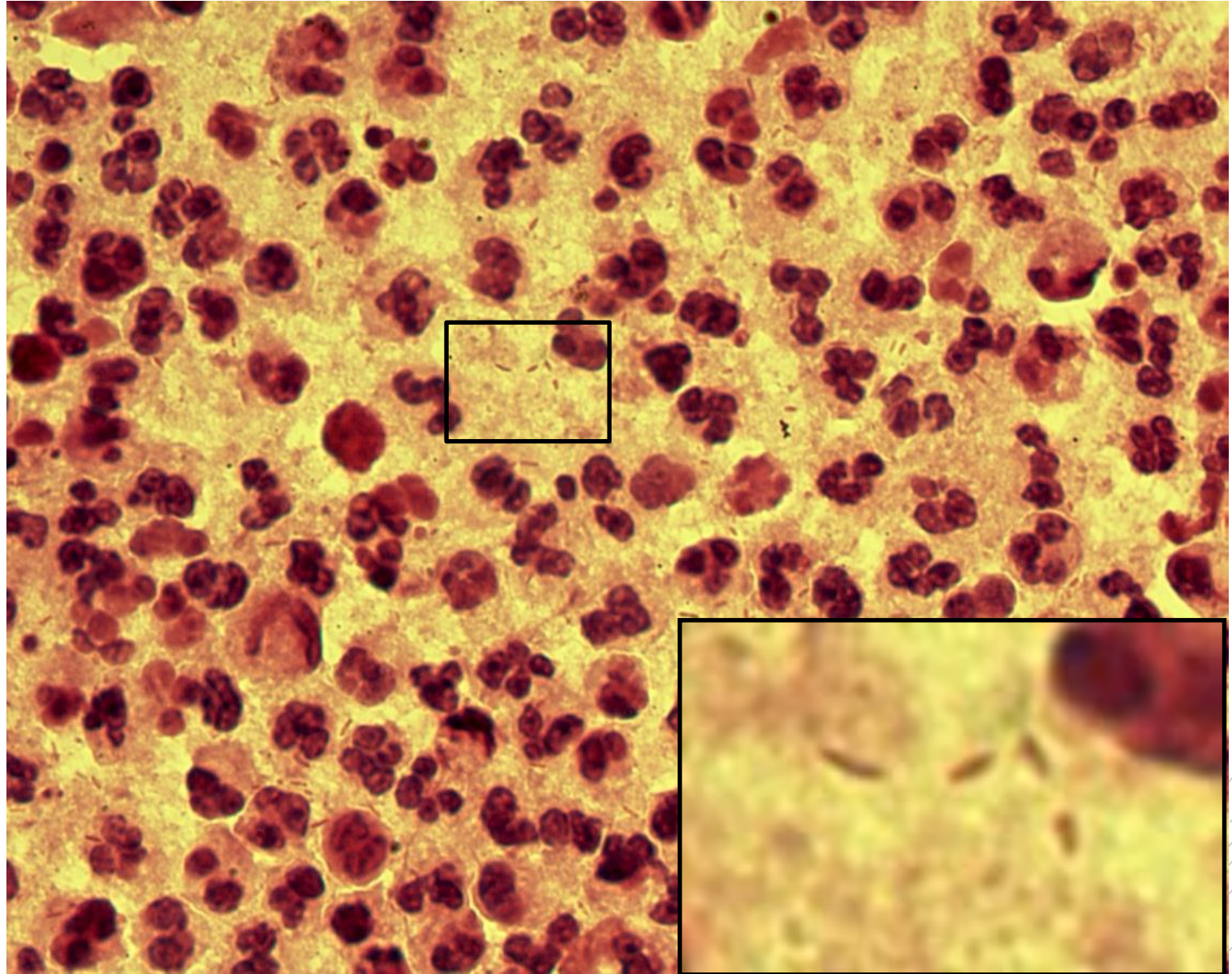
Bacteroides fragilis

Specimen: pus

Patient: female, 39 years old

Dg.: rectal abscess

Microscopy: Gram-negative rods



Author: MUDr. Alena Píšová



CHARLES UNIVERSITY
Second Faculty of Medicine

Slide No. 83

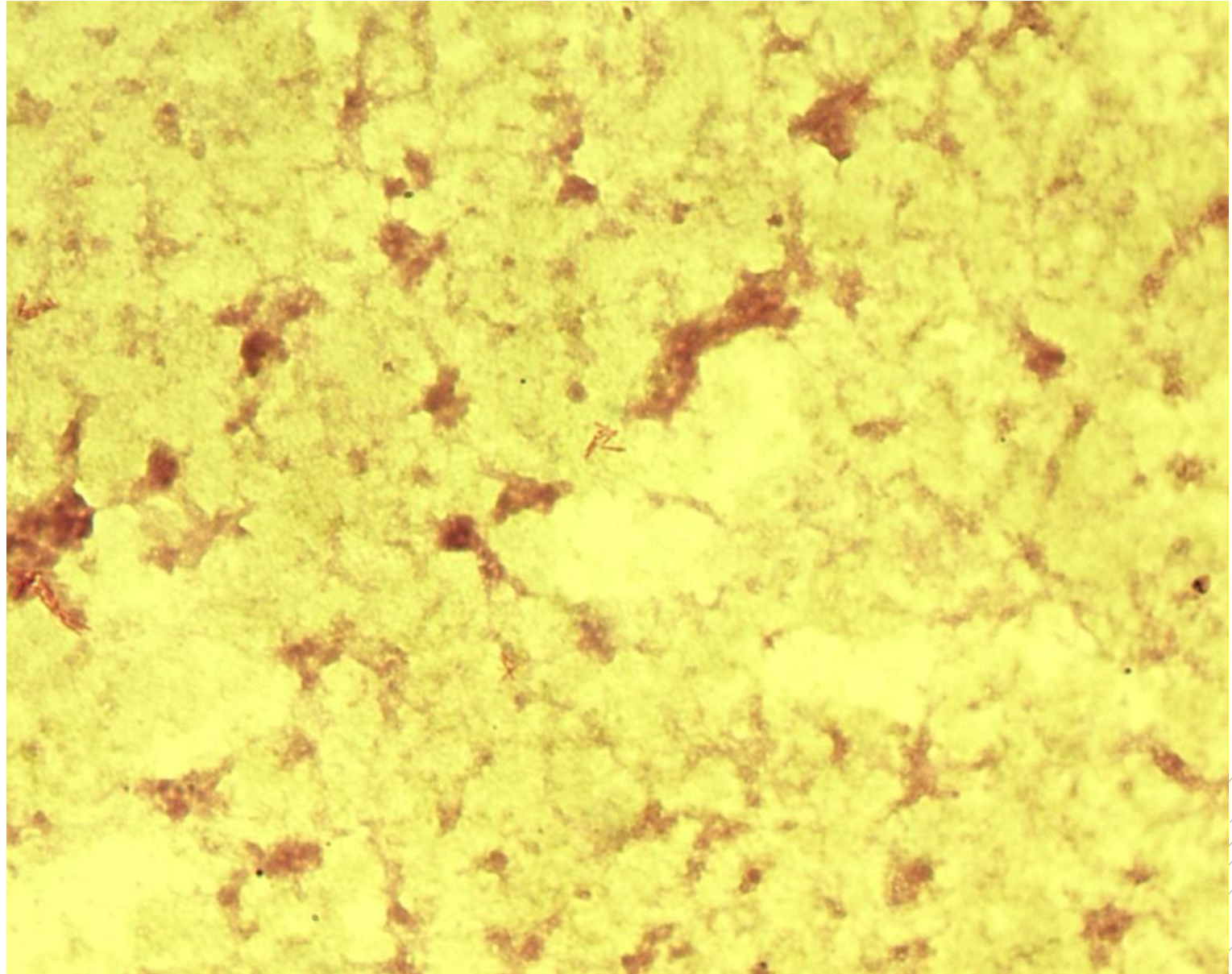
Mycobacterium abscessus

Specimen: pus

Patient: female, 20 years old

Dg.: lung abscess

Microscopy: acidoresistant rods,
Ziehl-Neelsen stain



Author: MUDr. Alena Pířová



CHARLES UNIVERSITY
Second Faculty of Medicine

Slide No. 83

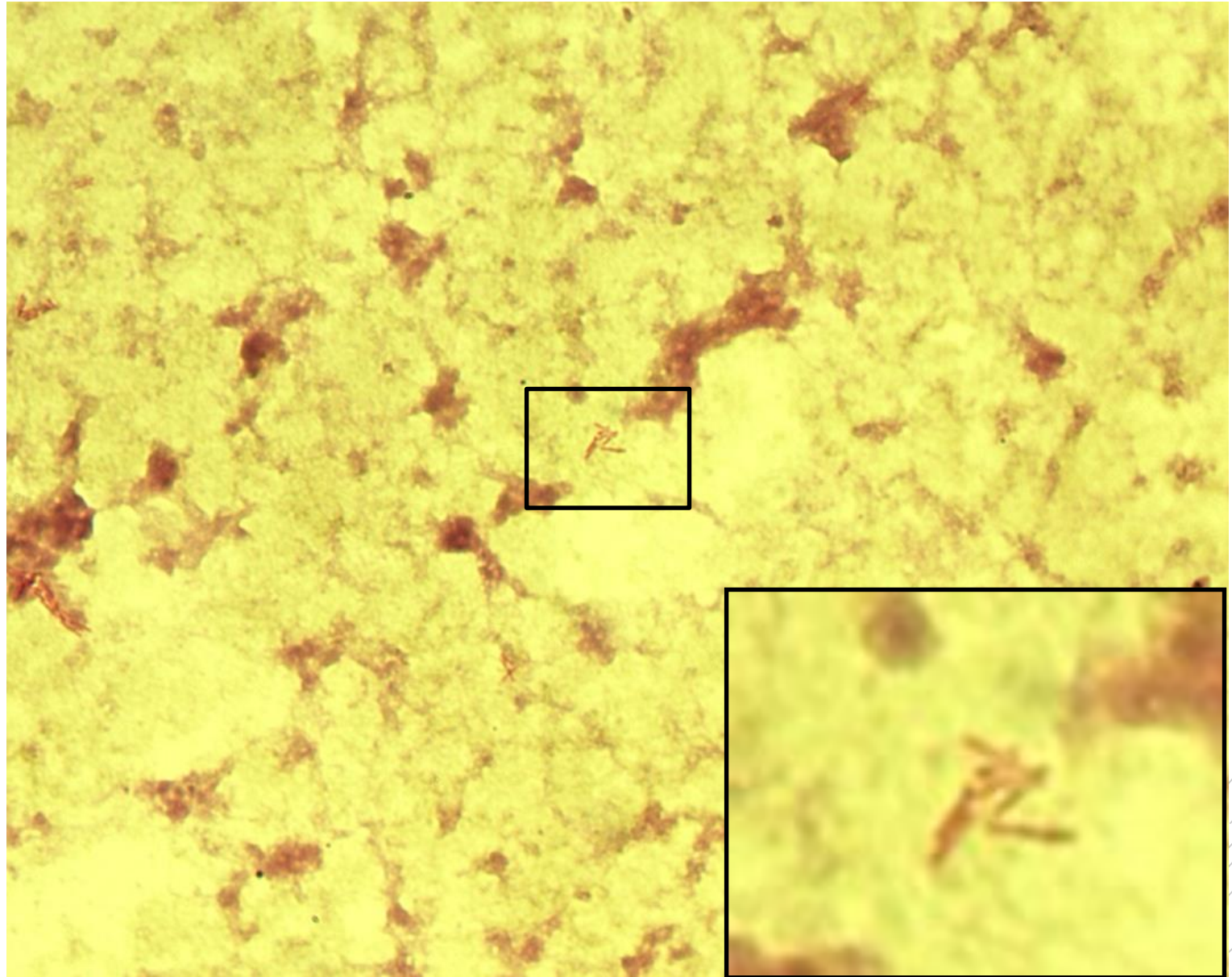
Mycobacterium abscessus

Specimen: pus

Patient: female, 20 years old

Dg.: lung abscess

Microscopy: acidoresistant rods,
Ziehl-Neelsen stain



Author: MUDr. Alena Pířová



CHARLES UNIVERSITY
Second Faculty of Medicine

Slide No. 84


Legionella pneumophila

Specimen: sputum

Patient: male, 65 years old

Dg.: pneumonia

Microscopy: Gram-negative rods



Author: doc. MVDr. Oto Melter, PhD.



CHARLES UNIVERSITY
Second Faculty of Medicine

Slide No. 84


Legionella pneumophila

Specimen: sputum

Patient: male, 65 years old

Dg.: pneumonia

Microscopy: Gram-negative rods



Author: doc. MVDr. Oto Melter, PhD.



CHARLES UNIVERSITY
Second Faculty of Medicine

Slide No. 85

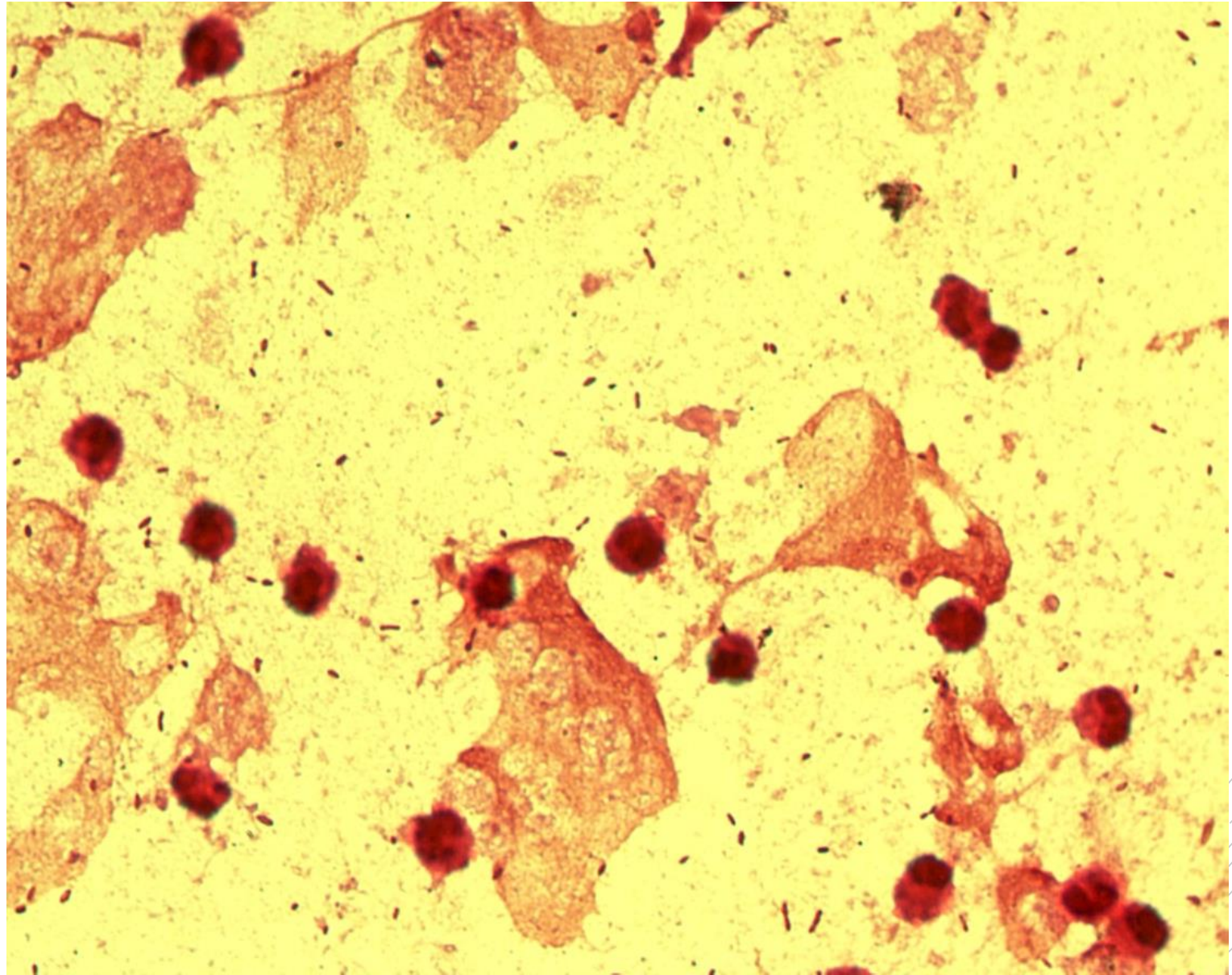
Haemophilus influenzae

Specimen: sputum

Patient: male, 58 years old

Dg.: pneumonia

Microscopy: Gram-negative rods



Author: MUDr. Alena Pířová



CHARLES UNIVERSITY
Second Faculty of Medicine

Slide No. 85

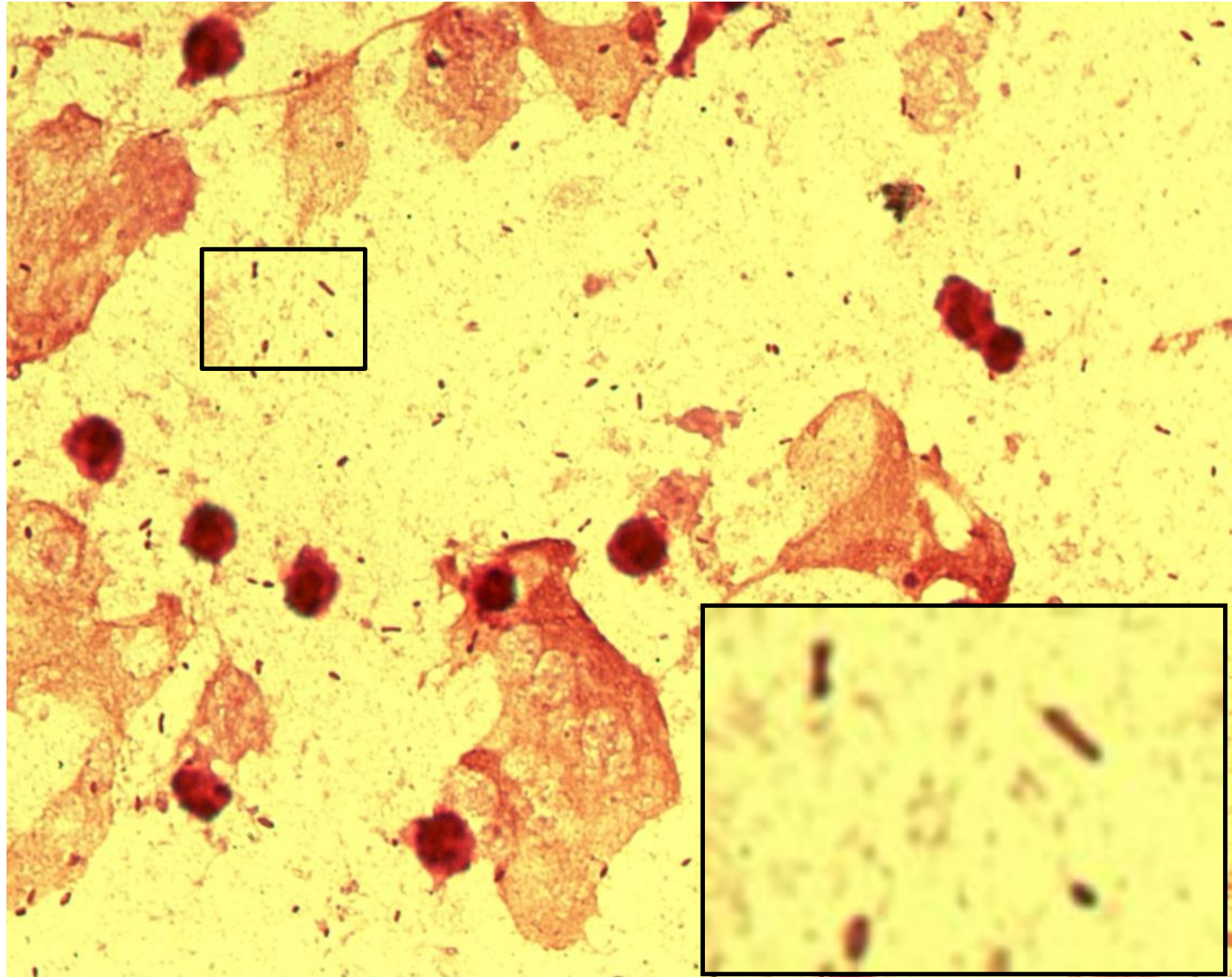
Haemophilus influenzae

Specimen: sputum

Patient: male, 58 years old

Dg.: pneumonia

Microscopy: Gram-negative rods



Author: MUDr. Alena Píšová



CHARLES UNIVERSITY
Second Faculty of Medicine

Slide No. 86

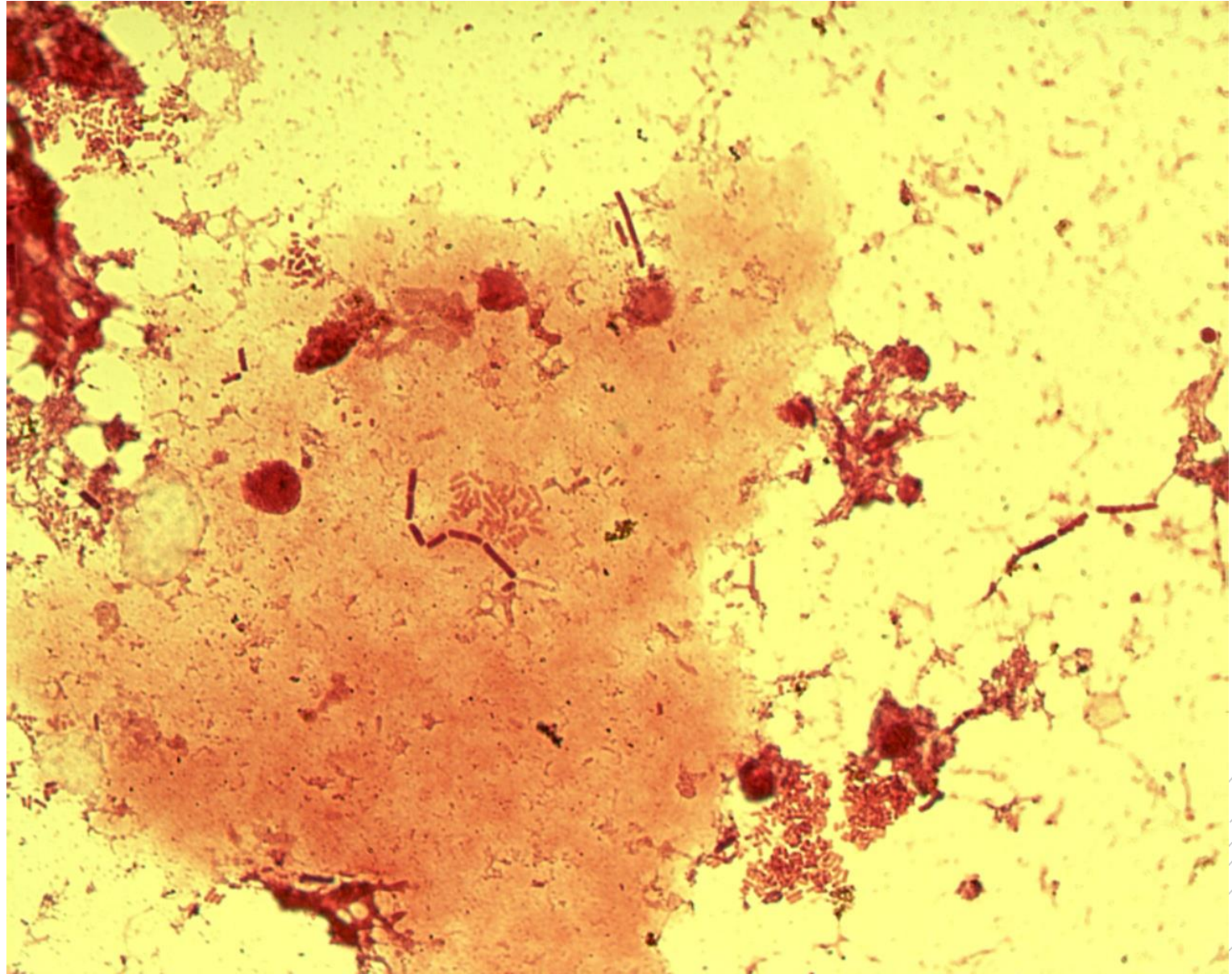
Escherichia coli,
Bacteroides
fragilis

Specimen: gall

Patient: female, 60 years old

Dg.: gallbladder inflammation

Microscopy: Gram-negative rods



Author: MUDr. Alena Pířová



CHARLES UNIVERSITY
Second Faculty of Medicine

Slide No. 86

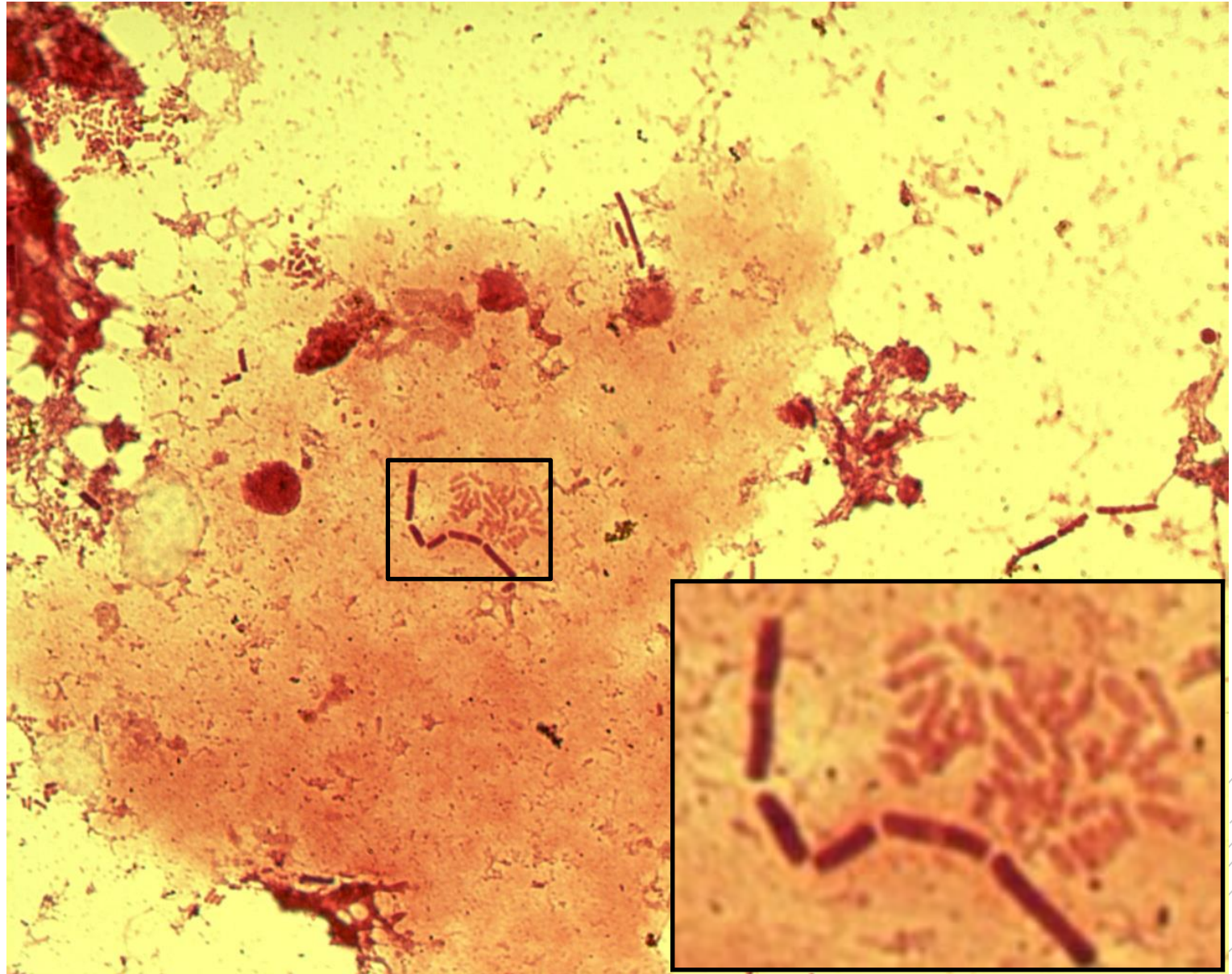
Escherichia coli,
Bacteroides fragilis

Specimen: gall

Patient: female, 60 years old

Dg.: gallbladder inflammation

Microscopy: Gram-negative rods



Author: MUDr. Alena Pířová



CHARLES UNIVERSITY
Second Faculty of Medicine

Slide No. 87

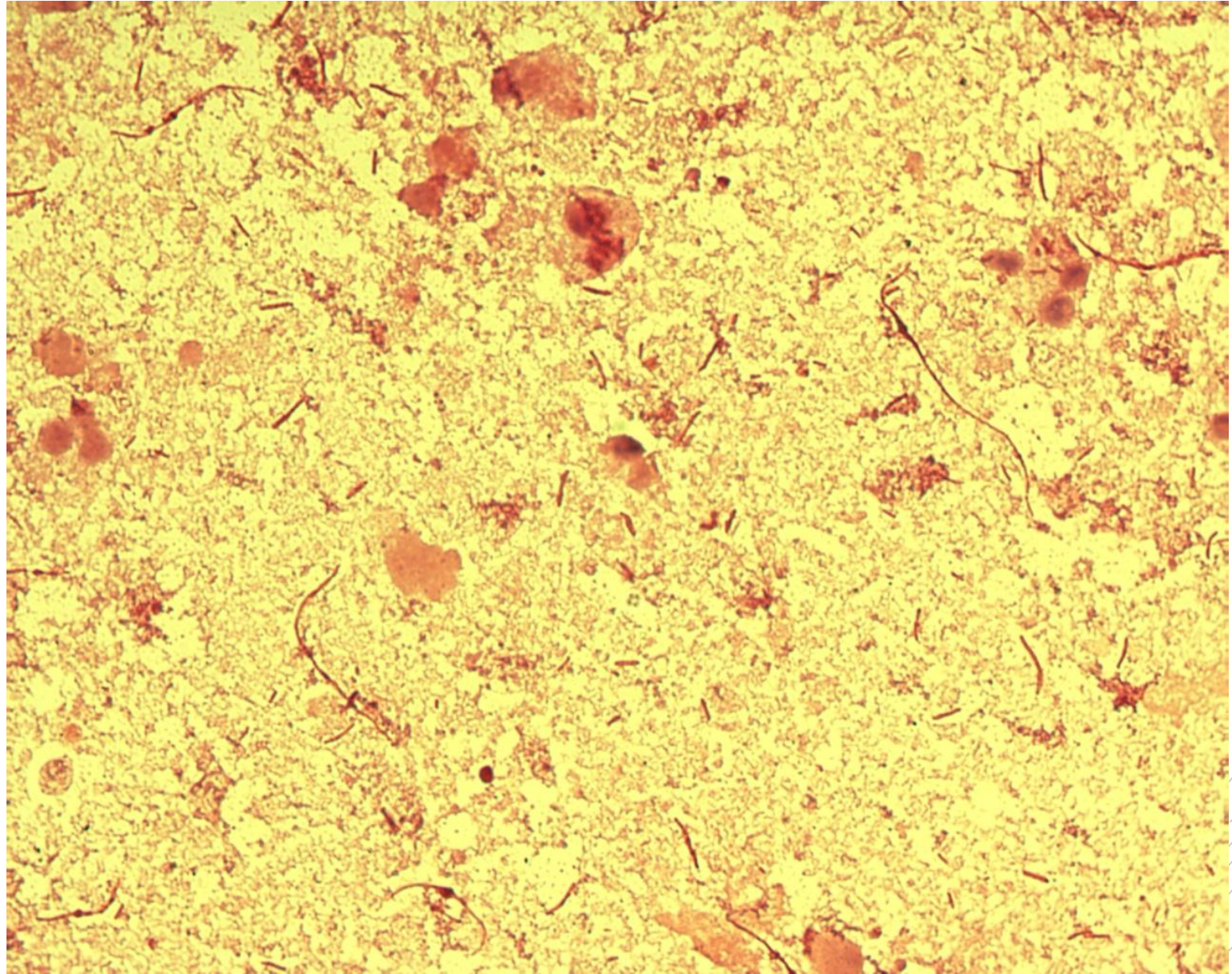
Proteus mirabilis

Specimen: Urine

Patient: female, 85 years old

Dg.: acute nephritis

Microscopy: Gram-negative rods



Author: MUDr. Alena Pířová



CHARLES UNIVERSITY
Second Faculty of Medicine

Slide No. 87

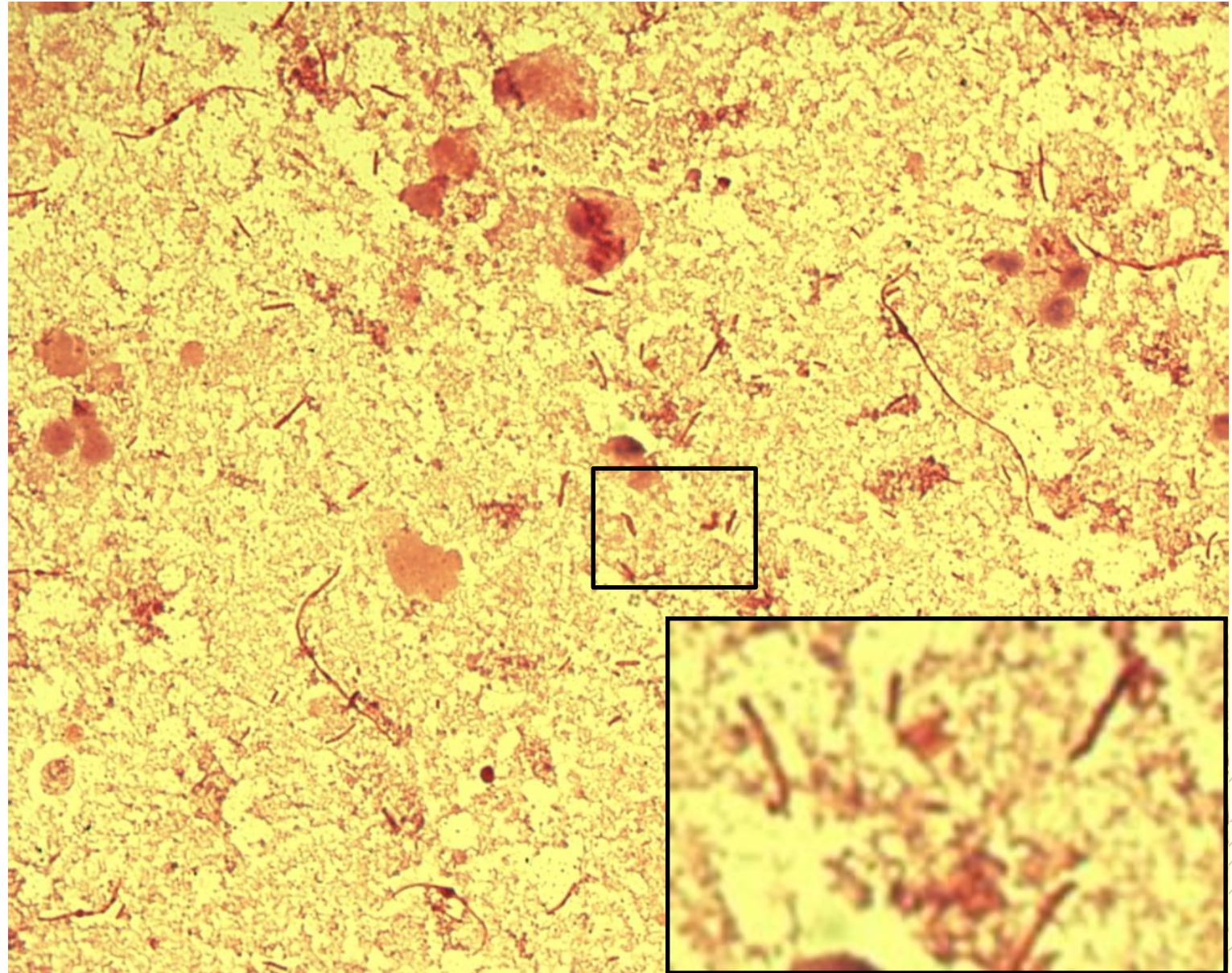
Proteus mirabilis

Specimen: Urine

Patient: female, 85 years old

Dg.: acute nephritis

Microscopy: Gram-negative rods



Author: MUDr. Alena Pířová



CHARLES UNIVERSITY
Second Faculty of Medicine

Slide No. 88

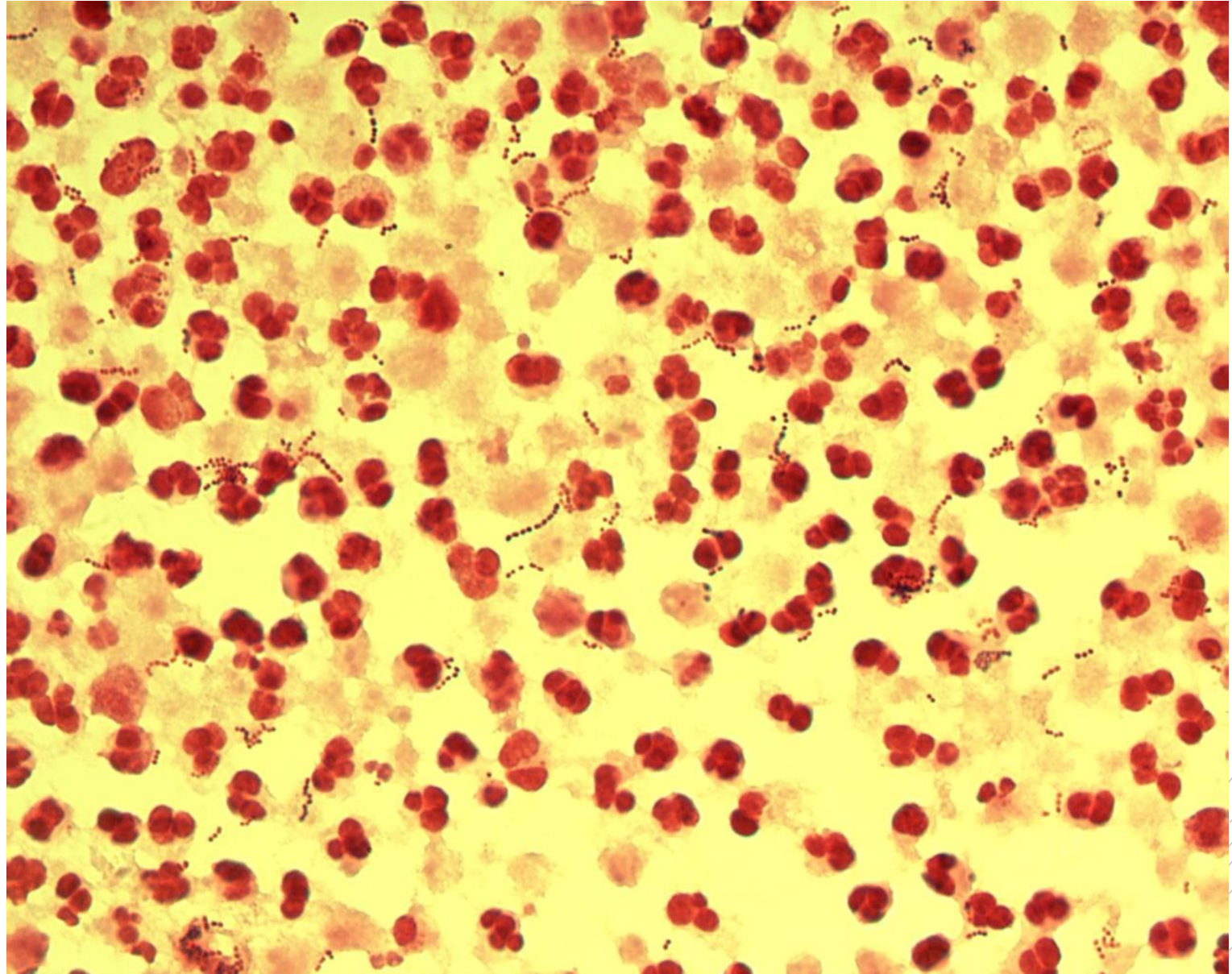
Streptococcus agalactiae

Specimen: pus

Patient: male, 68 years old

Dg.: abscess

Microscopy: Gram-positive cocci
in chains



Author: MUDr. Alena Pířová



CHARLES UNIVERSITY
Second Faculty of Medicine

Slide No. 88


Streptococcus agalactiae

Specimen: pus

Patient: male, 68 years old

Dg.: abscess

Microscopy: Gram-positive cocci
in chains



Author: MUDr. Alena Pířová



CHARLES UNIVERSITY
Second Faculty of Medicine

Slide No. 89

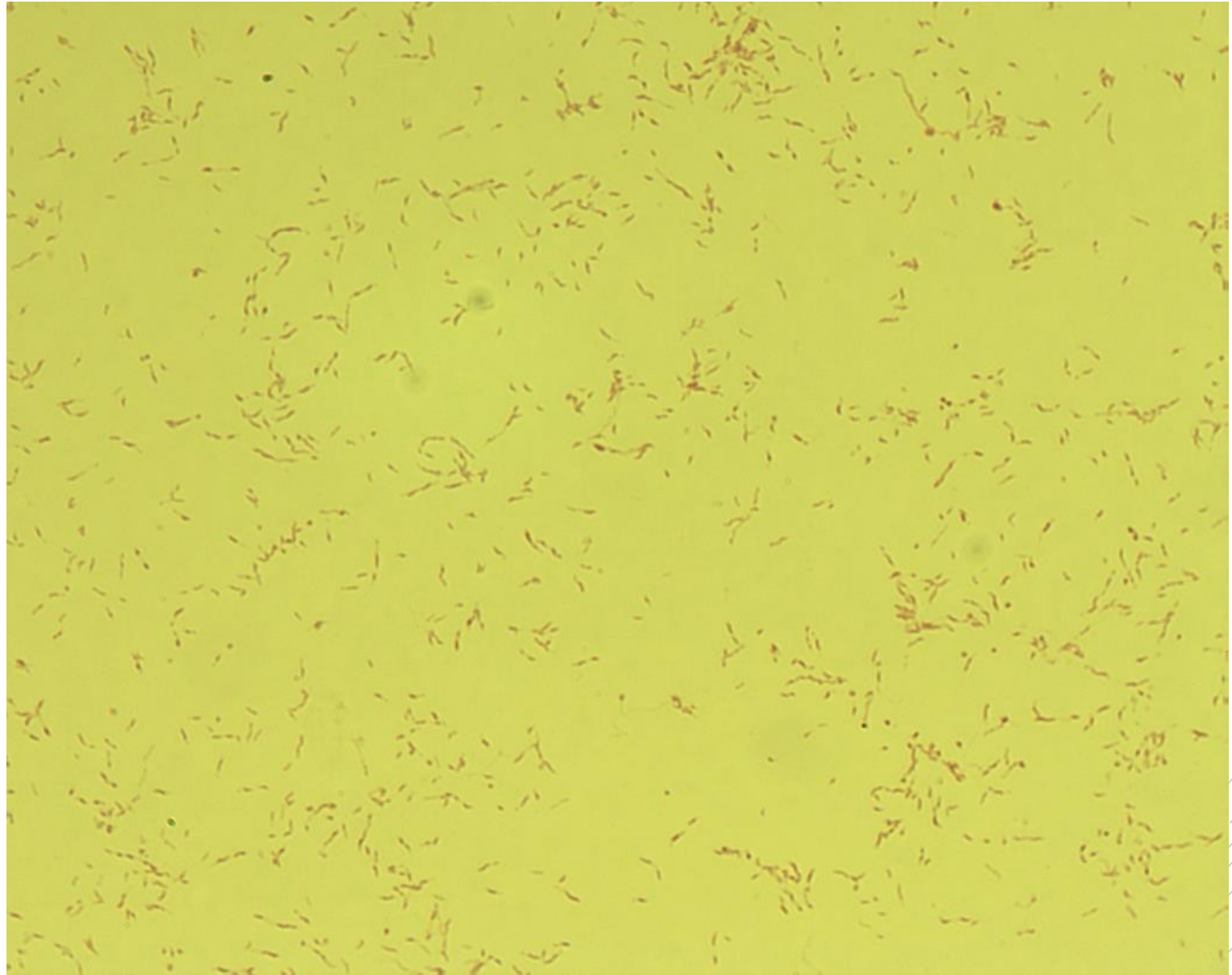
Campylobacter jejuni

Specimen: culture

Patient: male, 21 years old

Dg.: diarrhoea

Microscopy: spiral-shaped
Gram-negative rods



Author: MUDr. Svojtková, MUDr. Šolarová



CHARLES UNIVERSITY
Second Faculty of Medicine

Slide No. 89


Campylobacter jejuni

Specimen: culture

Patient: male, 21 years old

Dg.: diarrhoea

Microscopy: spiral-shaped
Gram-negative rods



Author: MUDr. Svojtková, MUDr. Šolarová



CHARLES UNIVERSITY
Second Faculty of Medicine

Slide No. 90

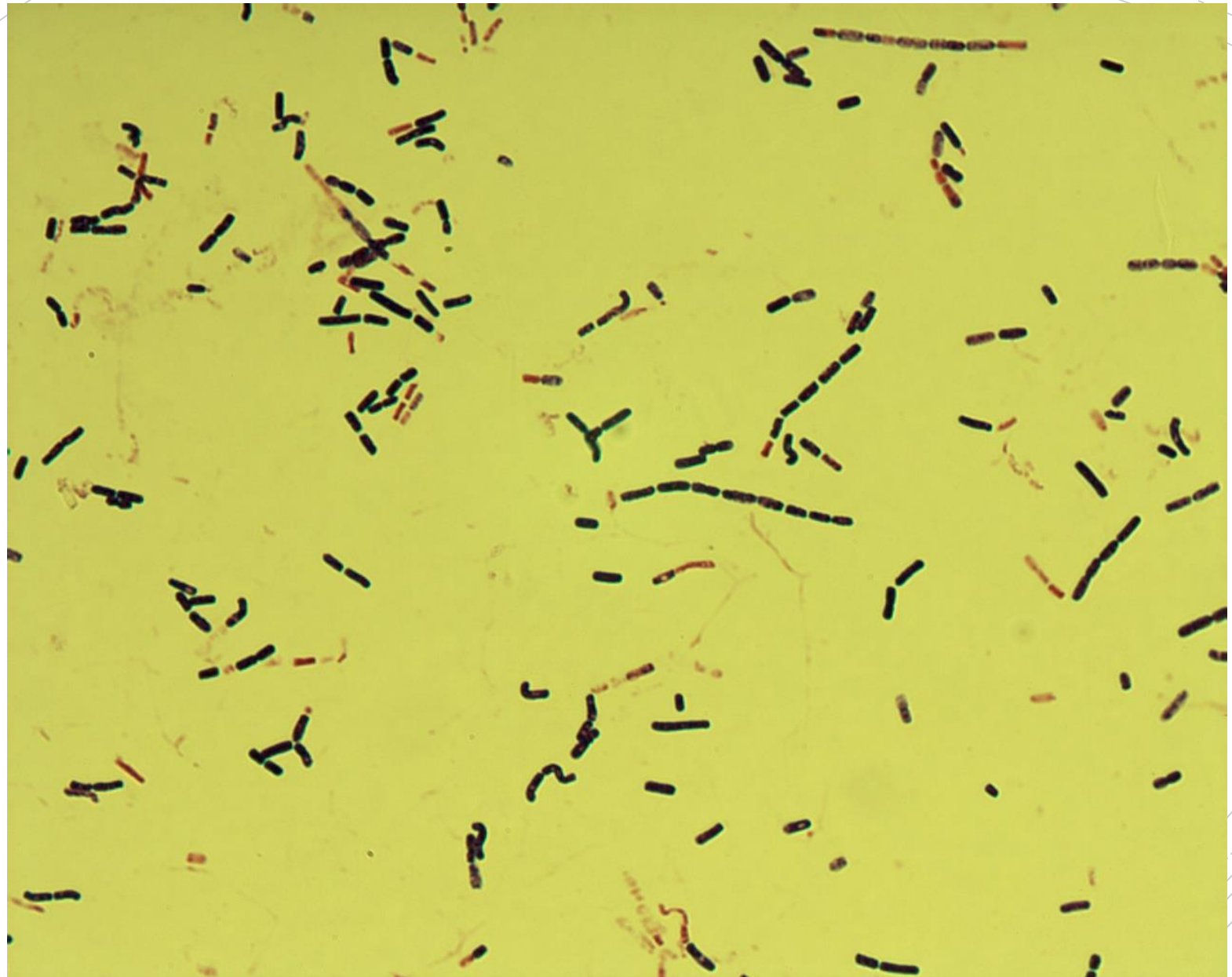
Bacillus cereus

Specimen: culture, suspected meal source

Patient: female, 38 years old

Dg.: enterotoxigenic

Microscopy: Gram-positive rod



Autor: Markéta Šolarová, Hanka Svojtková



CHARLES UNIVERSITY
Second Faculty of Medicine

Slide No. 90

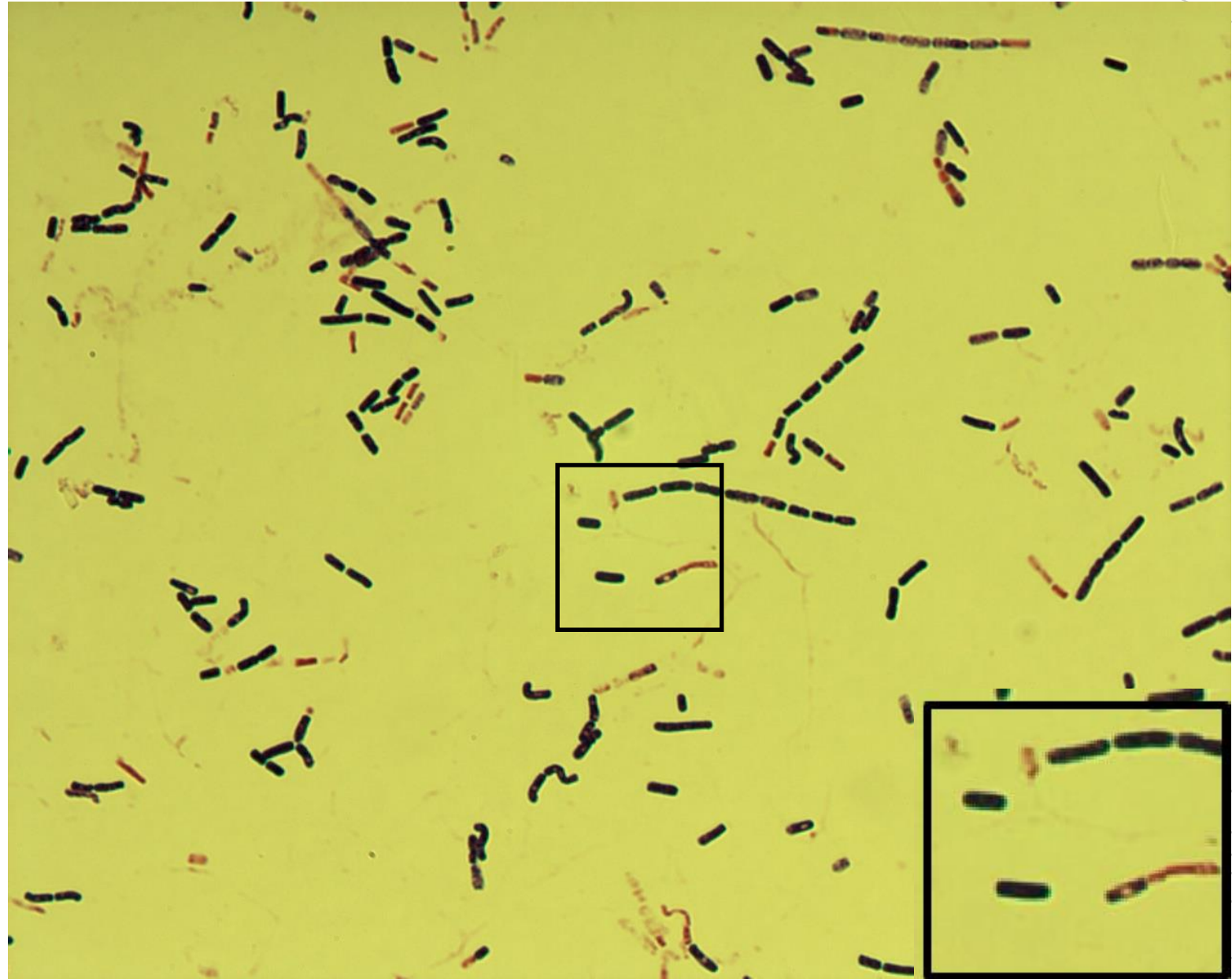
Bacillus cereus

Specimen: culture, suspected meal source

Patient: female, 38 years old

Dg.: enterotoxigenic

Microscopy: Gram-positive rod



Autor: Markéta Šolarová, Hanka Svojtková



CHARLES UNIVERSITY
Second Faculty of Medicine

Slide No. 91


Acinetobacter baumannii

Specimen: pus

Patient: male, 44 years old

Dg.: perforation of esophagus

Microscopy: Gram-negative rod



Autor: Markéta Šolarová, Hanka Svojtková



CHARLES UNIVERSITY
Second Faculty of Medicine

Slide No. 91


Acinetobacter baumannii

Specimen: pus

Patient: male, 44 years old

Dg.: perforation of esophagus

Microscopy: Gram-negative rod



Autor: Markéta Šolarová, Hanka Svojtková



CHARLES UNIVERSITY
Second Faculty of Medicine

Slide No. 92

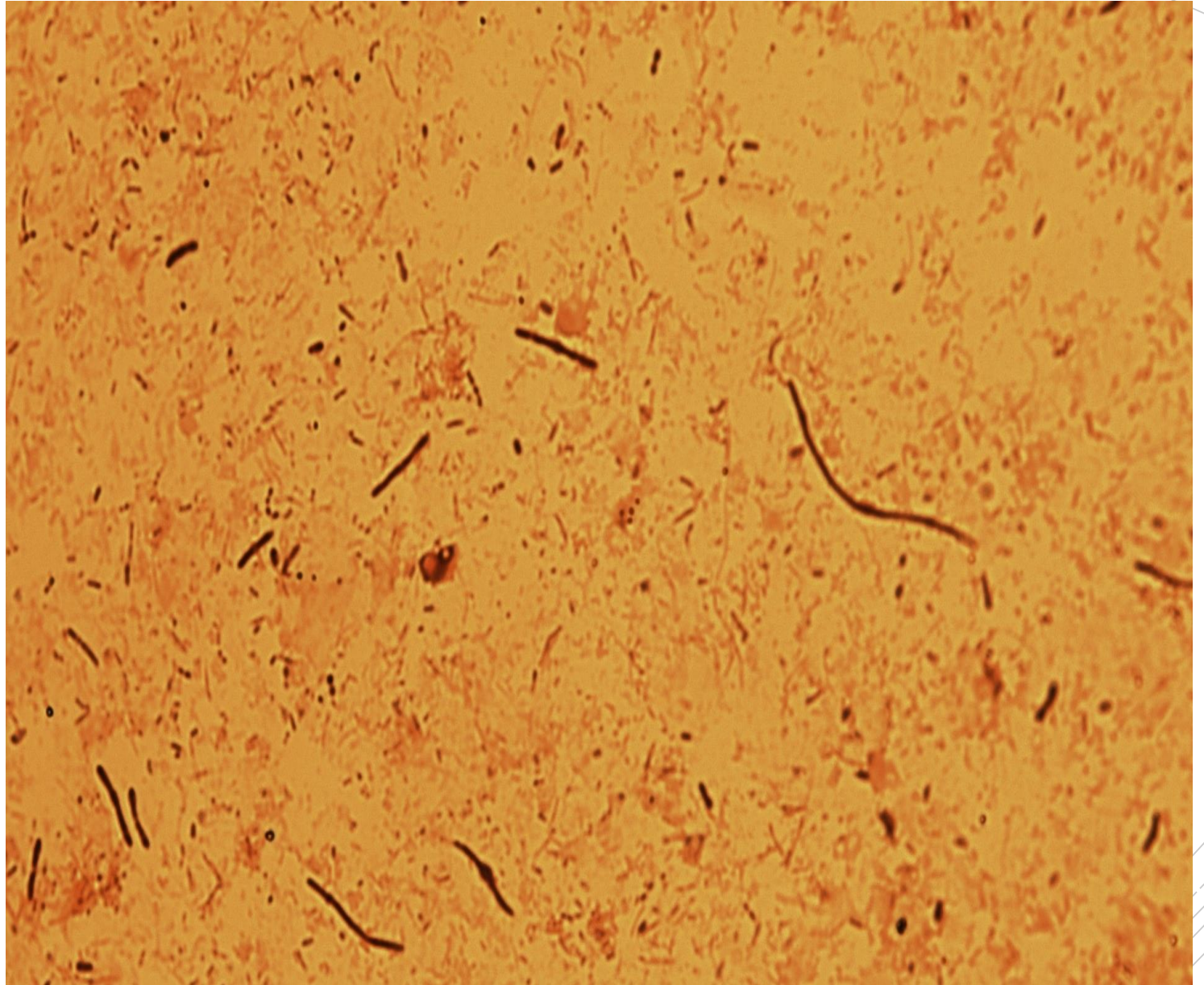
Escherichia,
Klebsiella,
Enterococcus,
C. perfringens

Specimen: pus

Patient: male, 64 years old

Dg.: rectal abscess

Microscopy: polymicrobial flora



Autor: MUDr. Alena Píšová



CHARLES UNIVERSITY
Second Faculty of Medicine

Slide No. 92

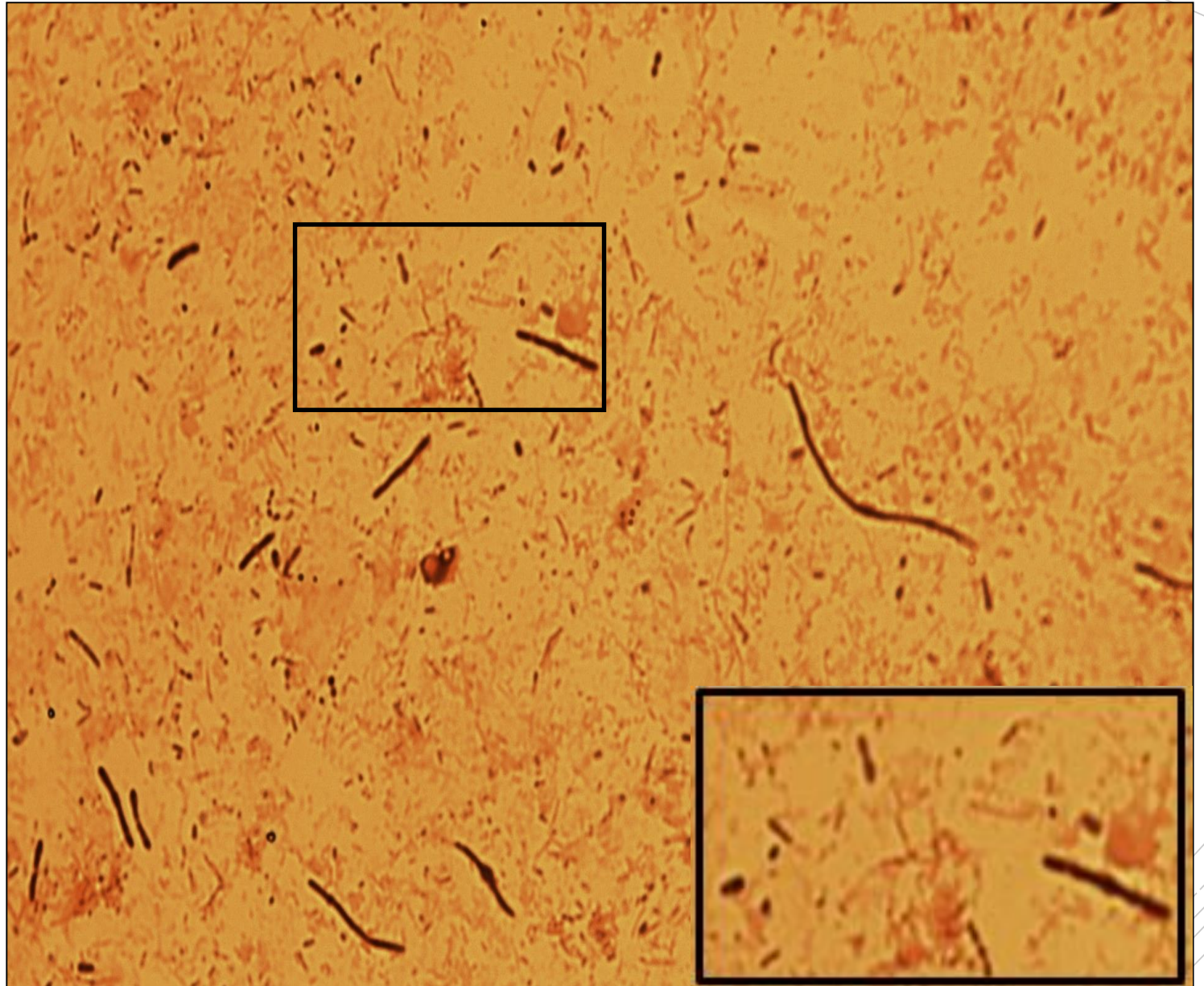
Escherichia,
Klebsiella,
Enterococcus,
C. perfringens

Specimen: pus

Patient: male, 64 years old

Dg.: rectal abscess

Microscopy: polymicrobial flora



Autor: MUDr. Alena Pířová



CHARLES UNIVERSITY
Second Faculty of Medicine

Slide No. 93

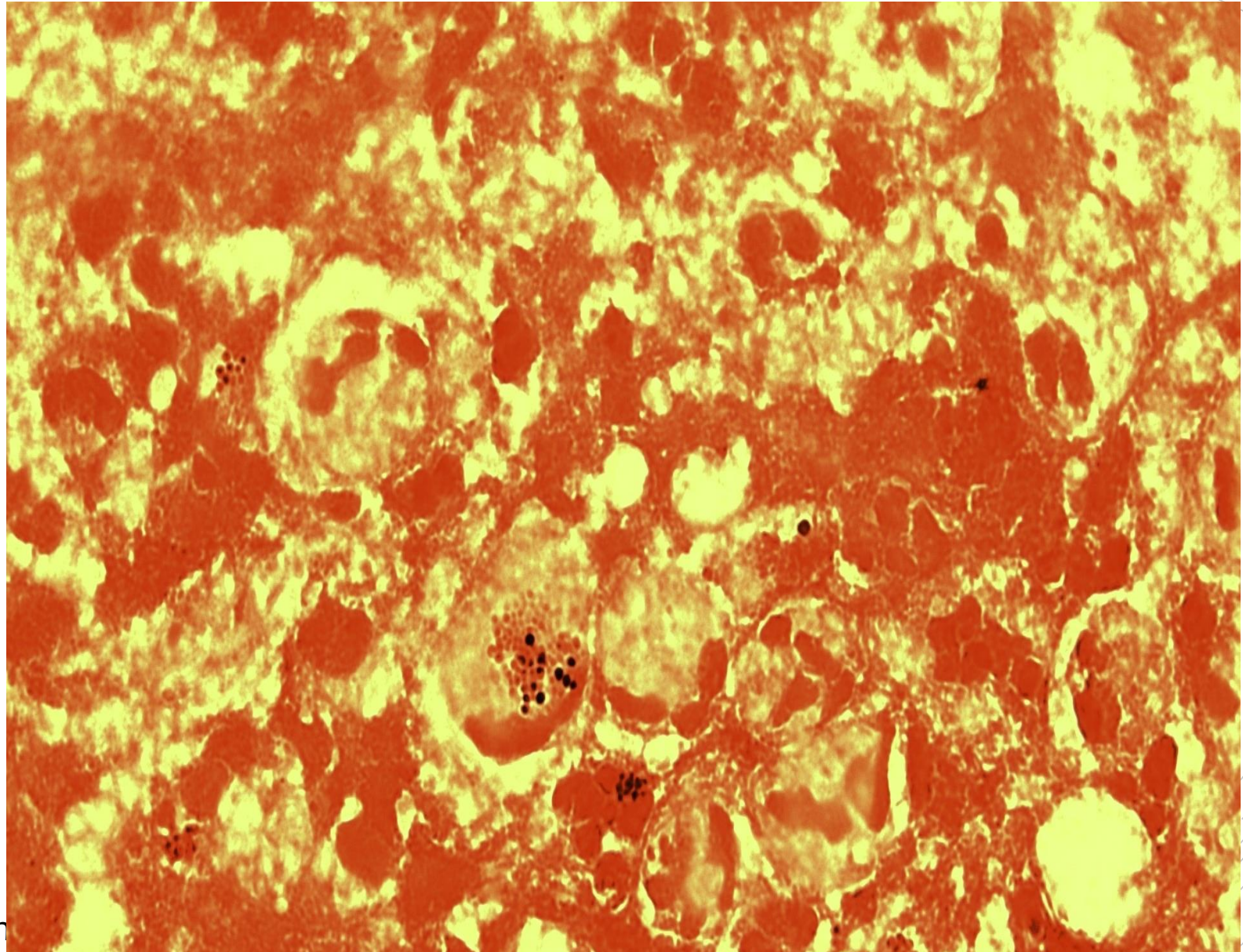
Staphylococcus aureus

Specimen: pus

Patient: male, 57 years old

Dg.: brain abscess

Microscopy: Gram-positive cocci (gram labile cocci within leukocytes)



Autor: MUDr. Alena Pířová



CHARLES UNIVERSITY
Second Faculty of Medicine

Slide No. 93


Staphylococcus aureus

Specimen: pus

Patient: male, 57 years old

Dg.: brain abscess

Microscopy: Gram-positive cocci (gram-labile cocci within leukocytes)



Autor: MUDr. Alena Pířová



CHARLES UNIVERSITY
Second Faculty of Medicine

Slide No. 94

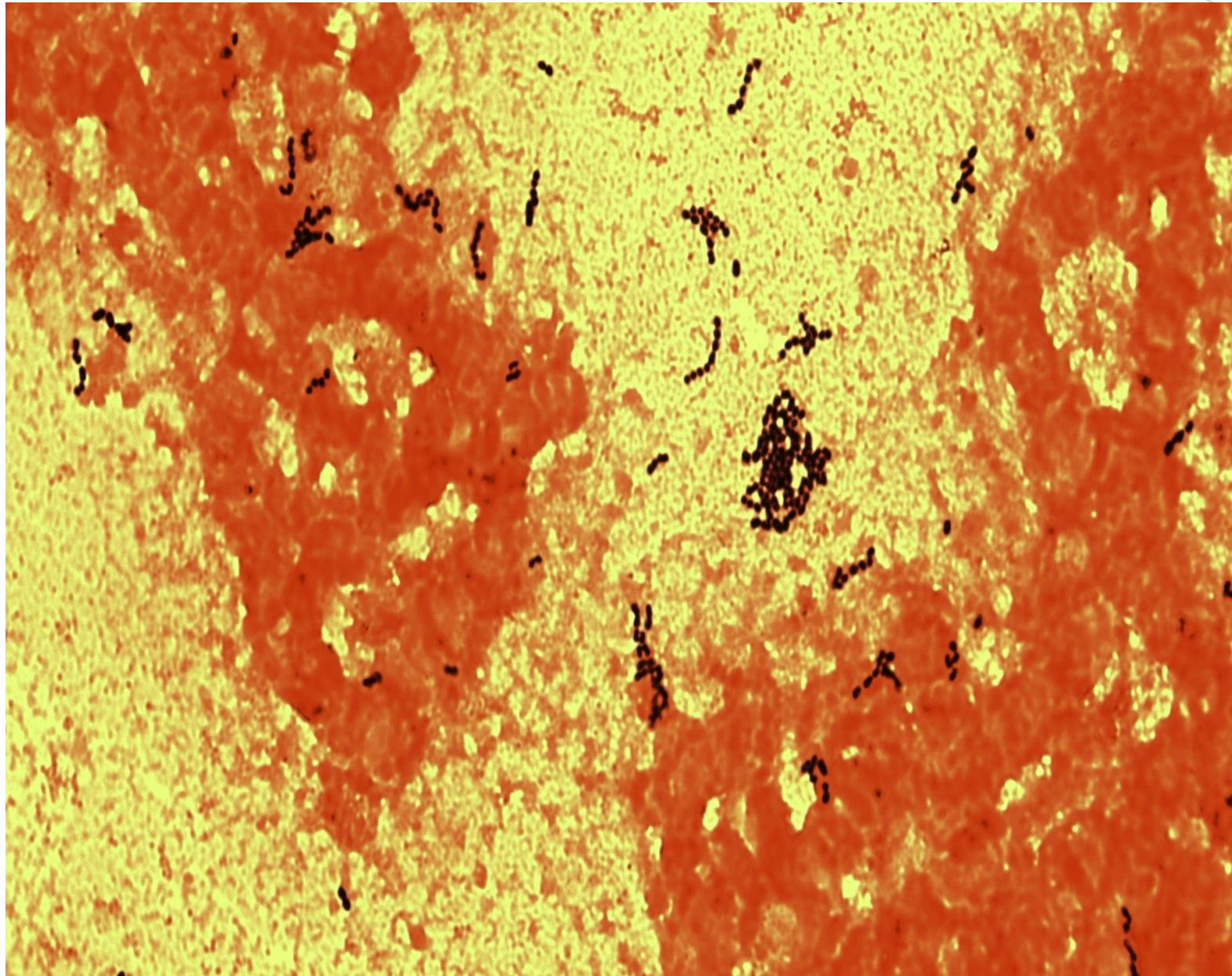
Streptococcus anginosus

Specimen: hemoculture

Patient: female, 44 years old

Dg.: Crohn's disease

Microscopy: Gram-positive cocci



Autor: MUDr. Petra Kabelíková



CHARLES UNIVERSITY
Second Faculty of Medicine

Slide No. 94


Streptococcus anginosus

Specimen: hemoculture

Patient: female, 44 years old

Dg.: Crohn's disease

Microscopy: Gram-positive cocci



Autor: MUDr. Petra Kabelíková



CHARLES UNIVERSITY
Second Faculty of Medicine

Slide No. 95

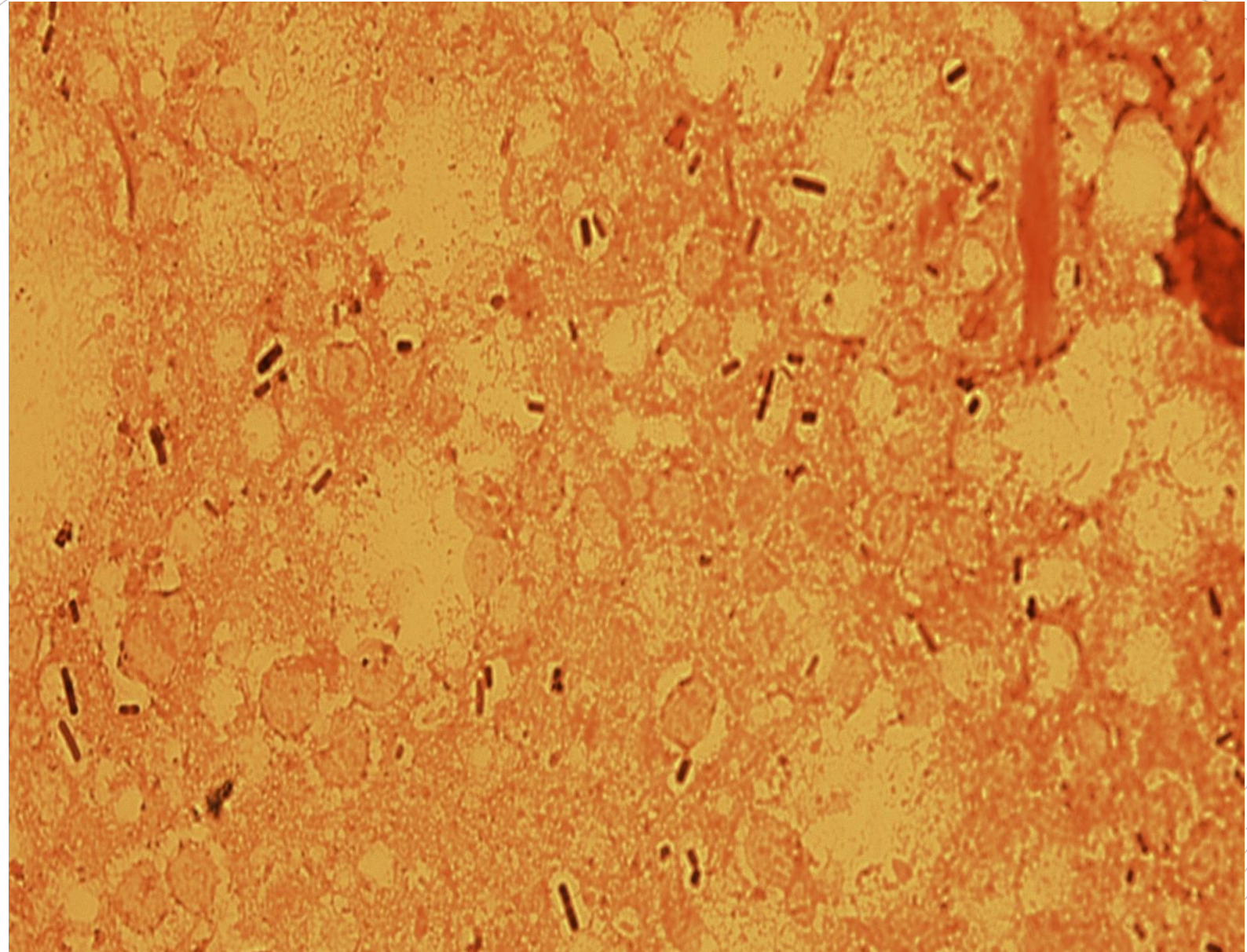
*Clostridium
perfringens,
Staphylococcus
hominis*

Specimen: tissue biopsy

Patient: female, 76 years old

Dg.: atherosclerosis of the end artery

Microscopy: gram-positive rods and cocci



Autor: MUDr. Alena Pířov



CHARLES UNIVERSITY
Second Faculty of Medicine

Slide No. 95

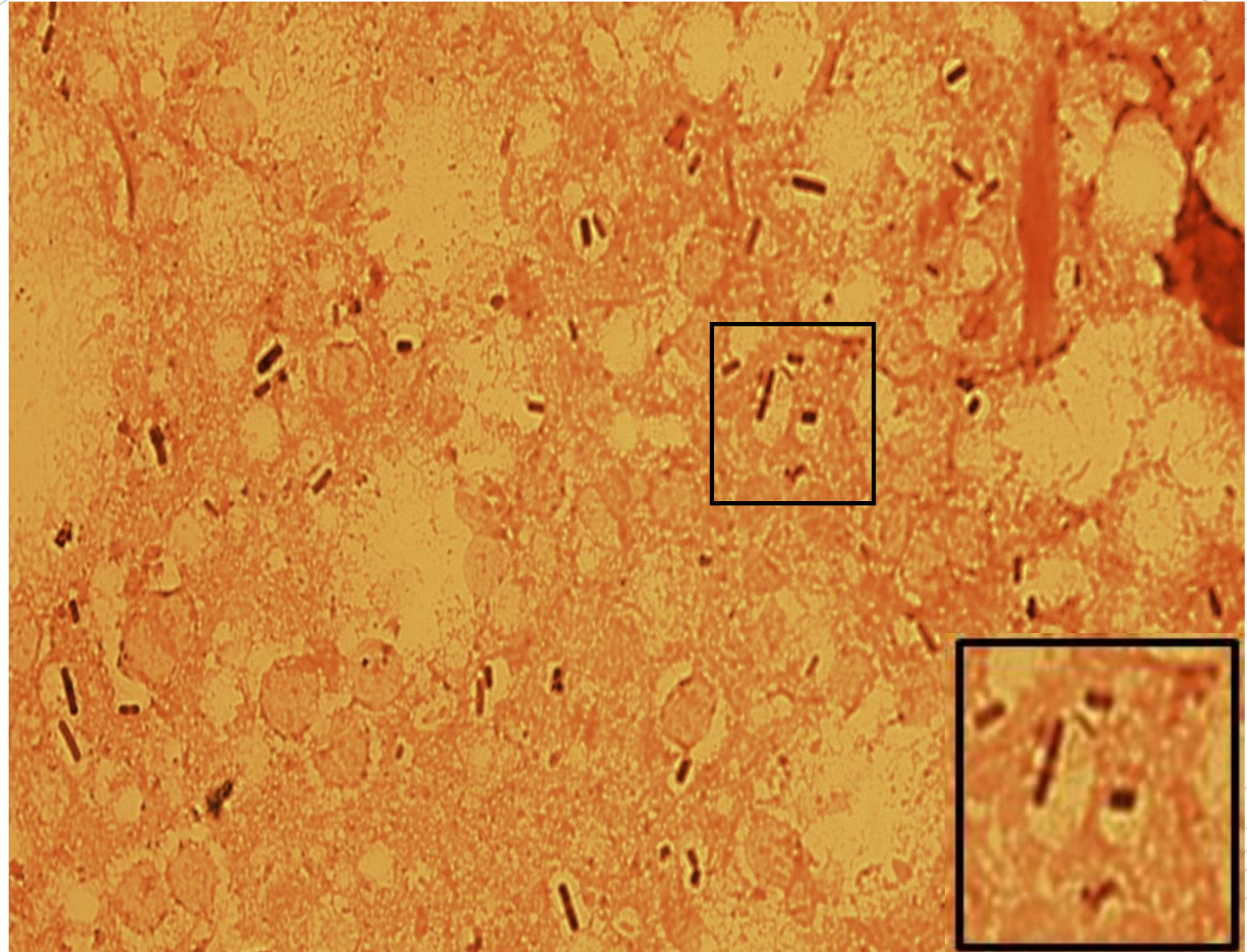
*Clostridium
perfringens,
Staphylococcus
hominis*

Specimen: tissue biopsy

Patient: female, 76 years old

Dg.: atherosclerosis of the end artery

Microscopy: gram-positive rods and cocci



Autor: MUDr. Alena Pířová



CHARLES UNIVERSITY
Second Faculty of Medicine

Slide No. 96

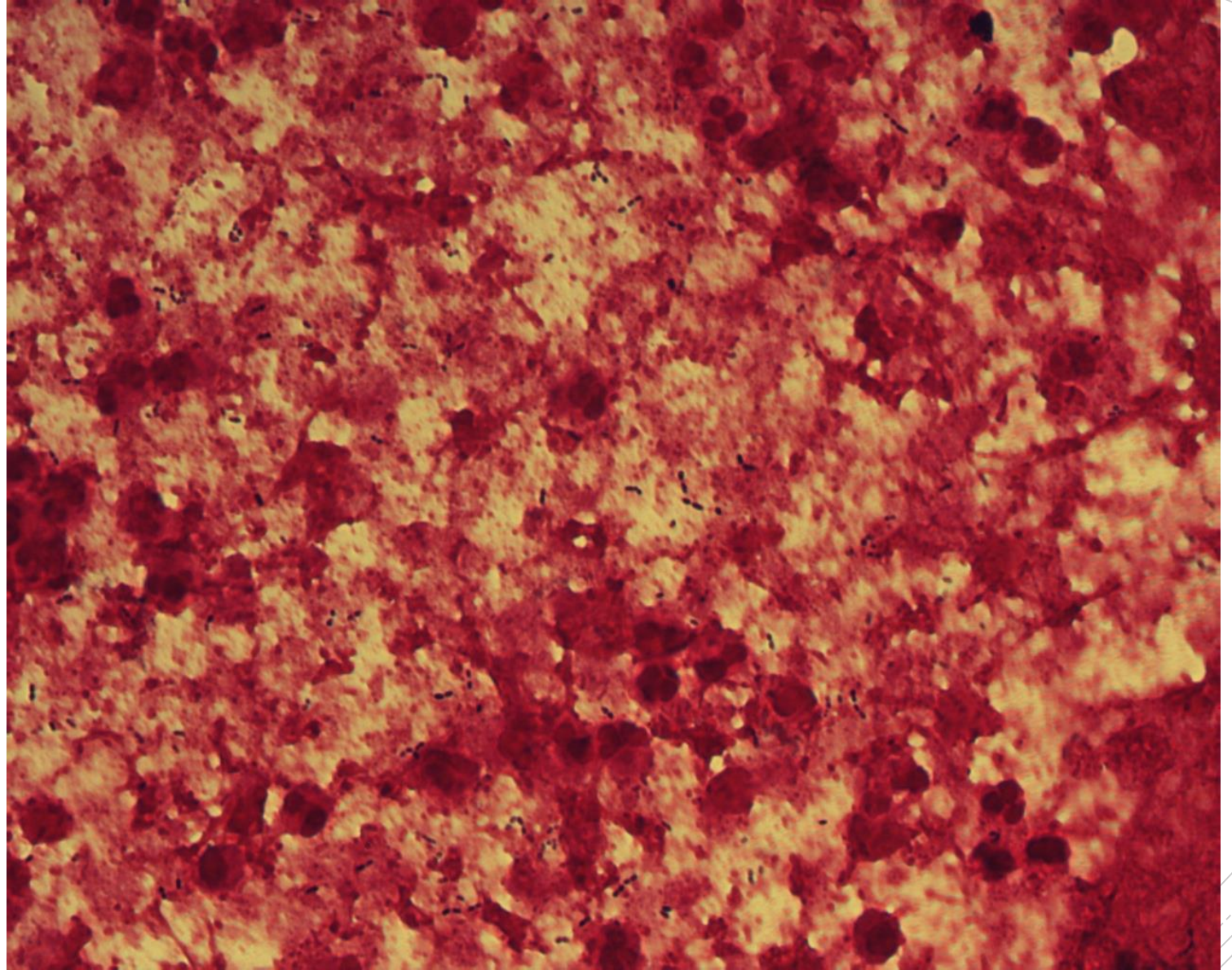
Streptococcus pneumoniae

Specimen: tissue

Patient: female, 57 years old

Dg.: meningitis

Microscopy: Gram-positive diplococci



Autor: MUDr. Alena Pířov



CHARLES UNIVERSITY
Second Faculty of Medicine

Slide No. 96


Streptococcus pneumoniae

Specimen: tissue

Patient: female, 57 years old

Dg.: meningitis

Microscopy: Gram-positive diplococci



Autor: MUDr. Alena Pířová



CHARLES UNIVERSITY
Second Faculty of Medicine

Slide No. 97

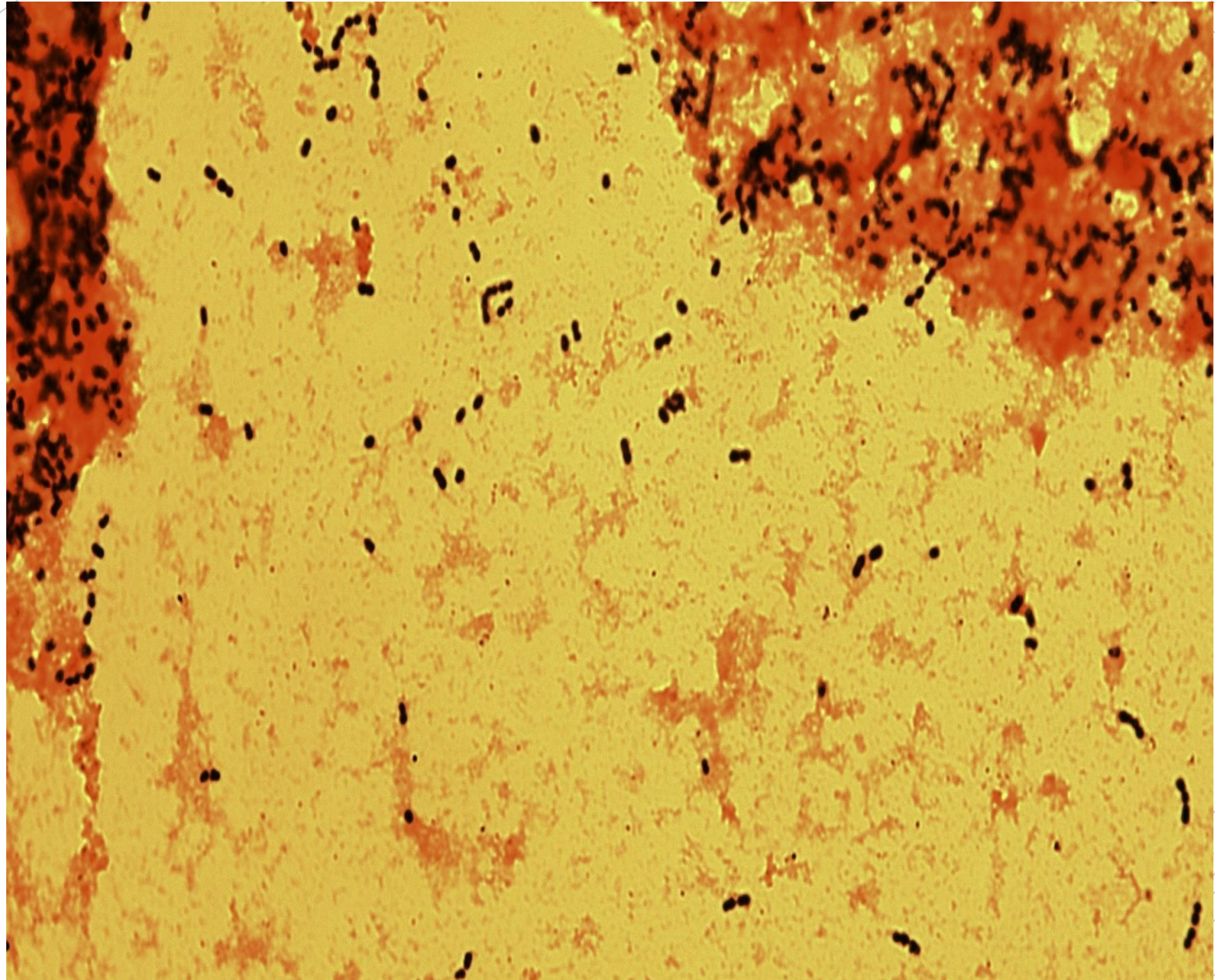
Streptococcus pneumoniae

Specimen: tissue

Patient: female, 57 years old

Dg.: meningitis

Microscopy: Gram-positive cocci and diplococci



Autor: MUDr. Alena Pířová



CHARLES UNIVERSITY
Second Faculty of Medicine

Slide No. 97


Streptococcus pneumoniae

Specimen: tissue

Patient: female, 57 years old

Dg.: meningitis

Microscopy: Gram-positive cocci and diplococci



Autor: MUDr. Alena Pířová



CHARLES UNIVERSITY
Second Faculty of Medicine

Slide No. 98


Escherichia coli

Specimen: urine

Patient: female, 80 years old

Dg.: urolithiasis

Microscopy: Gram-negative rods



Autor: MUDr. Alena Pířová



CHARLES UNIVERSITY
Second Faculty of Medicine

Slide No. 98


Escherichia coli

Specimen: urine

Patient: female, 80 years old

Dg.: urolithiasis

Microscopy: Gram-negative rods



Autor: MUDr. Alena Pířová



CHARLES UNIVERSITY
Second Faculty of Medicine

Slide No. 99

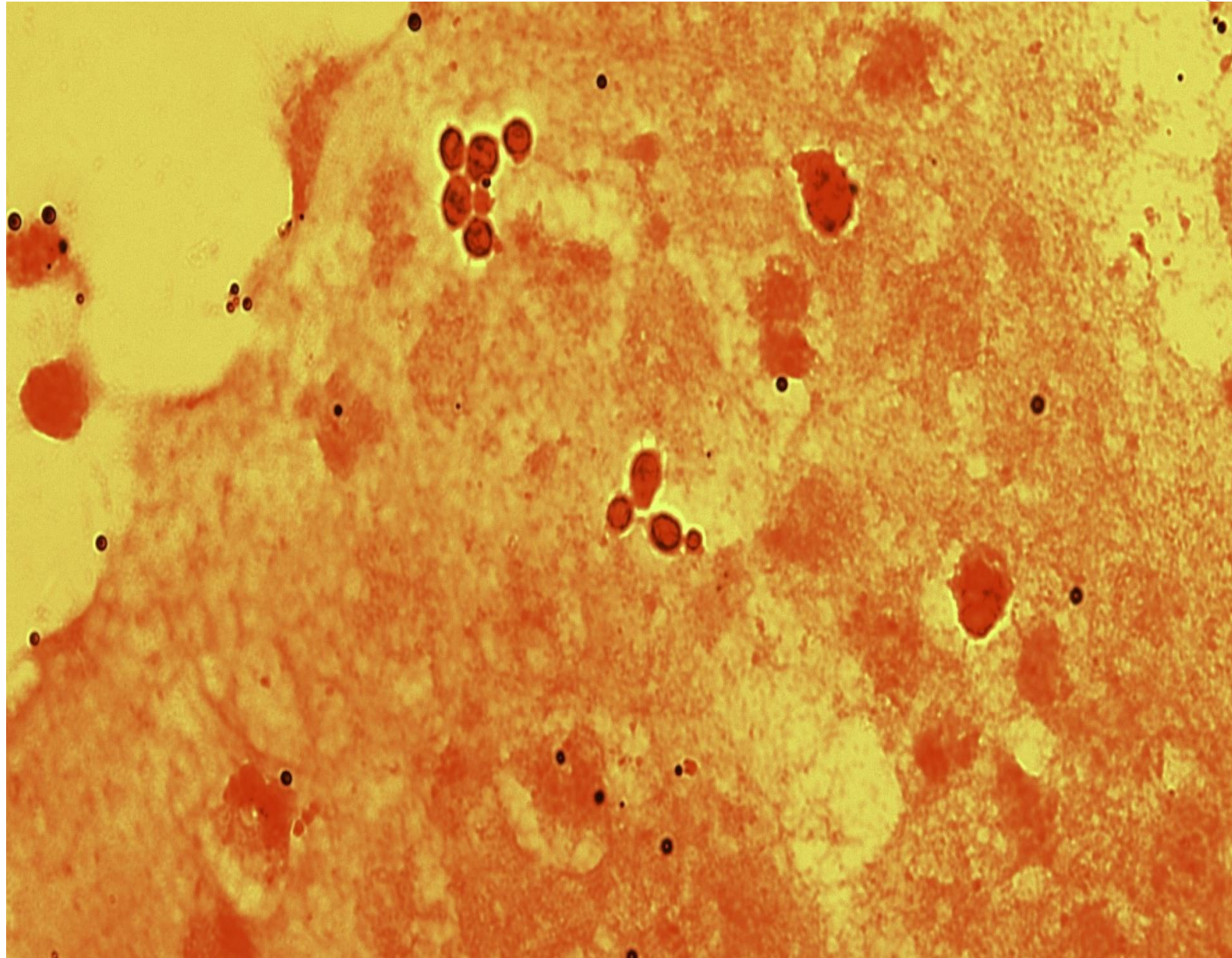
Candida albicans

Specimen: bile

Patient: female, 53 years old

Dg.: malignant tumor of the large intestines

Microscopy: blastospores



Autor: MUDr. Alena Pišová



CHARLES UNIVERSITY
Second Faculty of Medicine

Slide No. 99

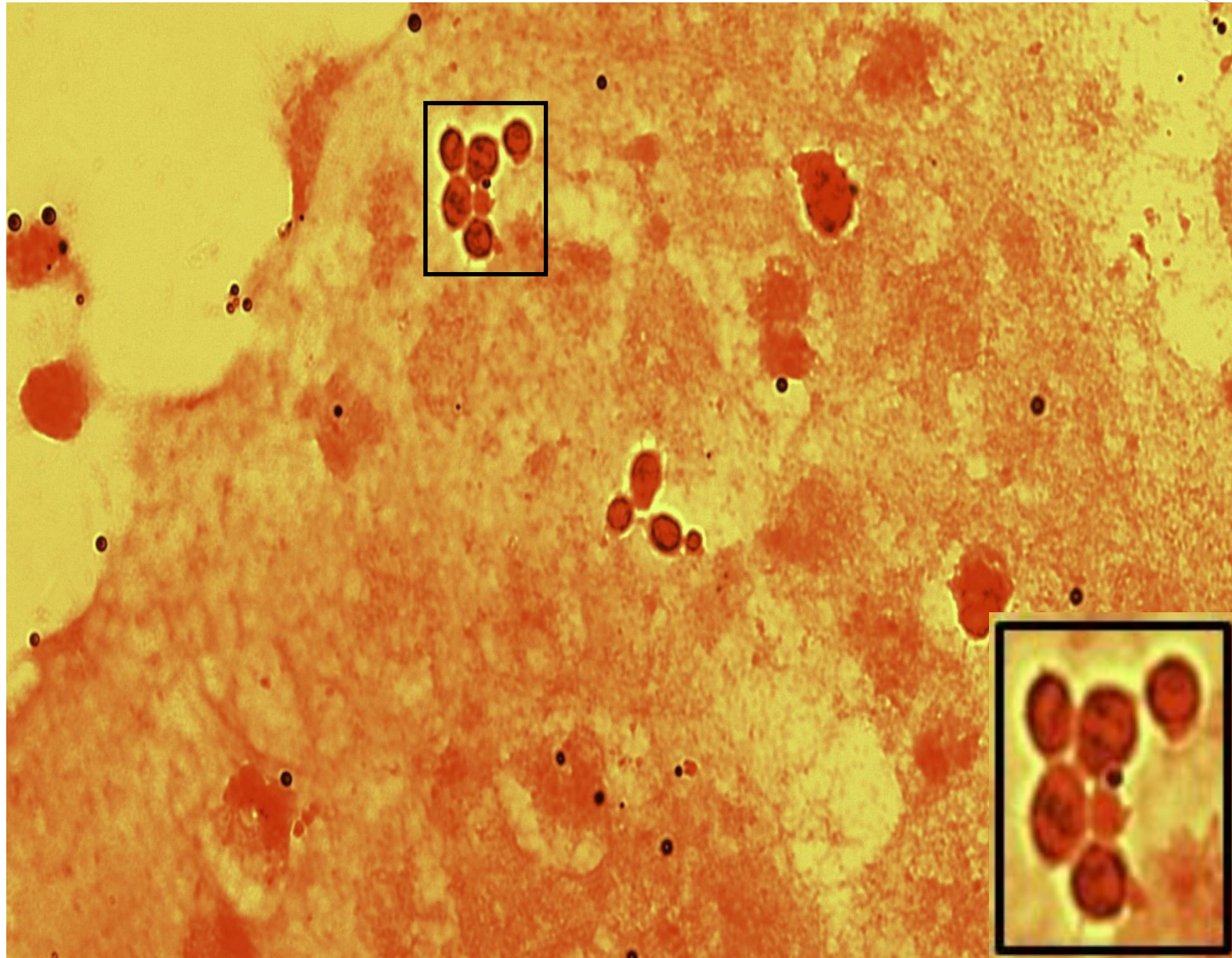
Candida albicans

Specimen: bile

Patient: female, 53 years old

Dg.: malignant tumor of the large intestines

Microscopy: blastospores



Autor: MUDr. Alena Pišová



CHARLES UNIVERSITY
Second Faculty of Medicine

Slide No. 100

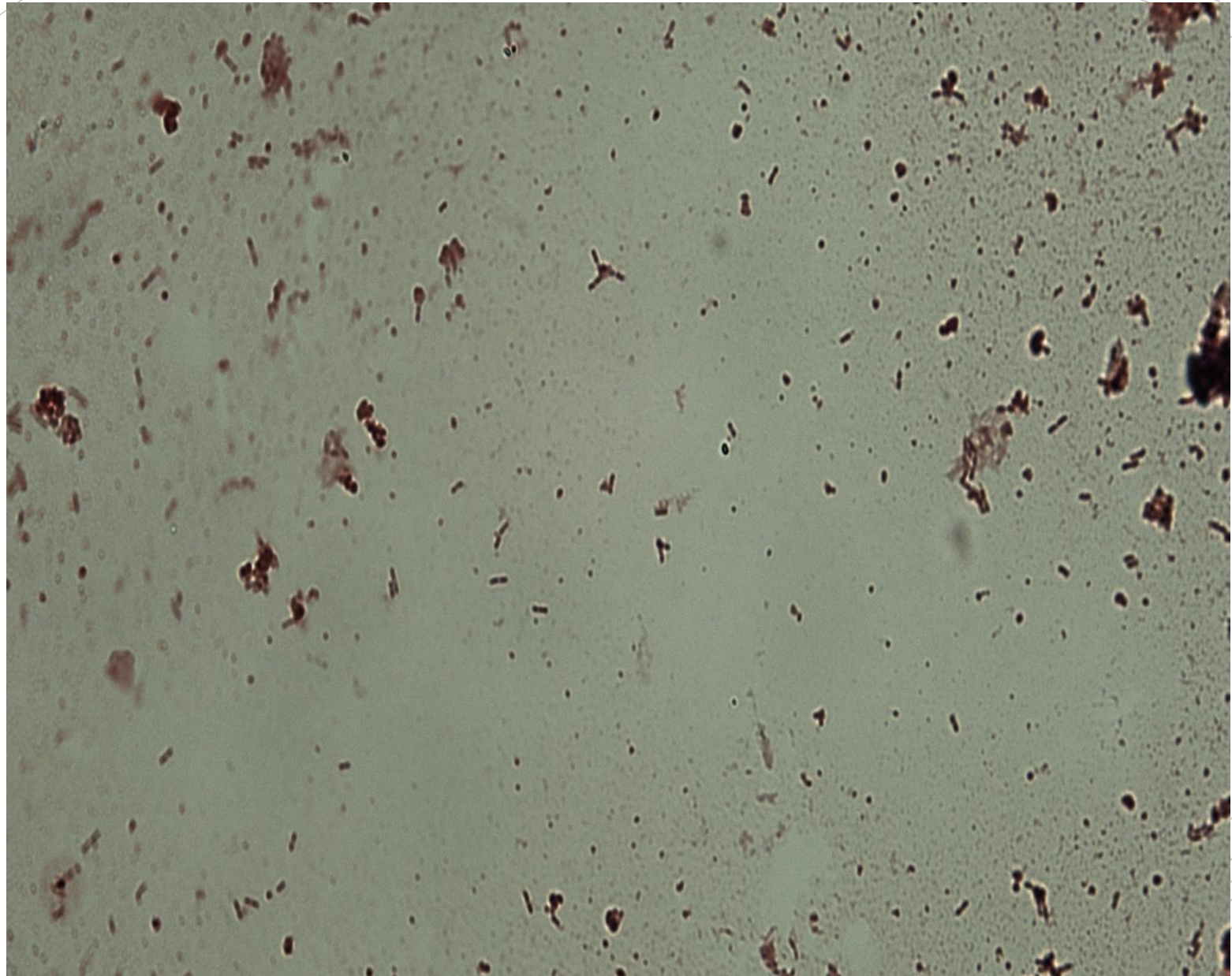
Listeria monocytogenes

Specimen: hemoculture

Patient: male, 78 years old

Dg.: sepsis

Microscopy: gram-positive rods (in the sample they are forming clusters)



Autor: MUDr. Alena Pišová



CHARLES UNIVERSITY
Second Faculty of Medicine

Slide No. 100


Listeria monocytogenes

Specimen: hemoculture

Patient: male, 78 years old

Dg.: sepsis

Microscopy: gram-positive rods (in the sample they are forming clusters)



Autor: MUDr. Alena Pišová