

Etiology of skin and soft tissue infections

MUDr. Eliška Bébrová

Superficial and localized skin infections

S.aureus pyoderma impetigo, folliculitis
abscess furuncul, karbuncul

S.aureus, beta-hem.str. celulitis

skin and subcutaneous tissue

S.pyogenes erysipel

skin and subcutaneous tissue and lymphatic vessels

P.aeruginosa ecthyma

skin and subcutaneous tissue

Rizikové specifické faktory

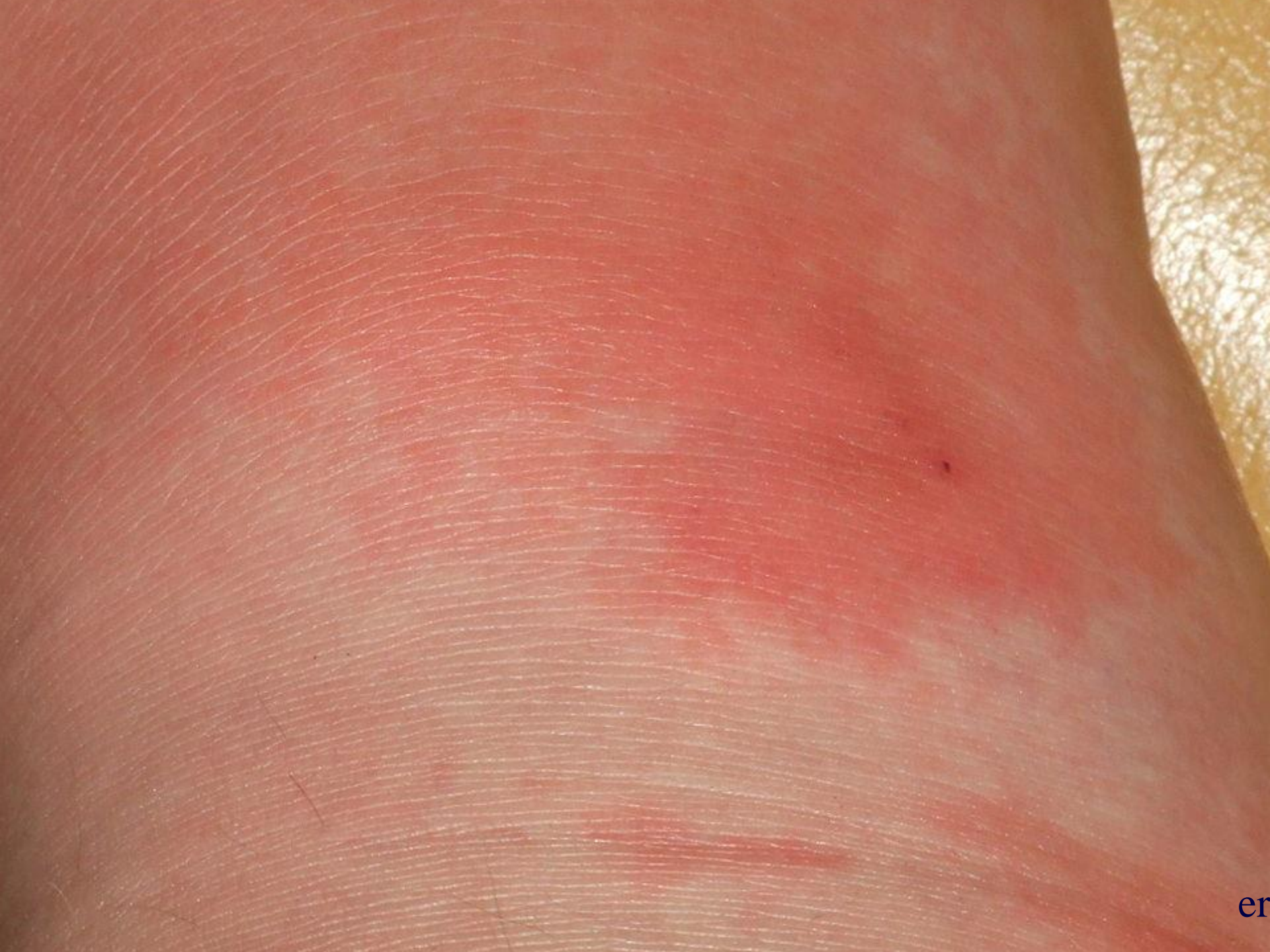kousnutí psem, kočkou *Pasteurella multocida*

poranění v mořské vodě *Vibrio vulnificans*

kočičí škrábnutí *Bartonella henselae*

popáleniny *S.aureus, P.aeruginosa*

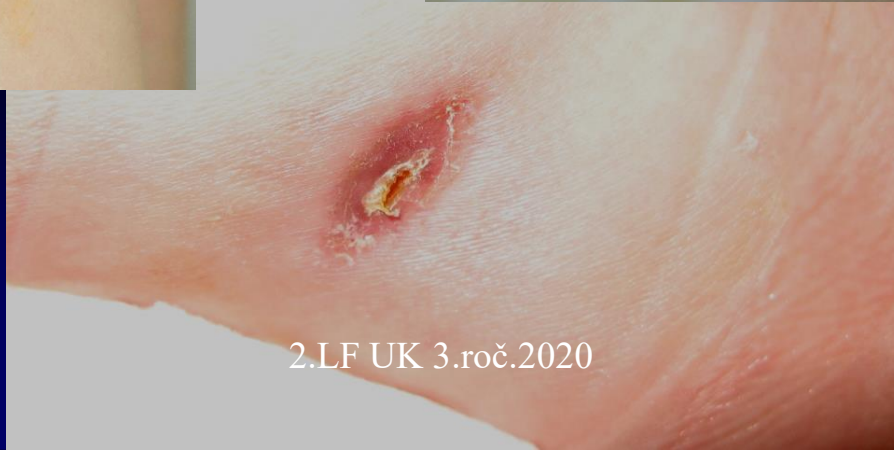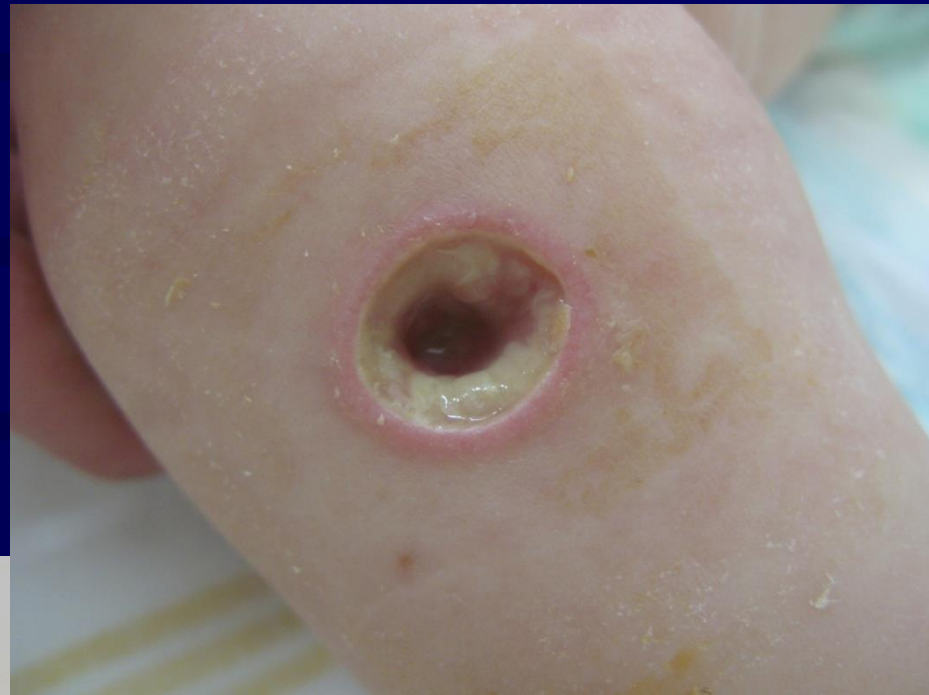
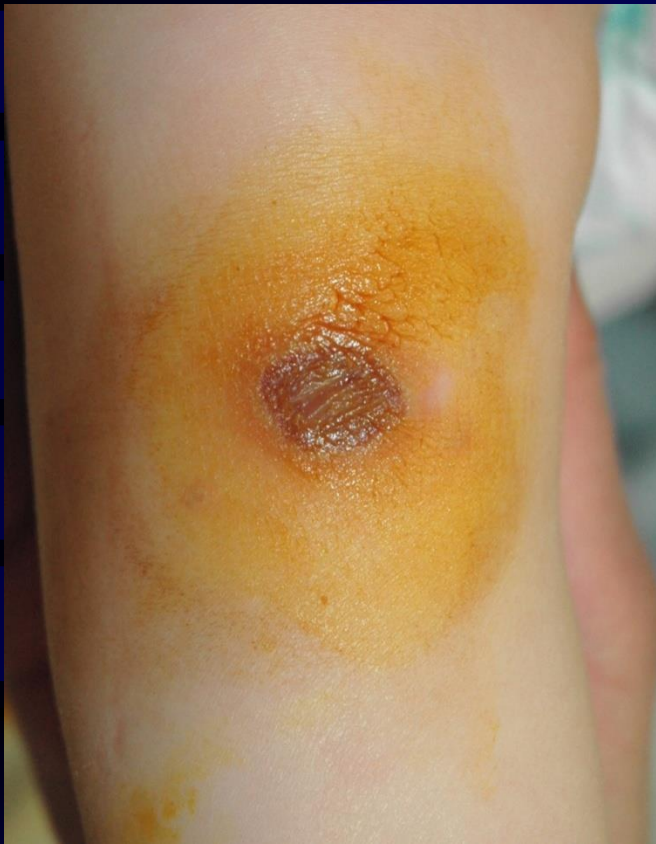Samples - swabs (in transport media) and liquid samples



er

Ecthyma gangrenosum

(before and after treatment, localization – anterior knee)



S. pyogenes

macro or microtrauma

bakteroides, fusobacterie

orofaryngeal inf.,

(tonzilofaryngitis , paratonzilar abscess),

stomatology

deep abdominal infections

myonecrosis (gas gangrene)

histotoxic clostridia

devastating injury, ischemi

C. perfringens

surgical procedures

aspirates, tissue samples

culture, urgent microscopy (staining - Gram, Schaeffer –
Fulton/spore staining)

Antibiotics to treat soft tissue infections caused by *Streptococcus pyogenes*

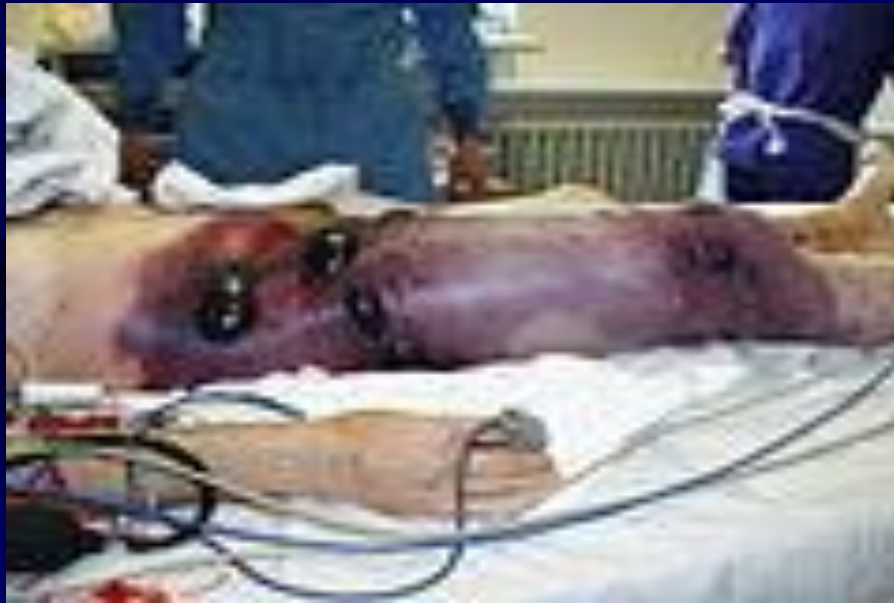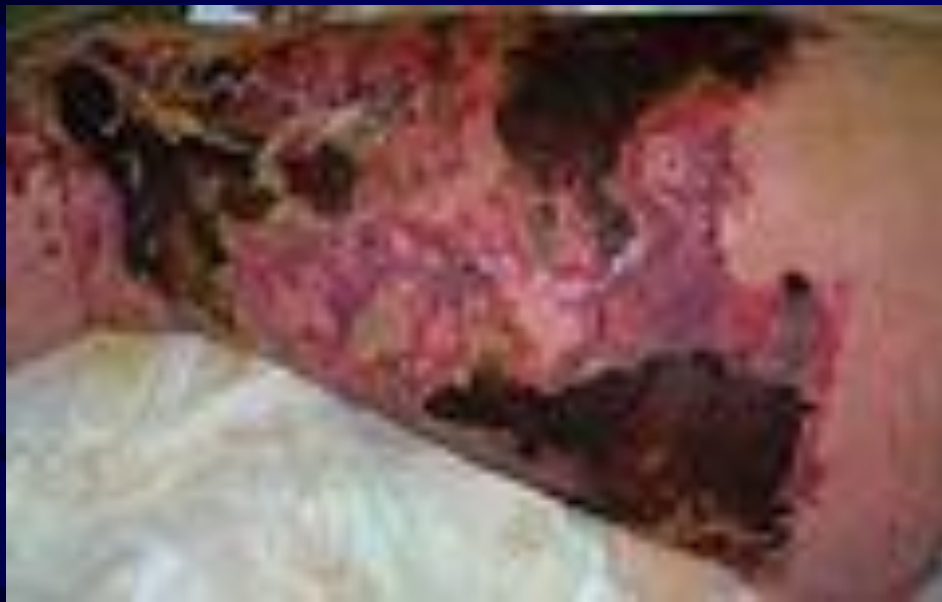Necrotizing fasciitis

always i.v. combination penicilin G and
clindamycin !!!!!

Skin and underlying tissue

celulitis,erysipel

penicilin i.v. or p.o.



Antibiotics to treat anaerobic infections

PNC G (clostridia, fusobacteria, peptostreptococci, aktinomyctes)

aminopenicilin / inhibitor (abdominal infections, aspiration pneumonia, B. fragilis)

clindamycin (abdominal infections, soft tissue inf., lung abscess, odontogenic inf., para a retrofaryngeal abscess, chronic sinusitis)

metronidazol (abdominal infections, CNS)

ureidopenicilin / inhibitor, karbapenemy
(nosocomiální inf.)

- If suspicion for aerobic and anaerobic infections the applied antibiotics must cover all of them!!

Osteomyelitis - classification

- * hematogenous

- * exogenic

 - per continuitatem

 - direct inoculation – posttraumatic and/or iatrogenic – related to surgical procedures

Etiology – hematogenous osteomyelitis

long bones, more frequent in childhood age

newbornes and children < 1 year *S. agalactiae*, *S. aureus*, *E. coli*
very often leads to septic arthritis

children 1-16 let
skin inf., respiratory and GIT inf.

S. aureus, *S. pyogenes*, *HI typ b*,
enterobacteria (salmonelae)

rarely adults

S. aureus, enterobakterie,
 β – hemolytic streptococci
sk.B,C,G

spondylodiscitidy, most often in adults

skin and soft tissue inf.,
endocarditis

S. aureus, β - hem.strept. sk.
B, C, G, *S. aureus*

UTI, GIT,
surgical wounds

enterobakterie (vč. salmonel)
pseudomonády, anaerobní bb.

CAVE

M.tuberculosis

risk patients – reumatoid arthritis, diabetes, chronic renal
insufficienci, malignity, malnutrition, drug and alcohol abusos,
cirrhosis.

Laboratory diagnosis

blood cultures, sensitivity 30–60%
intraosseal or periosteal aspirates

peroperative samples

microscopy

culture

aerobic and anaerobic culture

blood agar, chocolate agar, Schaedler agar

PCR diagnostic

Exogenous osteomyelitis

per continuitatem, from neighboring tissue

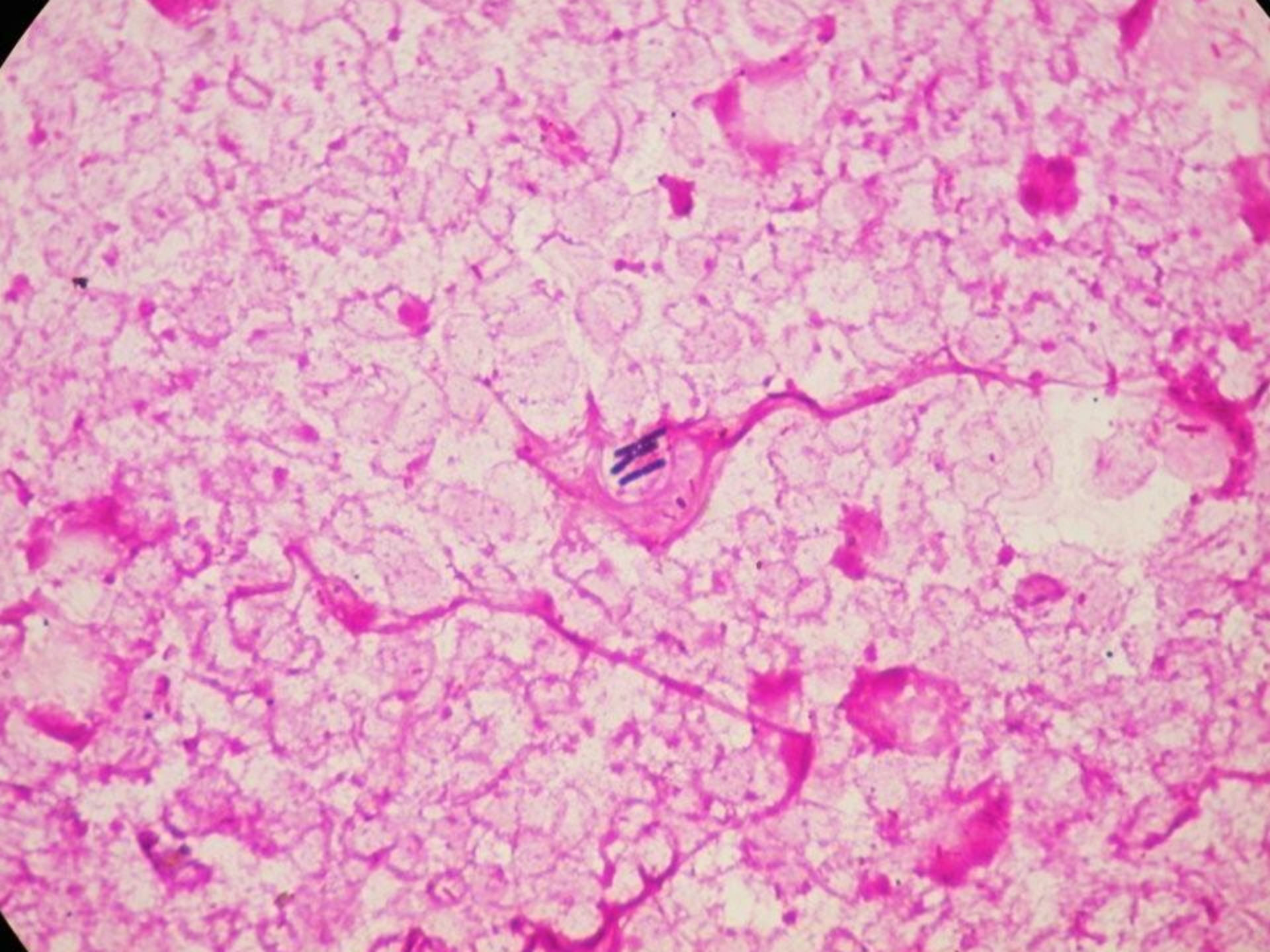
long bones, vertebra, facial bones
usually polymicrobial

wound infections
chronic ulcerations,
pressure ulcers, stomatologic lesions

bone trauma

S. aureus, streptococci,
enterobacteria, bacillary,
pasteurella, anaerobes

S. aureus, enterobacteria,
bacillary, anaerobes
including clostridia



Infectious surgical complication

* the risk of infectious complications increases in the presence of foreign materials

etiology

S. aureus vč. MRSA, *S. epidermidis*,
Pseudomonas aeruginosa

Laboratory diagnosis of exogenic osteomyelitis

- * blood culture – lower sensitivity (but should be used)
- * swabs from wounds or ulcers could reflect contamination (repeated samples are suggested)
- * aspiration, biopsy or peroperative samples are suggested

Arthritis

septic arthritis of native joint

hematogenous, usually single joint is affected

novorozenci, děti < 1 rok

větší děti, 1-14 let

skin inf.,

GIT inf.

dospělí

risk factors

cirrhosis

malignancy...

etiology

S. agalactiae, *S. aureus*, *E. coli*

N.gonorrhoeae

S. aureus, *S. pyogenes*, HI typ b,

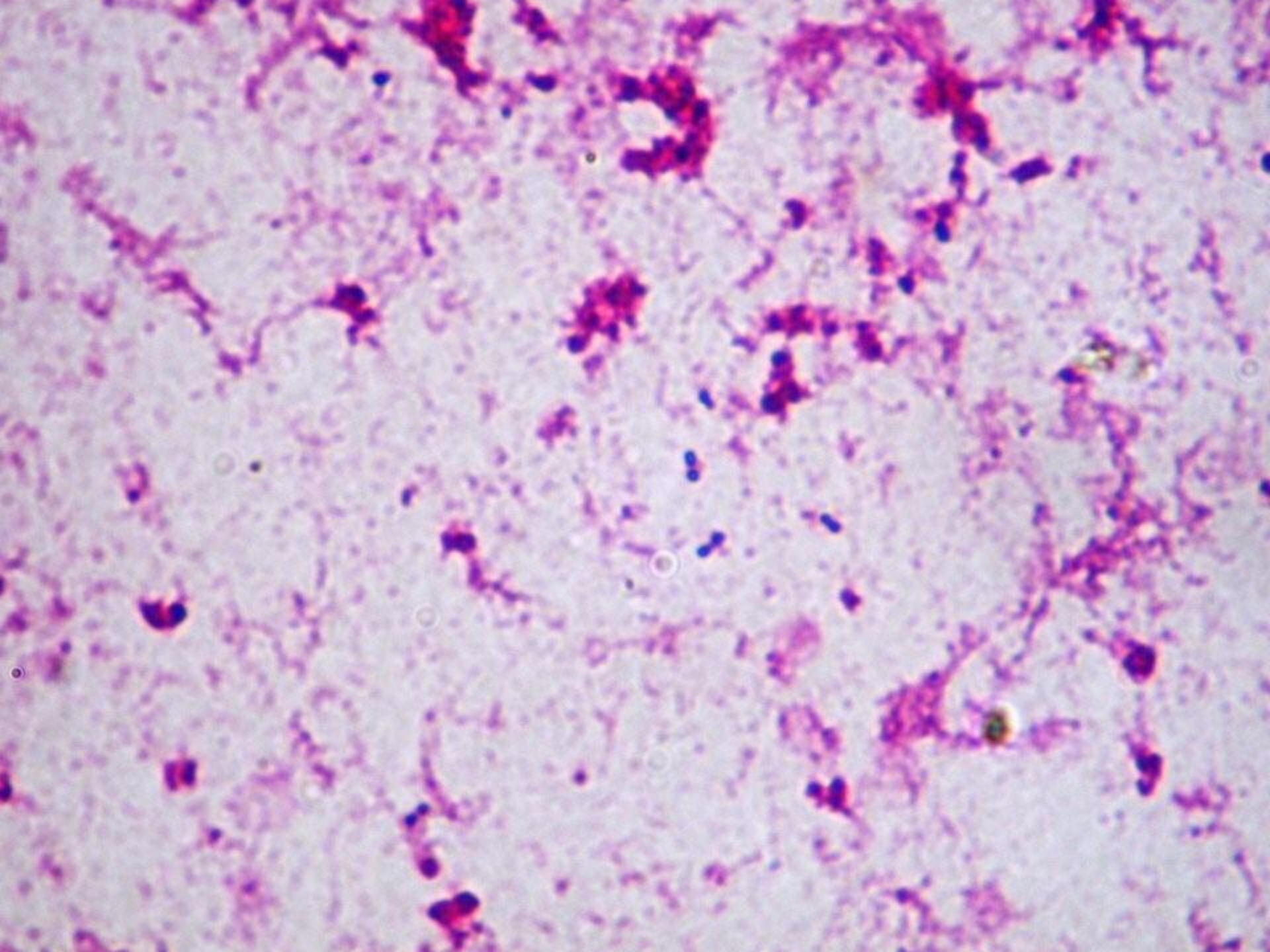
S. pneumoniae,

enterobacteria (salmonelae)

S. aureus, enterobakterie,

β - hemolytické streptokoky,

pseudomonády, *M. tuberculosis*



Laboratory diagnosis

blood cultures

aspirates

peroperative samples

microscopy

culture aerobic and anaerobic

(blood agar, Endo, chocolate and Schaedler agar

Therapy of bone and joint infections

acute

beginning – urgent and empiric

later – specific using agent antibiogram

ATB and osteomyelitis

newbornes

etiology *S.aureus*, *S. agalactiae*, enterobacteria

oxacilin, cephalosporins 3.gen.

children

etiology *S.aureus*, *S.pyogenes*, enterobacteria

oxacillin, lincosamides (clindamycine), cephalosporins 3.gen

adults

etiology *S.aureus* (cave MRSA), enterobacteria

oxacillin, lincosamides (clindamycine)

cephalosporins 3.gen.

(can be combination with fluoroquinolones)

MRSA - linezolid

ATB and septic arthritides

newbornes

etiologie *S.aureus*, *S. agalactiae*, enterobacteria,
N.gonorrhoeae

oxacillin, cephalosporins 3.gen.

children

etiologie *S.aureus*, *S.pyogenes*, *S.pneumoniae*, *H.influenzae*,
enterobacteria

oxacillin, linkosamides (clindamycine), cefalosporin 3.gen

dospělí

etiologie *S.aureus* (cave MRSA), enterobakterie

oxacilin, linkosamides (clindamycine)

cefalosporiny 3.gen.

(can be combination with fluoroquinolones)

MRSA - vankomycin or linezolid