

Bone and joint infections

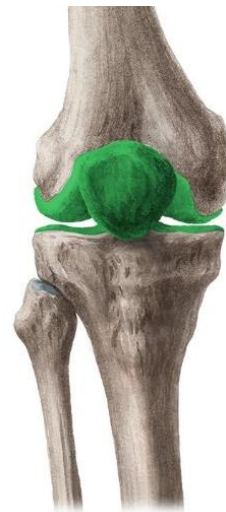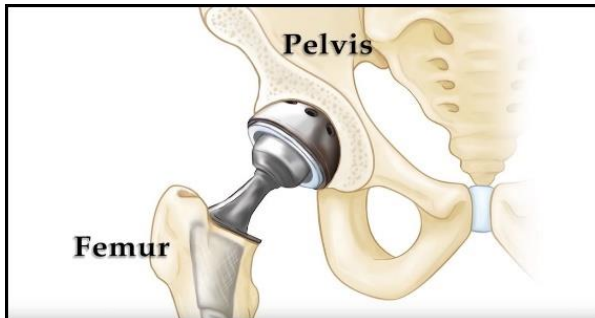
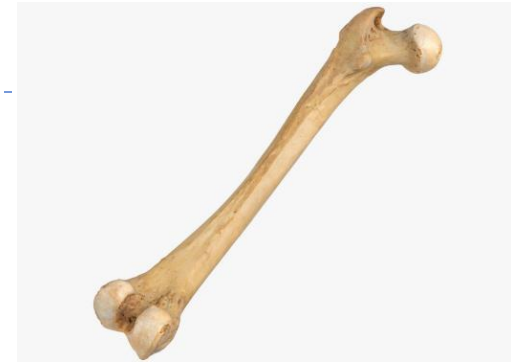Anežka Gryndlerová

Bone and joint infections

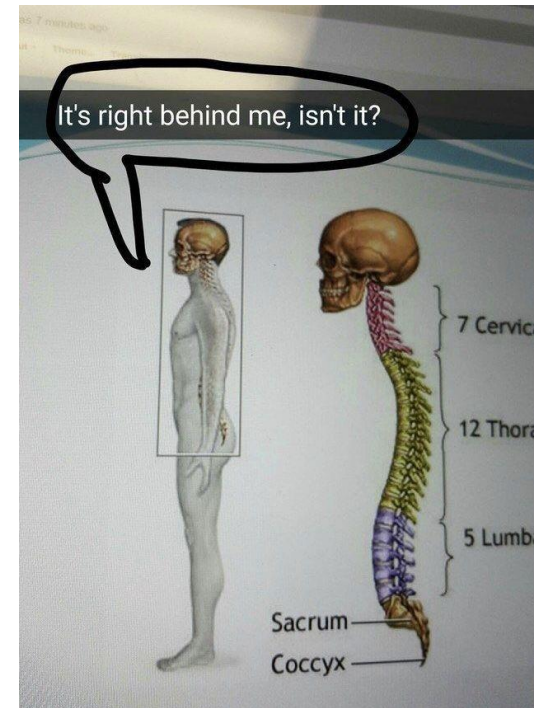
- ▶ **Poor ATB penetration into the infected tissue**
 - ▶ → Difficult to treat
 - ▶ → long term ATB treatment
 - ▶ → Combination with surgery



- ▶ Osteomyelitis
- ▶ Vertebral osteomyelitis
- ▶ Septic arthritis
- ▶ Periprosthetic joint infections



© www.kenhub.com



Tornado Studios

<https://cz.pinterest.com/pin/674484481729139216/>

<https://www.kenhub.com/en/library/anatomy/the-knee-joint>

<https://orthoinfo.aaos.org/en/treatment/total-hip-replacement/>

Osteomyelitis

- ▶ Bone and bone marrow infection
- ▶ Relatively uncommon, bones resistant to infection
 - ▶ Highly virulent pathogen, large inoculum, bone damage, foreign material

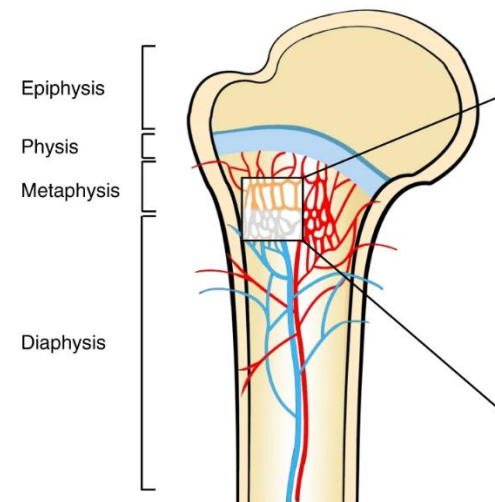
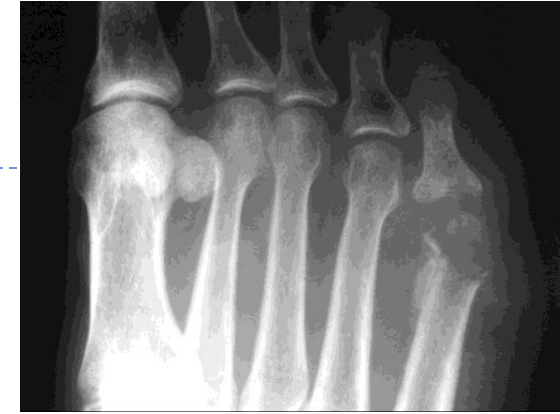▶ Etiology → Direct inoculation (trauma, surgery)

Per continuitatem

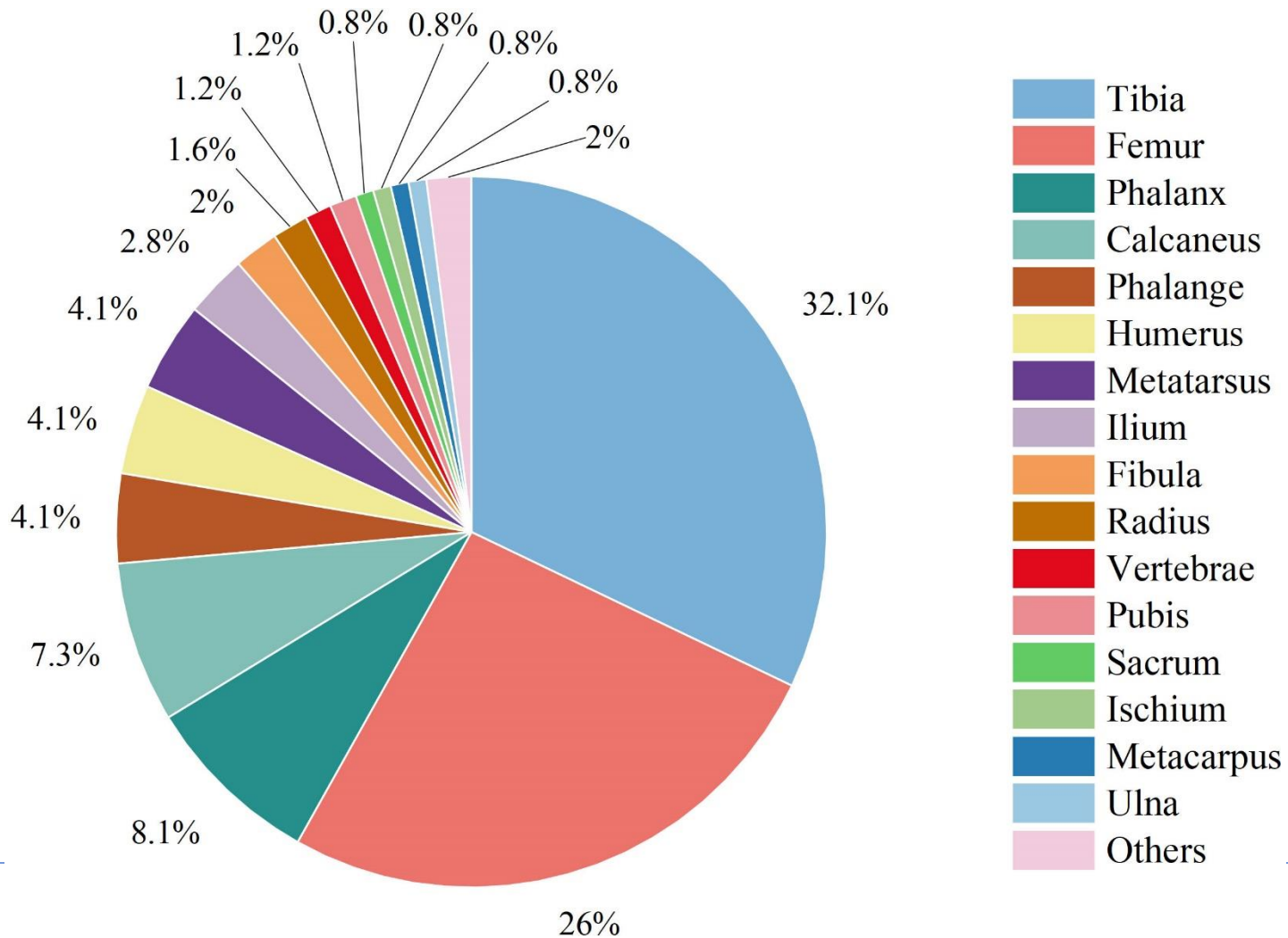
- Sacral pressure ulcer → sacral osteomyelitis
- Often polymicrobial
- Starts on periosteum
- Osteomyelitis associated with diabetic foot: colonisation → soft tissue infection → osteomyelitis (risk of amputation)

Hematogenous

- Often monomicrobial
- Starts in bone marrow
- Bacteriemia (endocarditis, catheter infection, transient bacteriemia - viridans streptococci, anaerobes, staphylococci, enterobacterales)
- Intact bone (*S. aureus*) damaged bone (trauma, cyst, ischemia, unknown)

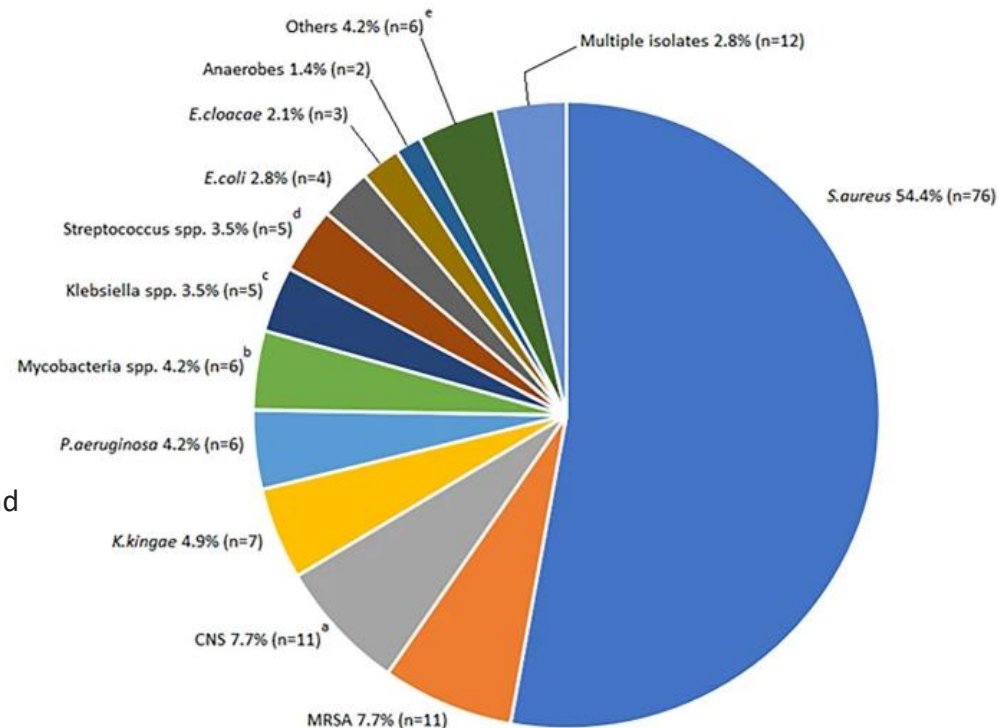


Lu S, Wang L, Luo W, Wang G, Zhu Z, Liu Y, Gao H, Fu C, Ren J, Zhang Y, Zhang Y. Analysis of the epidemiological status, microbiology, treatment methods and financial burden of **hematogenous osteomyelitis** based on 259 patients in Northwest China. *Front Endocrinol (Lausanne)*. 2023 Jan 4;13:1097147. doi: 10.3389/fendo.2022.1097147. PMID: 36686458; PMCID: PMC9846127.



Osteomyelitis – etiology

- ▶ *S. aureus*
- ▶ Coagulase-negative staphylococci (CNS)
 - ▶ Arteficial implants
- ▶ Enterobacteria (incl. *Salmonella*), *P. aeruginosa*, streptococci, enterococci, anaerobic bacteria
- ▶ Pediatrics: + *Kingella kingae* (6-36m.), GBS (neonates, infants), *Haemophilus influenzae*
- ▶ TBC



Krzysztofciak, A., Roversi, M., Musolino, A. *et al.* Clinical report and predictors of sequelae of 319 cases of **pediatric bacterial osteomyelitis**. *Sci Rep* 12, 14846 (2022).

<https://doi.org/10.1038/s41598-022-19208-2>

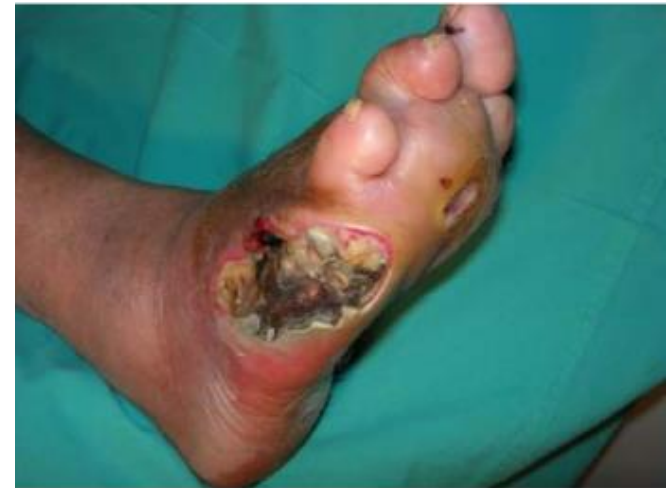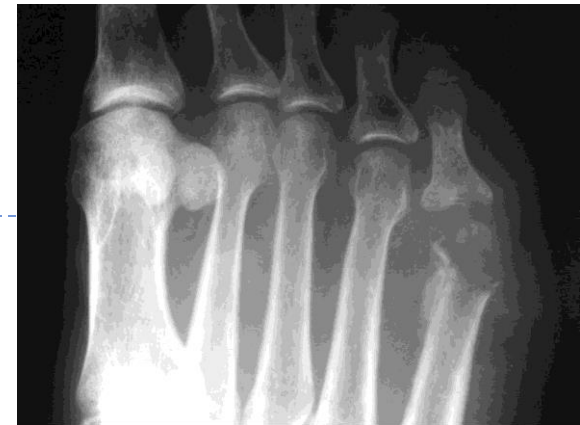Osteomyelitis

▶ Clinical presentation

- ▶ Long bones mostly (femur, tibia, phalanx)
- ▶ Pain, chills, tenderness, fever → swelling, redness
- ▶ Can lead to sepsis

▶ Microbiological diagnosis

- ▶ Samples?



Osteomyelitis

▶ Clinical presentation

- ▶ Long bones mostly (femur, tibia, phalanx)
- ▶ Pain, chills, tenderness, fever → swelling, redness
- ▶ Can lead to sepsis

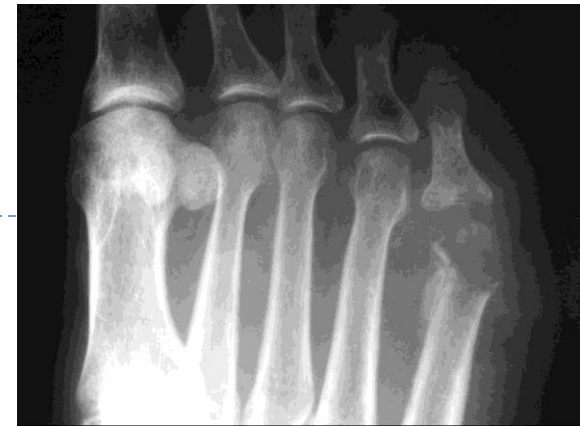▶ Microbiological diagnosis

▶ Samples?

- ▶ Blood culture
- ▶ Tissue/(swab) (especially during surgery!)



Methods?



Osteomyelitis

▶ Clinical presentation

- ▶ Long bones mostly (femur, tibia, phalanx)
- ▶ Pain, chills, tenderness, fever → swelling, redness
- ▶ Can lead to sepsis

▶ Microbiological diagnosis

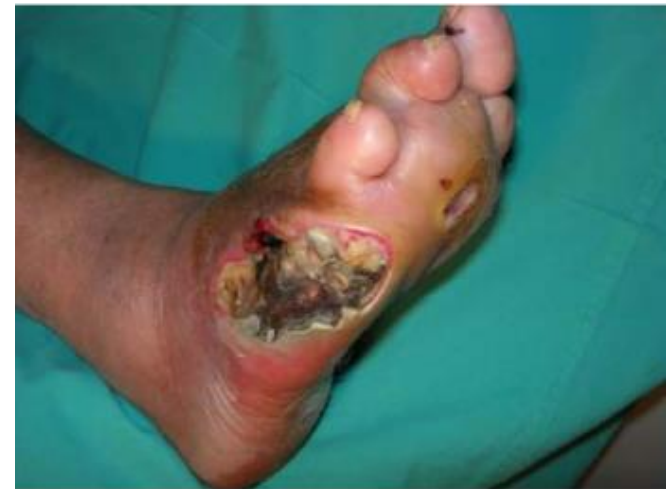▶ Samples?

- ▶ Blood culture
- ▶ Tissue/(swab) (especially during surgery!)



Methods?

- Microscopy (tissue/pus)
- Culture
- PCR



Osteomyelitis – diagnosis by bone biopsy

- ▶ Histology
- ▶ Microbiology

IWGDF/IDSA guidelines on the diagnosis and treatment of diabetes-related foot infections (IWGDF/IDSA 2023)

Éric Senneville ✉, Zaina Albalawi, Suzanne A. van Asten, Zulfiqarali G. Abbas, Geneve Allison, Javier Aragón-Sánchez, John M. Embil, Lawrence A. Lavery, Majdi Alhasan, Orhan Oz, Ilker Uçkay, Vilma Urbančič-Rovan, Zhang-Rong Xu, Edgar J. G. Peters ... [See fewer authors](#) ^

Recommendation 10

In a person for whom there is suspicion of osteomyelitis of the foot (before or after treatment), consider obtaining bone (rather than soft tissue) samples for culture, either intraoperatively or percutaneously. (Conditional; Moderate).

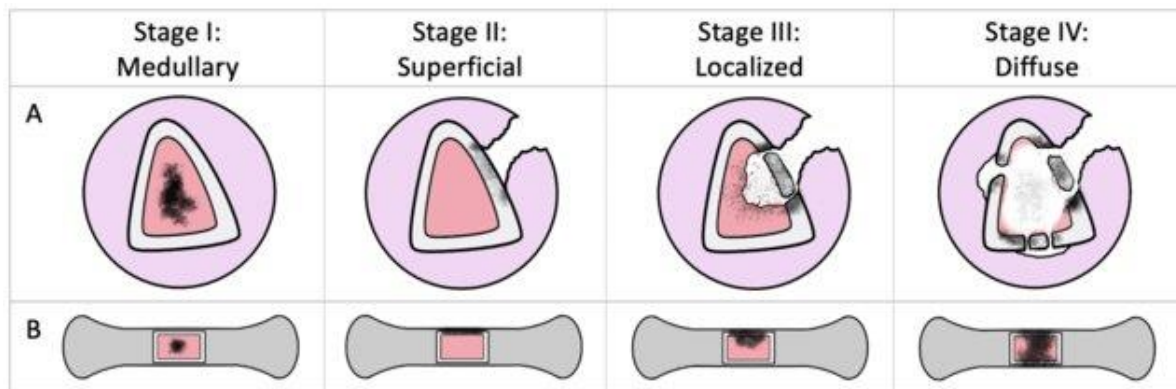
Rationale

Obtaining a bone specimen to diagnose osteomyelitis is the generally accepted criterion standard for diagnosing the infection, and the only definitive way to determine the causative pathogen(s). Bone Biopsy is, however, usually not performed in most cases of suspected DFO due to the absence of a health care professional adequately trained to perform the procedure and/or the fear of possible adverse effects, especially fracture or induced infection of the bone.¹¹⁴ Published studies consistently report a low correlation between

Cierny-Mader classification

▶ Anatomical

- ▶ 1 – monobacterial, hematogenous, arteficial material in medullary cavity
- ▶ 2 – cortical bone, per continuitatem
- ▶ 3 – cortical bone + medullary cavity, not full diameter affected
- ▶ 4 – cortical bone + medullary cavity, full diameter affected – impairment of stability



▶ Physiological class (physiological condition of the patient)

- ▶ DM, immune disease, malnutrition, renal or hepatic failure, extremes of age, malignancy ...

▶ → Treatment strategy

Osteomyelitis – therapy

- ▶ Surgery – débridement (removal of necrotic and infected tissue), foreign material removal
- ▶ ATB
 - ▶ Long term
 - ▶ Targeted, if possible (start after microbiology result)
 - ▶ Septic osteomyelitis – empirical treatment
 - ▶ Always cover *S. aureus*!
 - ▶ Probably *S. aureus*: oxacilin + aminoglycoside
 - ▶ Possible polymicrobial etiology – broad spectrum ATB (e.g. cefepime + aminoglycoside, cefepime + vancomycin)



Osteomyelitis – targeted therapy

► Is's complicated....

Suggested antimicrobial regimens for the most commonly isolated pathogens causing osteoarticular infections in infants and children when results of culture and susceptibility testing are known

Pathogen	Parenteral agents	Oral agents
<i>Staphylococcus aureus</i>		
Methicillin-susceptible	Cefazolin Nafcillin Oxacillin	Cephalexin Cloxacillin (not available in the United States) Dicloxacillin Clindamycin*
Methicillin-resistant		
Clindamycin-susceptible	Vancomycin Clindamycin	Clindamycin
Clindamycin-resistant [¶]	Vancomycin Linezolid Daptomycin ^Δ	Linezolid



Osteomyelitis – targeted therapy (simplified)

▶ Beta-lactam ATBs, vancomycin

- ▶ Staphylococci – oxacilin, vancomycin (MRSA, some CNS)
- ▶ Enterococci – ampicilin, vancomycin (*E. faecium*)
- ▶ Streptococci – penicilin G
- ▶ Enterobacterales – III./IV. gen. cephalosporins
- ▶ *P. aeruginosa* – antipseudomonal beta-lactams (examples?)
- ▶ Possible to add aminoglycosides (acute phase)

▶ Other antibiotics

▶ Clindamycin

- ▶ + very good bone penetration
- ▶ - CDI, bacteriostatic, only covers G+ and anaerobes

▶ Linezolid

- ▶ + good bone concentrations
- ▶ - llimited use (28d, toxicity), bacteriostatic, only G+ bacteria

▶ Rifampin (in combination)

- ▶ + good biofilm concentration
- ▶ - drug interactions, mostly G+ and TBC

▶ Ciprofloxacin

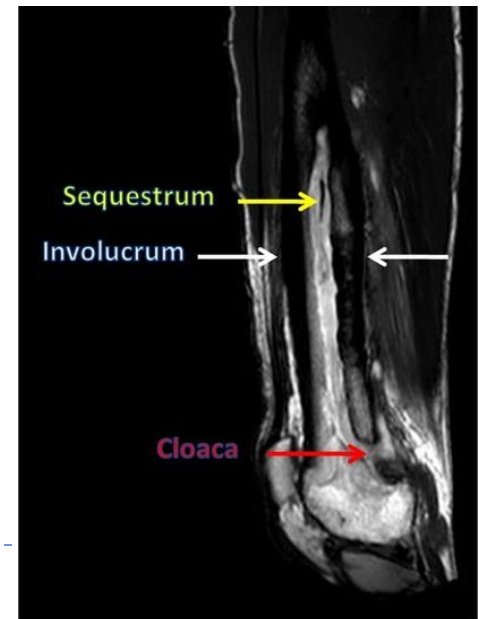- ▶ + good bone concentrations
- ▶ - resistance development during therapy and treatment failure, mostly for G-

▶ Length: individual (4-6 w. or more)



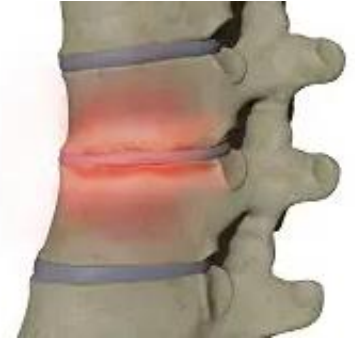Chronic osteomyelitis

- ▶ Injury/spread per continuitatem (DM), less frequently after acute OM
- ▶ >4 w.
- ▶ Bone necrosis, sequestrum (avascular), involucrum, fibrosis, cloaca (in bone cortex), fistula → (temporary) purulent discharge
- ▶ Usually no systemic symptoms, local symptoms – pain, discharge
- ▶ Relapses
- ▶ Surgery (necrotic tissue) + ATBs + risk factors elimination



Vertebral osteomyelitis (spondylodiscitis)

- ▶ Intervertebral disc + vertebrae
- ▶ Lumbar spine
- ▶ Adults
- ▶ Pathogenesis
 - ▶ Mostly hematogenous
 - ▶ Infective endocarditis, catheter-related infections, skin and soft tissue infections
 - ▶ i.v. drugs abusers
 - ▶ Direct inoculation (surgery)
- ▶ Etiology
 - ▶ *S. aureus*
 - ▶ CNS, Enterobacteriales, *P. aeruginosa*, TBC, *Candida* spp.



Vertebral osteomyelitis (spondylodiscitis)

▶ Clinical presentation

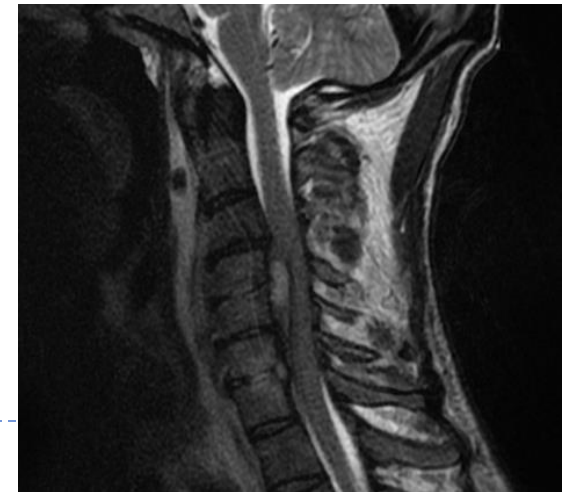
Slowly progressing back pain,
fever may not appear

Acute back pain,
fever chills, sweating

- ▶ Back pain: worsening with movement, percussion
- ▶ Neurological symptoms can occur – motor and sensory impairment (epidural abscess)

▶ Complications

- ▶ Epidural abscess/empyema, psoas abscess



Vertebral osteomyelitis (spondylodiscitis)

▶ Diagnosis

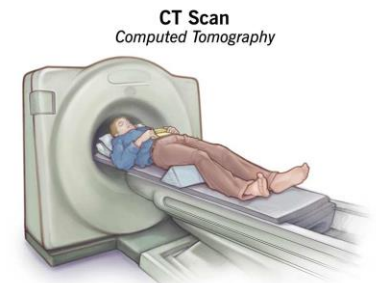
- ▶ MRI (details in radiology)
- ▶ Blood culture, samples from infection site (microscopy, culture, ev. PCR)

IDSA 2015 Clinical Practice Guidelines for the Diagnosis and Treatment of Native Vertebral Osteomyelitis in Adults

Published CID, 7/29/2015

III. When Should an Image-Guided Aspiration Biopsy or Additional Workup Be Performed in Patients With NVO?

14. We recommend an image-guided aspiration biopsy in patients with suspected NVO (based on clinical, laboratory, and imaging studies) when a microbiologic diagnosis for a known associated organism (*S. aureus*, *Staphylococcus lugdunensis*, and *Brucella* species) has not been established by blood cultures or serologic tests (*strong, low*).
15. We advise against performing an image-guided aspiration biopsy in patients with *S. aureus*, *S. lugdunensis*, or *Brucella* species bloodstream infection suspected of having NVO based on clinical, laboratory, and imaging studies (*strong, low*).



Vertebral osteomyelitis (spondylodiscitis)

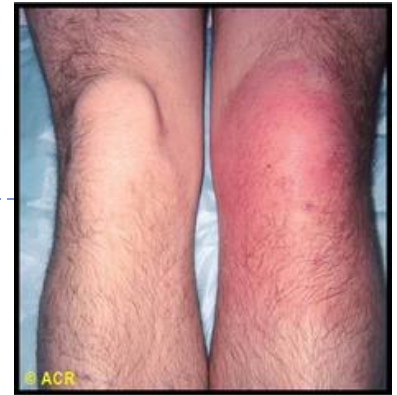▶ Therapy

- ▶ Targeted if not complicated
- ▶ Sepsis, complications
 - ▶ Probably *S. aureus*: oxacilin + aminoglycoside
 - ▶ Possible G- etiology – e.g. cefepime + aminoglycoside
- ▶ Surgery possible, ATBs 6w.



Septic arthritis (infectious arthritis)

- ▶ Purulent infection of a joint
- ▶ Usually monoarticular (knee, hip)
- ▶ Risk factors:
 - ▶ Joint pathology: rheumatoid arthritis, gout, trauma, orthopedic surgery in history
 - ▶ Immune suppression (DM, malignancy, older age, ...)
 - ▶ i.v. drug abusers, infective endocarditis
 - ▶ Foreign body presence
- ▶ Etiology
 - ▶ Hematogenous (synovial vascularisation), per continuitatem, direct inoculation
 - ▶ *S. aureus*, streptococci, Enterobacteriales, *P. aeruginosa*, *H. influenzae*, *Kingella kingae*, *Neisseria gonorrhoeae*



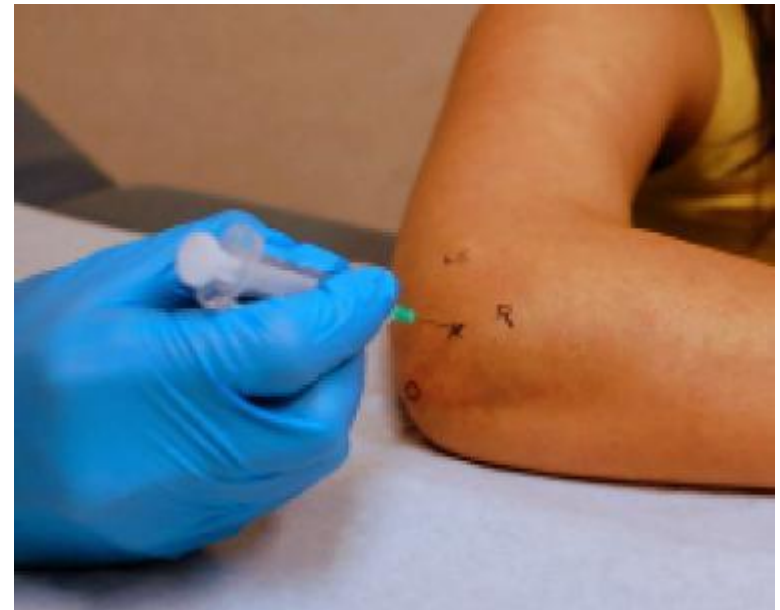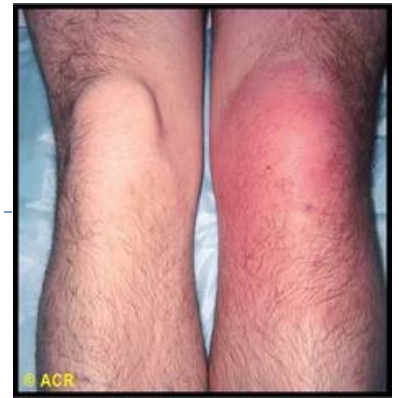Septic arthritis

- ▶ **Clinical presentation**

- ▶ Swelling, pain, redness, impaired function, fever

- ▶ **Microbiological sampling**

- ▶ Synovial fluid, blood culture
- ▶ Microscopy, culture, PCR



Septic arthritis – ATB treatment

▶ Microscopy

- ▶ G+ cocci in clusters
 - ▶ Oxacilin
 - ▶ MRSA suspicion – vancomycin, (linezolid)
- ▶ G- diplococci
 - ▶ 3rd gen. cephalosporins
- ▶ G- rods
 - ▶ Cefepime, piperacillin/tazobactam
- ▶ Negative
 - ▶ e.g. cefepime + vancomycin

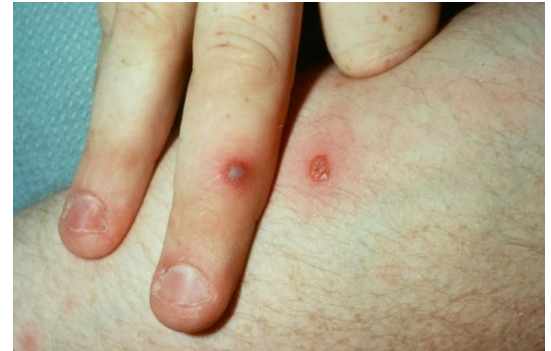▶ Targeted treatment

▶ 2-3 w. or more



Disseminated gonococcal infection

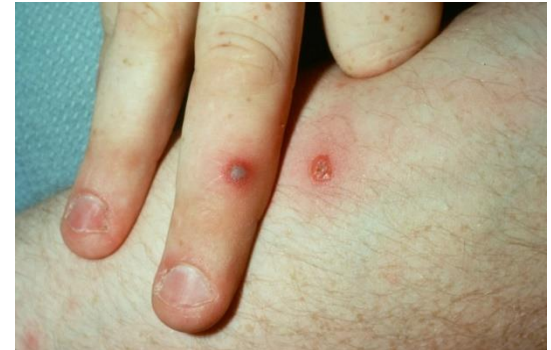- ▶ Urethritis, proctitis, pharyngitis, cervicitis
 - arthritis-dermatitis syndrome: bacteriemia with fever, dermatitis, tenosynovitis (hand, fingers), assymetric migratory polyarthritits
 - monoarthritis



- ▶ Microbiological sampling
 - ▶ Synovial fluid, blood culture – can be negative, especially in arthritis-dermatitis syndrome
 - ▶ ?

Disseminated gonococcal infection

- ▶ Urethritis, proctitis, pharyngitis
 - arthritis-dermatitis syndrome: bacteriemia with fever, dermatitis, tenosynovitis (hand, fingers), assymetric migratory polyarthritits
 - monoarthritis



- ▶ Microbiological sampling
 - ▶ Synovial fluid, blood culture – can be negative, especially in arthritis-dermatitis syndrome
 - ▶ ?

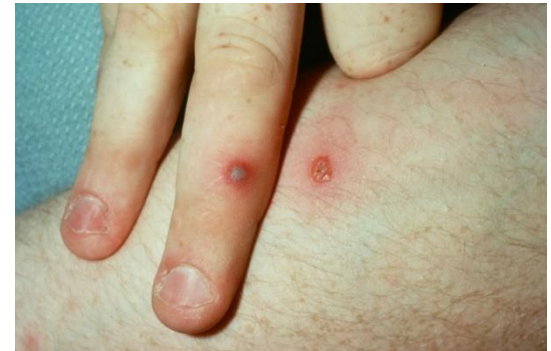

Disseminated gonococcal infection

- ▶ Urethritis, proctitis, pharyngitis

→ arthritis-dermatitis syndrome: bacteriemia with fever, dermatitis, tenosynovitis (hand, fingers), asymmetric migratory polyarthritits

→ monoarthritis



- ▶ Microbiological sampling

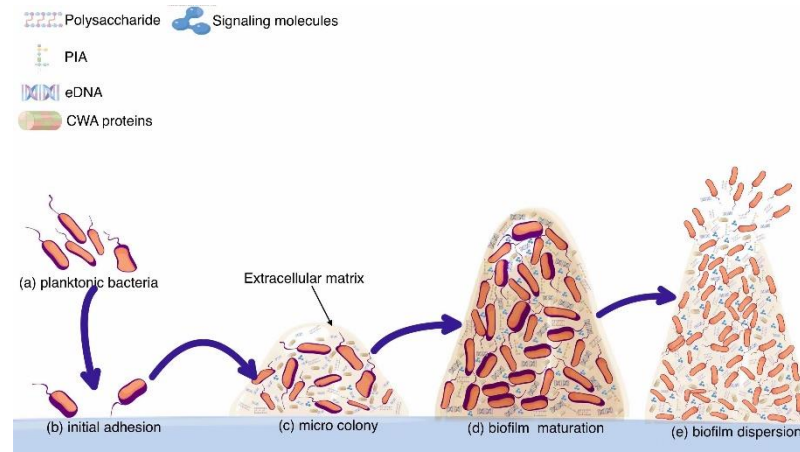
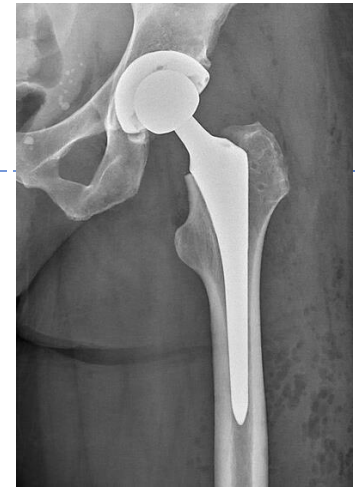- ▶ Synovial fluid, blood culture – can be negative, especially in arthritis-dermatitis syndrome

- ▶ ?

- ▶ Urine, swab (urethral/cervical/rectal/throat) – culture, PCR

Periprosthetic joint infections

- ▶ Incidence 1-2%
- ▶ Pathogenesis
 - ▶ Contamination of operating field, hematogenous
 - ▶ Adhesion to arteficial material and biofilm formation
 - ▶ Poor ATB penetration into a biofilm – surgery and removal often needed



Periprosthetic joint infections - classification

▶ Acute infection (< 3 m.)

- ▶ High virulence (*S.aureus*, beta-hemolytic streptococci, enterobacteriales)
- ▶ Fever, swelling, pain, redness

▶ Delayed (3-12 m.), Late (> 12 m.) infection

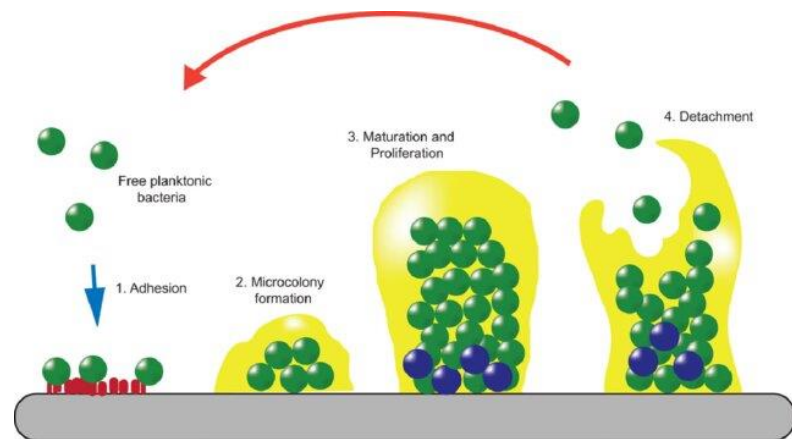
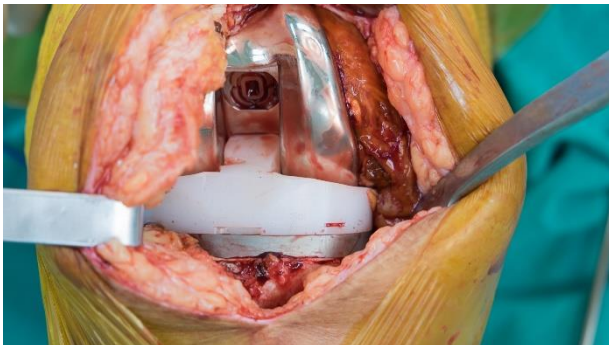
- ▶ Lesser virulence (CNS, *Cutibacterium acnes*, coryneform bacteria, viridans streptococci, enterococci...)
- ▶ Late – also hematogenous
- ▶ Pain, loosening of implant, impaired joint function
- ▶ Possibly without signs of systemic inflammation



Periprosthetic joint infections

▶ Microbiological sampling

- ▶ Synovial fluid, tissue, (implant – sonication)
 - ▶ Microscopy, culture, PCR
- ▶ Careful interpretation
 - ▶ Contamination by skin microbiota?
 - ▶ Synovial fluid – false negativity? (biofilm)
- ▶ Tissue – 6 or more samples
 - ▶ 1 sample positive – significant for virulent pathogens, 2-3 samples for pathogens with lesser virulence





Periprosthetic joint infections – treatment

- ▶ **Surgery + ATB therapy**
 - ▶ Debridement and implant retention (DAIR)
 - ▶ One-stage exchange
 - ▶ Two-stage exchange
 - ▶ With antibiotic-impregnated spacer insertion
 - ▶ ATBs
 - ▶ min 2-6 w.
 - ▶ Targeted
 - ▶ + ATBs with good biofilm concentrations (rifampin, ciprofloxacin)
 - ▶ Empirical treatment – etiology unknown: vancomycin + fluoroquinolone + rifampin → deescalation

Reactive arthritis

- ▶ Immune response (T-cells, cytokines)
 - ▶ Young adults
 - ▶ 1-4 weeks after infection
 - ▶ Other symptoms can be present (conjunctivitis, urethritis)
 - ▶ Triggers: *Chlamydia trachomatis*, *Ureaplasma urealyticum*, *Mycoplasma genitalium*, *Campylobacter*, *Salmonella*, *Shigella*, *Yersinia*, ...
 - ▶ Microbiological testing according to symptoms (urine, stool, blood serum, ...)
 - ▶ Treatment of infection, symptomatic therapy (NSAID – diclofenac; other drugs – rheumatology)
-



Thank you for your attention

