

# ATLAS OF CLINICAL MICROBIOLOGY

## Glass slides microscopy

Author collective:

O. Melter, T. Kopecká, M. Šolarová, H. Nekvasilová, H. Svojtková, A. Píšová, P. Kabelíková, D. Lžičařová,  
S. Opálková, K. Dundrová, J. Hurych, M. Finsterle

© Department of Medical Microbiology, Second Faculty of Medicine, Charles University, Prague (2019)



CHARLES UNIVERSITY  
Second Faculty of Medicine



CHARLES UNIVERSITY  
Second Faculty of Medicine

Slide No. 1

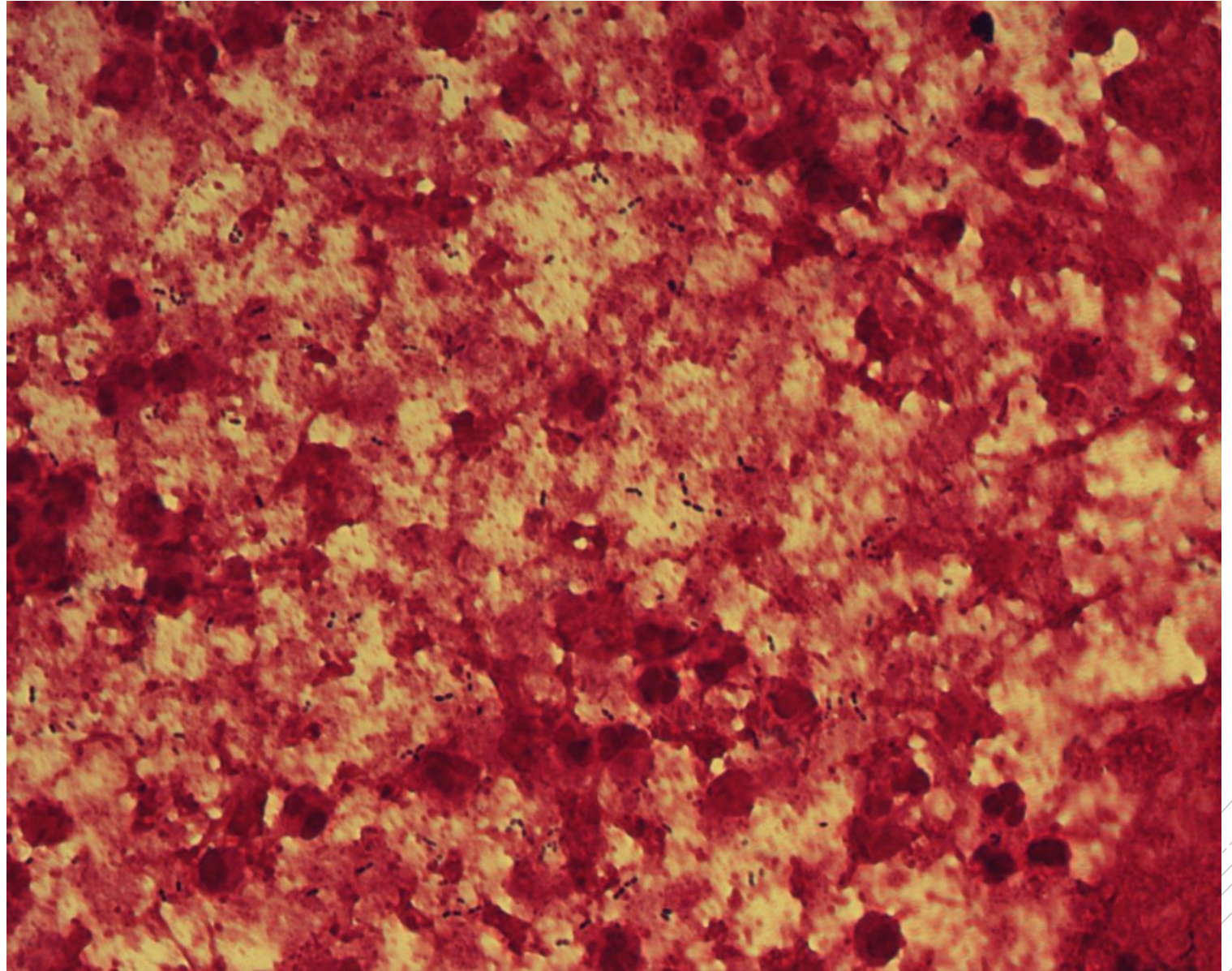
# *Streptococcus pneumoniae*

**Specimen:** sputum

**Patient:** male, 42 years old

**Dg.:** exacerbation of bronchiectasis

**Microscopy:** Gram-positive diplococci,  
lancet-shaped



Author: MUDr. Alena Pířová



CHARLES UNIVERSITY  
Second Faculty of Medicine

Slide No. 1


# *Streptococcus pneumoniae*

**Specimen:** sputum

**Patient:** male, 42 years old

**Dg.:** exacerbation of bronchiectasis

**Microscopy:** Gram-positive diplococci,  
lancet-shaped



Author: MUDr. Alena Pířová



CHARLES UNIVERSITY  
Second Faculty of Medicine

Slide No. 2

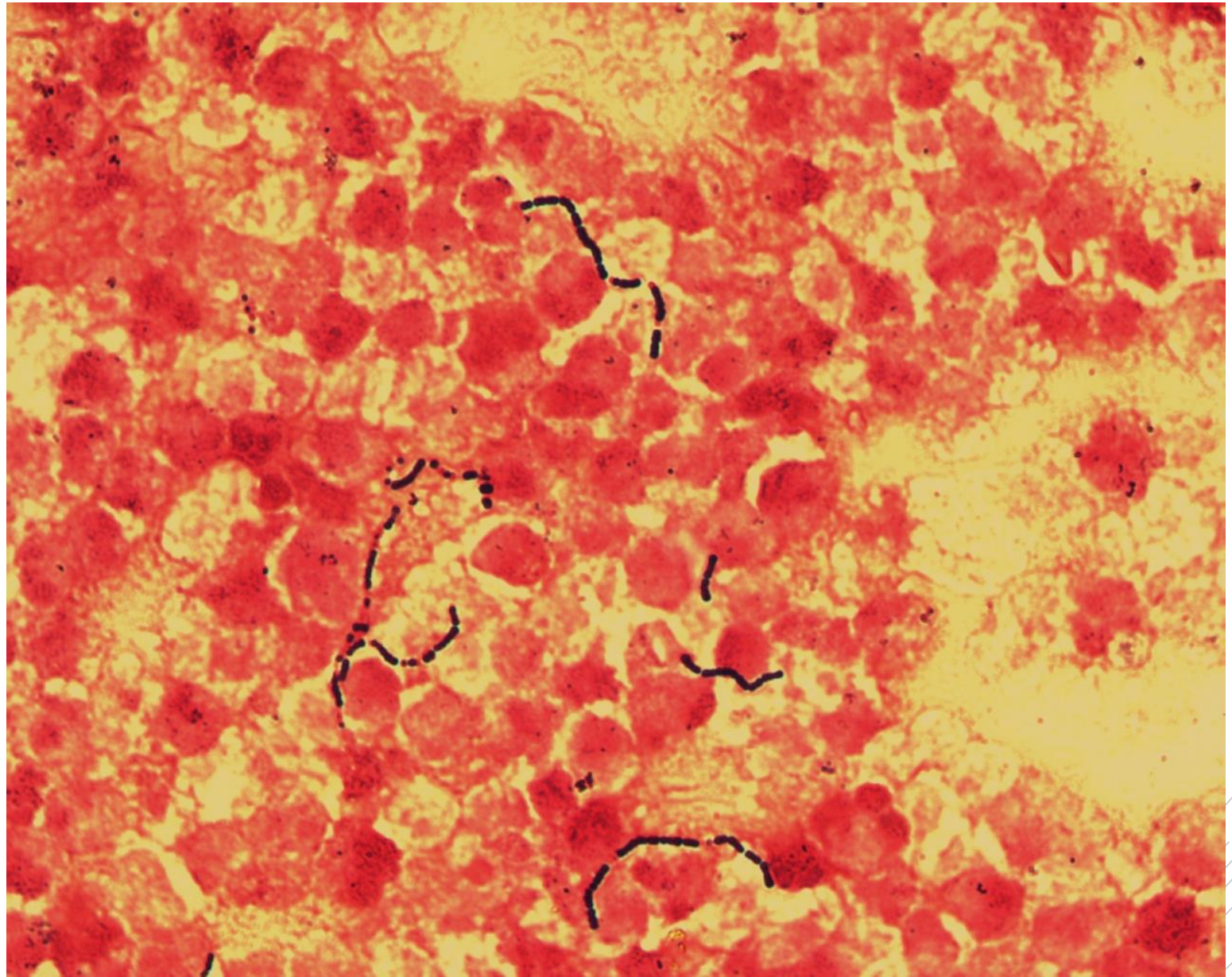
# *Streptococcus agalactiae*

**Specimen:** Pus

**Patient:** male, 77 years old

**Dg.:** periappendicular abscess

**Microscopy:** Gram-positive cocci  
in chains



Author: MUDr. Alena Pířová



CHARLES UNIVERSITY  
Second Faculty of Medicine

Slide No. 2


# *Streptococcus agalactiae*

**Specimen:** Pus

**Patient:** male, 77 years old

**Dg.:** periappendicular abscess

**Microscopy:** Gram-positive cocci  
in chains



Author: MUDr. Alena Pířová



CHARLES UNIVERSITY  
Second Faculty of Medicine

Slide No. 3

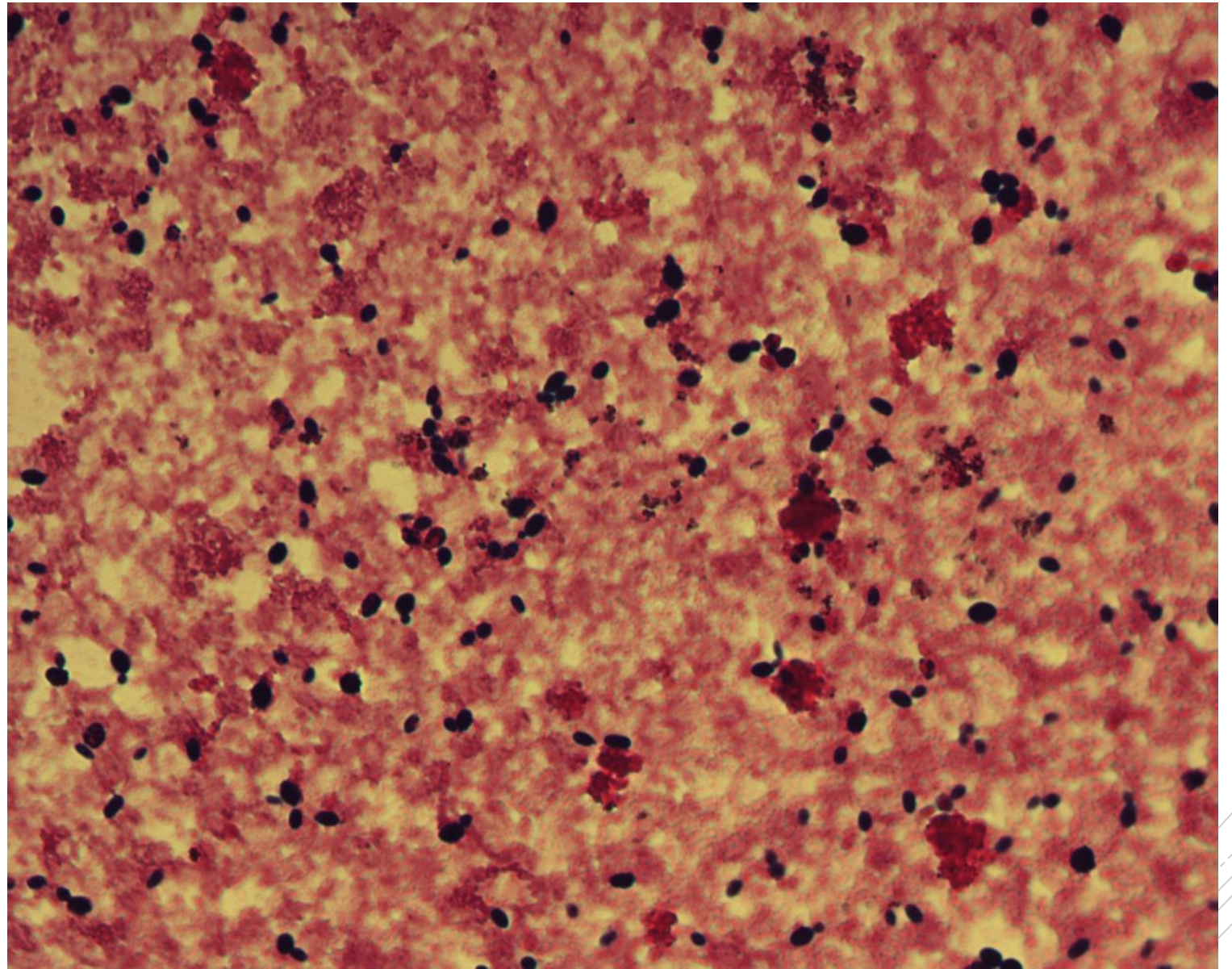
# *Candida fabianii*

**Specimen:** blood culture

**Patient:** male, 2 years old

**Dg.:** acute myeloid leukemia

**Microscopy:** yeast blastoconidia



Author: MUDr. Petra Kabelíková



CHARLES UNIVERSITY  
Second Faculty of Medicine

Slide No. 3

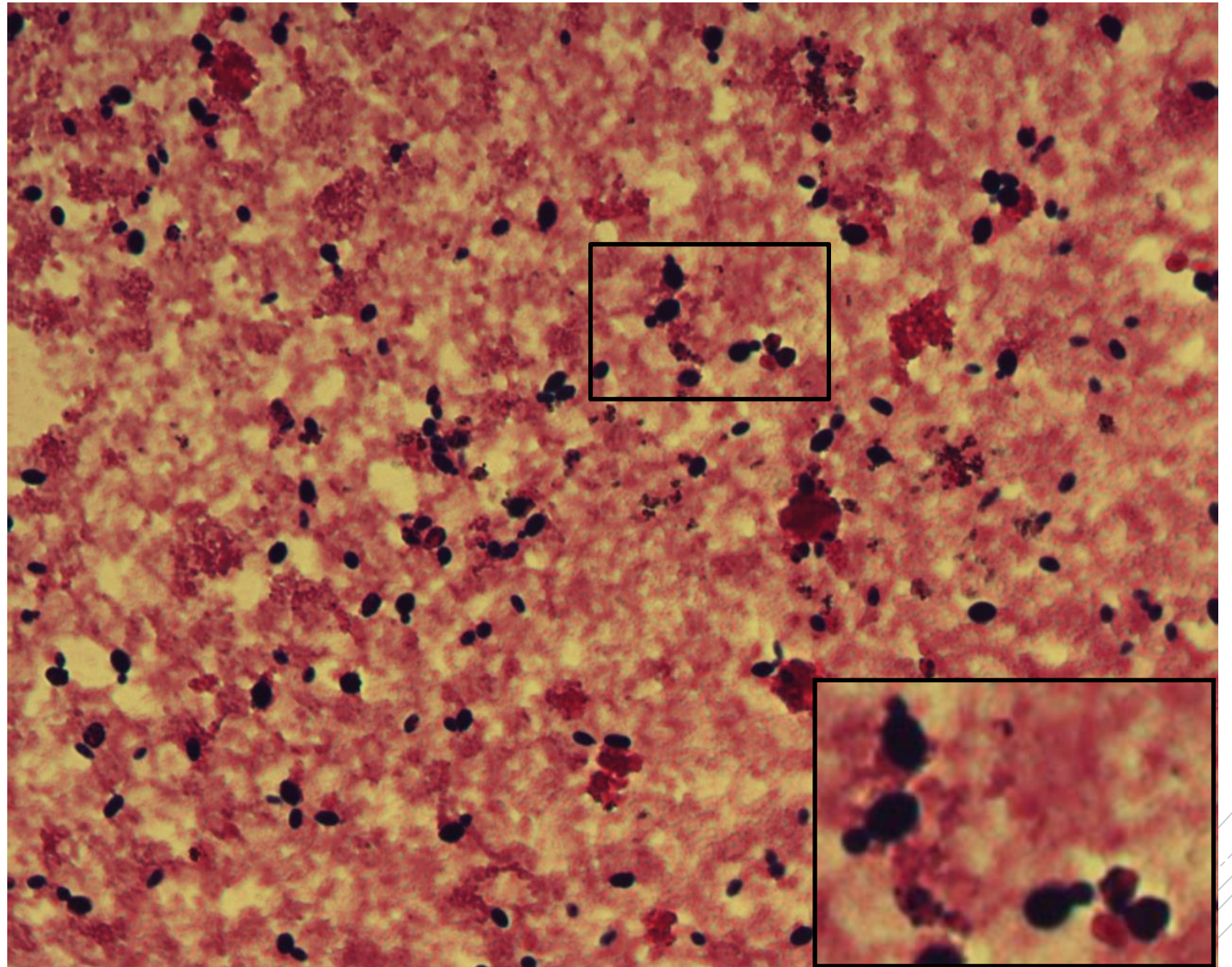
# *Candida fabianii*

**Specimen:** blood culture

**Patient:** male, 2 years old

**Dg.:** acute myeloid leukemia

**Microscopy:** yeast blastoconidia



Author: MUDr. Petra Kabelíková



CHARLES UNIVERSITY  
Second Faculty of Medicine

Slide No. 4

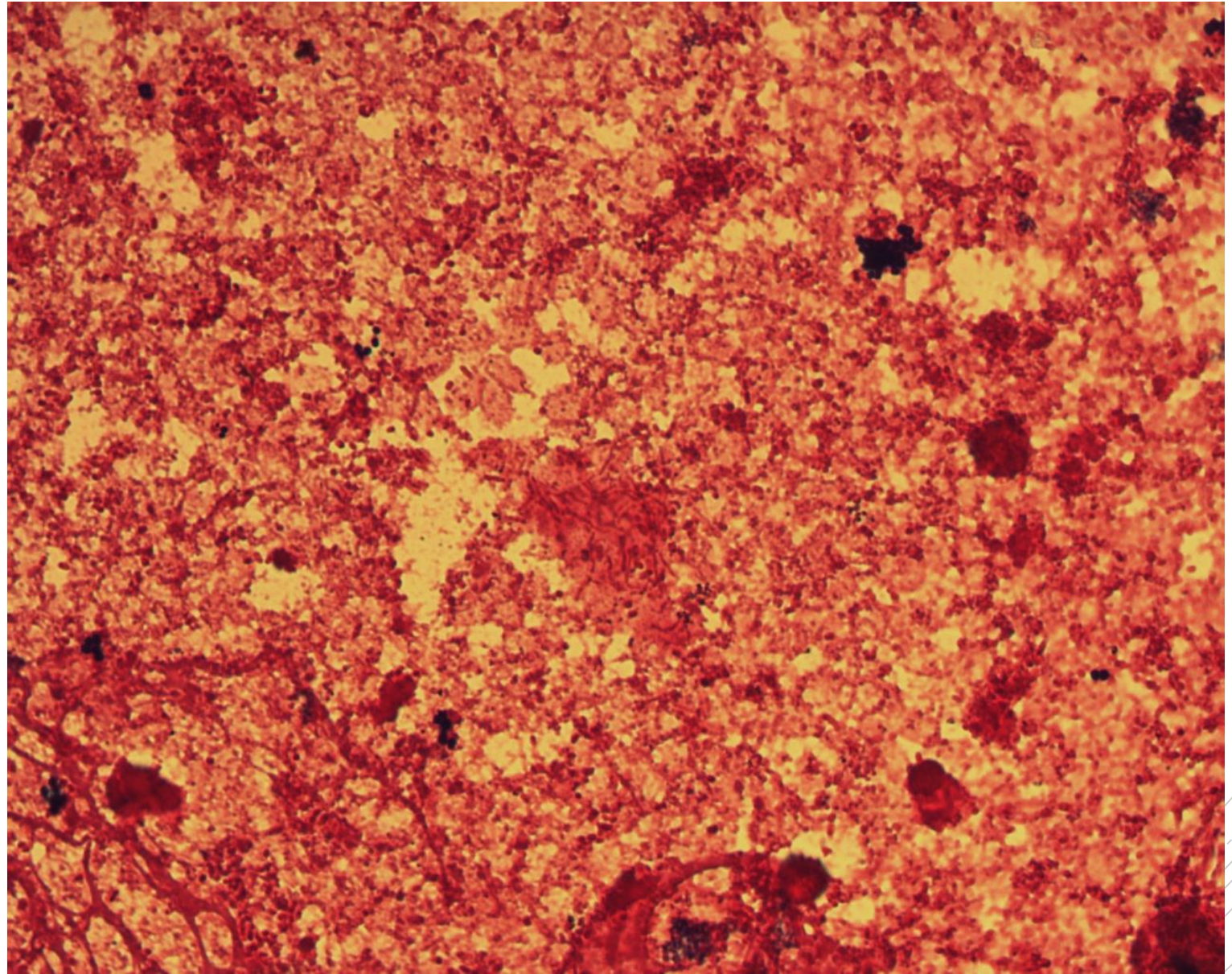
# *Escherichia coli,* *Proteus mirabilis*

**Specimen:** blood culture

**Patient:** female, 89 years old

**Dg.:** urosepsis

**Microscopy:** Gram-negative rods



Author: MUDr. Petra Kabelíková





CHARLES UNIVERSITY  
Second Faculty of Medicine

Slide No. 4

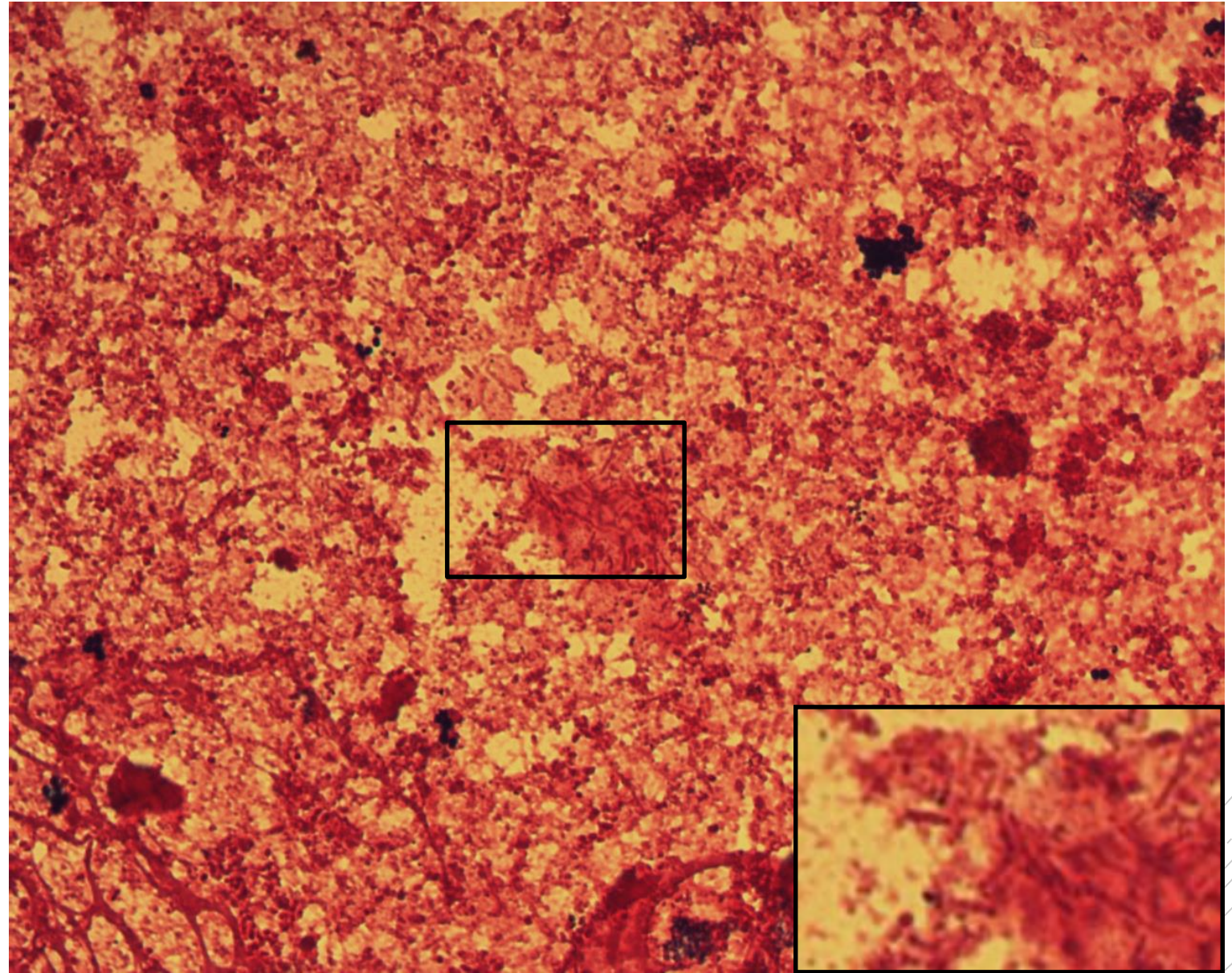
# *Escherichia coli,* *Proteus mirabilis*

**Specimen:** blood culture

**Patient:** female, 89 years old

**Dg.:** urosepsis

**Microscopy:** Gram-negative rods



Author: MUDr. Petra Kabelíková



CHARLES UNIVERSITY  
Second Faculty of Medicine

Slide No. 5

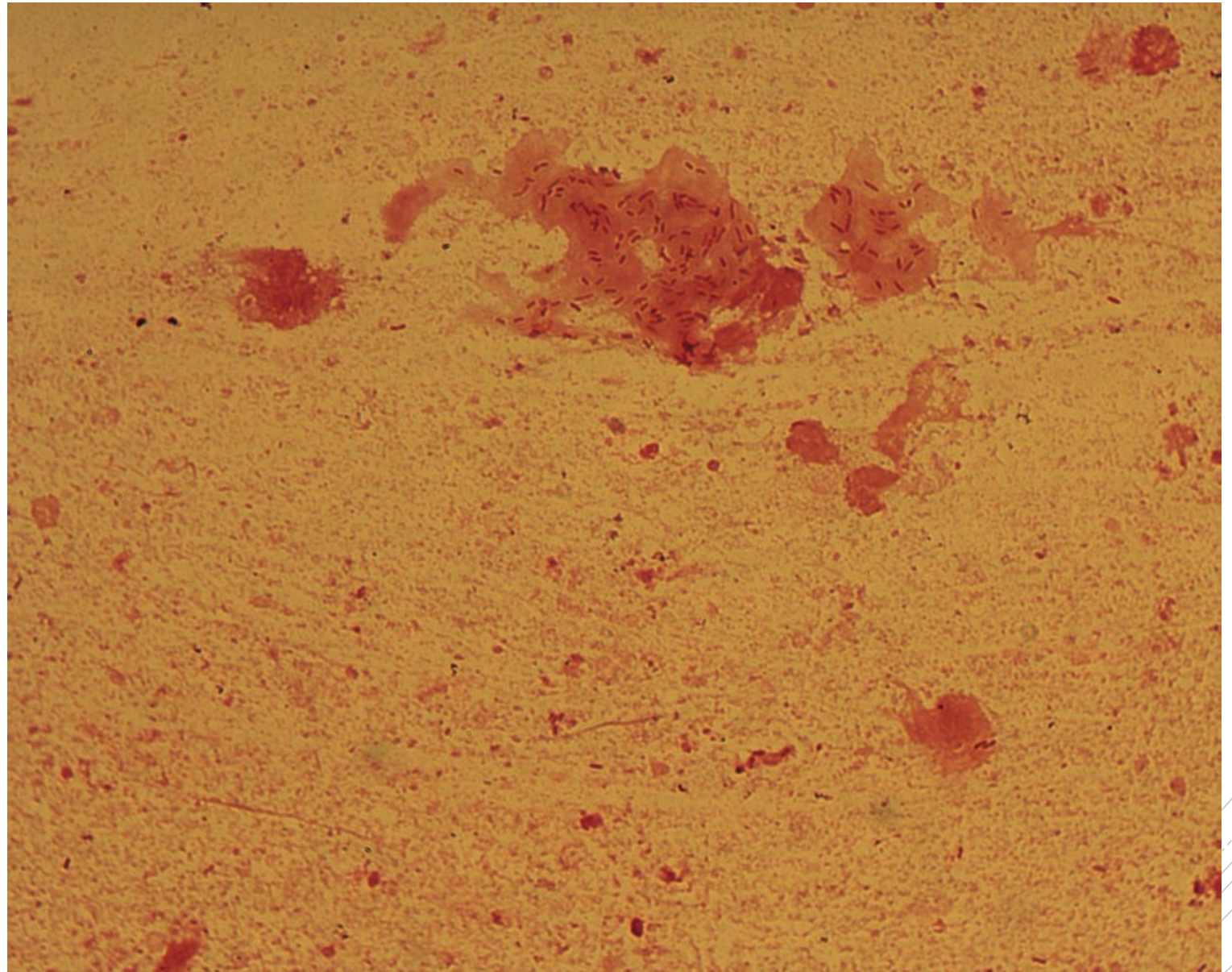
# *Pseudomonas aeruginosa*

**Specimen:** sputum

**Patient:** male, 25 years old

**Dg.:** cystic fibrosis exacerbation

**Microscopy:** Gram-negative rods  
in a biofilm fragment



Author: doc. MVDr. Oto Melter, PhD.



CHARLES UNIVERSITY  
Second Faculty of Medicine

Slide No. 5

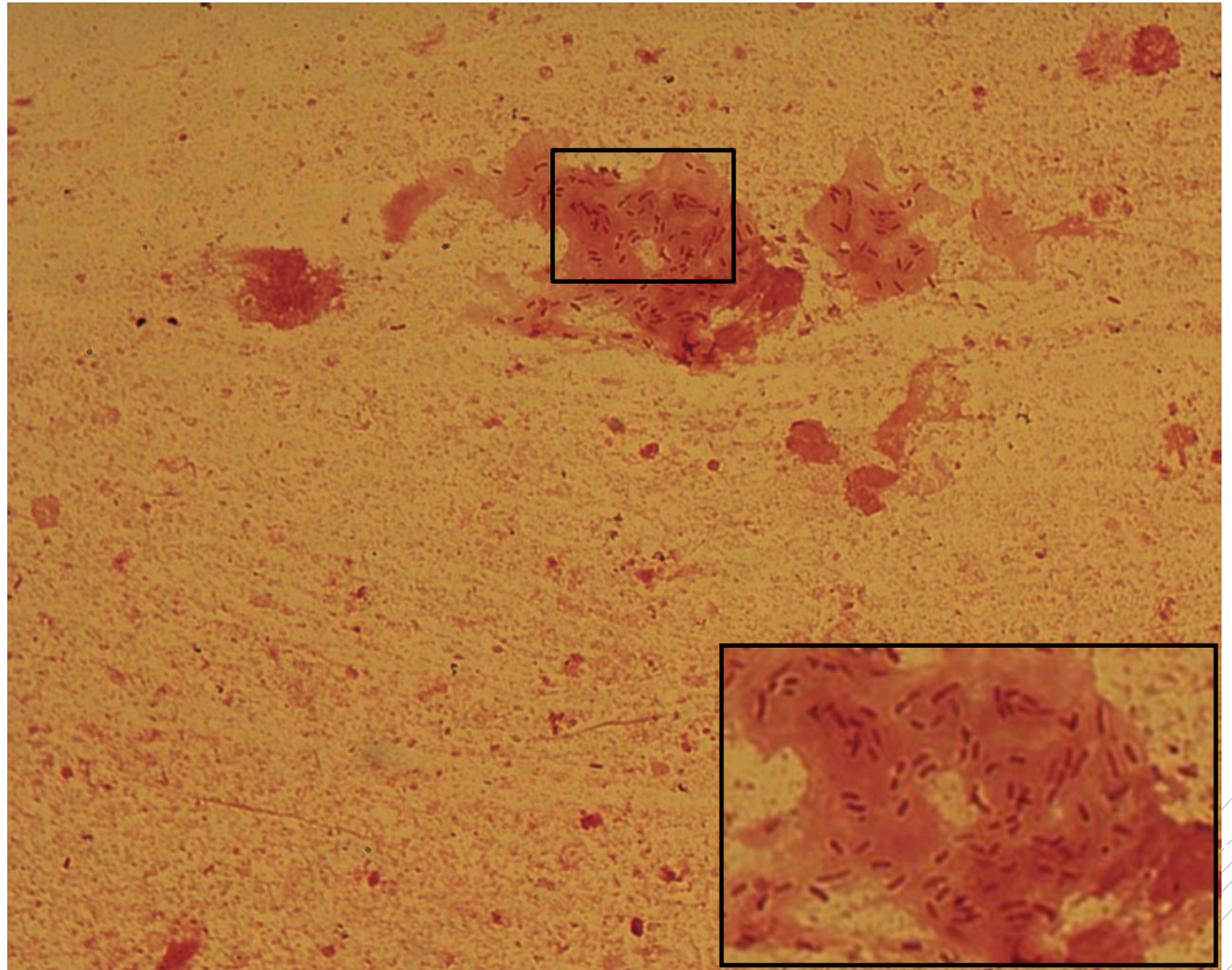
# *Pseudomonas aeruginosa*

**Specimen:** sputum

**Patient:** male, 25 years old

**Dg.:** cystic fibrosis exacerbation

**Microscopy:** Gram-negative rods  
in a biofilm fragment



Author: doc. MVDr. Oto Melter, PhD.



CHARLES UNIVERSITY  
Second Faculty of Medicine

Slide No. 6

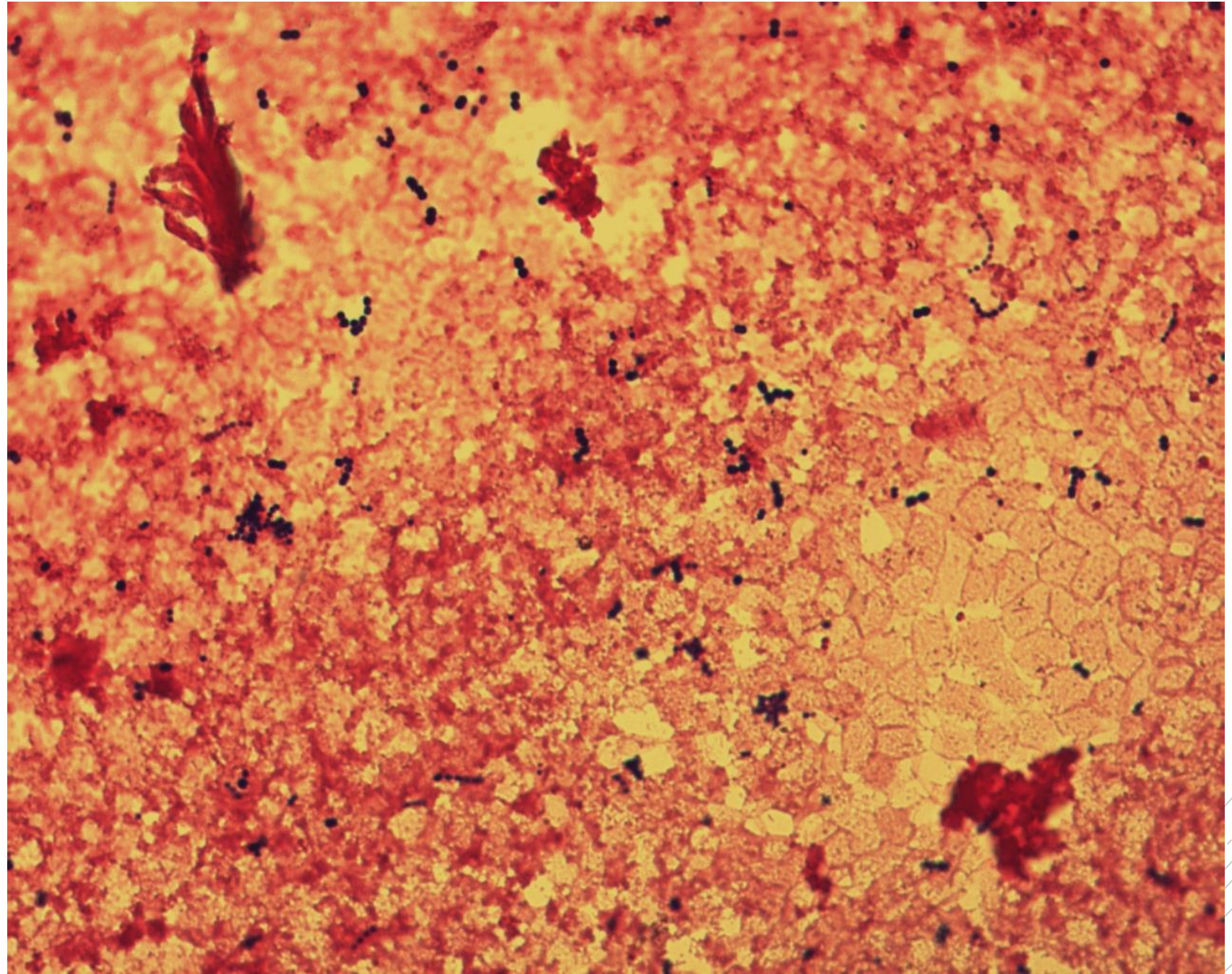
# *Enterococcus faecalis*

**Specimen:** blood culture

**Patient:** female, 71 years old

**Dg.:** gallbladder sepsis

**Microscopy:** Gram-positive cocci  
in chains



Author: MUDr. Petra Kabelíková



CHARLES UNIVERSITY  
Second Faculty of Medicine

Slide No. 6

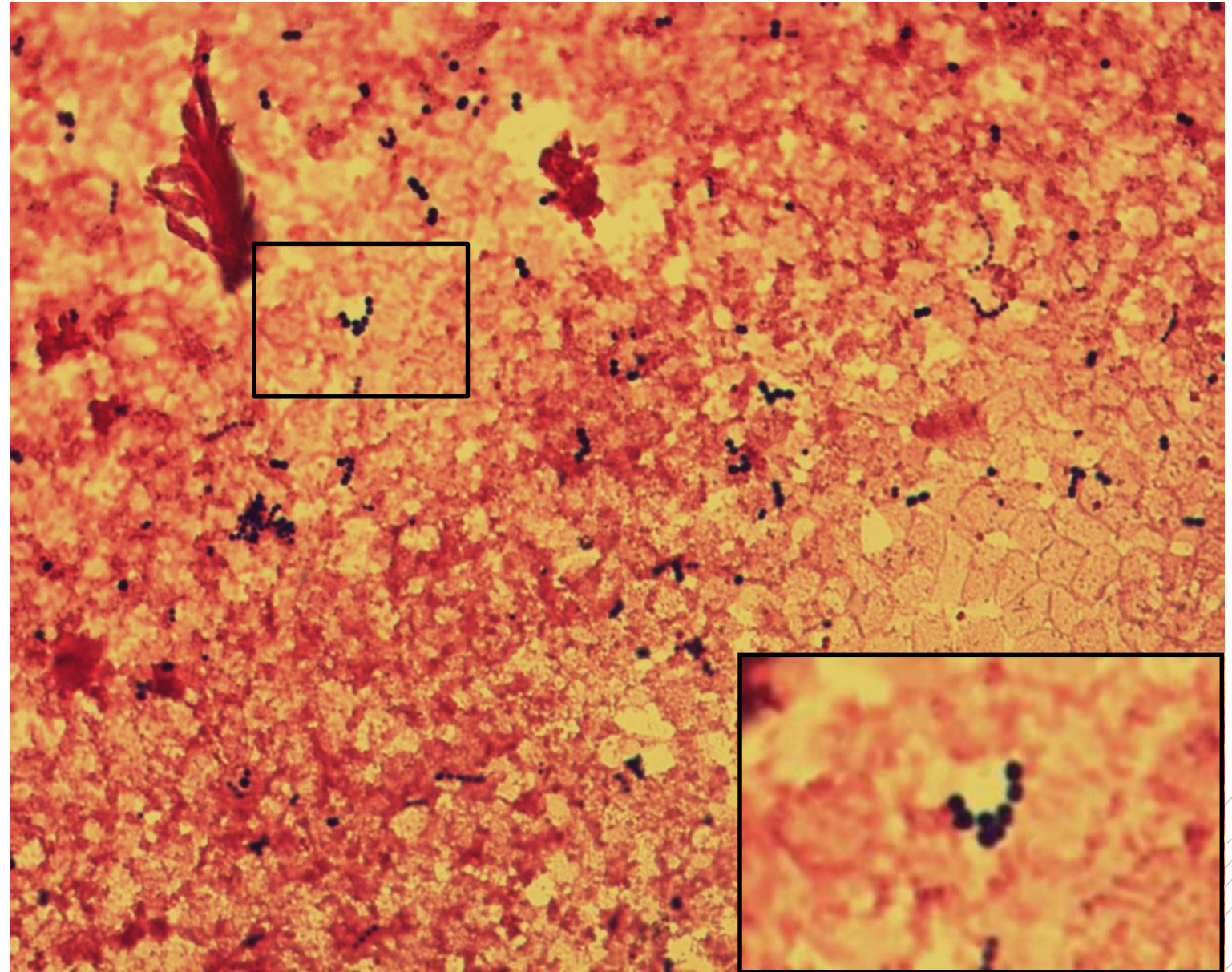
# *Enterococcus faecalis*

**Specimen:** blood culture

**Patient:** female, 71 years old

**Dg.:** gallbladder sepsis

**Microscopy:** Gram-positive cocci  
in chains



Author: MUDr. Petra Kabelíková



CHARLES UNIVERSITY  
Second Faculty of Medicine

Slide No. 7

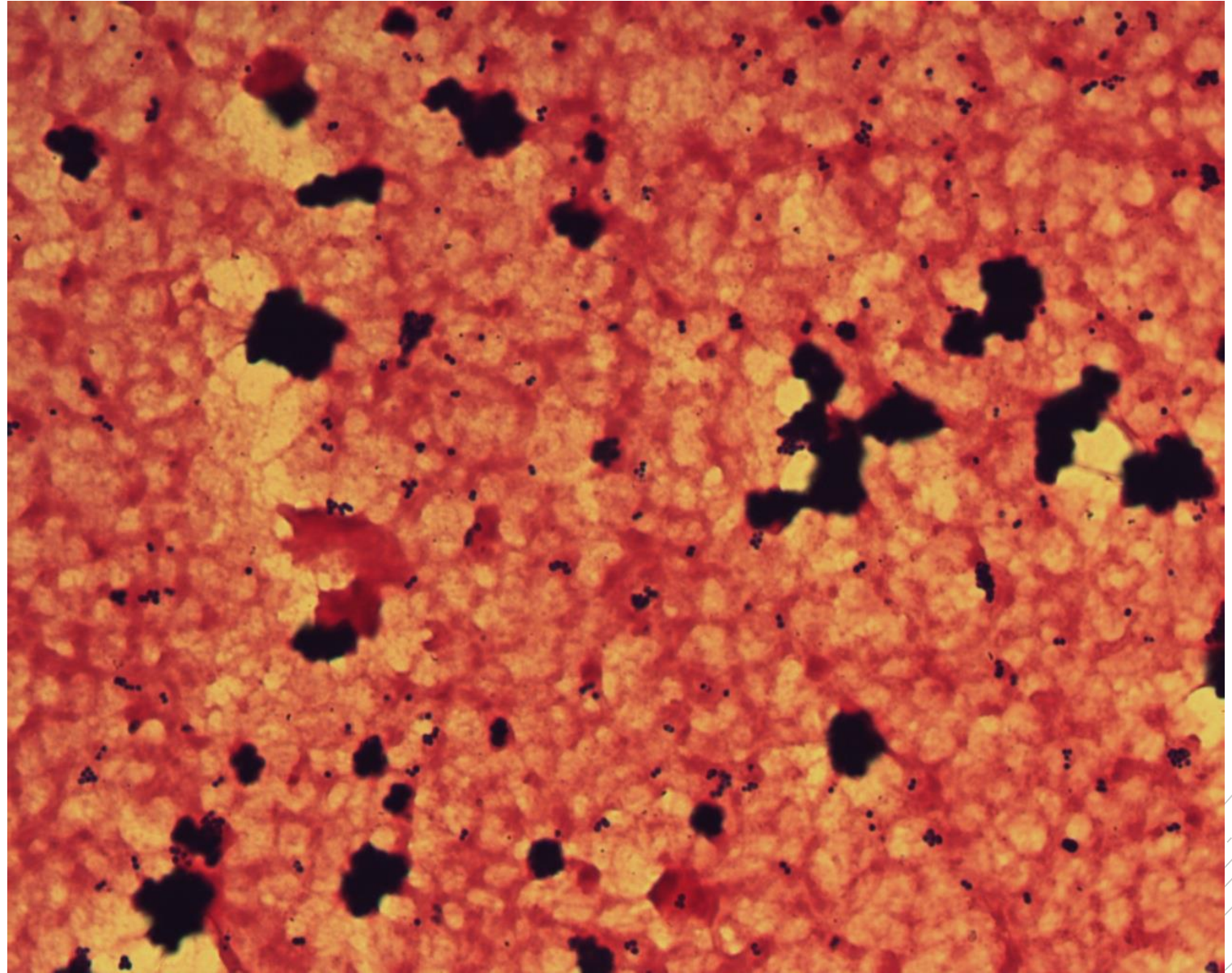
# *Staphylococcus aureus*

**Specimen:** blood culture

**Patient:** female, 84 years old

**Dg.:** endocarditis

**Microscopy:** Gram-positive cocci  
in clusters



Author: MUDr. Petra Kabelíková



CHARLES UNIVERSITY  
Second Faculty of Medicine

Slide No. 7


# *Staphylococcus aureus*

**Specimen:** blood culture

**Patient:** female, 84 years old

**Dg.:** endocarditis

**Microscopy:** Gram-positive cocci  
in clusters



Author: MUDr. Petra Kabelíková



CHARLES UNIVERSITY  
Second Faculty of Medicine

Slide No. 8

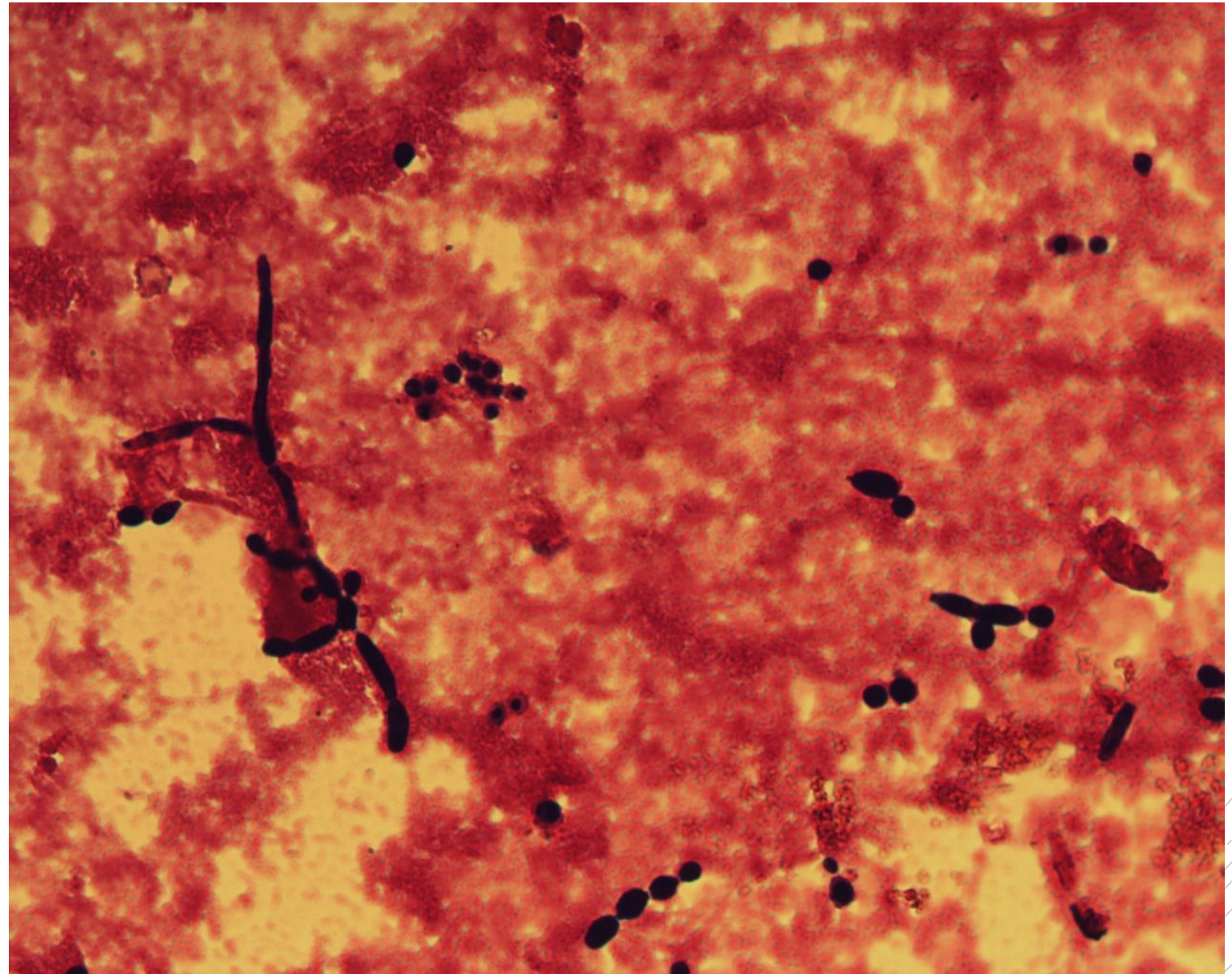
# *Candida albicans*

**Specimen:** blood culture

**Patient:** female, 9 years old

**Dg.:** catheter sepsis

**Microscopy:** yeast blastoconidia,  
pseudohyphae



Author: MUDr. Petra Kabelíková





CHARLES UNIVERSITY  
Second Faculty of Medicine

Slide No. 8

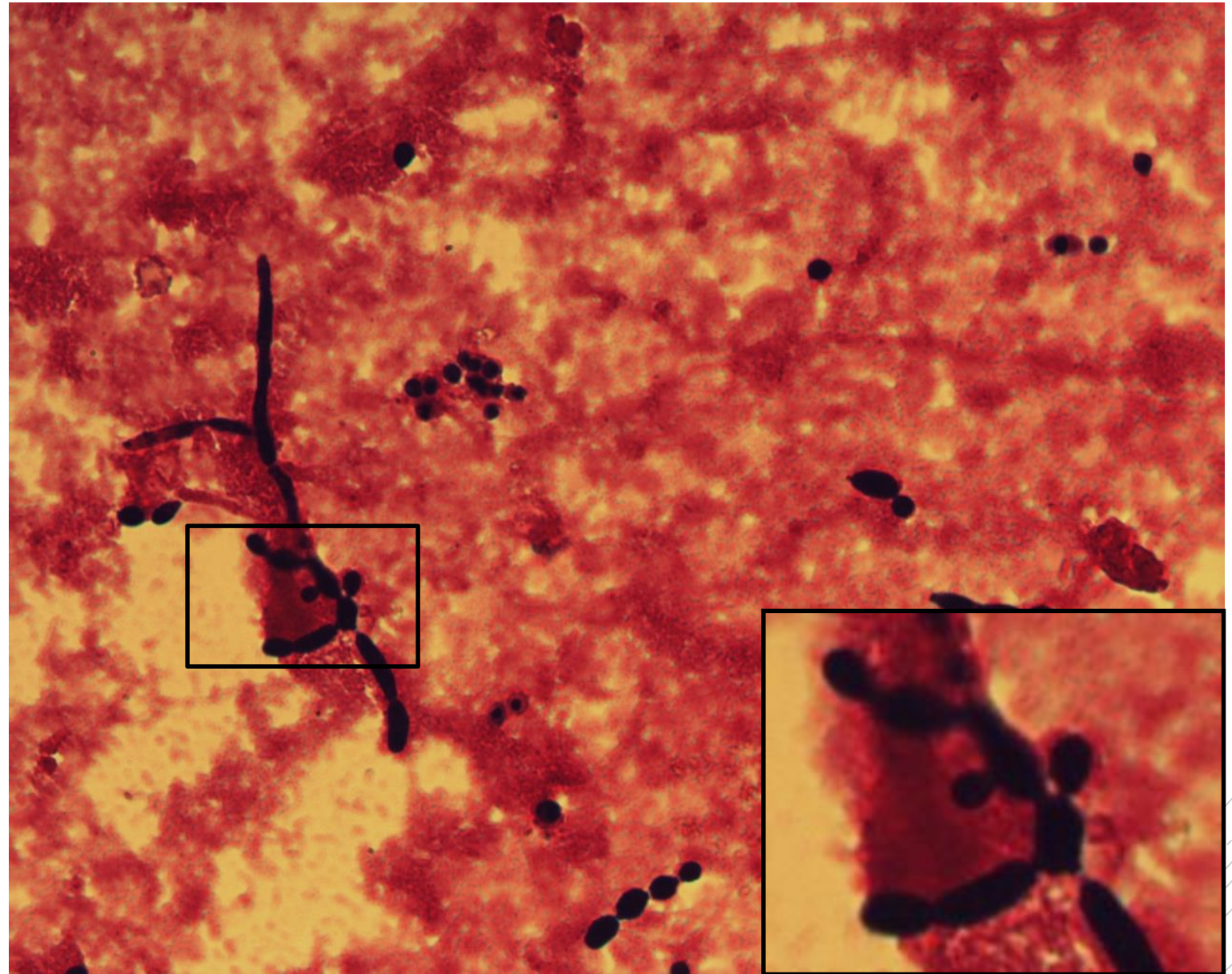
# *Candida albicans*

**Specimen:** blood culture

**Patient:** female, 9 years old

**Dg.:** catheter sepsis

**Microscopy:** yeast blastoconidia,  
pseudohyphae



Author: MUDr. Petra Kabelíková



CHARLES UNIVERSITY  
Second Faculty of Medicine

Slide No. 9

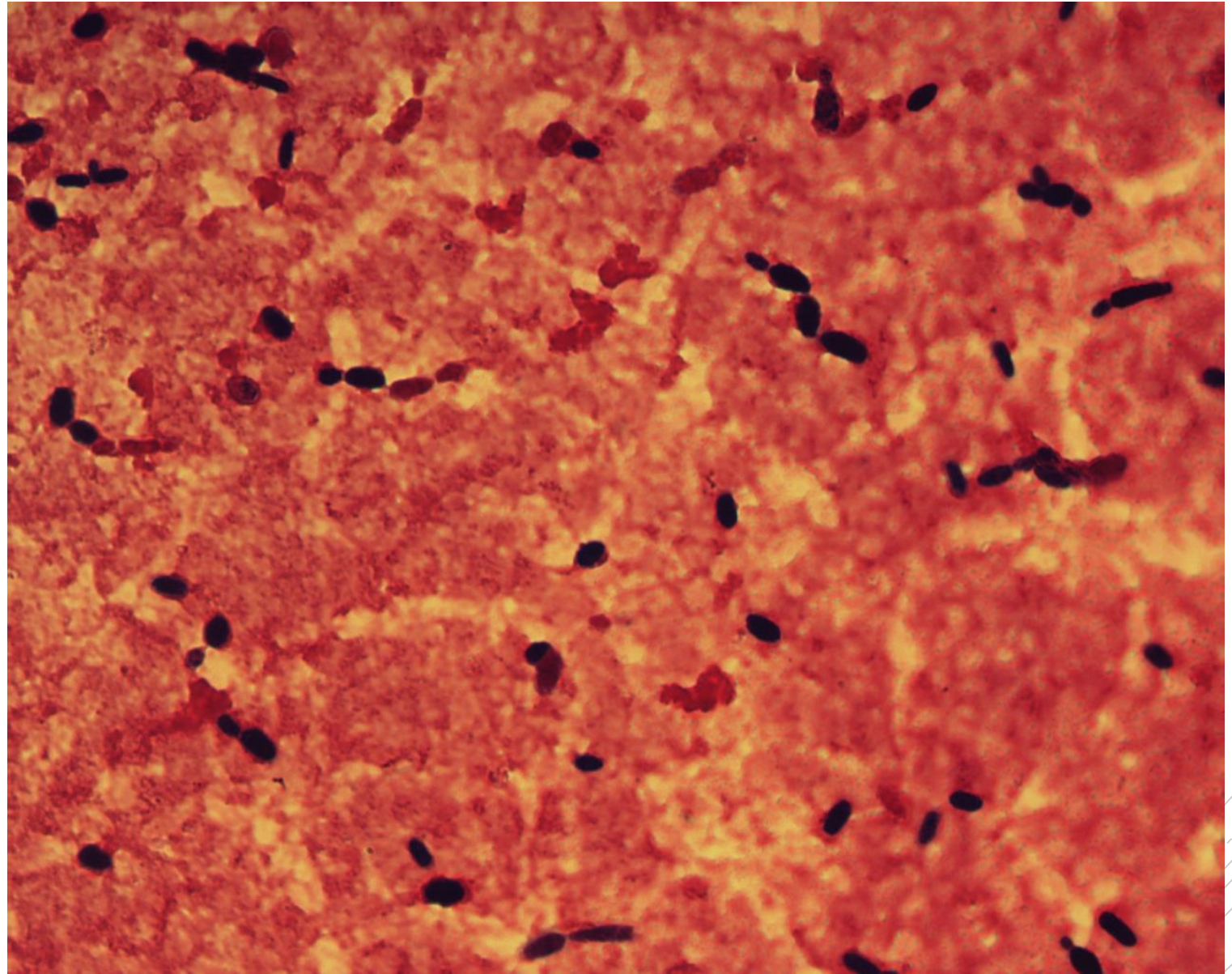
# *Candida tropicalis*

**Specimen:** blood culture

**Patient:** female, 75 years old

**Dg.:** catheter sepsis

**Microscopy:** yeast blastoconidia



Author: MUDr. Petra Kabelíková



CHARLES UNIVERSITY  
Second Faculty of Medicine

Slide No. 9

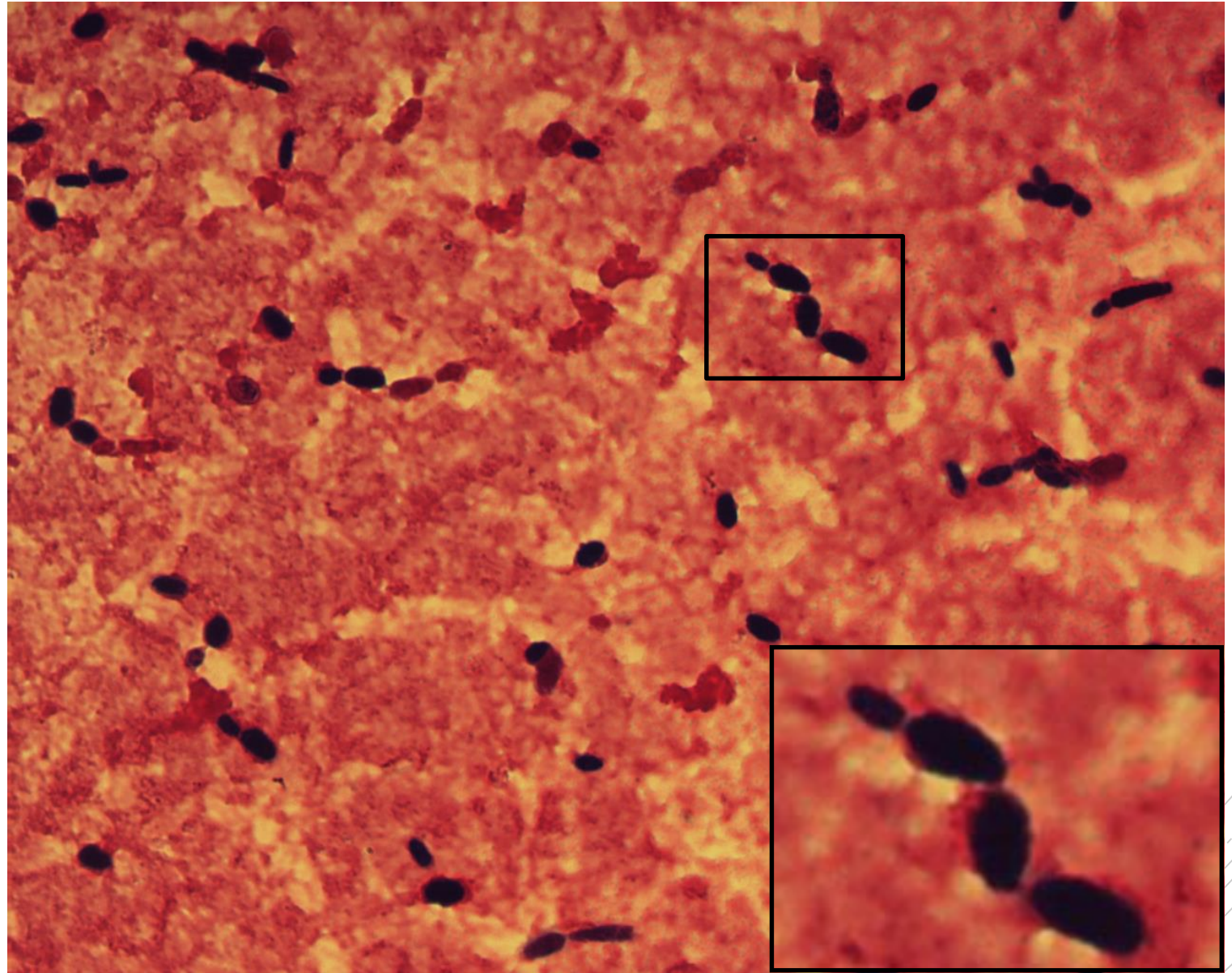
# *Candida tropicalis*

**Specimen:** blood culture

**Patient:** female, 75 years old

**Dg.:** catheter sepsis

**Microscopy:** yeast blastoconidia



Author: MUDr. Petra Kabelíková



CHARLES UNIVERSITY  
Second Faculty of Medicine

Slide No. 10

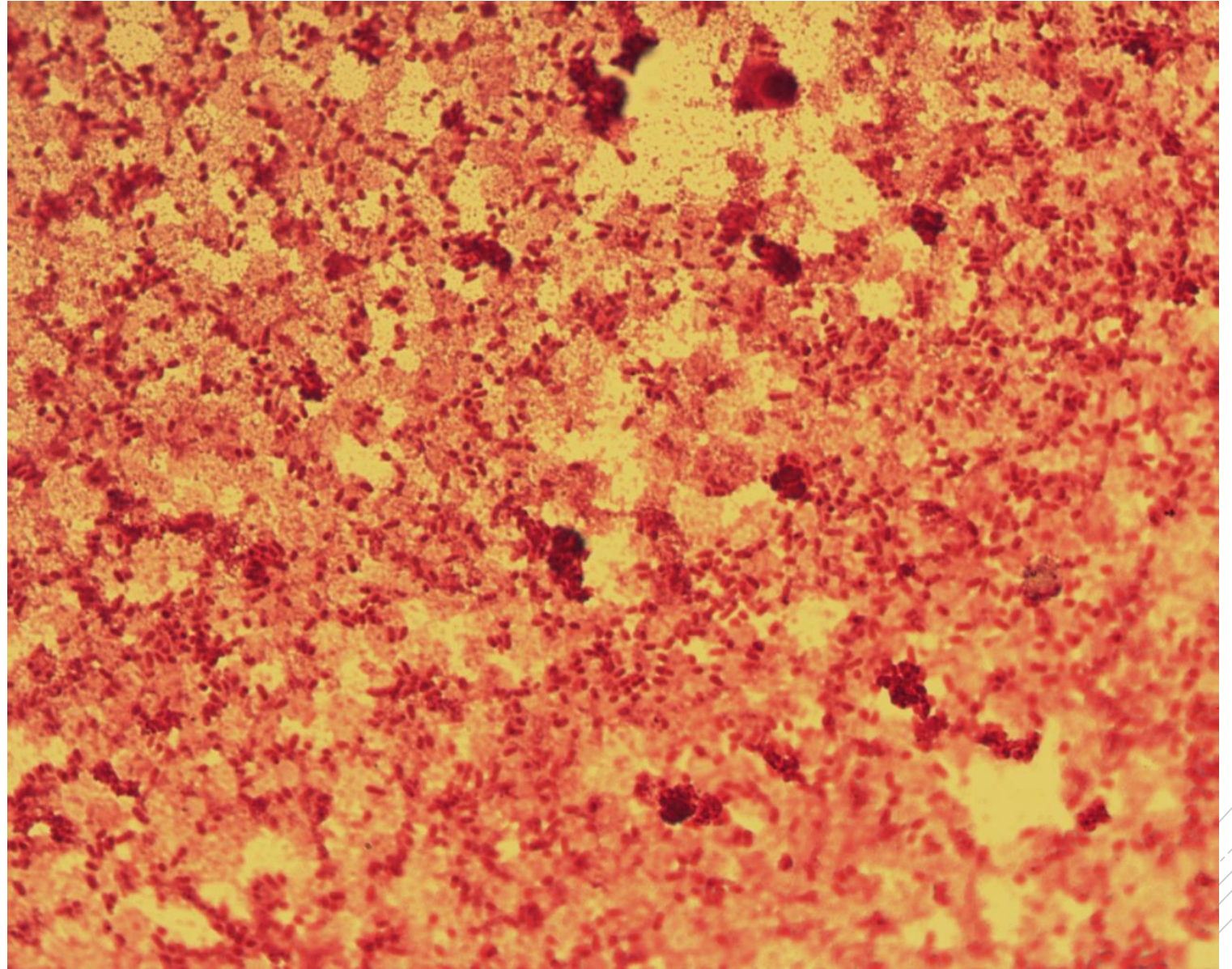
# *Klebsiella pneumoniae*

**Specimen:** blood culture

**Patient:** male, 40 years old

**Dg.:** sepsis of unknown origin

**Microscopy:** Gram-negative rods



Author: MUDr. Petra Kabelíková



CHARLES UNIVERSITY  
Second Faculty of Medicine

Slide No. 10

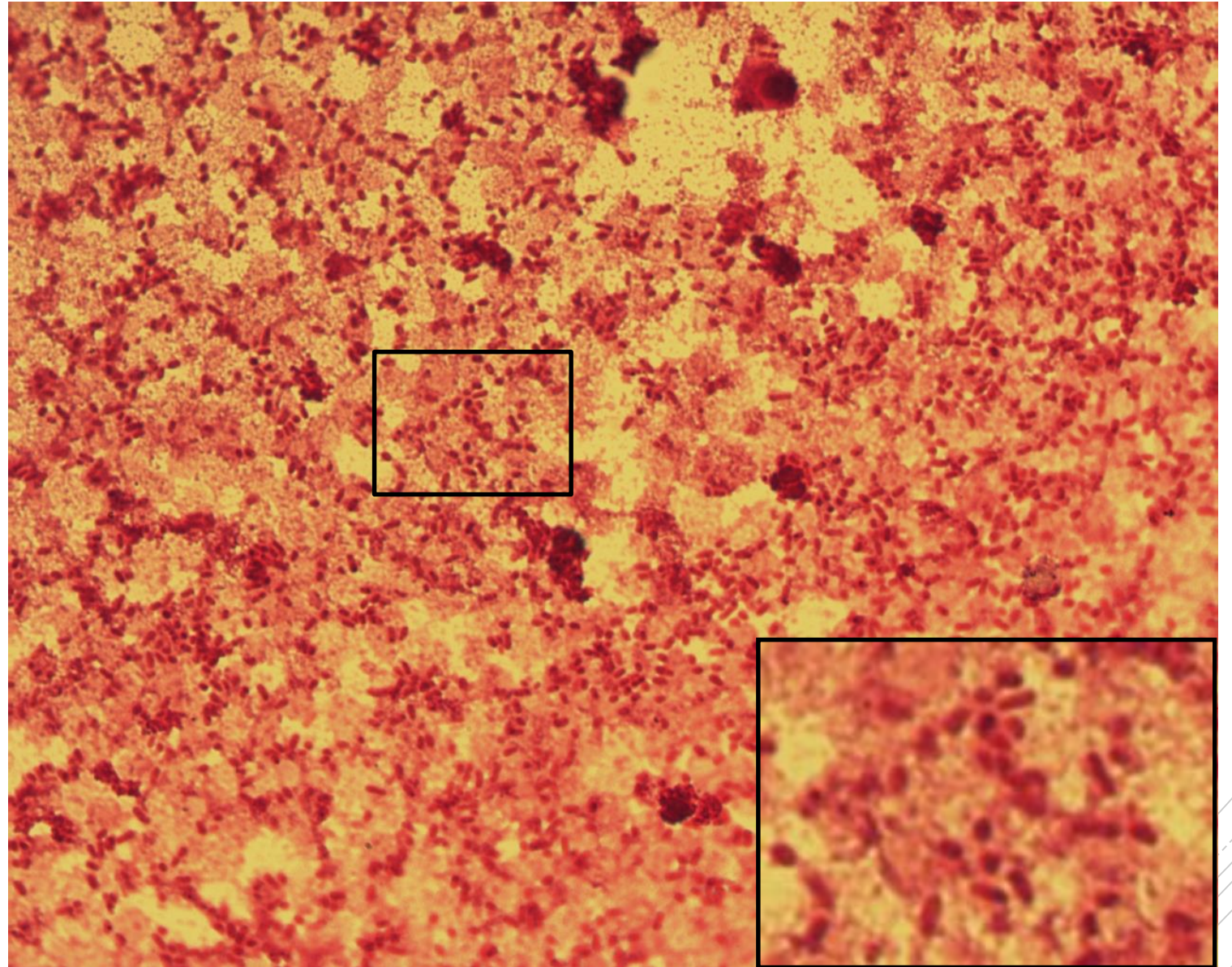
# *Klebsiella pneumoniae*

**Specimen:** blood culture

**Patient:** male, 40 years old

**Dg.:** sepsis of unknown origin

**Microscopy:** Gram-negative rods



Author: MUDr. Petra Kabelíková



CHARLES UNIVERSITY  
Second Faculty of Medicine

Slide No. 11

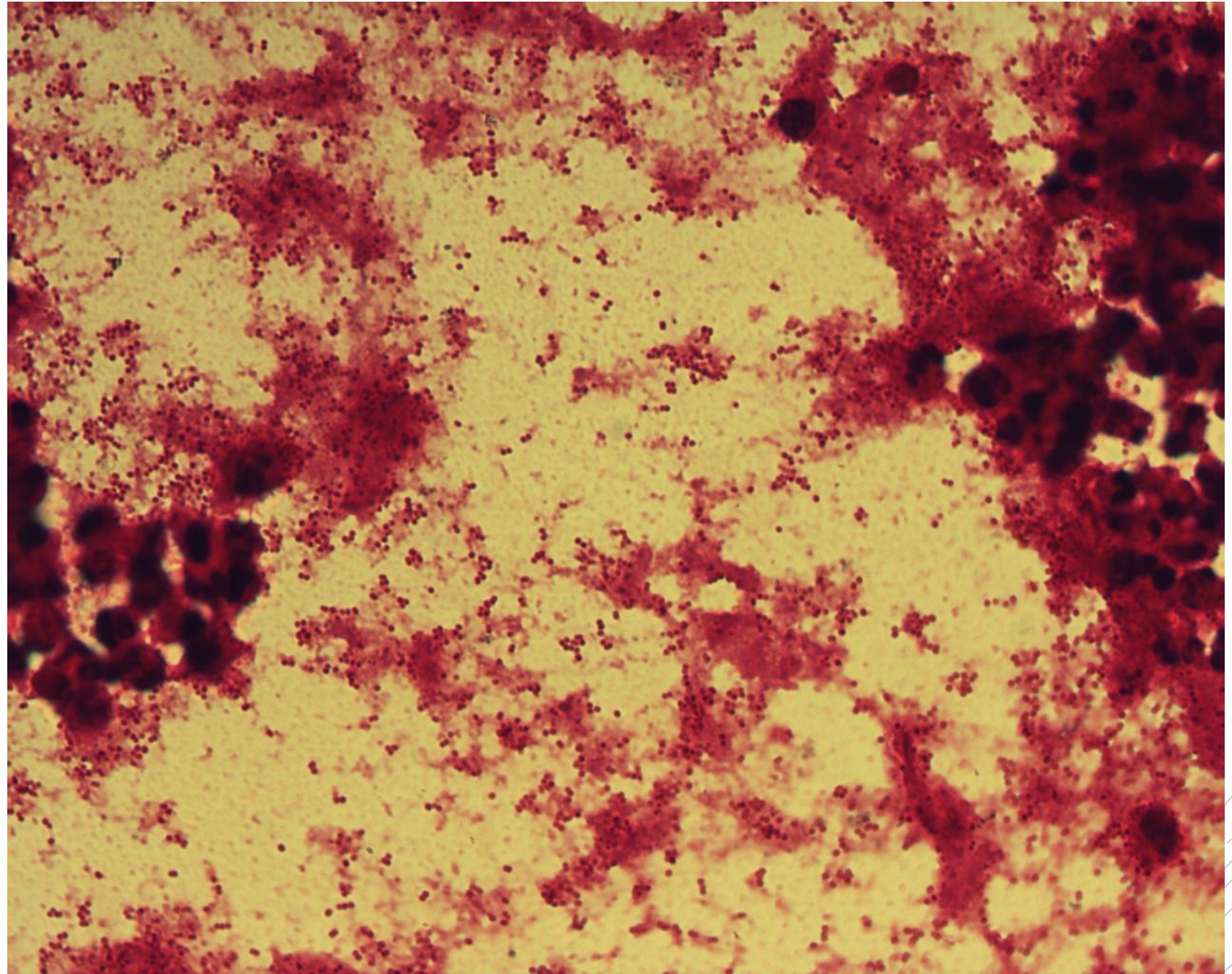
# *Branhamella catarrhalis*

**Specimen:** sputum

**Patient:** male, 85 years old

**Dg.:** nosocomial pneumonia

**Microscopy:** Gram-negative cocci  
in couples and clusters



Author: MUDr. Alena Píšová



CHARLES UNIVERSITY  
Second Faculty of Medicine

Slide No. 11

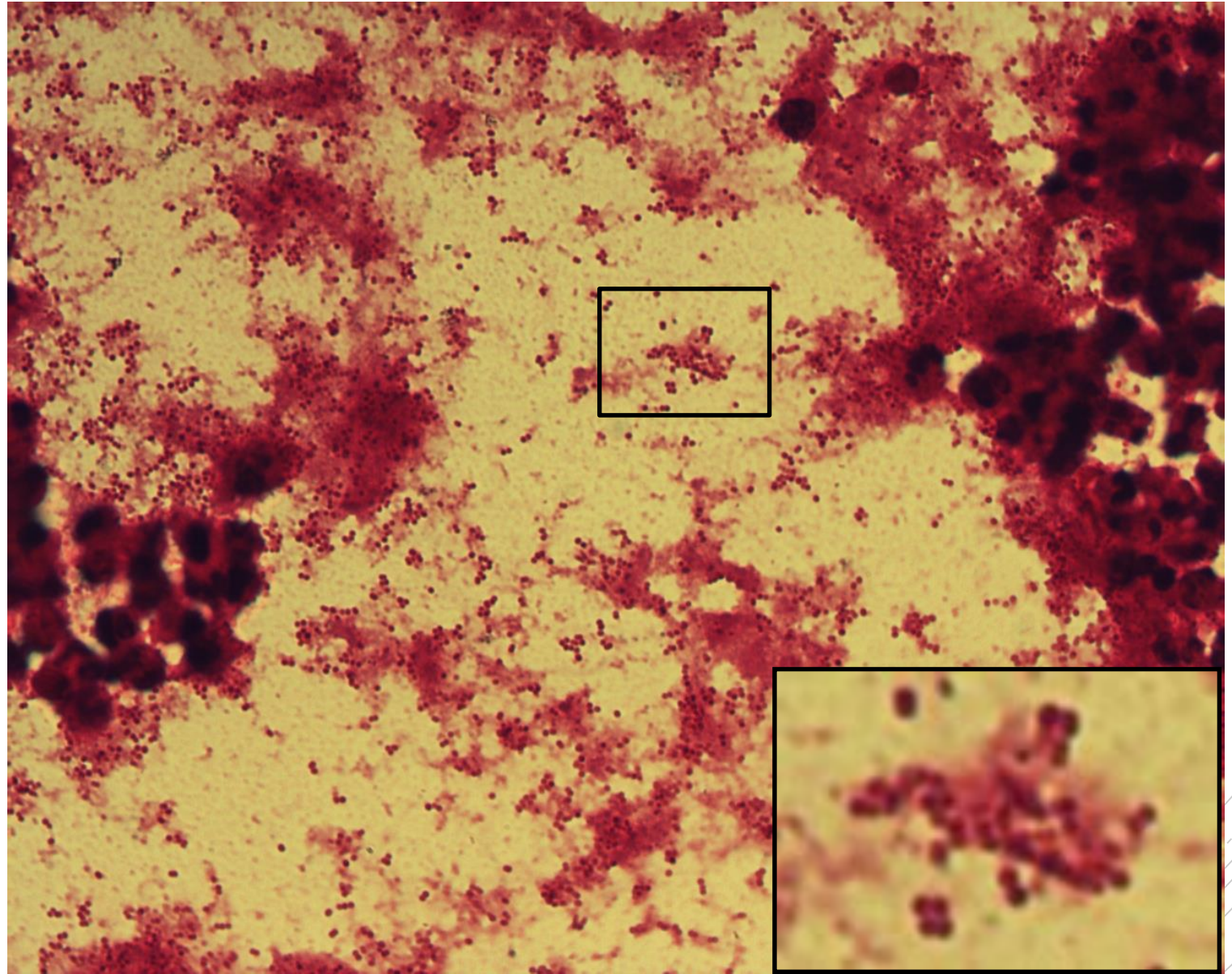
# *Branhamella catarrhalis*

**Specimen:** sputum

**Patient:** male, 85 years old

**Dg.:** nosocomial pneumonia

**Microscopy:** Gram-negative cocci  
in couples and clusters



Author: MUDr. Alena Pířová



CHARLES UNIVERSITY  
Second Faculty of Medicine

Slide No. 12

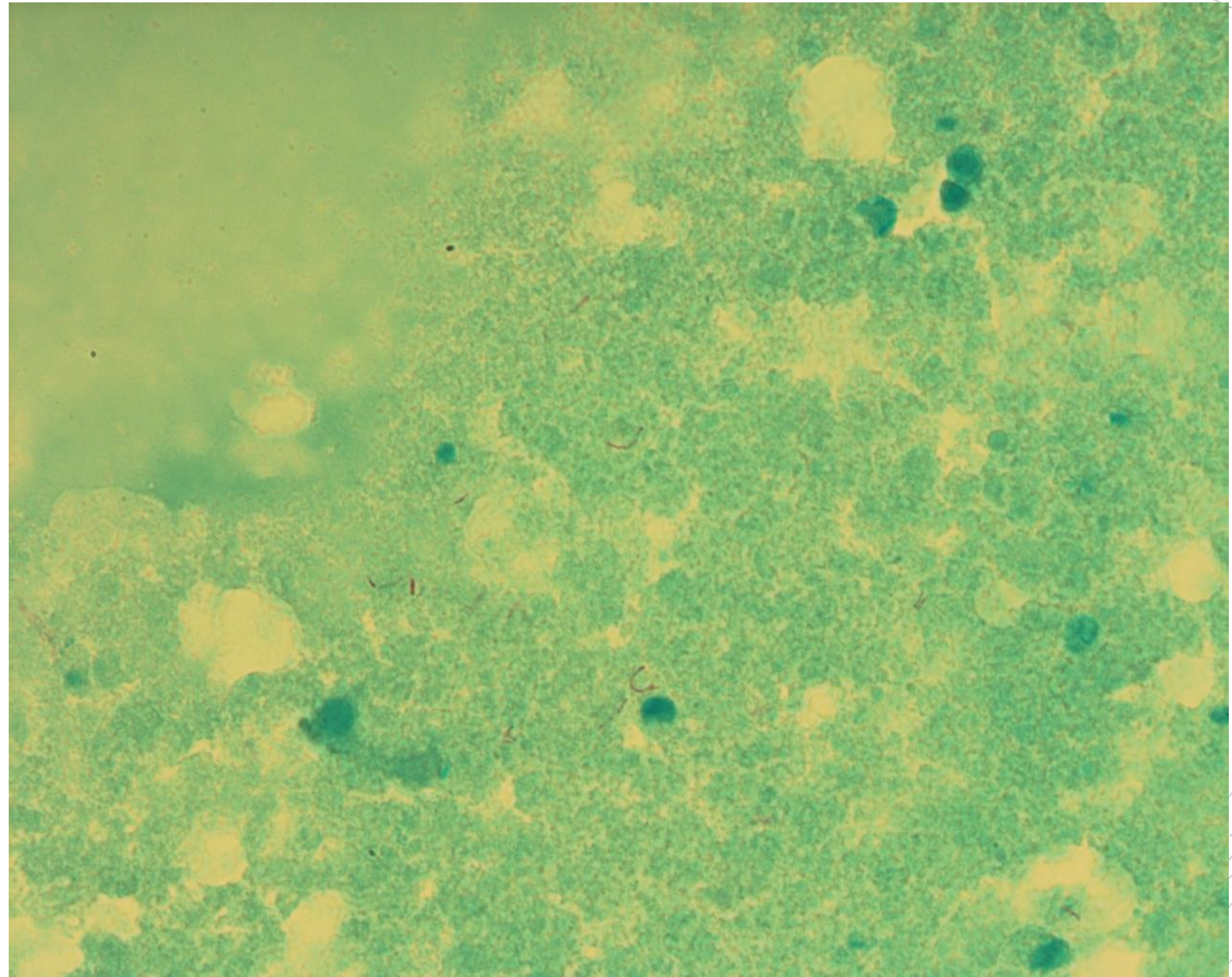
# *Mycobacterium abscessus*

**Specimen:** sputum

**Patient:** female, 15 years old

**Dg.:** cystic fibrosis

**Microscopy:** acidoresistant rods



Author: doc. MVDr. Otto Melter, PhD.





CHARLES UNIVERSITY  
Second Faculty of Medicine

Slide No. 12

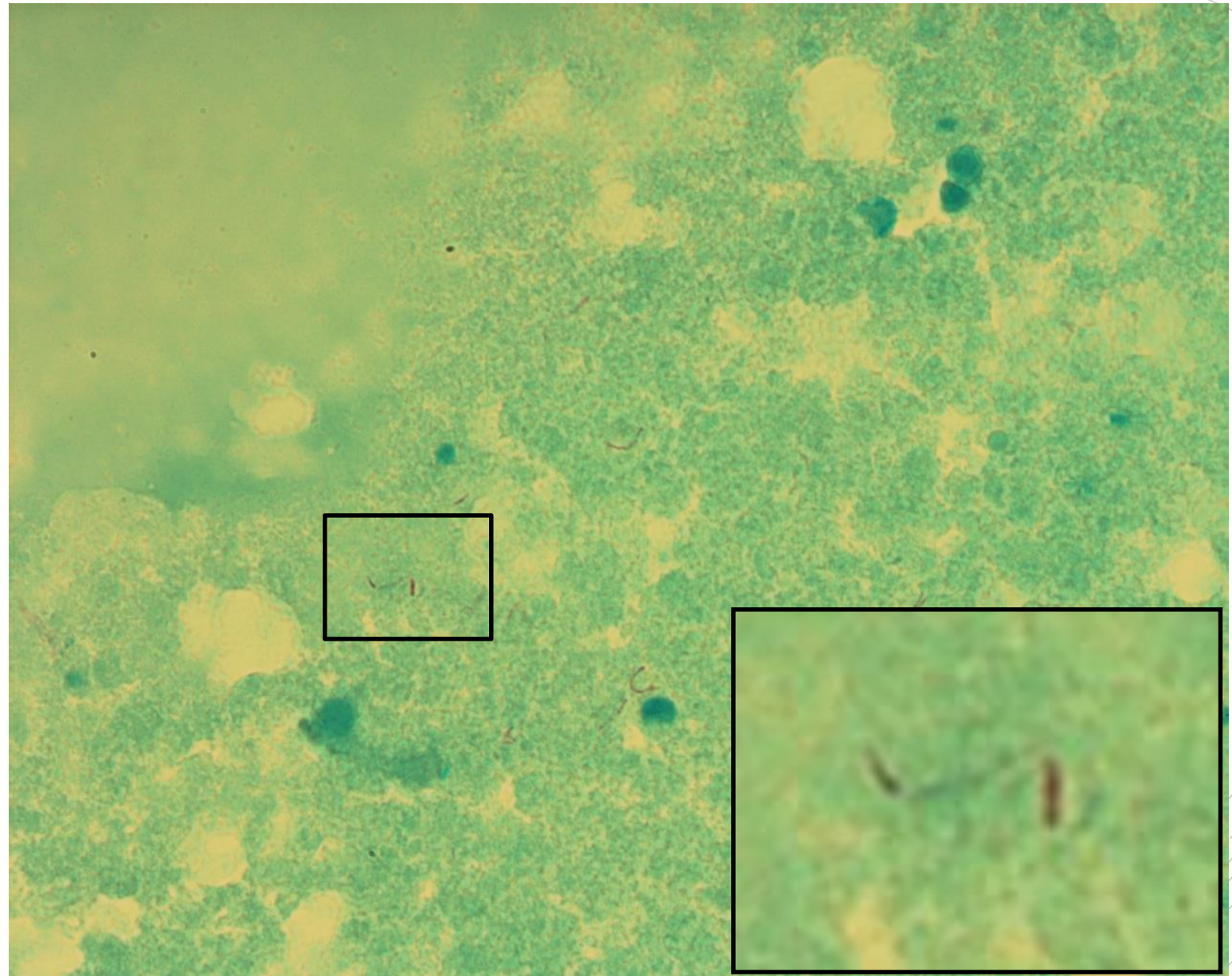
# *Mycobacterium abscessus*

**Specimen:** sputum

**Patient:** female, 15 years old

**Dg.:** cystic fibrosis

**Microscopy:** acidoresistant rods



Author: doc. MVDr. Otto Melter, PhD.



CHARLES UNIVERSITY  
Second Faculty of Medicine

Slide No. 13

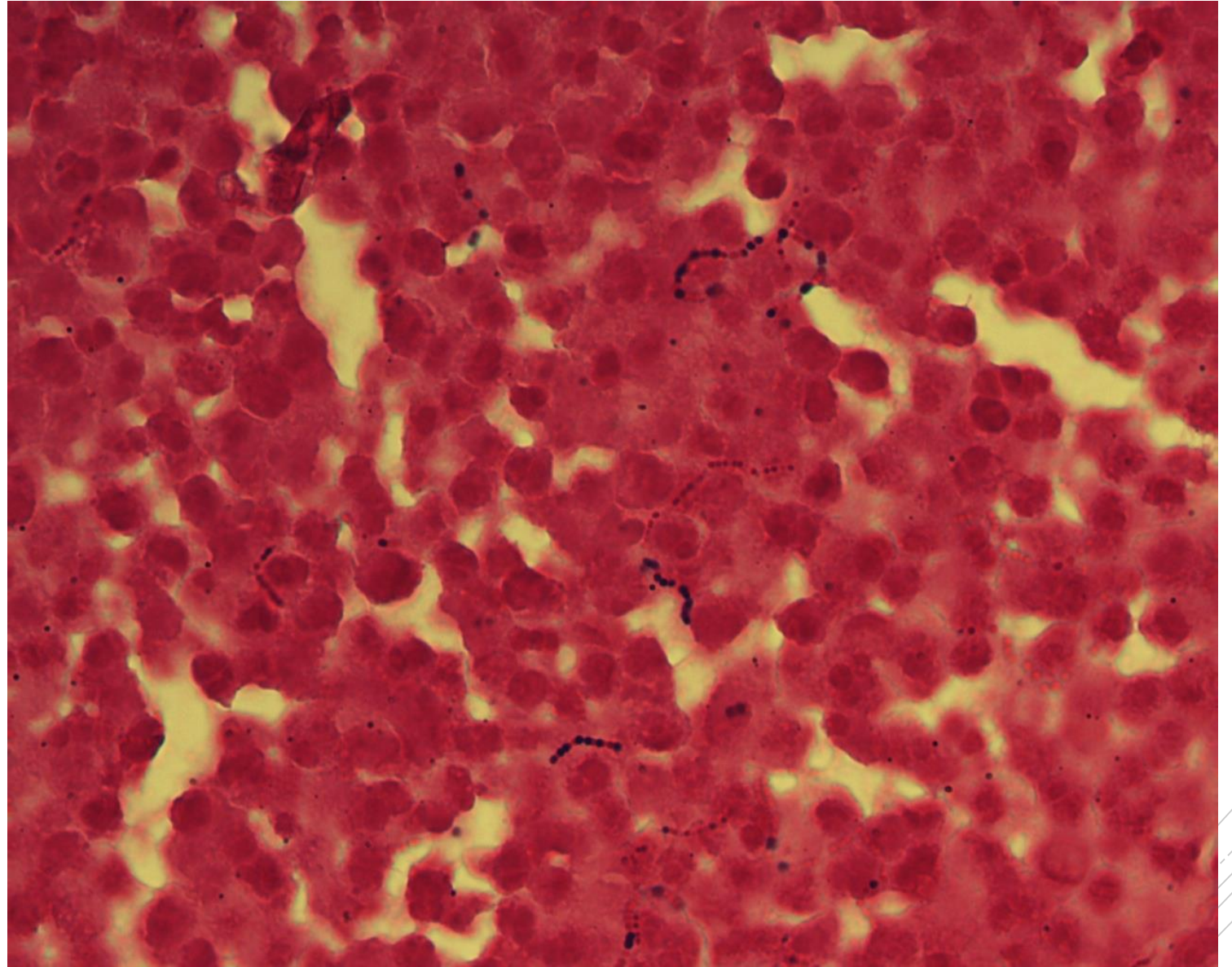
# *Streptococcus agalactiae*

**Specimen:** joint fluid

**Patient:** male, 47 years old

**Dg.:** infectious arthritis

**Microscopy:** Gram-positive cocci  
in chains



Author: MUDr. Lenka Tritová



CHARLES UNIVERSITY  
Second Faculty of Medicine

Slide No. 13

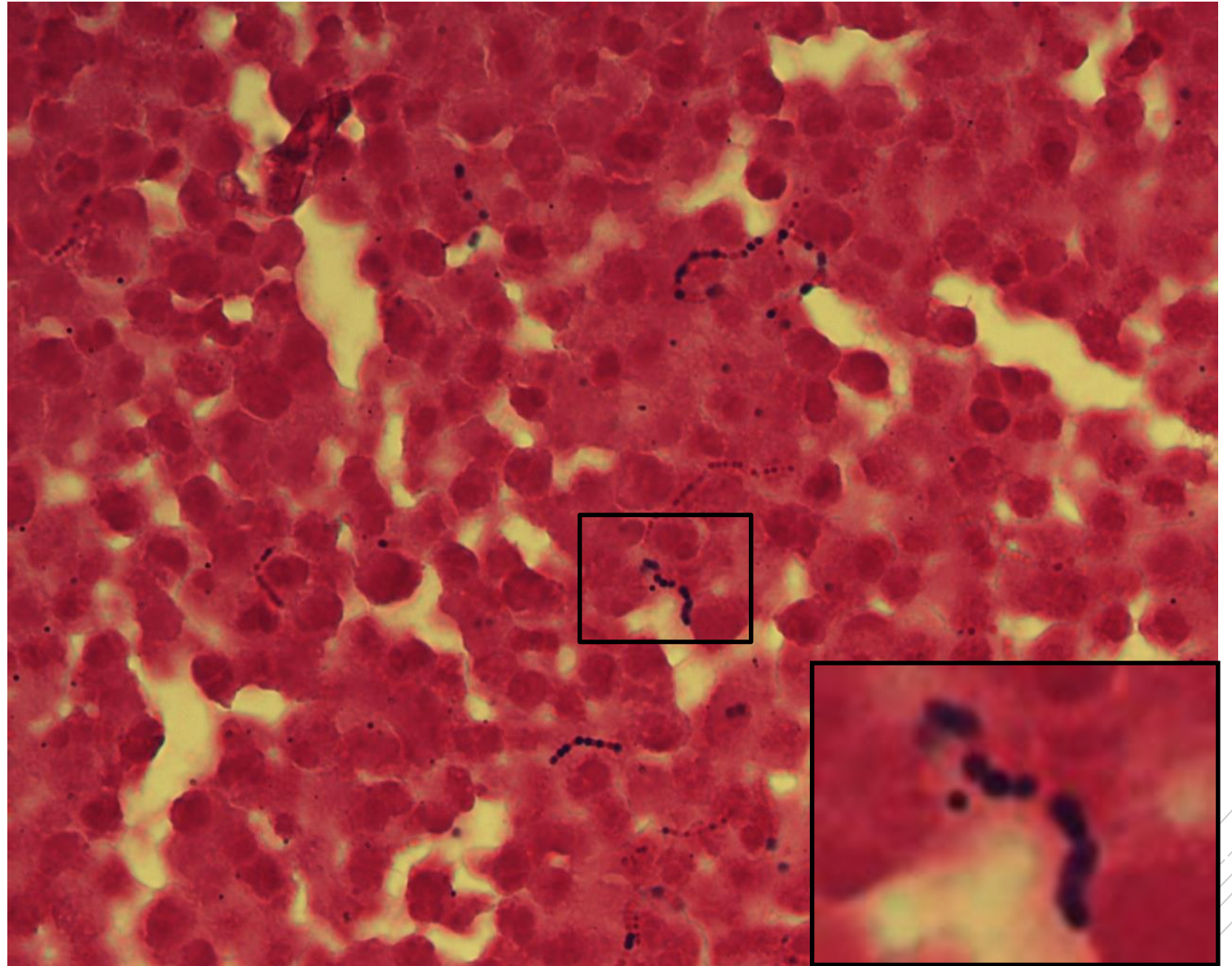
# *Streptococcus agalactiae*

**Specimen:** joint fluid

**Patient:** male, 47 years old

**Dg.:** infectious arthritis

**Microscopy:** Gram-positive cocci  
in chains



Author: MUDr. Lenka Tritová



CHARLES UNIVERSITY  
Second Faculty of Medicine

Slide No. 14

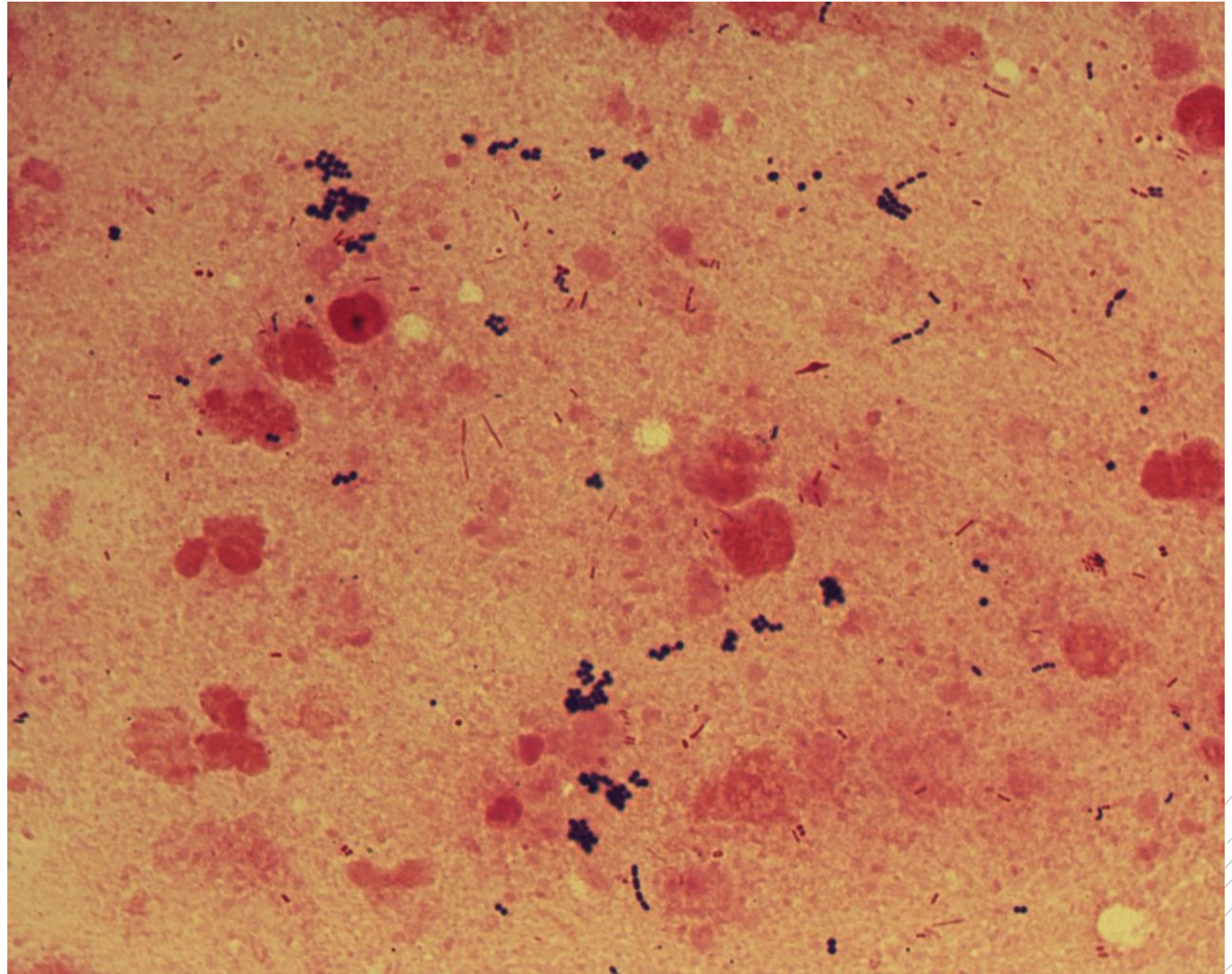
*Staphylococcus aureus,*  
*Pseudomonas aeruginosa*

**Specimen:** sputum

**Patient:** male, 17 years old

**Dg.:** cystic fibrosis

**Microscopy:** Gram-positive cocci  
in clusters, Gram-negative rods



Author: doc. MVDr. Otto Melter, PhD.



CHARLES UNIVERSITY  
Second Faculty of Medicine

Slide No. 14

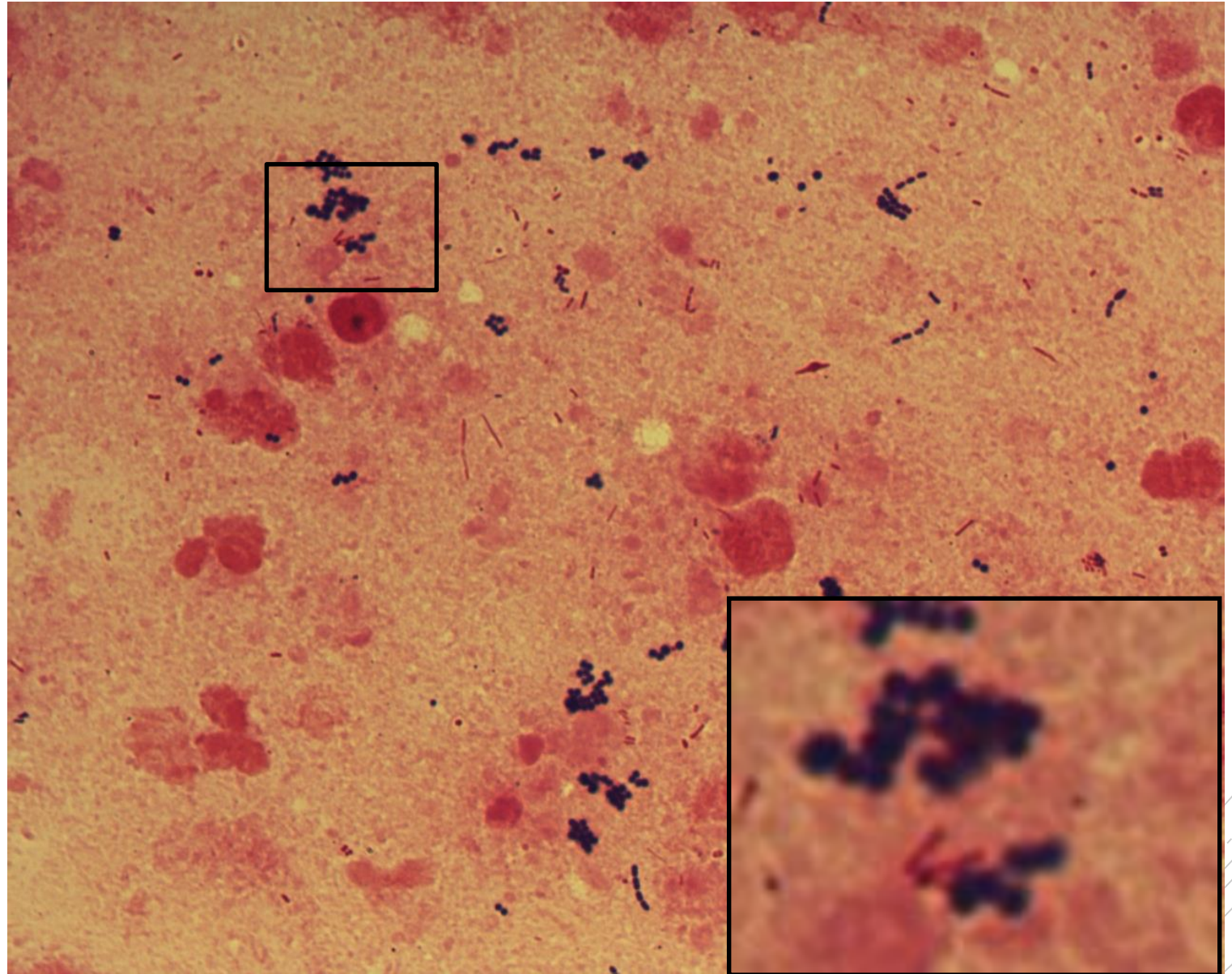
*Staphylococcus aureus,*  
*Pseudomonas aeruginosa*

**Specimen:** sputum

**Patient:** male, 17 years old

**Dg.:** cystic fibrosis

**Microscopy:** Gram-positive cocci in clusters, Gram-negative rods



Author: doc. MVDr. Otto Melter, PhD.



CHARLES UNIVERSITY  
Second Faculty of Medicine

Slide No. 15

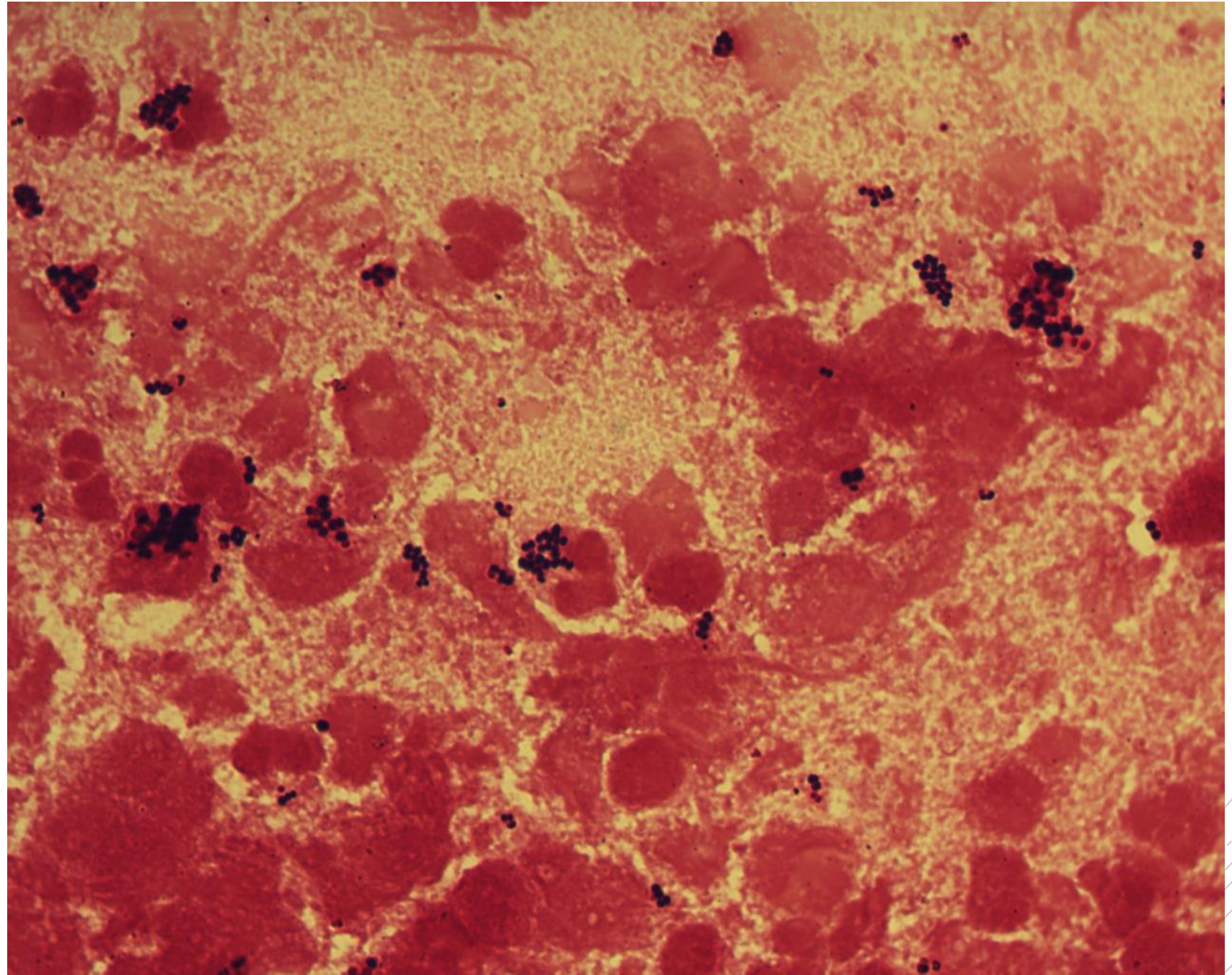
# *Staphylococcus aureus*

**Specimen:** sputum

**Patient:** female, 21 years old

**Dg.:** cystic fibrosis

**Microscopy:** Gram-positive cocci  
in clusters



Author: doc. MVDr. Otto Melter, PhD.



CHARLES UNIVERSITY  
Second Faculty of Medicine

Slide No. 15

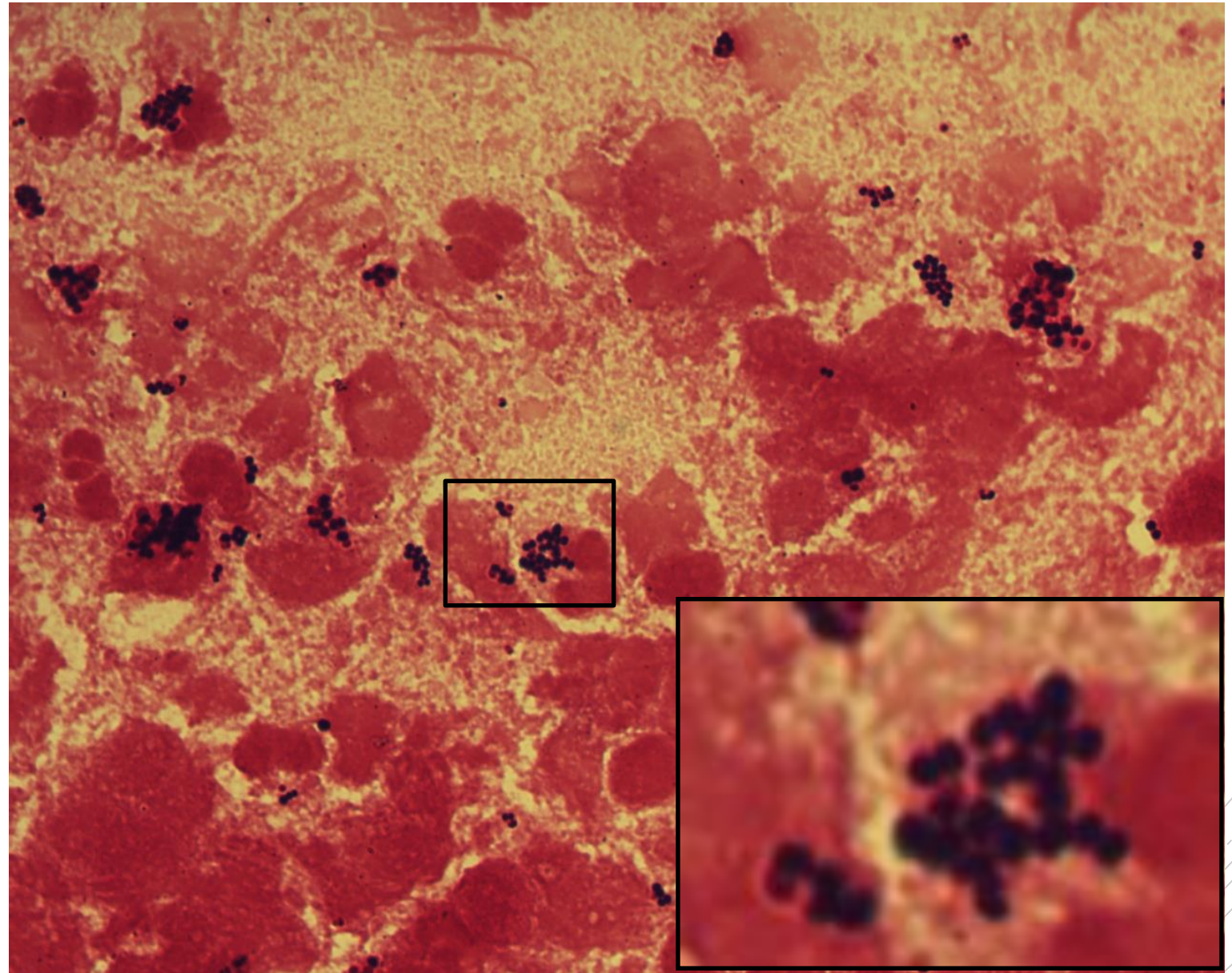
# *Staphylococcus aureus*

**Specimen:** sputum

**Patient:** female, 21 years old

**Dg.:** cystic fibrosis

**Microscopy:** Gram-positive cocci  
in clusters



Author: doc. MVDr. Otto Melter, PhD.



CHARLES UNIVERSITY  
Second Faculty of Medicine

Slide No. 16

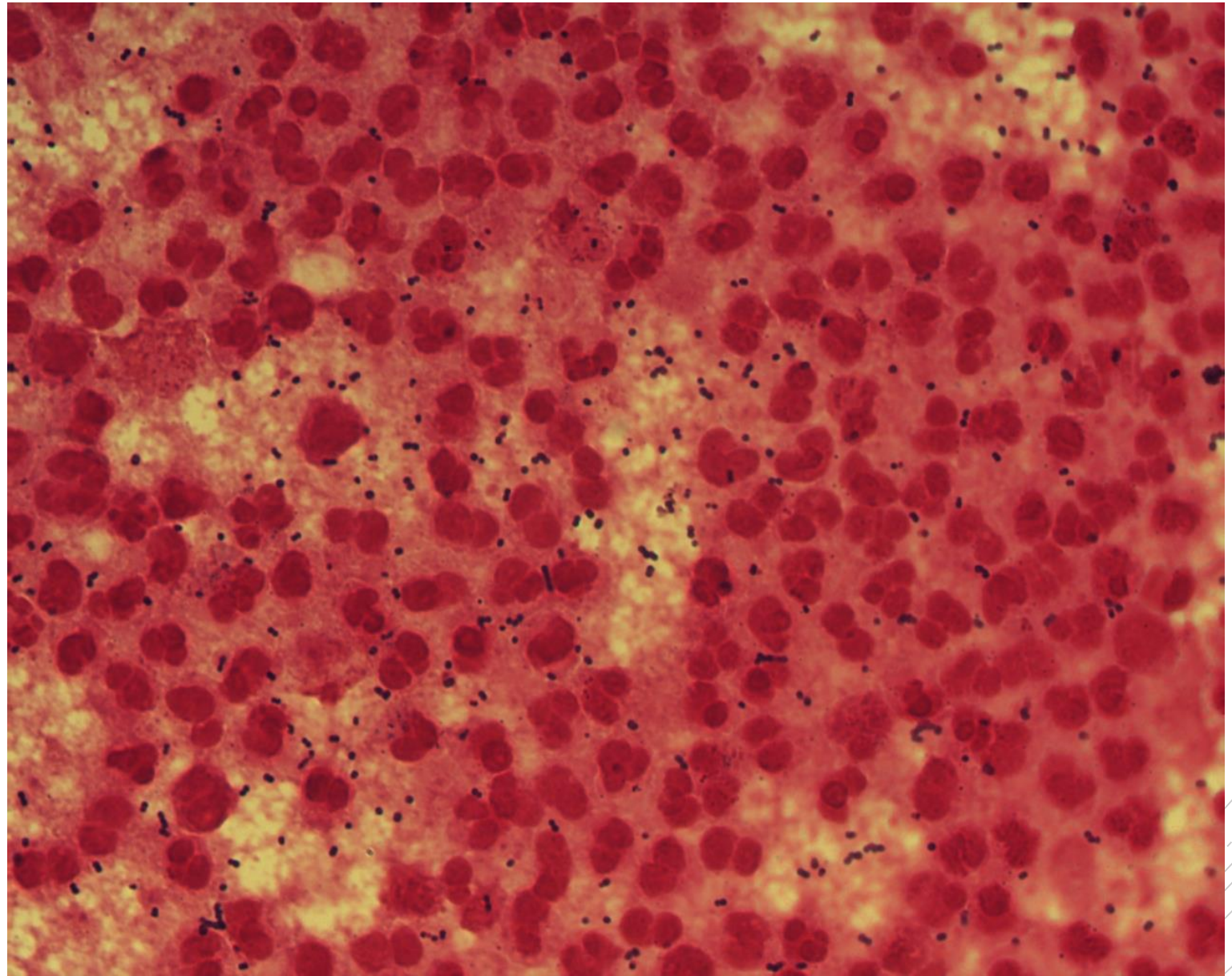
*Streptococcus  
beta-haemolyticus  
group G*

**Specimen:** knee joint fluid

**Patient:** male, 81 years old

**Dg.:** prosthesis infection

**Microscopy:** Gram-positive diplococci



Author: MUDr. Anastázia Ešnerová





CHARLES UNIVERSITY  
Second Faculty of Medicine

Slide No. 16

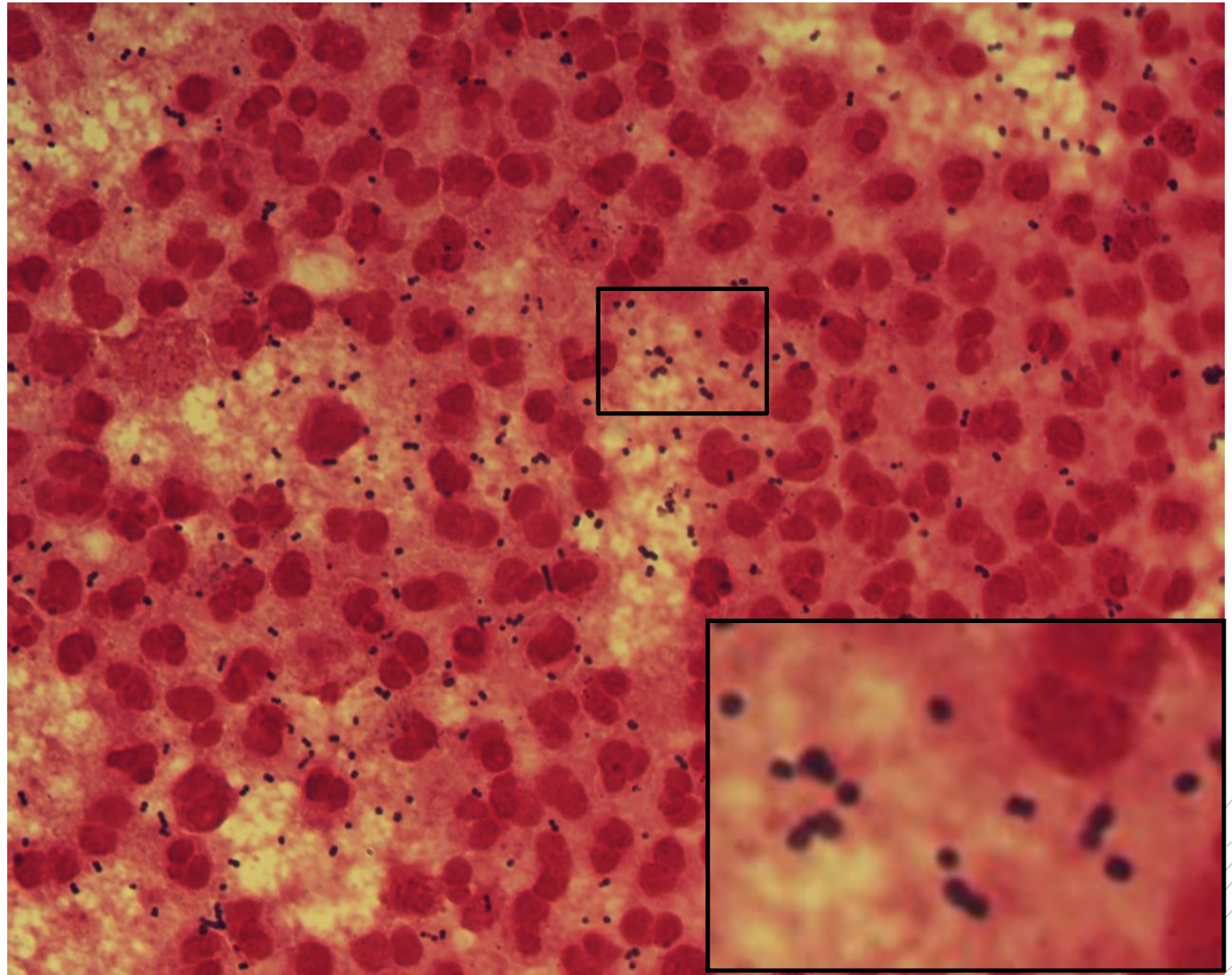
*Streptococcus  
beta-haemolyticus  
group G*

**Specimen:** knee joint fluid

**Patient:** male, 81 years old

**Dg.:** prosthesis infection

**Microscopy:** Gram-positive diplococci



Author: MUDr. Anastázia Ešnerová



CHARLES UNIVERSITY  
Second Faculty of Medicine

Slide No. 17

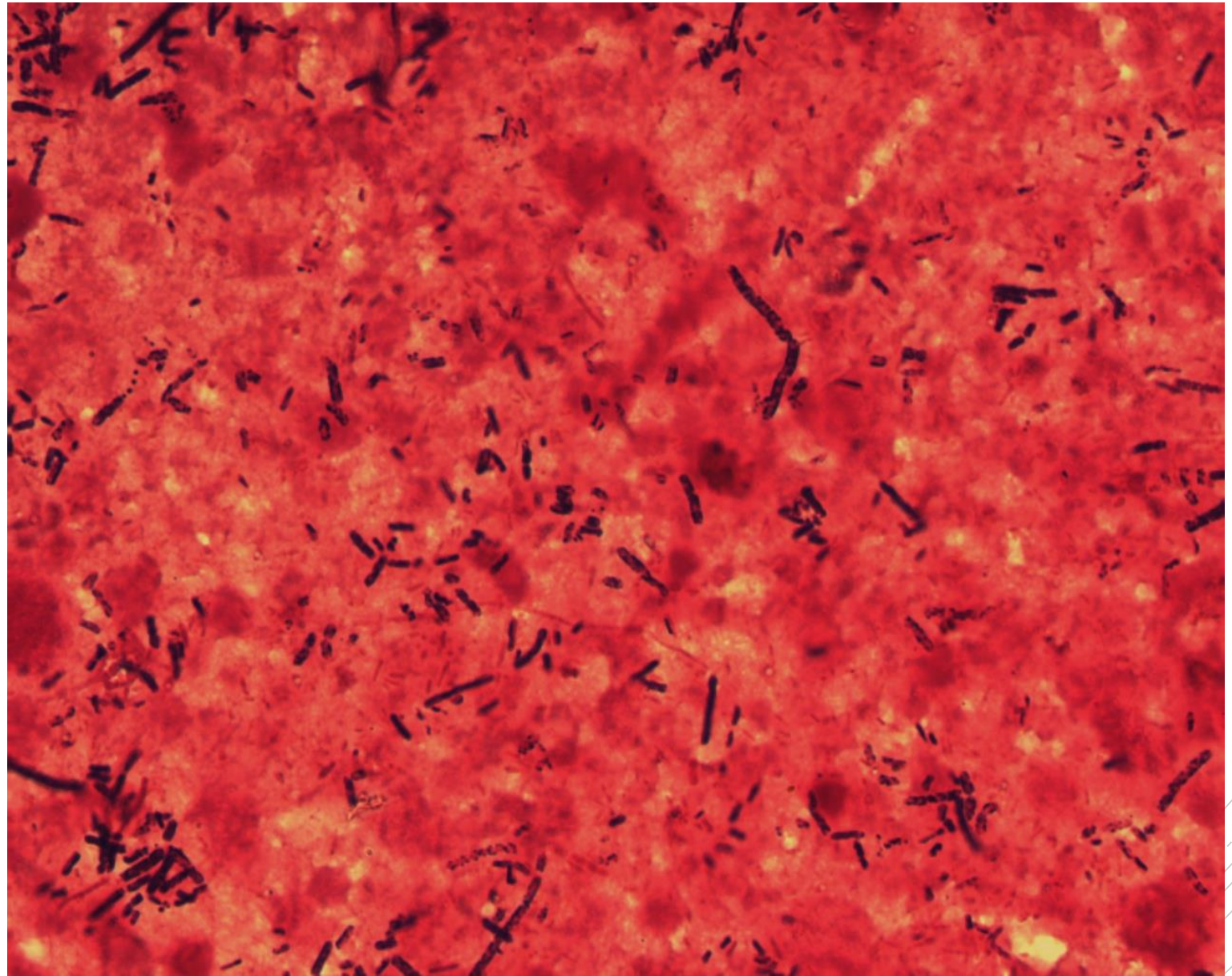
# *Clostridium perfringens*

**Specimen:** liver puncture fluid

**Patient:** female, 80 years old

**Dg.:** liver abscess

**Microscopy:** Gram-positive  
spore-forming rods



Author: MUDr. Alena Pířová

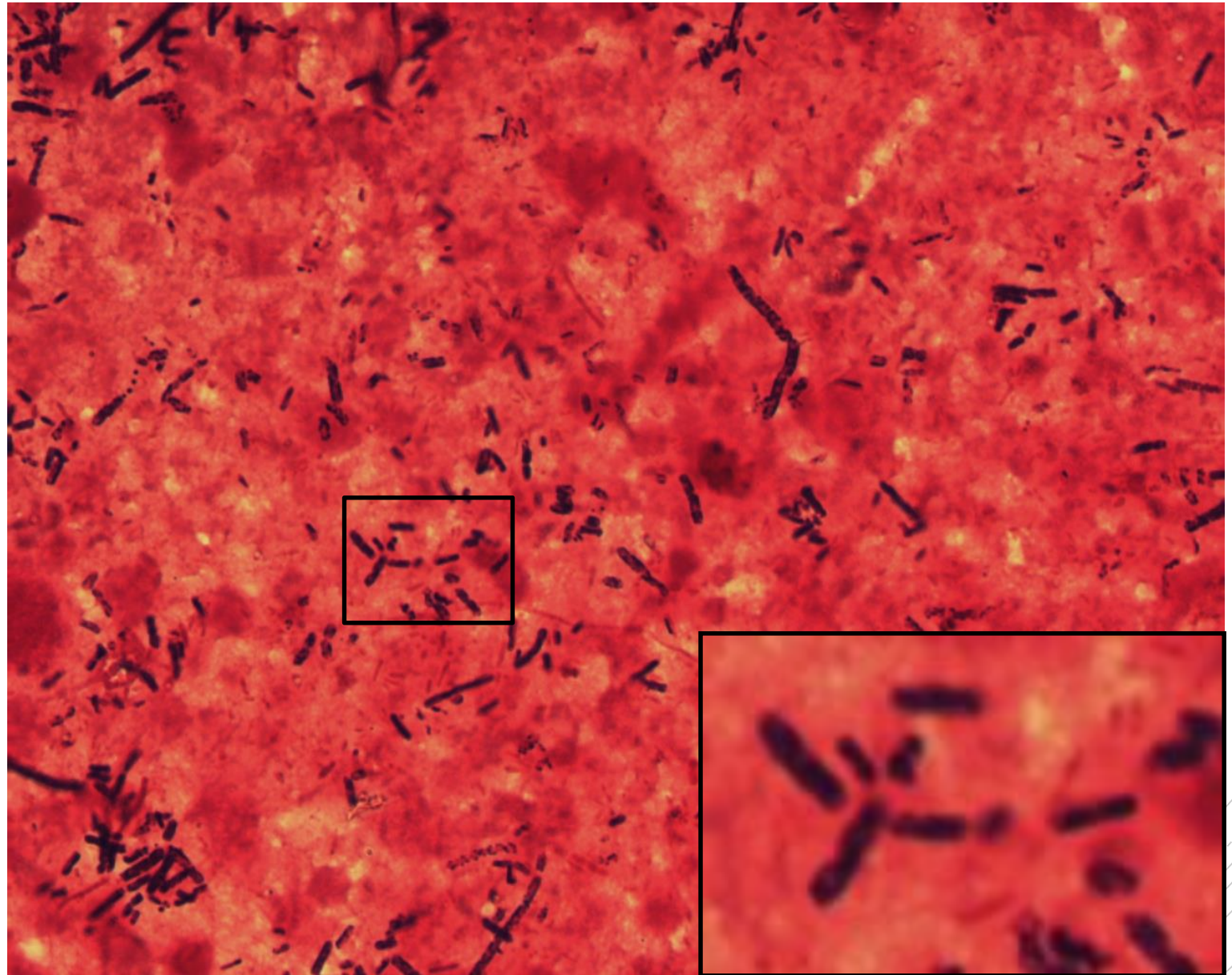


CHARLES UNIVERSITY  
Second Faculty of Medicine

Slide No. 17

# *Clostridium perfringens*

**Specimen:** liver puncture fluid  
**Patient:** female, 80 years old  
**Dg.:** liver abscess  
**Microscopy:** Gram-positive  
spore-forming rods



Author: MUDr. Alena Pířová



CHARLES UNIVERSITY  
Second Faculty of Medicine

Slide No. 18

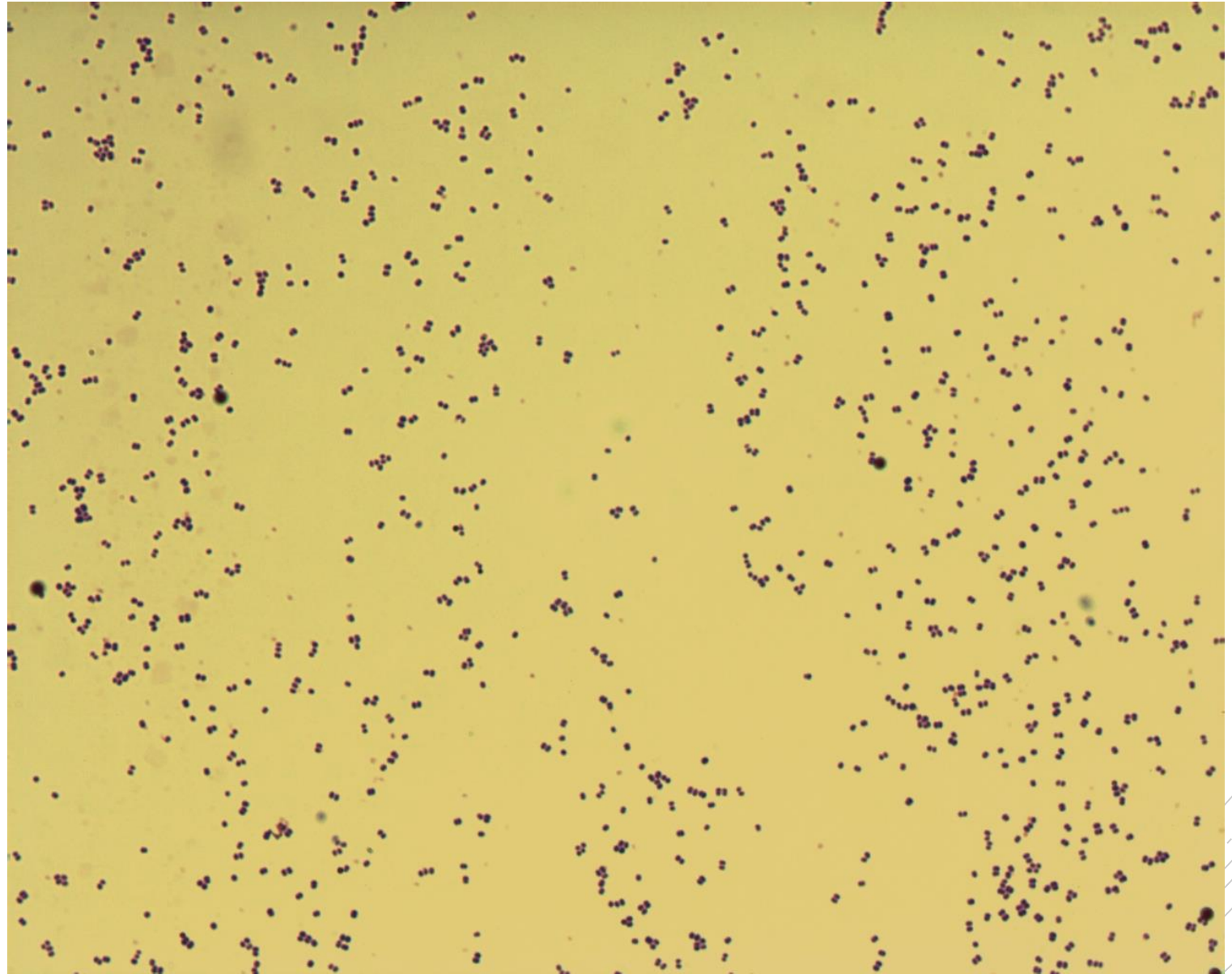
# *Staphylococcus epidermidis*

**Specimen:** culture – heart valve

**Patient:** male, 52 years old

**Dg.:** endocarditis

**Microscopy:** Gram-positive cocci



Authors: Markéta Šolarová, Hana Nekvasilová



CHARLES UNIVERSITY  
Second Faculty of Medicine

Slide No. 18


# *Staphylococcus epidermidis*

**Specimen:** culture – heart valve

**Patient:** male, 52 years old

**Dg.:** endocarditis

**Microscopy:** Gram-positive cocci



Authors: Markéta Šolarová, Hana Nekvasilová



CHARLES UNIVERSITY  
Second Faculty of Medicine

Slide No. 19

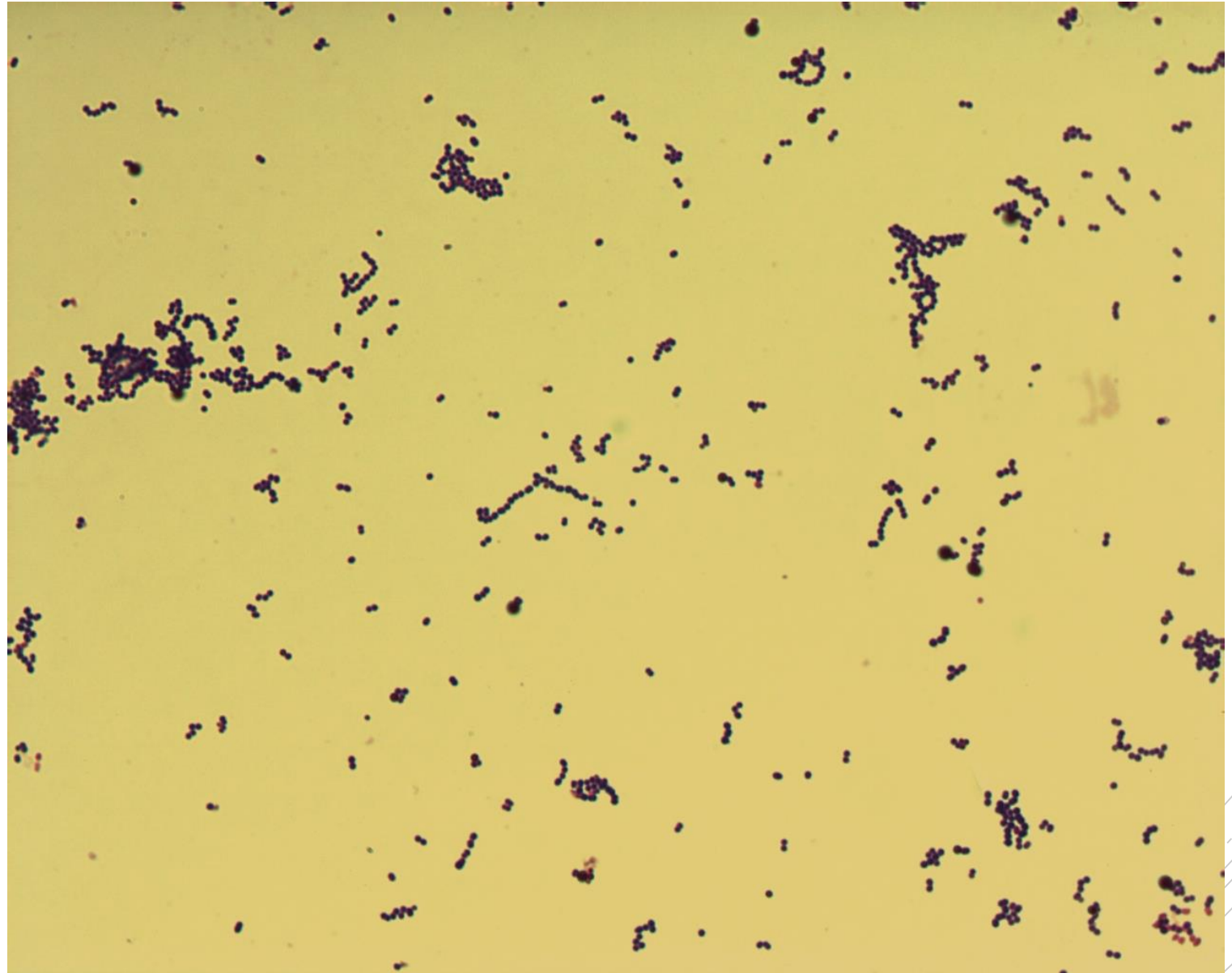
# *Streptococcus pyogenes*

**Specimen:** culture – tissue biopsy

**Patient:** male, 40 years old

**Dg.:** necrotizing fasciitis

**Microscopy:** Gram-positive cocci  
in chains



Authors: Markéta Šolarová, Hana Nekvasilová



CHARLES UNIVERSITY  
Second Faculty of Medicine

Slide No. 19

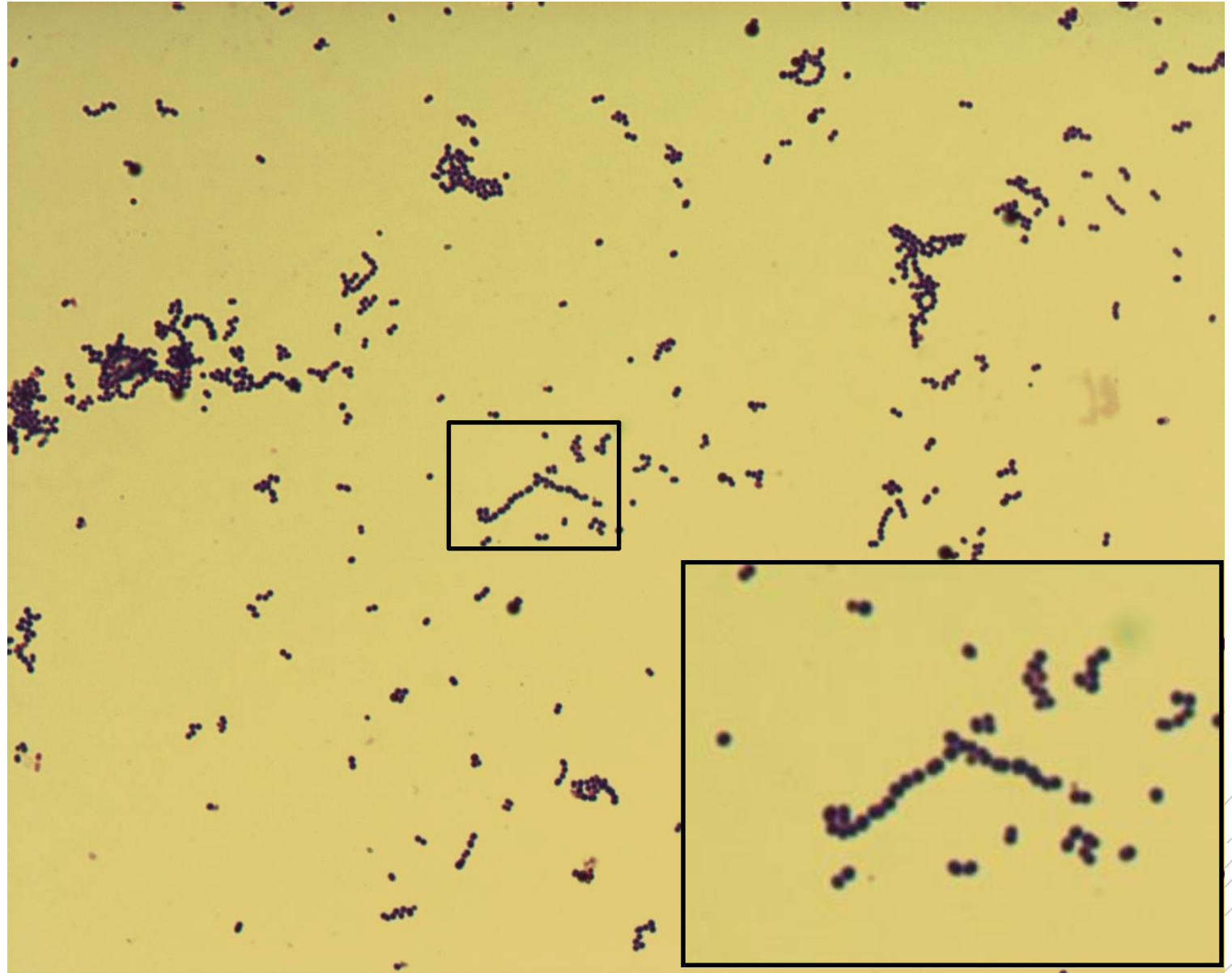
# *Streptococcus pyogenes*

**Specimen:** culture – tissue biopsy

**Patient:** male, 40 years old

**Dg.:** necrotizing fasciitis

**Microscopy:** Gram-positive cocci  
in chains



Authors: Markéta Šolarová, Hana Nekvasilová



CHARLES UNIVERSITY  
Second Faculty of Medicine

Slide No. 20

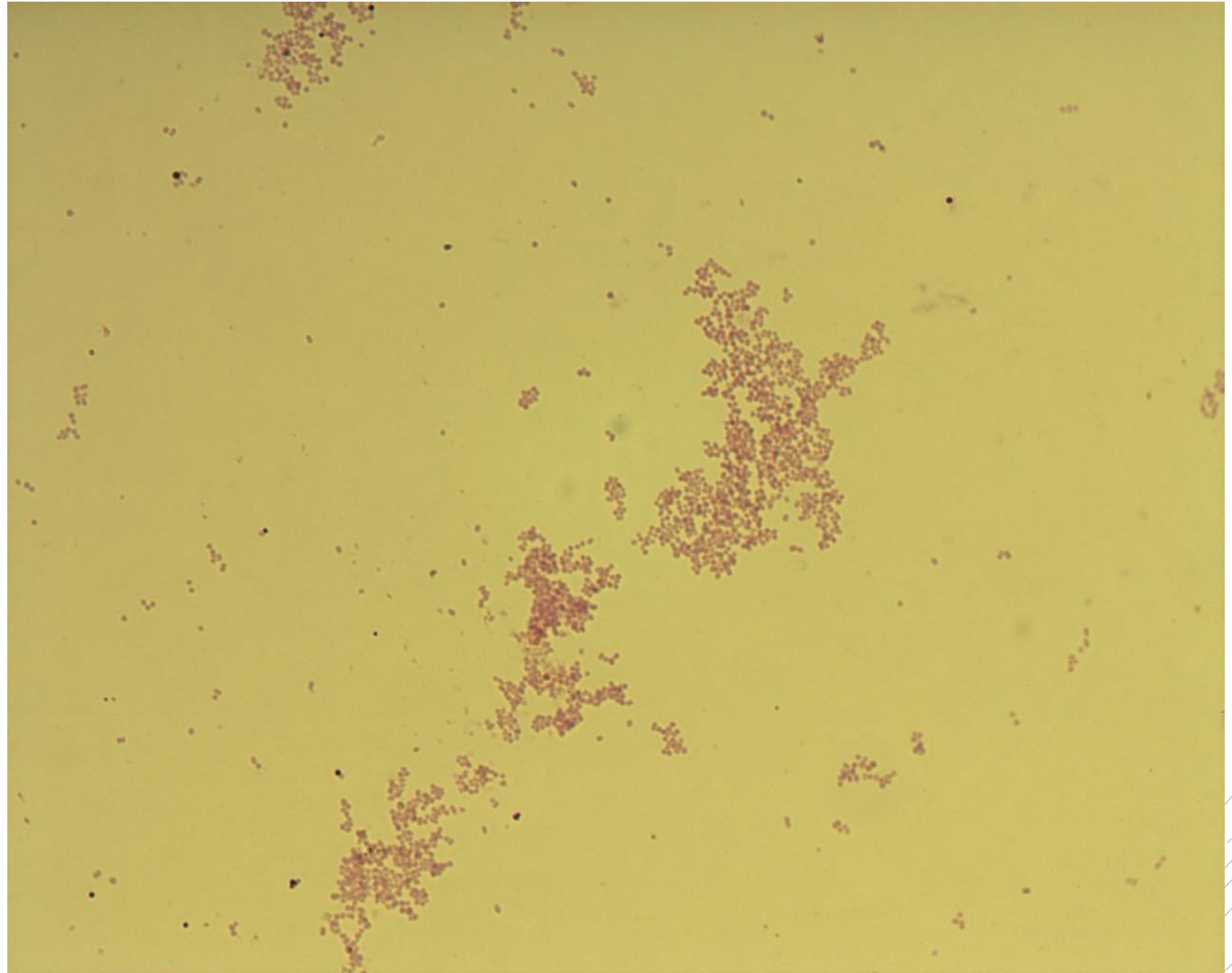
# *Branhamella catarrhalis*

**Specimen:** culture – external ear swab

**Patient:** female, 7 years old

**Dg.:** acute otitis media

**Microscopy:** Gram-negative cocci  
in couples, quartets and clusters



Authors: Markéta Šolarová, Hana Nekvasilová





CHARLES UNIVERSITY  
Second Faculty of Medicine

Slide No. 20

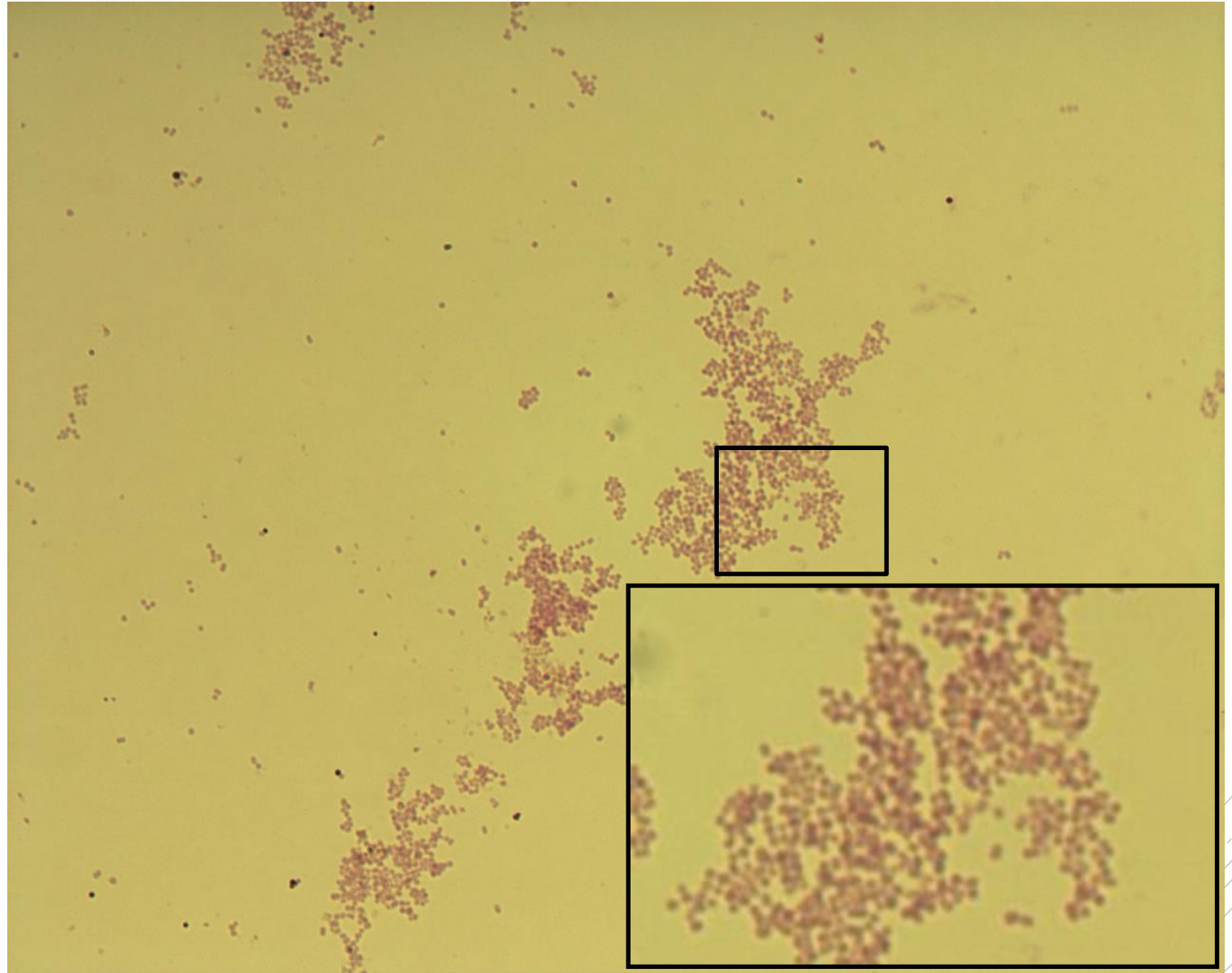
# *Branhamella catarrhalis*

**Specimen:** culture – external ear swab

**Patient:** female, 7 years old

**Dg.:** acute otitis media

**Microscopy:** Gram-negative cocci  
in couples, quartets and clusters



Authors: Markéta Šolarová, Hana Nekvasilová

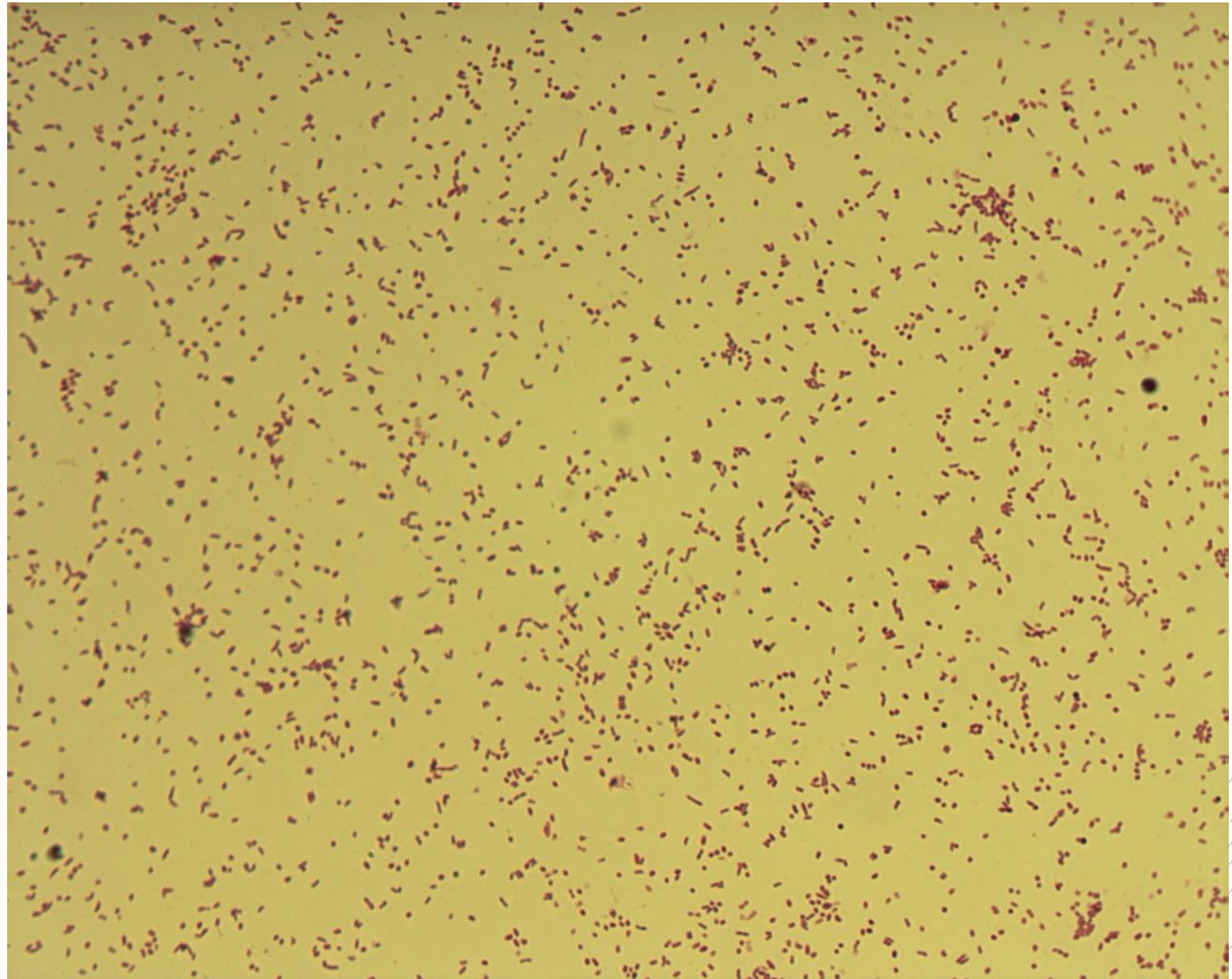


CHARLES UNIVERSITY  
Second Faculty of Medicine

Slide No. 21

# *Haemophilus influenzae type b*

**Specimen:** culture - CSF  
**Patient:** male, 8 years old  
**Dg.:** purulent meningitis  
**Microscopy:** Gram-negative  
coccobacilli



Authors: Markéta Šolarová, Hana Nekvasilová

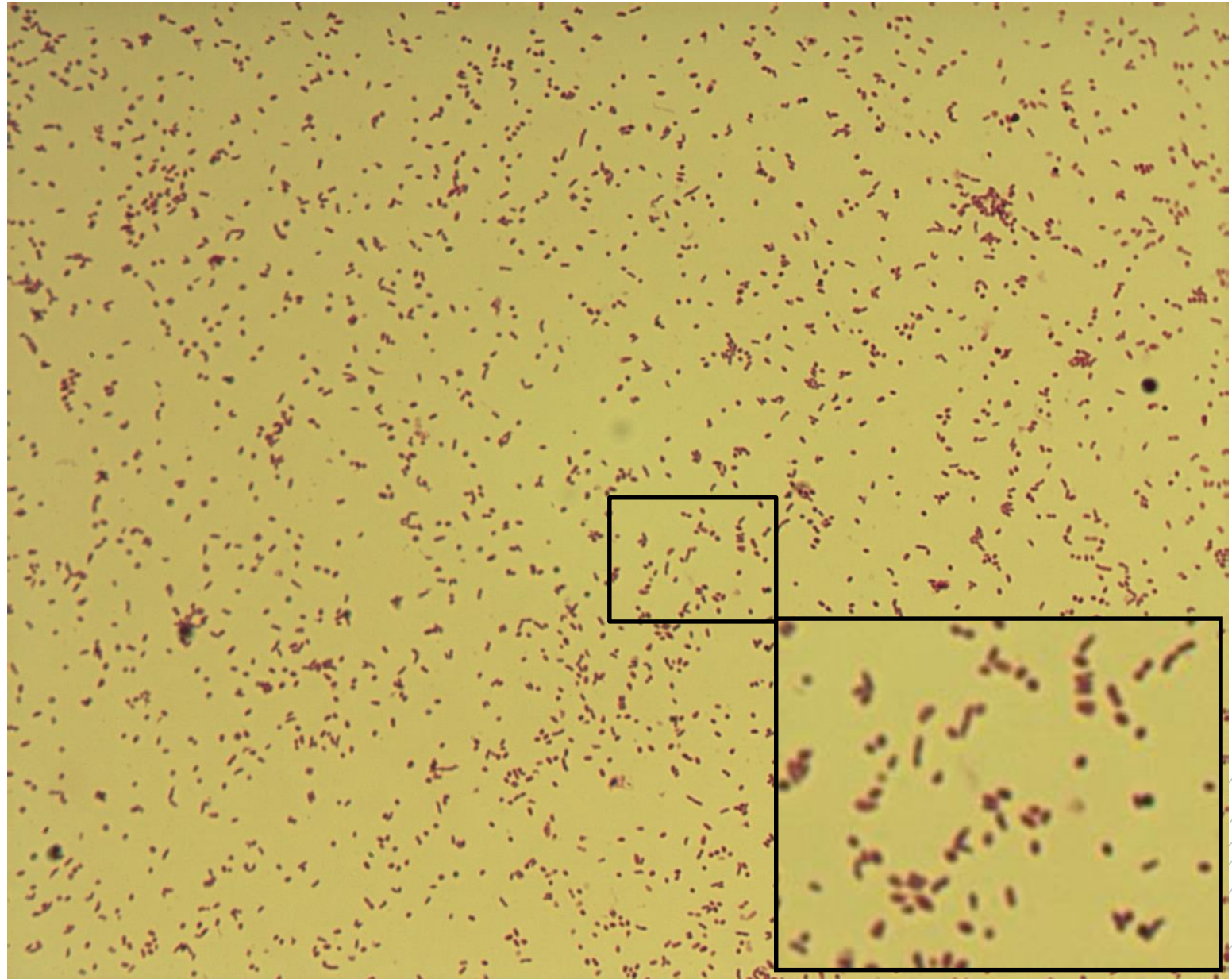


CHARLES UNIVERSITY  
Second Faculty of Medicine

Slide No. 21

# *Haemophilus influenzae* type b

**Specimen:** culture - CSF  
**Patient:** male, 8 years old  
**Dg.:** purulent meningitis  
**Microscopy:** Gram-negative  
coccobacilli



Authors: Markéta Šolarová, Hana Nekvasilová



CHARLES UNIVERSITY  
Second Faculty of Medicine

Slide No. 22

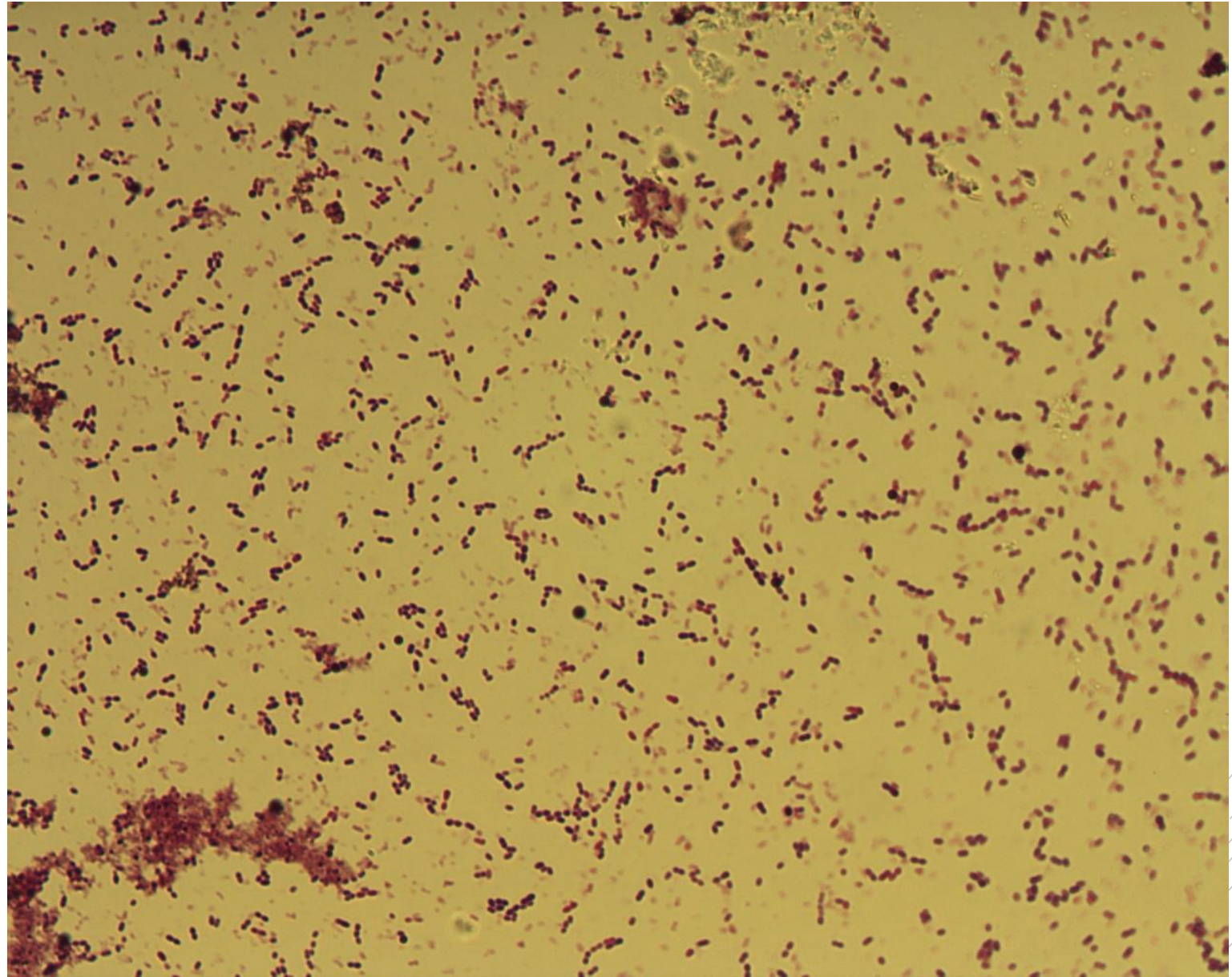
# *Streptococcus pneumoniae*

**Specimen:** sputum

**Patient:** female, 75 years old

**Dg.:** community pneumonia

**Microscopy:** Gram-positive diplococci



Authors: Markéta Šolarová, Hana Nekvasilová



CHARLES UNIVERSITY  
Second Faculty of Medicine

Slide No. 22

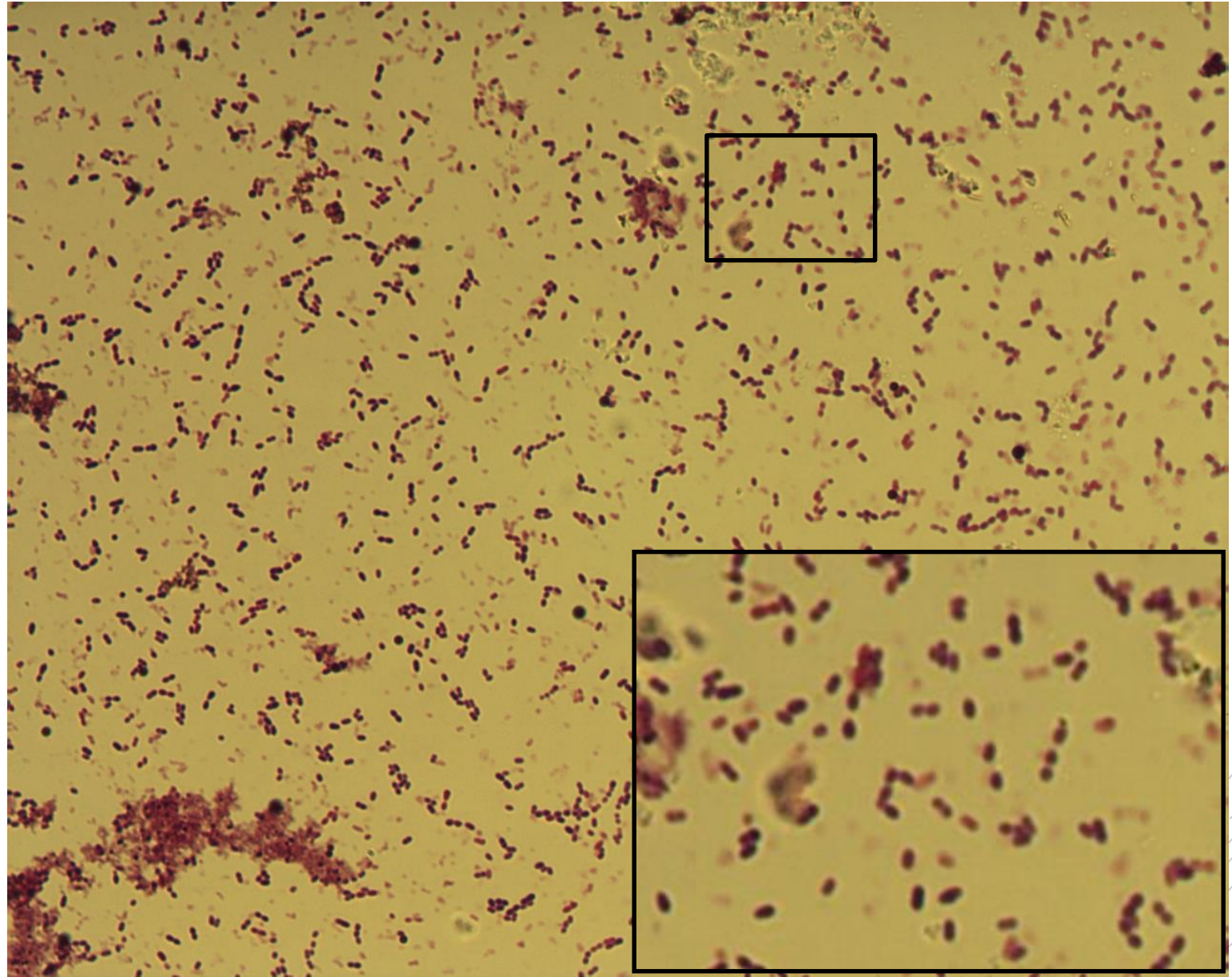
# *Streptococcus pneumoniae*

**Specimen:** sputum

**Patient:** female 75 years old

**Dg.:** community pneumonia

**Microscopy:** Gram-positive diplococci



Authors: Markéta Šolarová, Hana Nekvasilová



CHARLES UNIVERSITY  
Second Faculty of Medicine

Slide No. 23

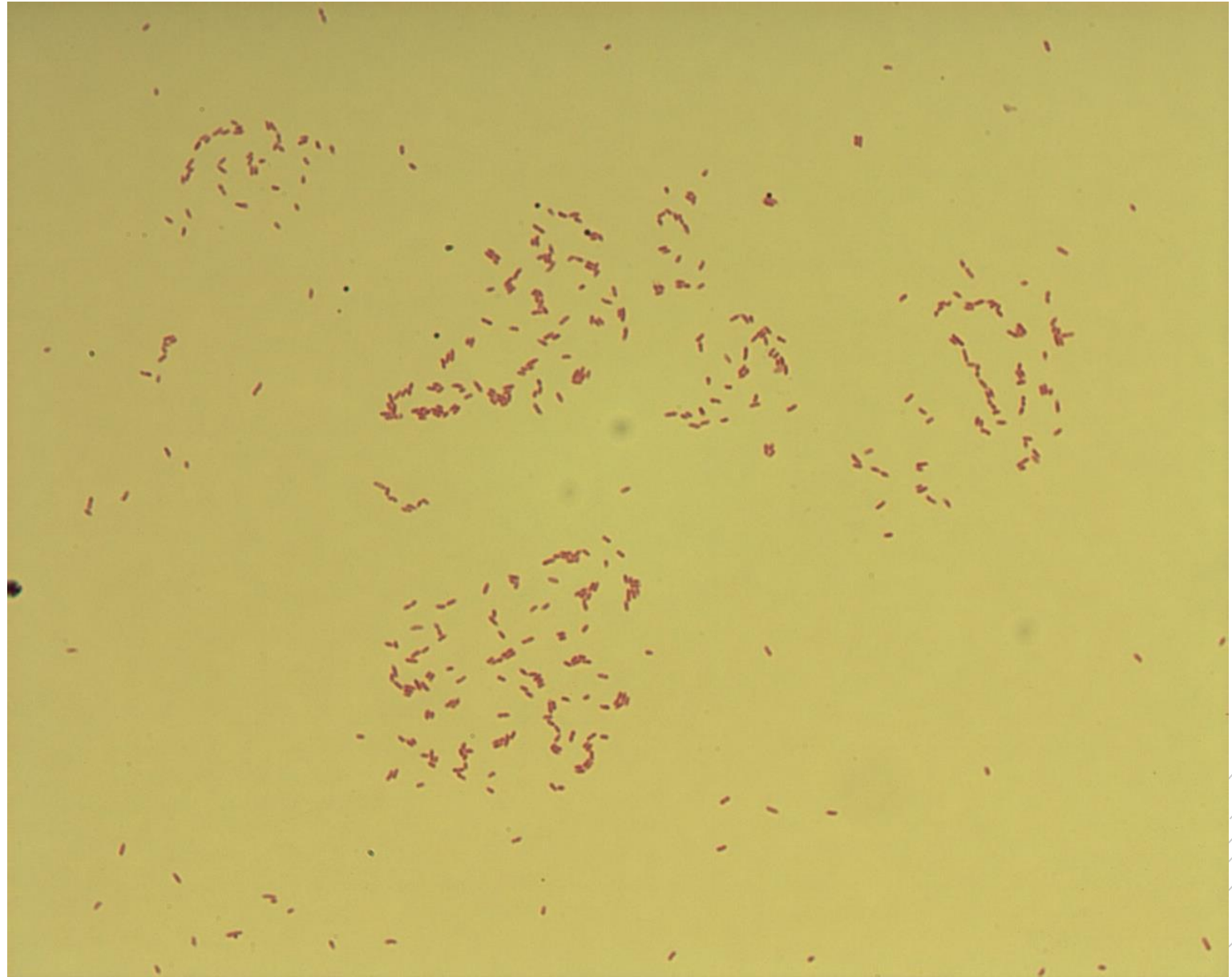
# *Pseudomonas aeruginosa*

**Specimen:** culture – tissue

**Patient:** female, 2 years old

**Dg.:** ecthyma gangrenosum

**Microscopy:** thin Gram-negative rods



Authors: Markéta Šolarová, Hana Nekvasilová



CHARLES UNIVERSITY  
Second Faculty of Medicine

Slide No. 23

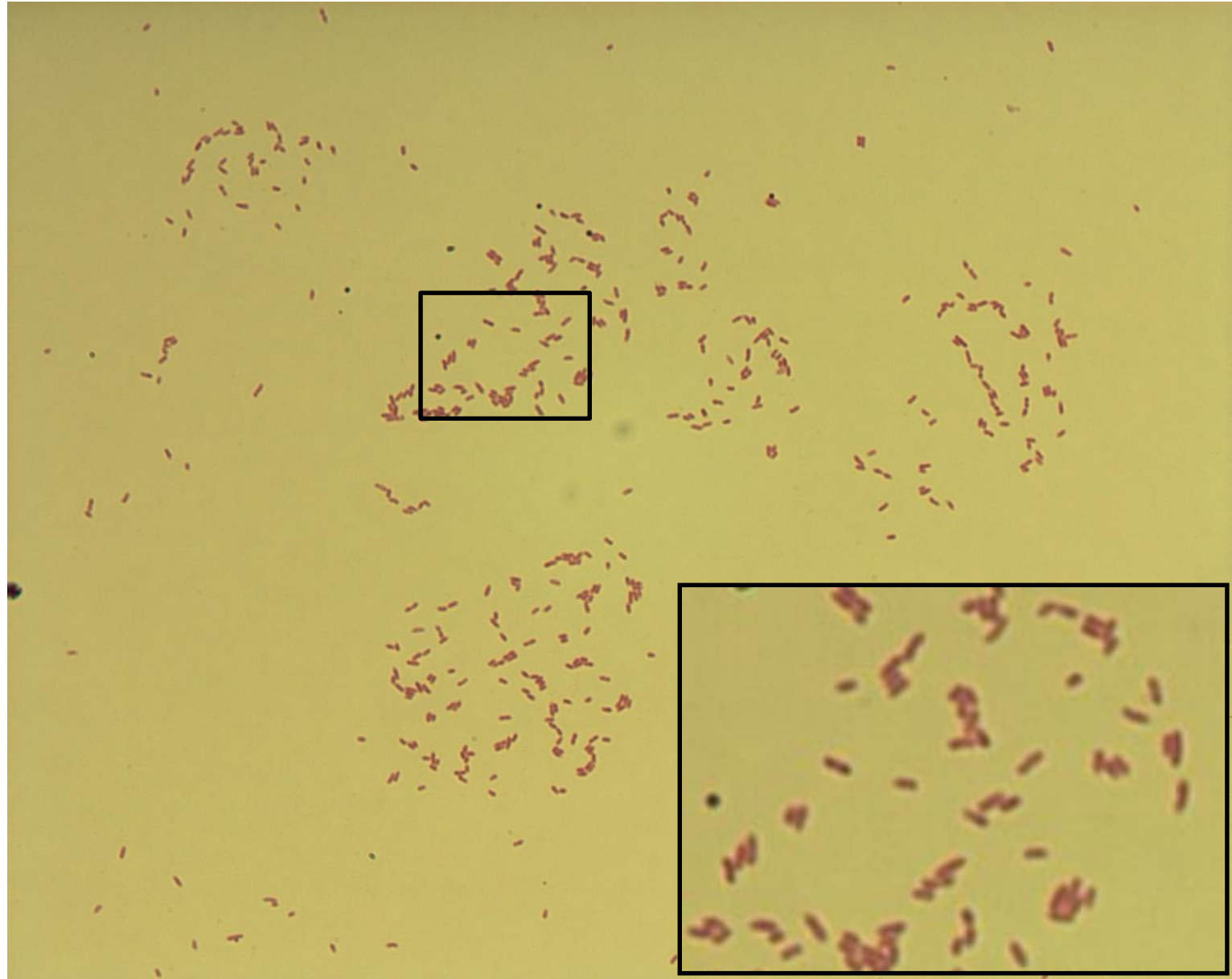
# *Pseudomonas aeruginosa*

**Specimen:** culture - tissue

**Patient:** female, 2 years old

**Dg.:** ecthyma gangrenosum

**Microscopy:** thin Gram-negative rods



Authors: Markéta Šolarová, Hana Nekvasilová



CHARLES UNIVERSITY  
Second Faculty of Medicine

Slide No. 24

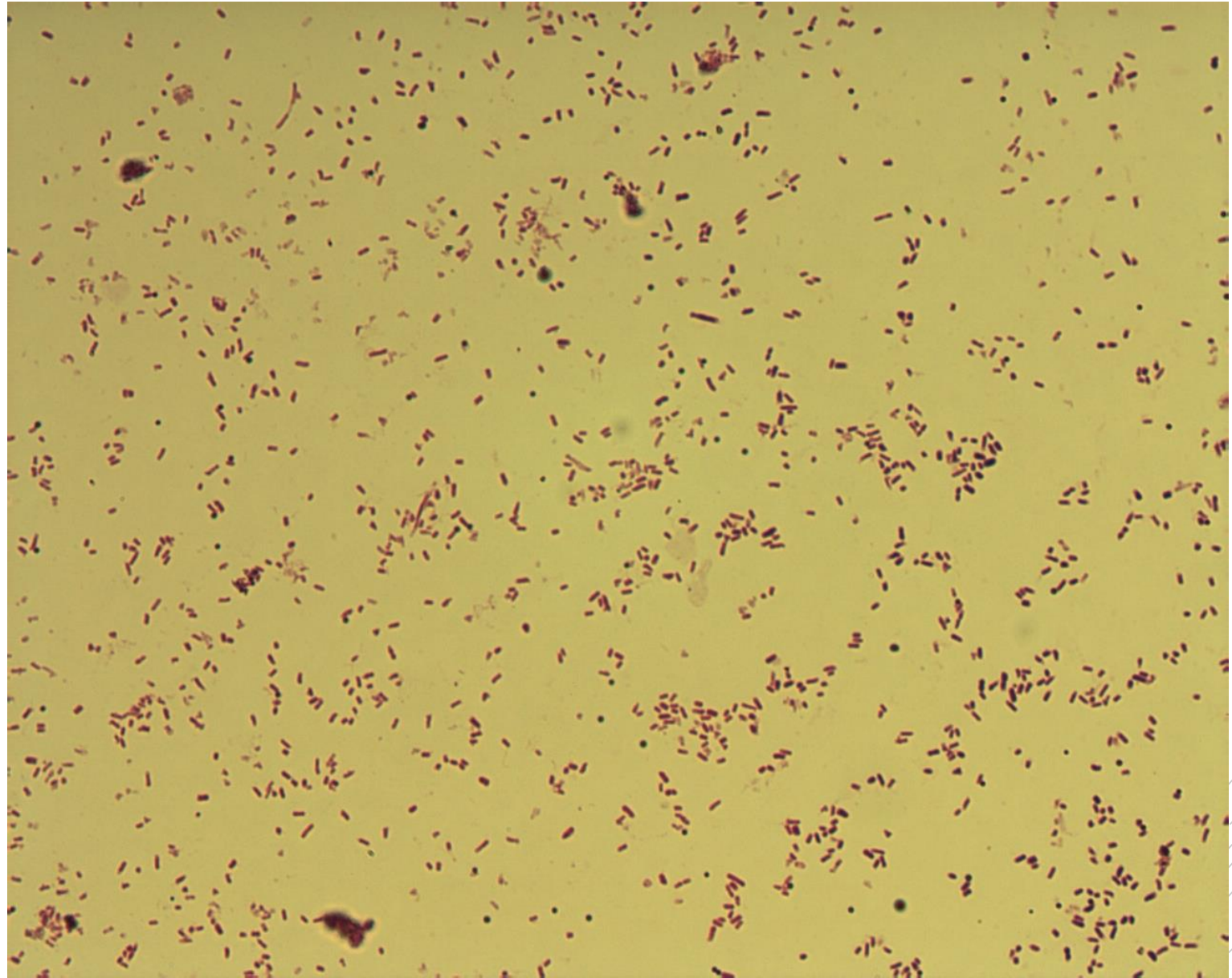
# *Escherichia coli*

**Specimen:** culture - urine

**Patient:** female, 55 years old

**Dg.:** urinary tract infection

**Microscopy:** Gram-negative rods



Authors: Markéta Šolarová, Hana Nekvasilová





CHARLES UNIVERSITY  
Second Faculty of Medicine

Slide No. 24


# *Escherichia coli*

**Specimen:** culture - urine

**Patient:** female, 55 years old

**Dg.:** urinary tract infection

**Microscopy:** Gram-negative rods



Authors: Markéta Šolarová, Hana Nekvasilová



CHARLES UNIVERSITY  
Second Faculty of Medicine

Slide No. 25

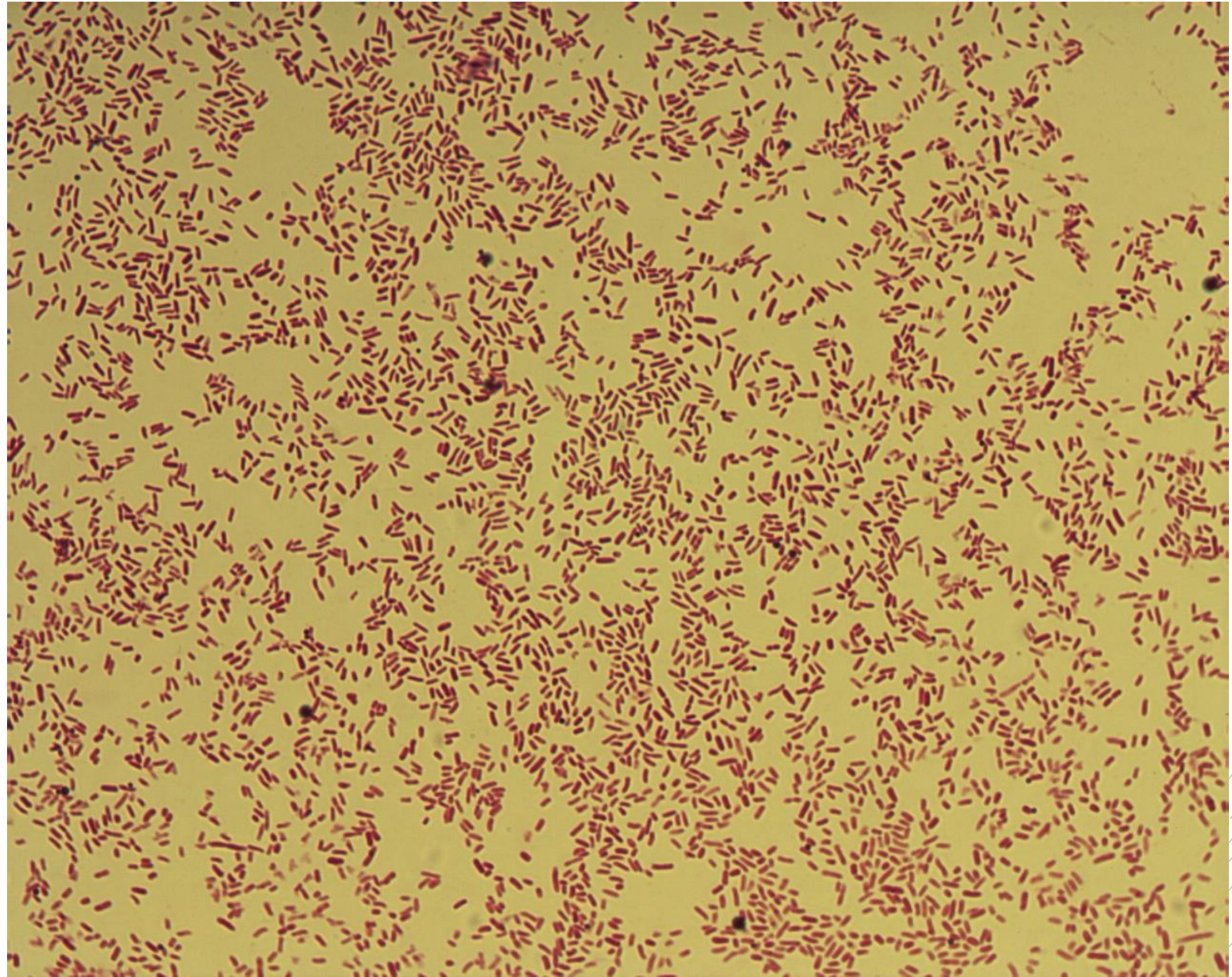
# *Salmonella* Enteritidis

**Specimen:** culture - stools

**Patient:** male, 22 years old

**Dg.:** gastroenteritis

**Microscopy:** Gram-negative rods



Authors: Markéta Šolarová, Hana Nekvasilová



CHARLES UNIVERSITY  
Second Faculty of Medicine

Slide No. 25

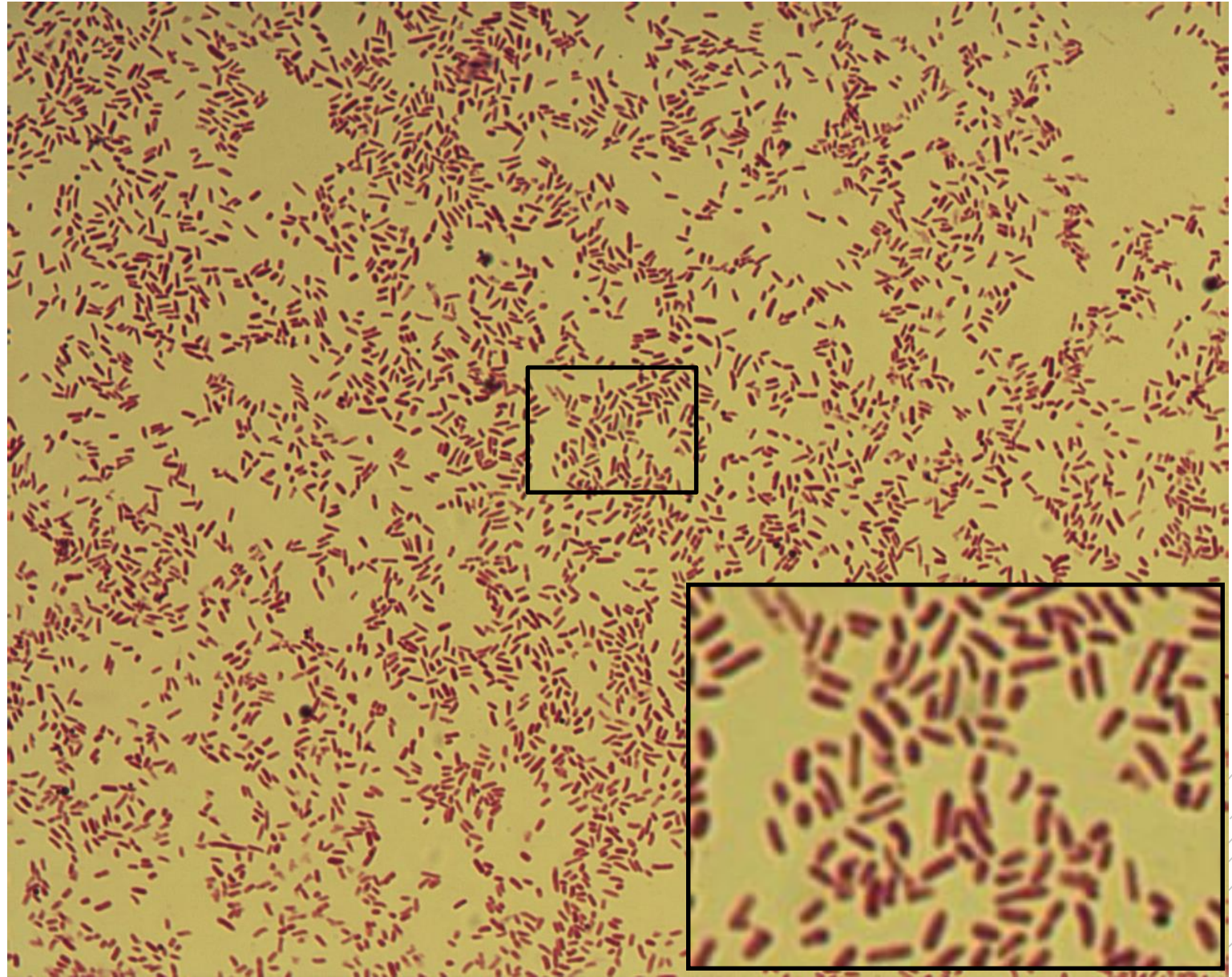
# *Salmonella* Enteritidis

**Specimen:** culture - stools

**Patient:** male, 22 years old

**Dg.:** gastroenteritis

**Microscopy:** Gram-negative rods



Authors: Markéta Šolarová, Hana Nekvasilová



CHARLES UNIVERSITY  
Second Faculty of Medicine

Slide No. 26

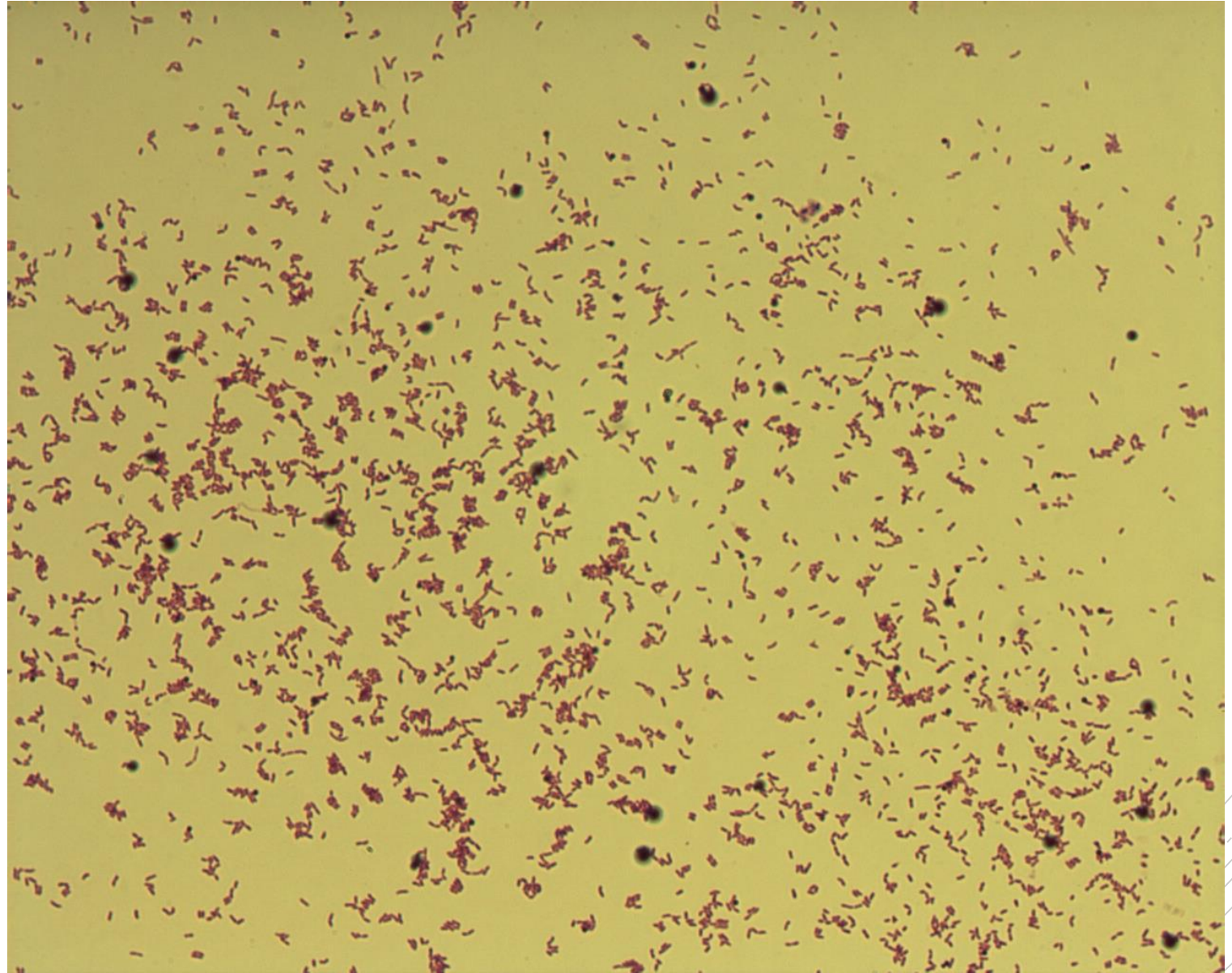
# *Arcanobacterium haemolyticum*

**Specimen:** culture – throat swab

**Patient:** female 17 years old

**Dg.:** tonsillitis

**Microscopy:** Gram-positive rods



Authors: Markéta Šolarová, Hana Nekvasilová



CHARLES UNIVERSITY  
Second Faculty of Medicine

Slide No. 26

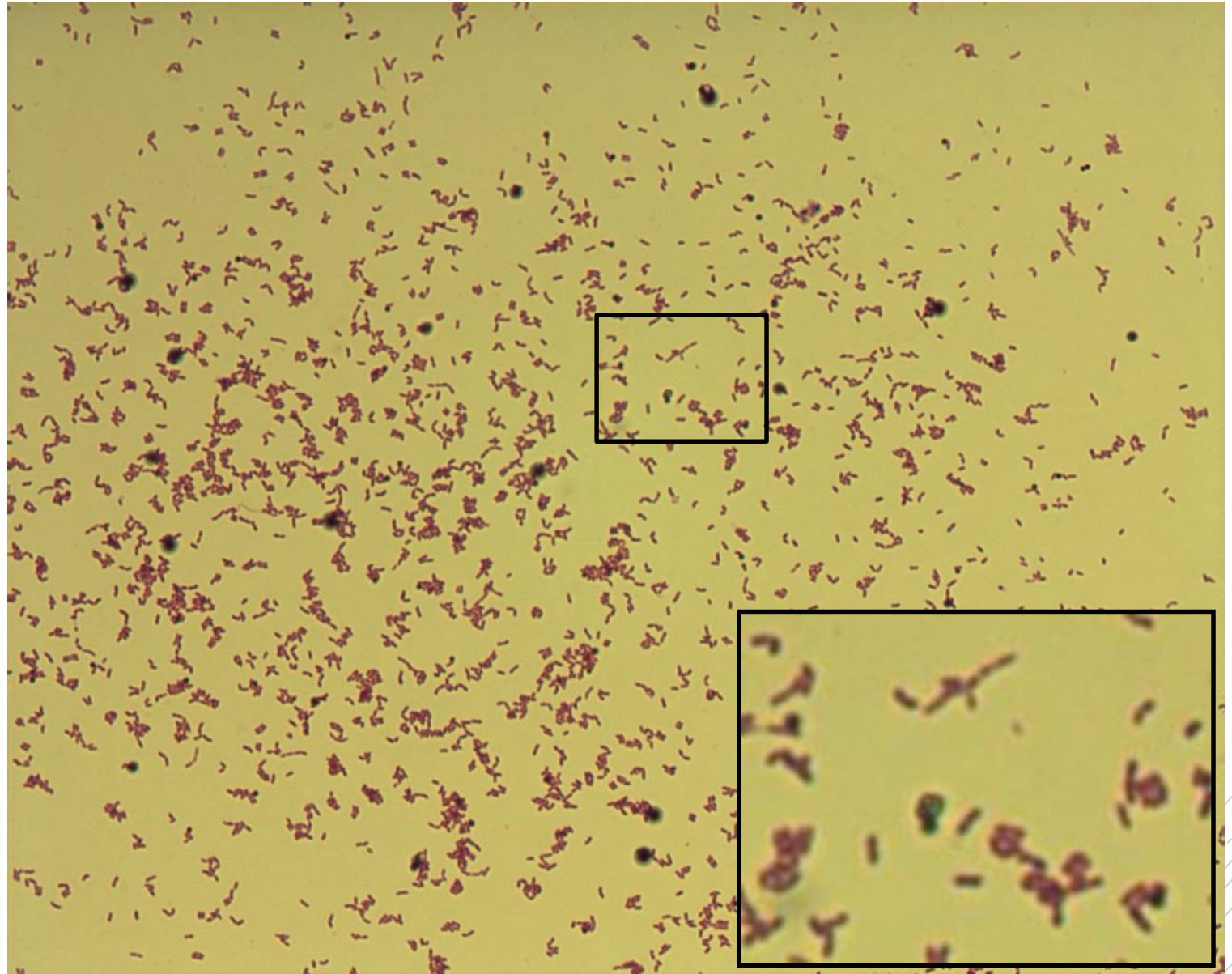
# *Arcanobacterium haemolyticum*

**Specimen:** culture – throat swab

**Patient:** female, 17 years old

**Dg.:** tonsillitis

**Microscopy:** Gram-positive rods



Authors: Markéta Šolarová, Hana Nekvasilová



CHARLES UNIVERSITY  
Second Faculty of Medicine

Slide No. 27

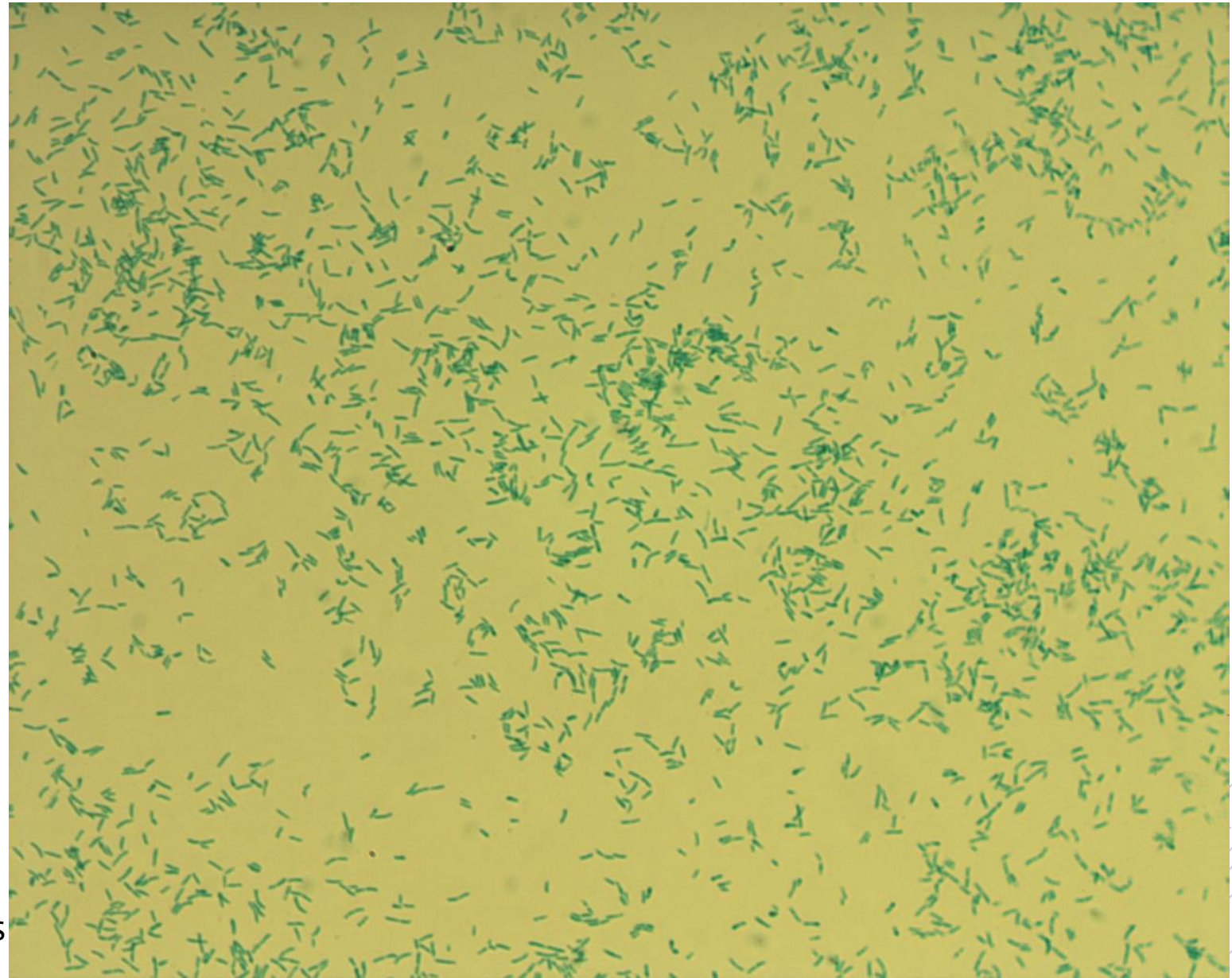
# *Corynebacterium diphtheriae*

**Specimen:** culture – throat swab

**Patient:** male, 2 years old

**Dg.:** tonsilopharyngitis

**Microscopy:** Albert stain, club-like rods  
with metachromatic granules



Authors: Markéta Šolarová, Hana Nekvasilová



CHARLES UNIVERSITY  
Second Faculty of Medicine

Slide No. 27


# *Corynebacterium diphtheriae*

**Specimen:** culture – throat swab

**Patient:** male, 2 years old

**Dg.:** tonsilopharyngitis

**Microscopy:** Albert stain, club-like rods with metachromatic granules



Authors: Markéta Šolarová, Hana Nekvasilová



CHARLES UNIVERSITY  
Second Faculty of Medicine

Slide No. 28

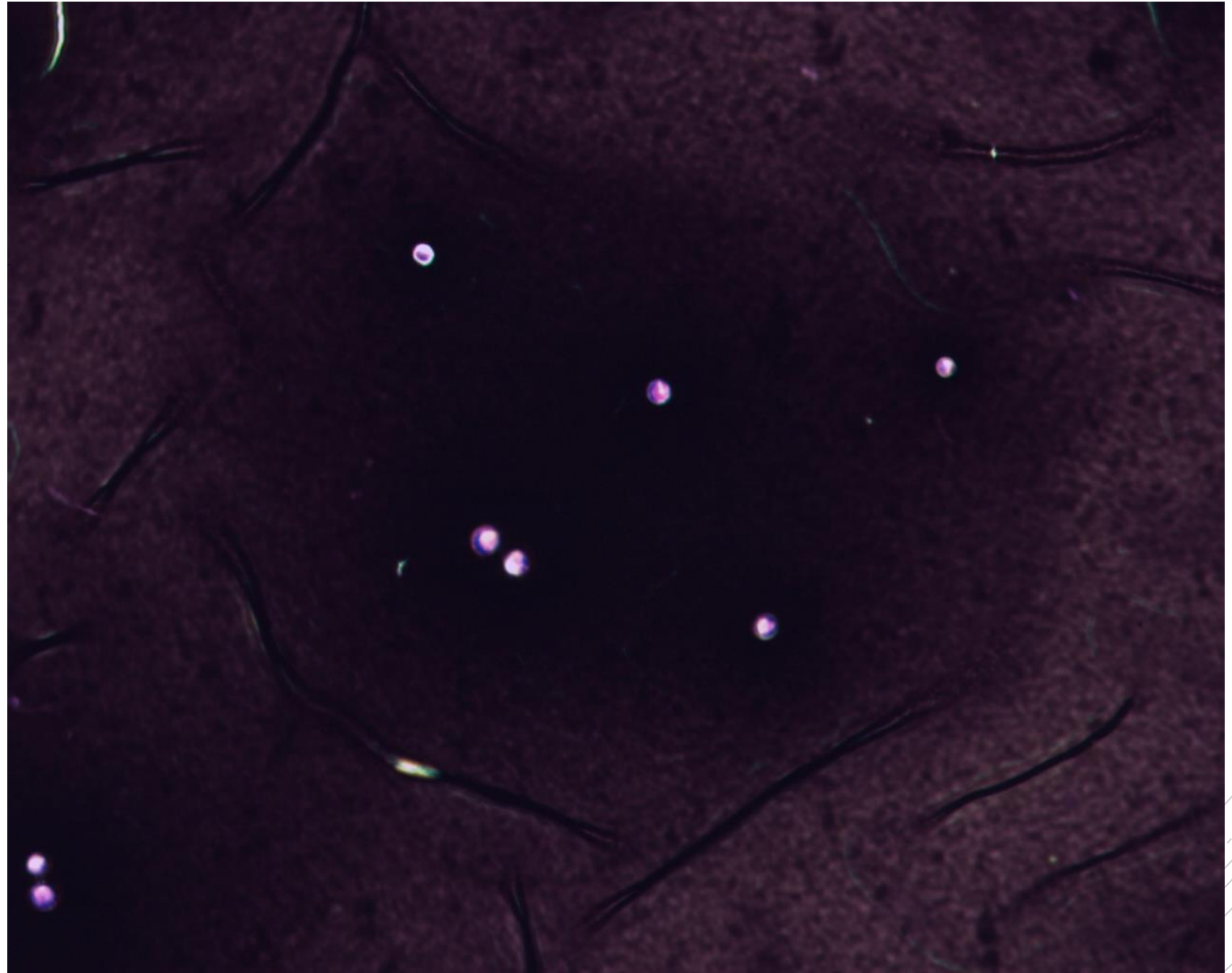
# *Cryptococcus neoformans*

**Specimen:** sputum

**Patient:** male, 34 years old

**Dg.:** pneumonia

**Microscopy:** capsules in Burri stain



Authors: Markéta Šolarová, Hana Nekvasilová





CHARLES UNIVERSITY  
Second Faculty of Medicine

Slide No. 28

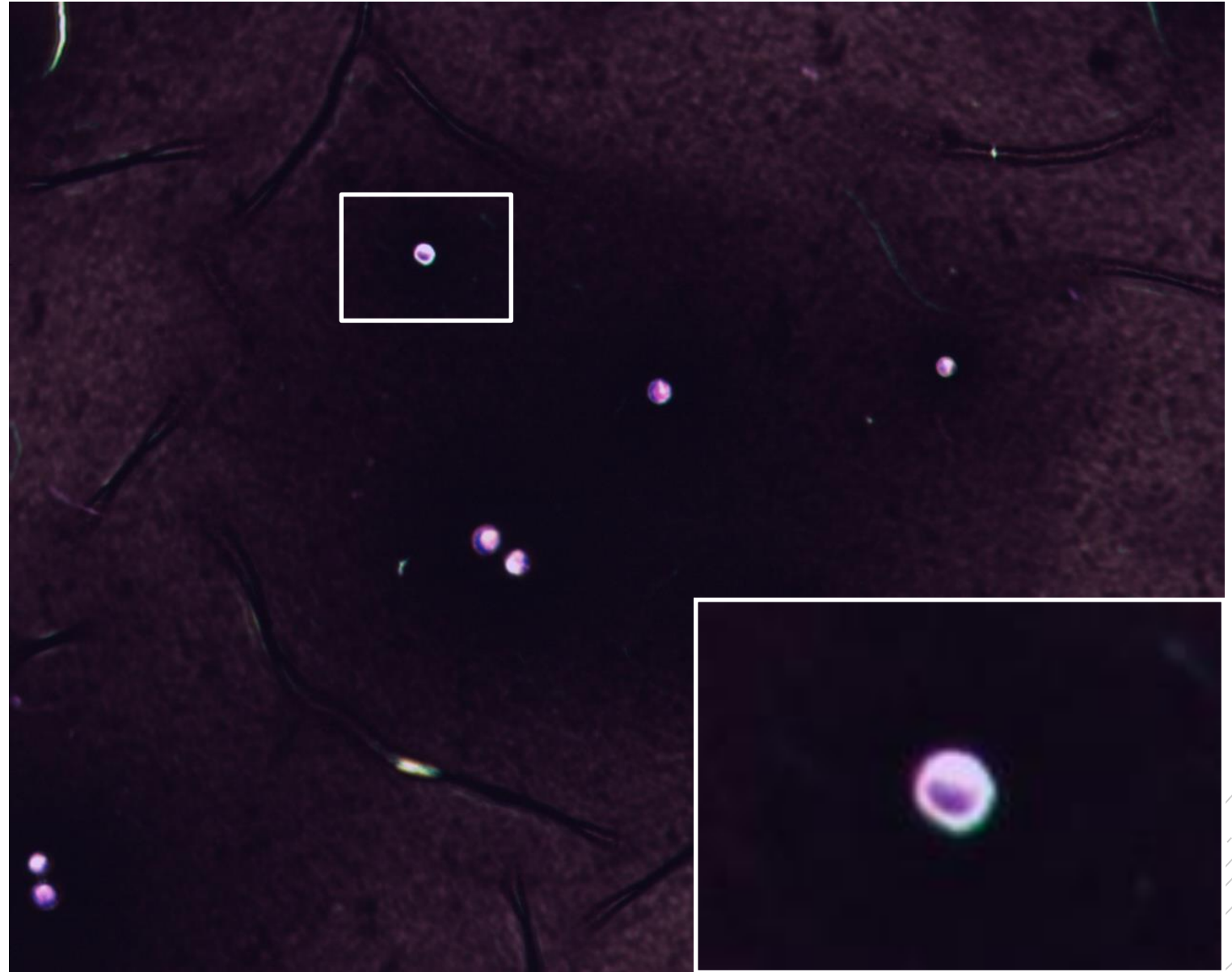
# *Cryptococcus neoformans*

**Specimen:** sputum

**Patient:** male, 34 years old

**Dg.:** pneumonia

**Microscopy:** capsules in Burri stain



Authors: Markéta Šolarová, Hana Nekvasilová



CHARLES UNIVERSITY  
Second Faculty of Medicine

Slide No. 29

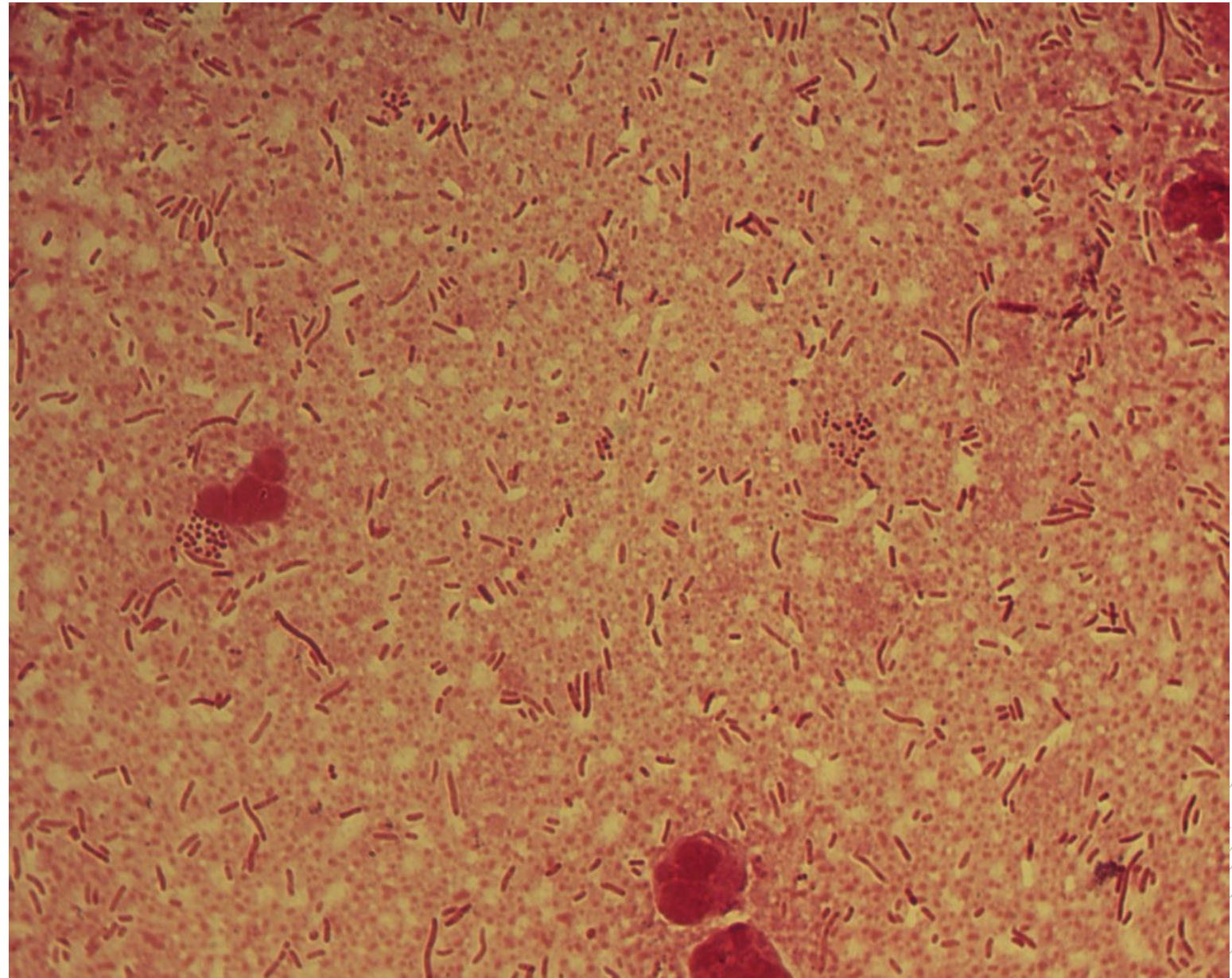
*Klebsiella  
pneumoniae,  
Enterococcus  
faecium*

**Specimen:** pus

**Patient:** male, 80let

**Dg.:** gallbladder tumor

**Microscopy:** Gram-negative rods and  
Gram-positive cocci



Author: MUDr. Alena Píšová



CHARLES UNIVERSITY  
Second Faculty of Medicine

Slide No. 29

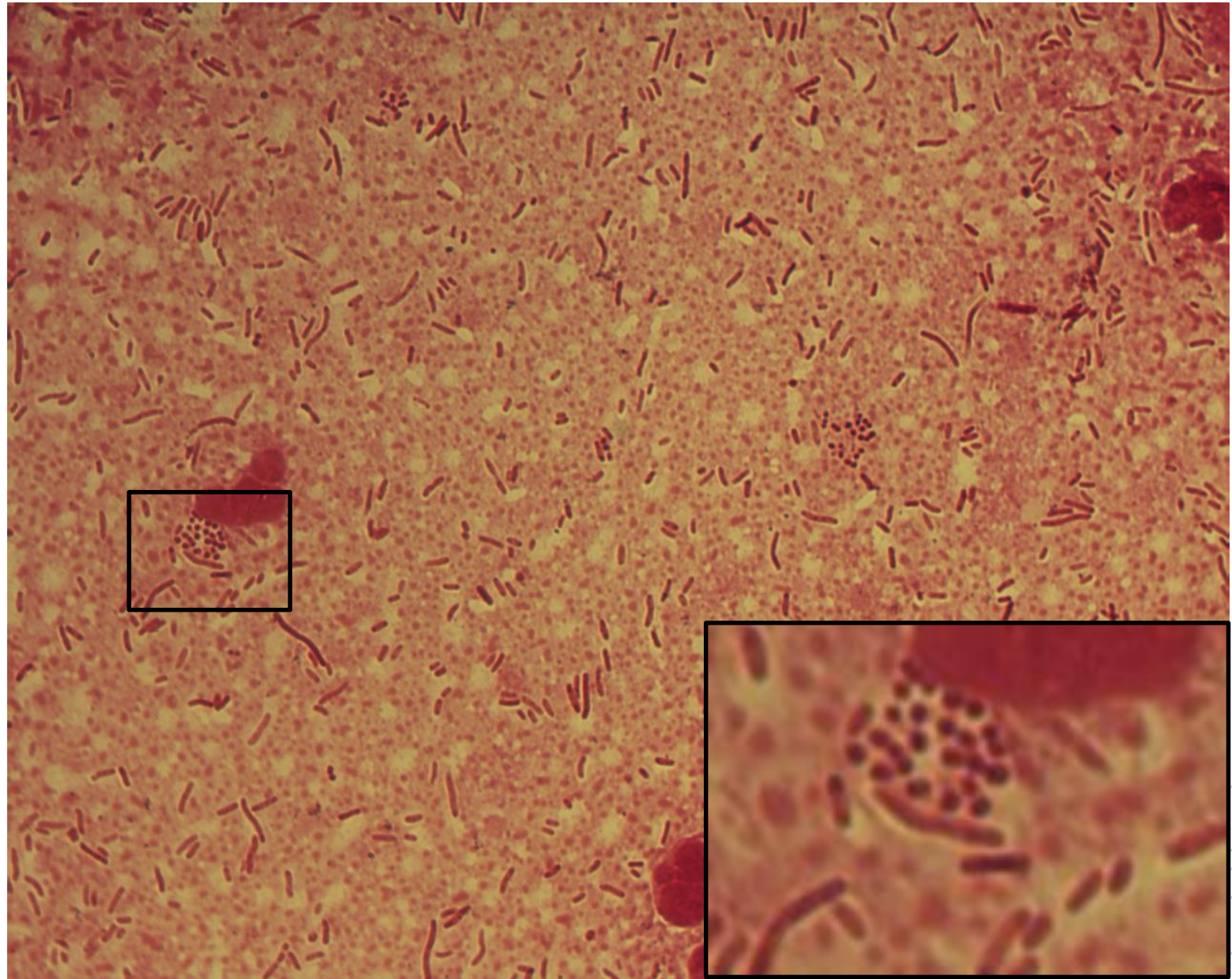
*Klebsiella  
pneumoniae,  
Enterococcus  
faecium*

**Specimen:** pus

**Patient:** male, 80let

**Dg.:** gallbladder tumor

**Microscopy:** Gram-negative rods and  
Gram-positive cocci



Author: MUDr. Alena Píšová



CHARLES UNIVERSITY  
Second Faculty of Medicine

Slide No. 30


# *Salmonella* Enteritidis

**Specimen:** blood culture

**Patient:** female, 68 years old

**Dg.:** bloodstream infection

**Microscopy:** Gram-negative rods



Authors: MUDr. Petra Kabelíková, Sandra Opálková



CHARLES UNIVERSITY  
Second Faculty of Medicine

Slide No. 30


# *Salmonella* Enteritidis

**Specimen:** blood culture

**Patient:** female, 68 years old

**Dg.:** bloodstream infection

**Microscopy:** Gram-negative rods



Authors: MUDr. Petra Kabelíková, Sandra Opálková



CHARLES UNIVERSITY  
Second Faculty of Medicine

Slide No. 31

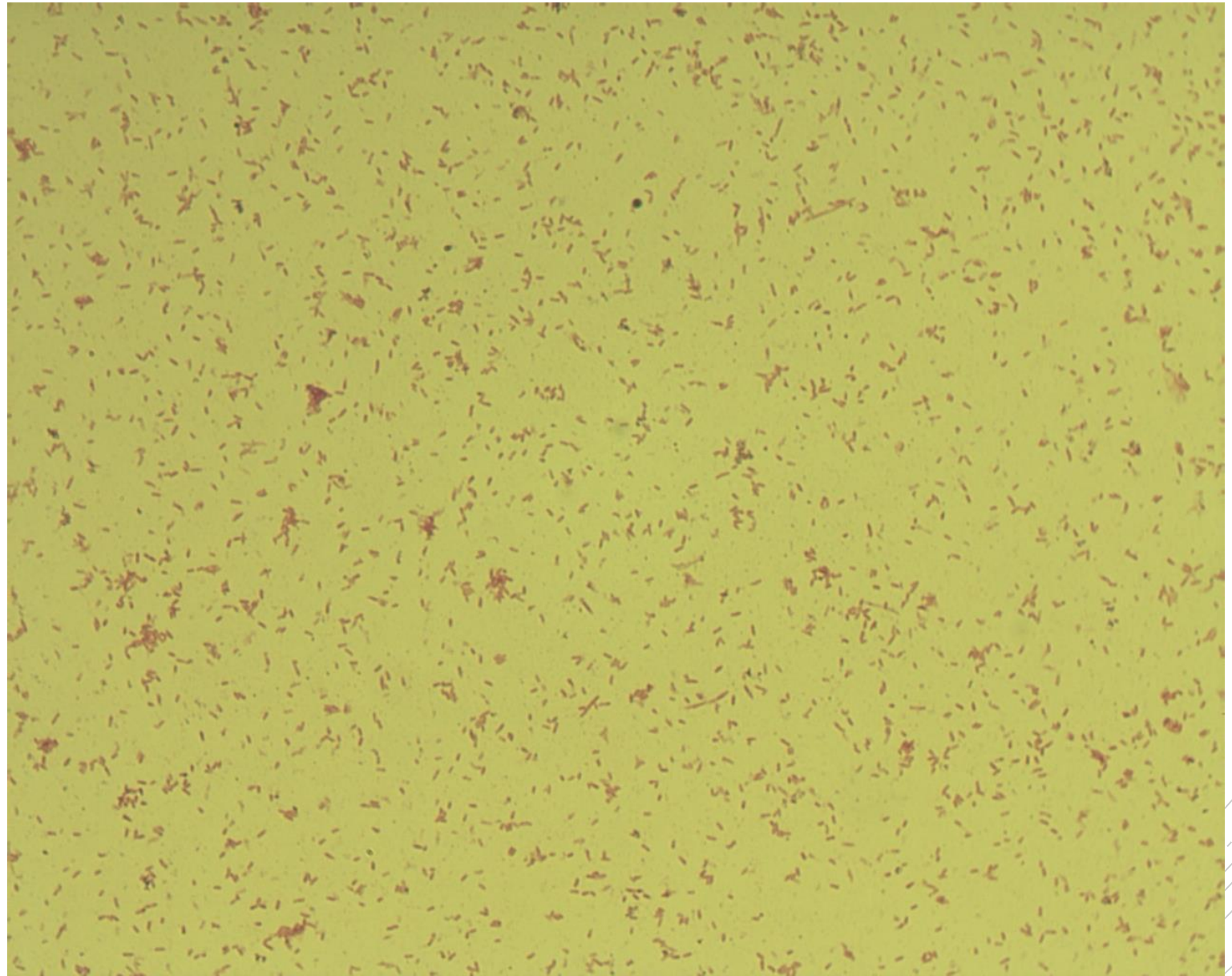
# *Bordetella pertussis*

**Specimen:** throat swab

**Patient:** male, 11 years old

**Dg.:** pharyngitis

**Microscopy:** Gram-negative  
coccobacilli



Authors: Markéta Šolarová, Hana Nekvasilová



CHARLES UNIVERSITY  
Second Faculty of Medicine

Slide No. 31


# *Bordetella pertussis*

**Specimen:** throat swab

**Patient:** male, 11 years old

**Dg.:** pharyngitis

**Microscopy:** Gram-negative  
coccobacilli



Authors: Markéta Šolarová, Hana Nekvasilová



CHARLES UNIVERSITY  
Second Faculty of Medicine

Slide No. 32

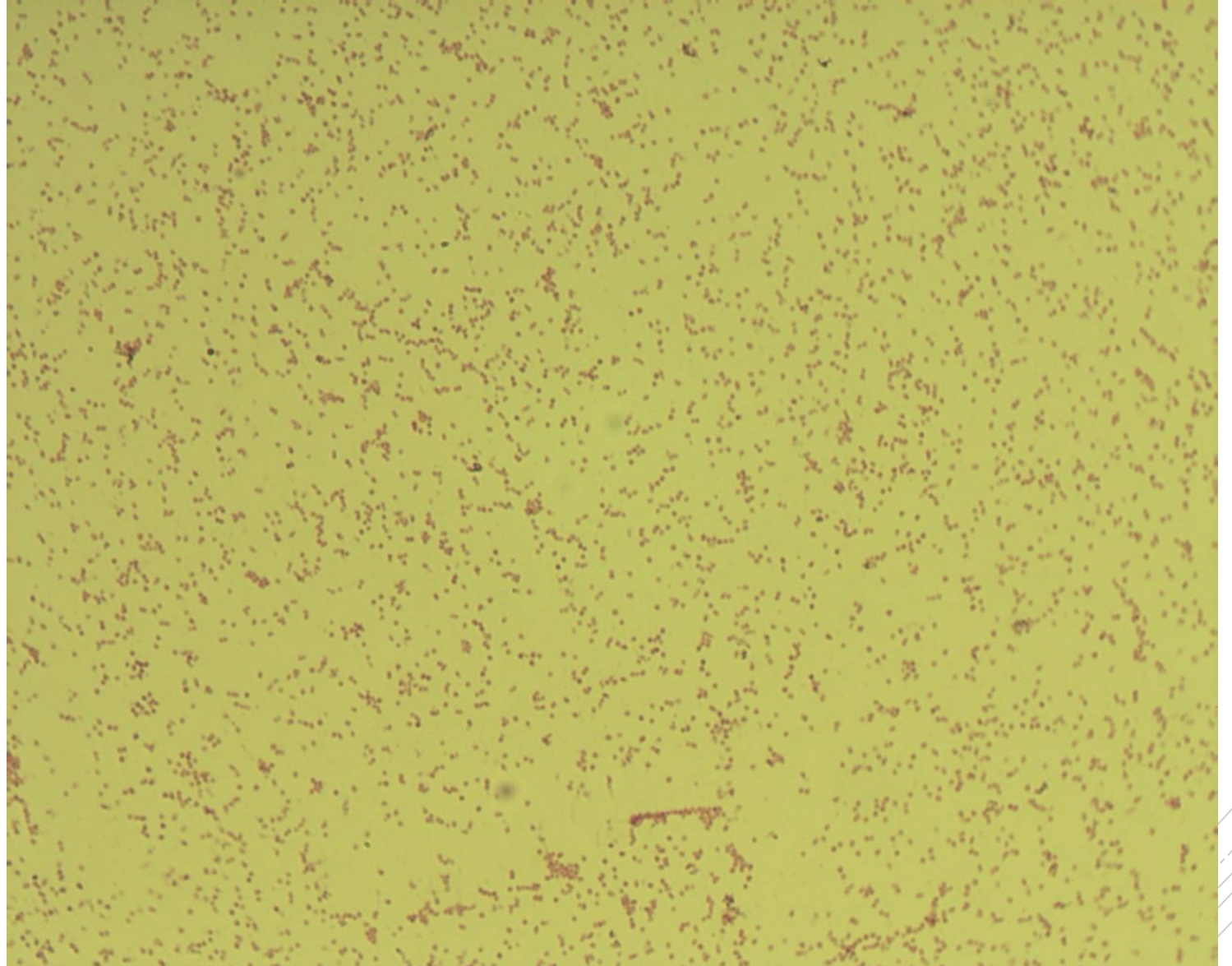
# *Bordetella parapertussis*

**Specimen:** throat swab

**Patient:** female, 10 years old

**Dg.:** pharyngitis

**Microscopy:** Gram-negative  
coccobacilli



Authors: Markéta Šolarová, Hana Nekvasilová





CHARLES UNIVERSITY  
Second Faculty of Medicine

Slide No. 32


# *Bordetella parapertussis*

**Specimen:** throat swab

**Patient:** female, 10 years old

**Dg.:** pharyngitis

**Microscopy:** Gram-negative cocco-rods



Authors: Markéta Šolarová, Hana Nekvasilová



CHARLES UNIVERSITY  
Second Faculty of Medicine

Slide No. 33

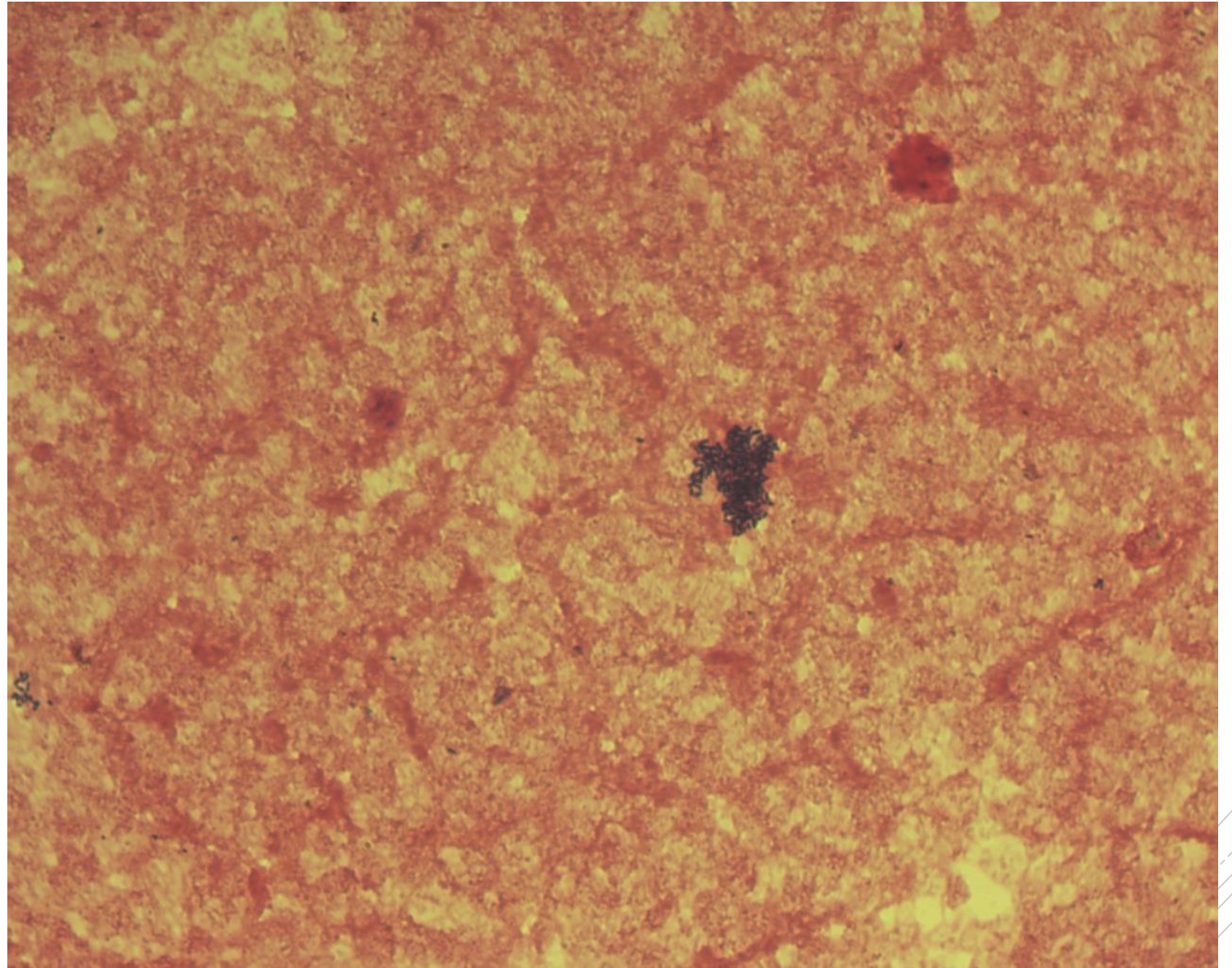
# *Listeria monocytogenes*

**Specimen:** blood culture

**Patient:** male, 71 years old

**Dg.:** sepsis

**Microscopy:** Gram-positive rods



Authors: MUDr. Petra Kabelíková, Sandra Opálková



CHARLES UNIVERSITY  
Second Faculty of Medicine

Slide No. 33

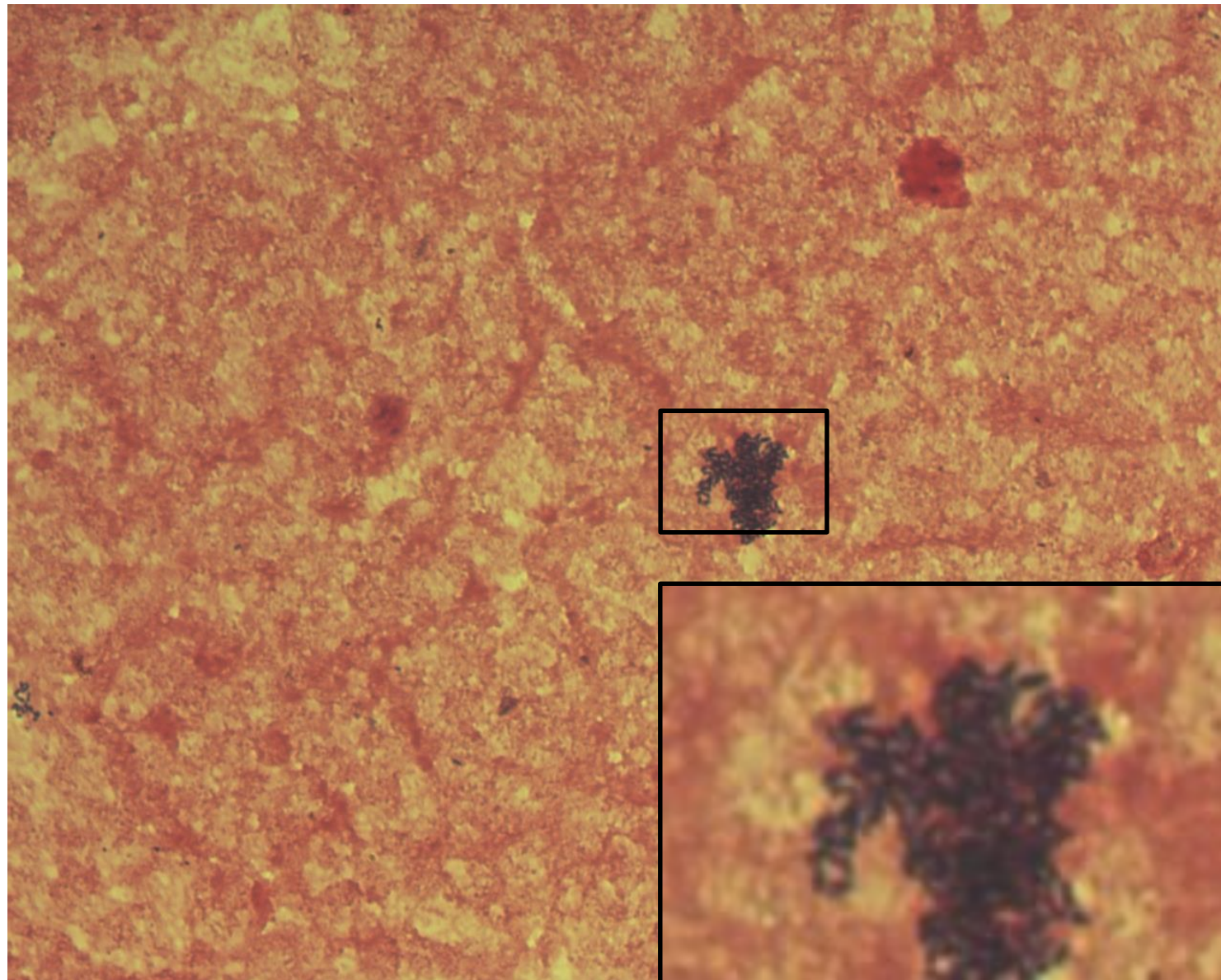
# *Listeria monocytogenes*

**Specimen:** blood culture

**Patient:** male, 71 years old

**Dg.:** sepsis

**Microscopy:** Gram-positive rods



Authors: MUDr. Petra Kabelíková, Sandra Opálková



CHARLES UNIVERSITY  
Second Faculty of Medicine

Slide No. 34

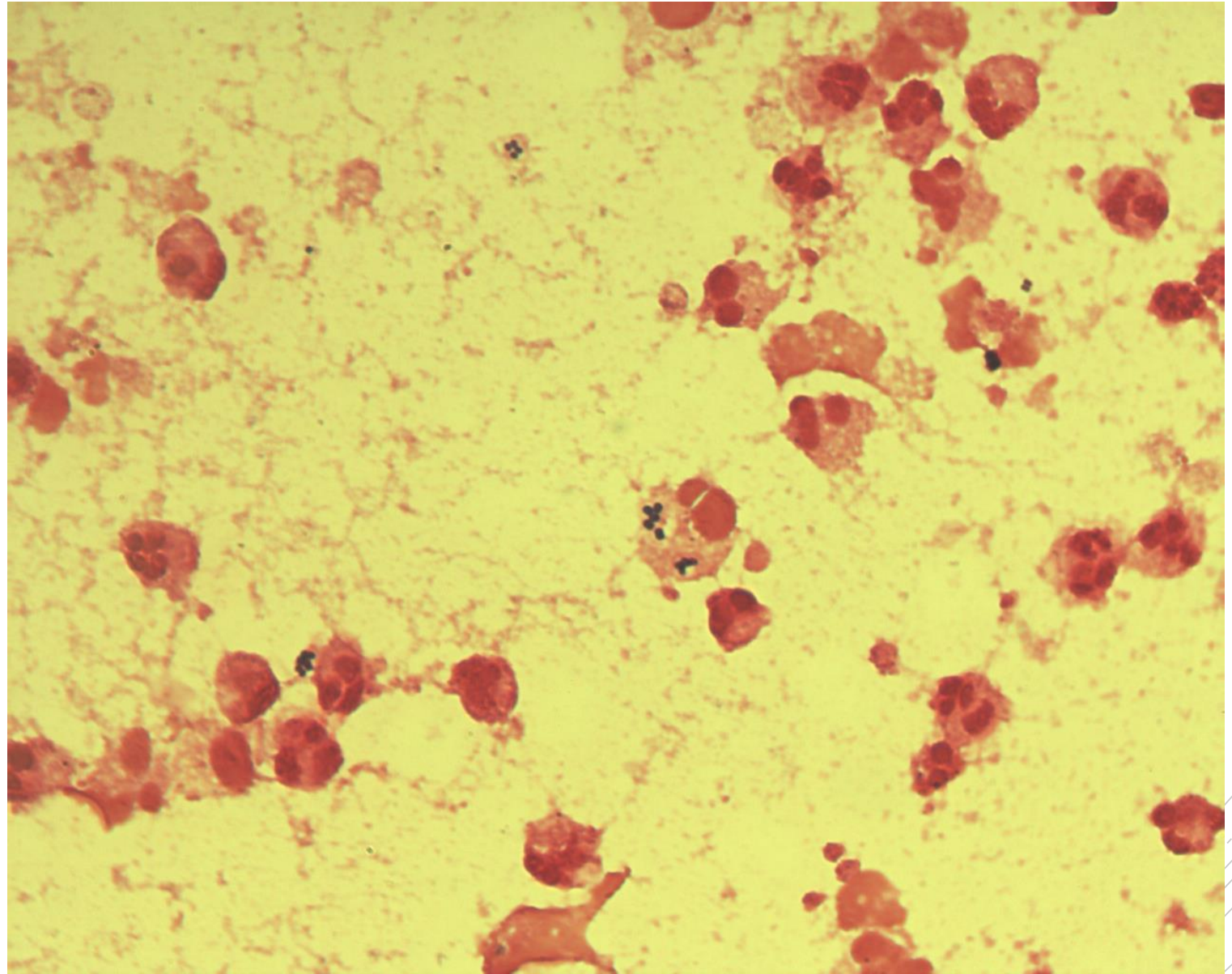
# *Staphylococcus aureus*

**Specimen:** joint fluid

**Patient:** male, 30 years old

**Dg.:** infectious arthritis

**Microscopy:** Gram-positive cocci  
in clusters



Author: doc. MVDr. Oto Melter, PhD.



CHARLES UNIVERSITY  
Second Faculty of Medicine

Slide No. 34

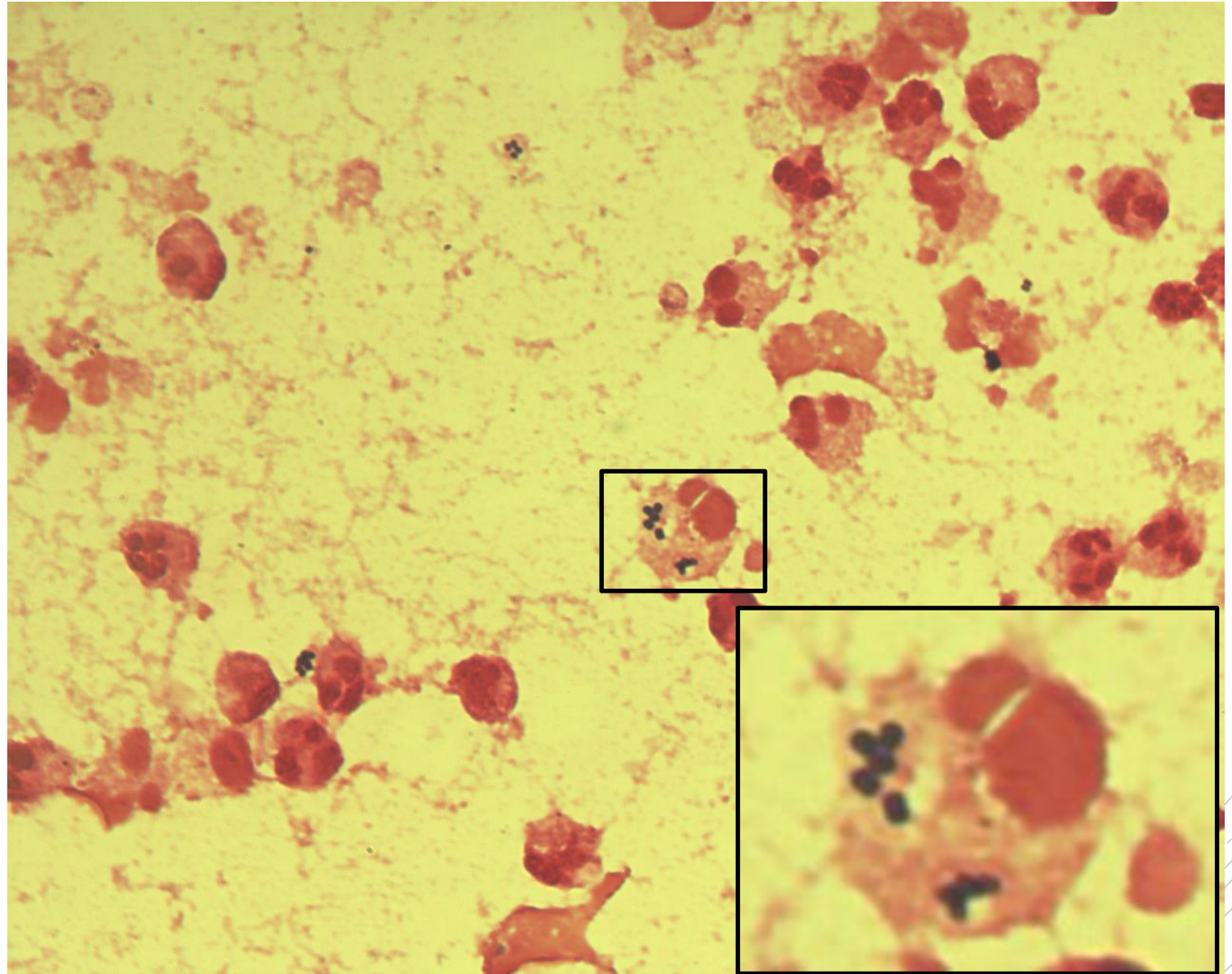
# *Staphylococcus aureus*

**Specimen:** joint fluid

**Patient:** male, 30 years old

**Dg.:** infectious arthritis

**Microscopy:** Gram-positive cocci  
in clusters



Author: doc. MVDr. Oto Melter, PhD.



CHARLES UNIVERSITY  
Second Faculty of Medicine

Slide No. 35

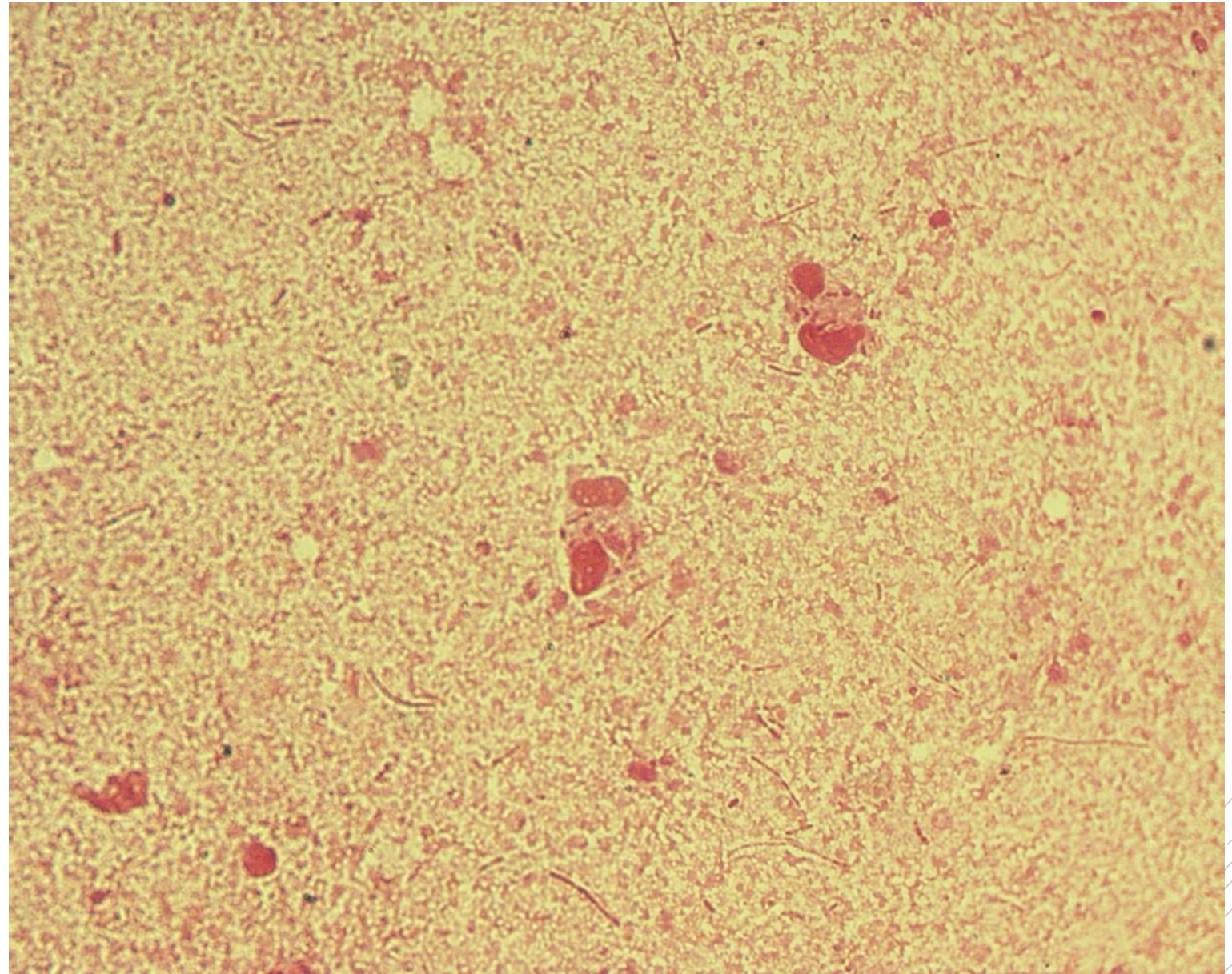
# *Burkholderia cepacia*

**Specimen:** sputum

**Patient:** male, 16 years old

**Dg.:** cystic fibrosis (exacerbation)

**Microscopy:** Gram-negative rods



Author: doc. MVDr. Oto Melter, PhD.



CHARLES UNIVERSITY  
Second Faculty of Medicine

Slide No. 35

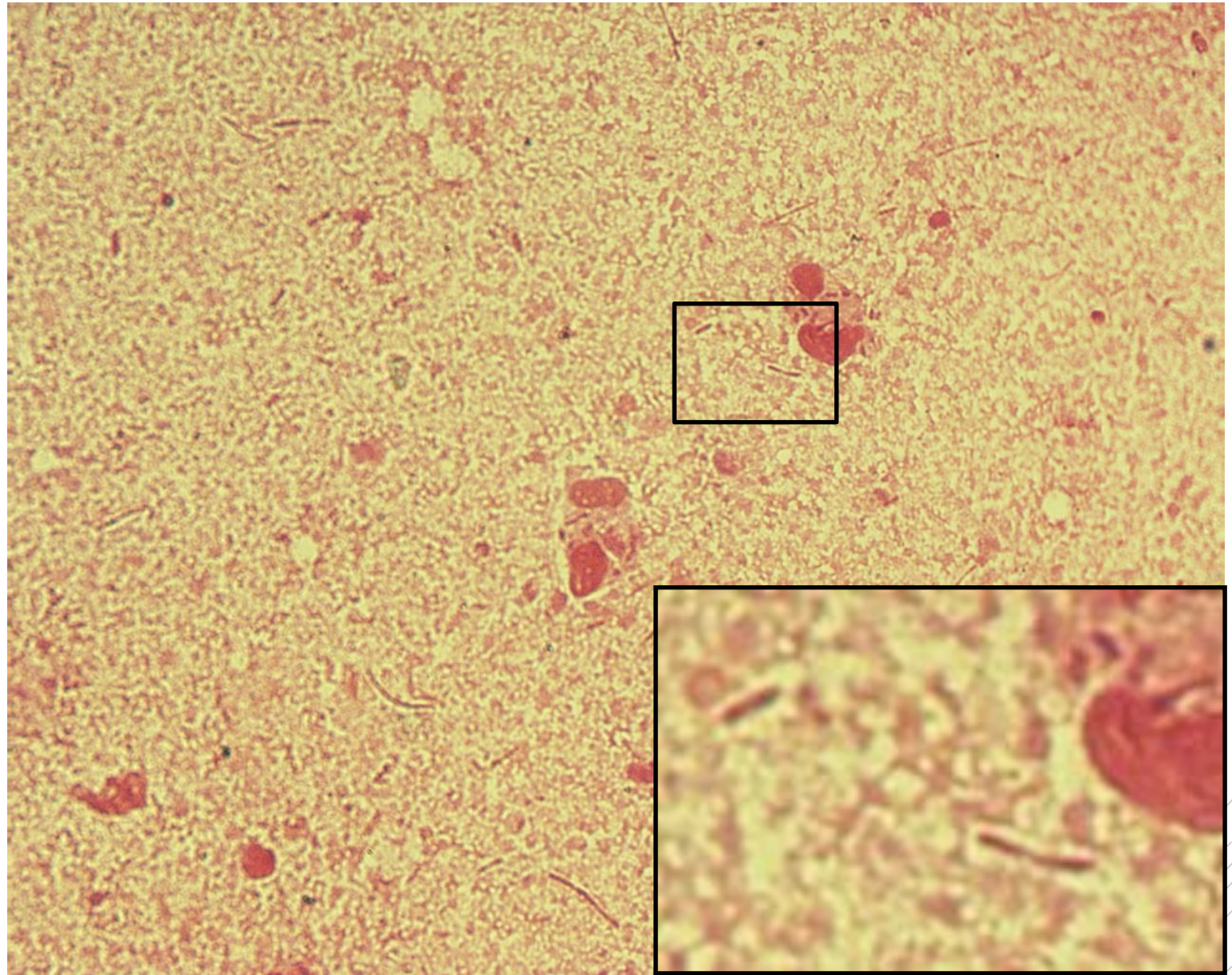
# *Burkholderia cepacia*

**Specimen:** sputum

**Patient:** male, 16 years old

**Dg.:** cystic fibrosis (exacerbation)

**Microscopy:** Gram-negative rods



Author: doc. MVDr. Oto Melter, PhD.



CHARLES UNIVERSITY  
Second Faculty of Medicine

Slide No. 36

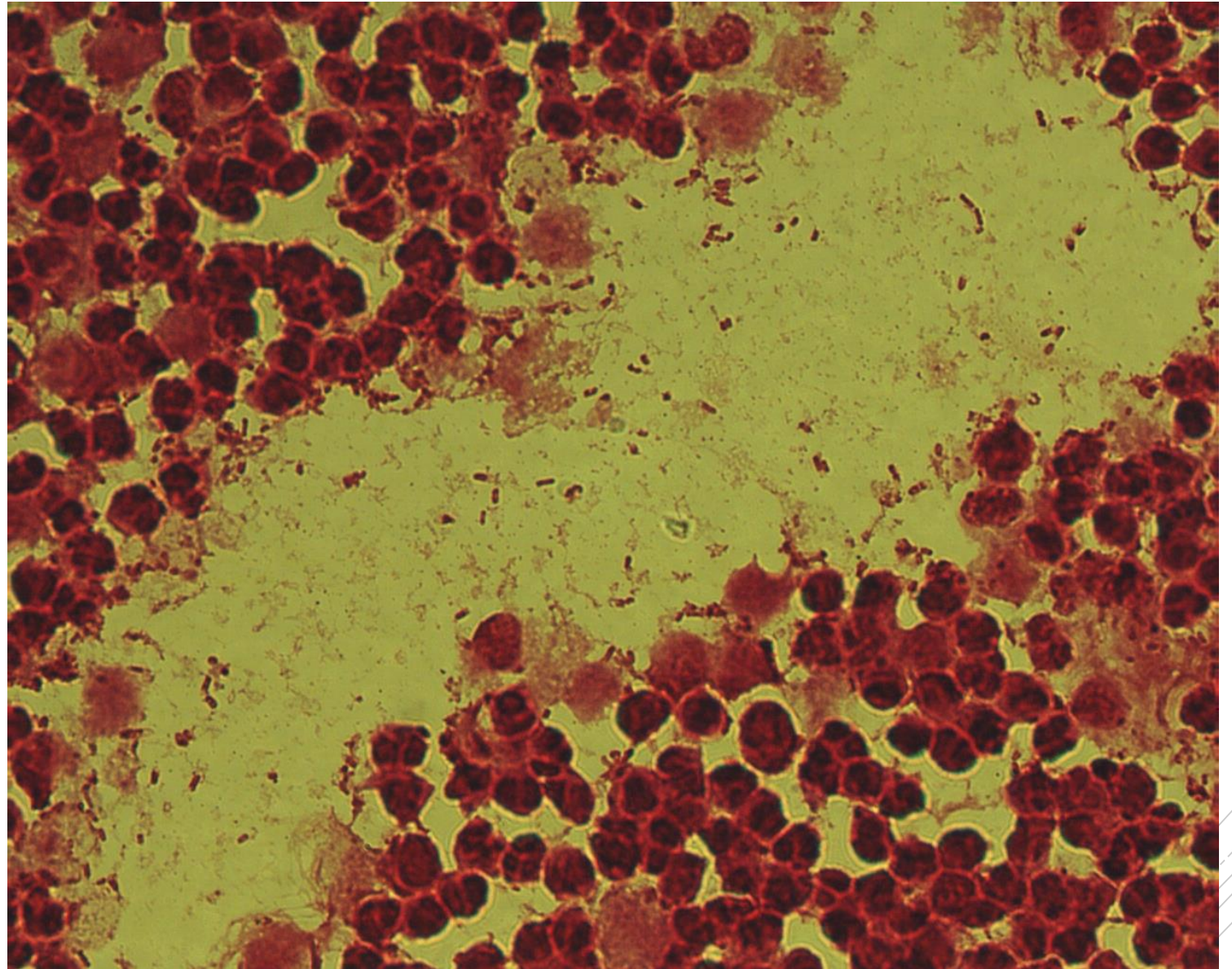
# *Escherichia coli*

**Specimen:** kidney tissue

**Patient:** female, 54 years old

**Dg.:** kidney stones

**Microscopy:** Gram-negative rods



Author: MUDr. Alena Pířová





CHARLES UNIVERSITY  
Second Faculty of Medicine

Slide No. 36

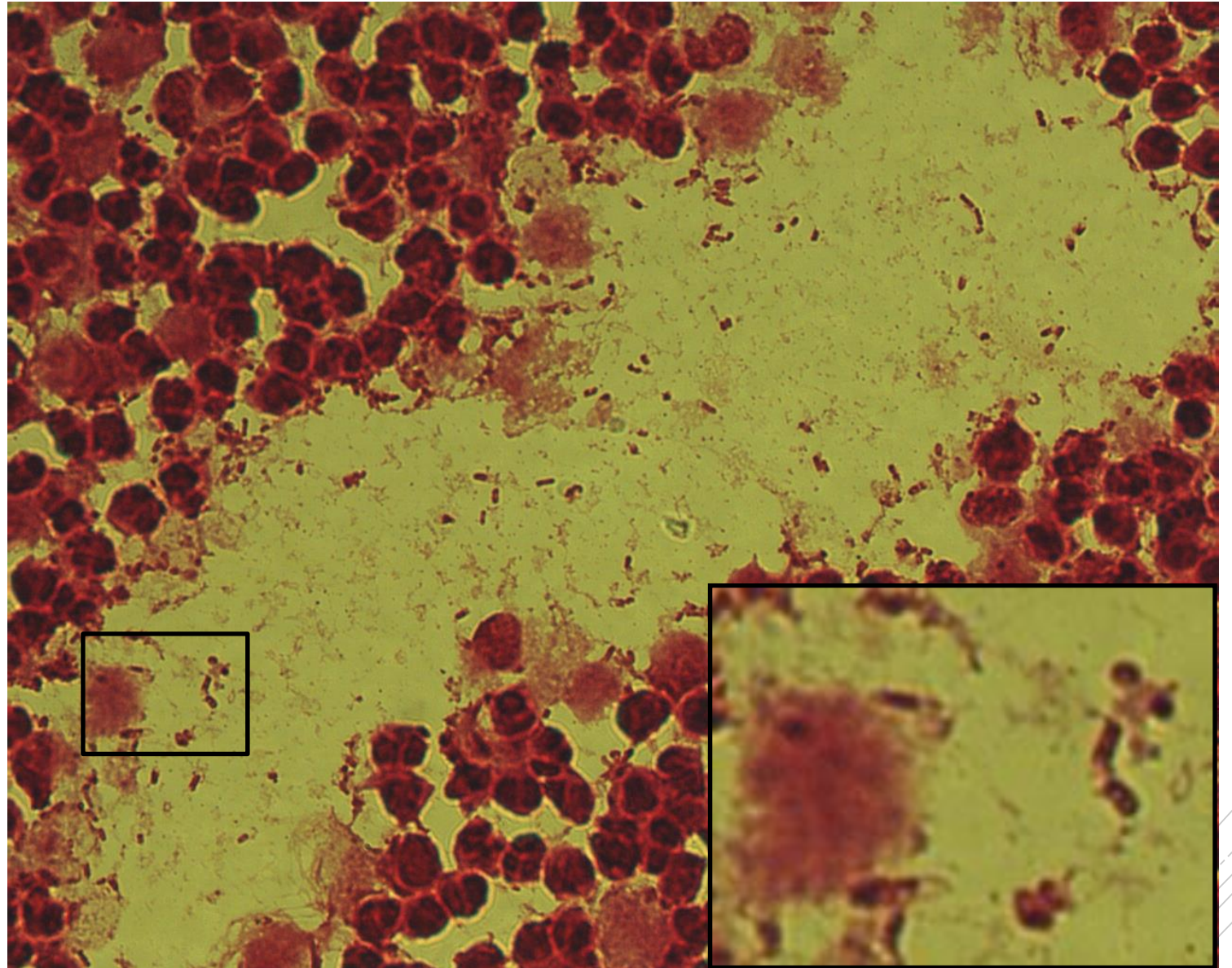
# *Escherichia coli*

**Specimen:** kidney tissue

**Patient:** female, 54 years old

**Dg.:** kidney stones

**Microscopy:** Gram-negative rods



Author: MUDr. Alena Pířová



CHARLES UNIVERSITY  
Second Faculty of Medicine

Slide No. 37

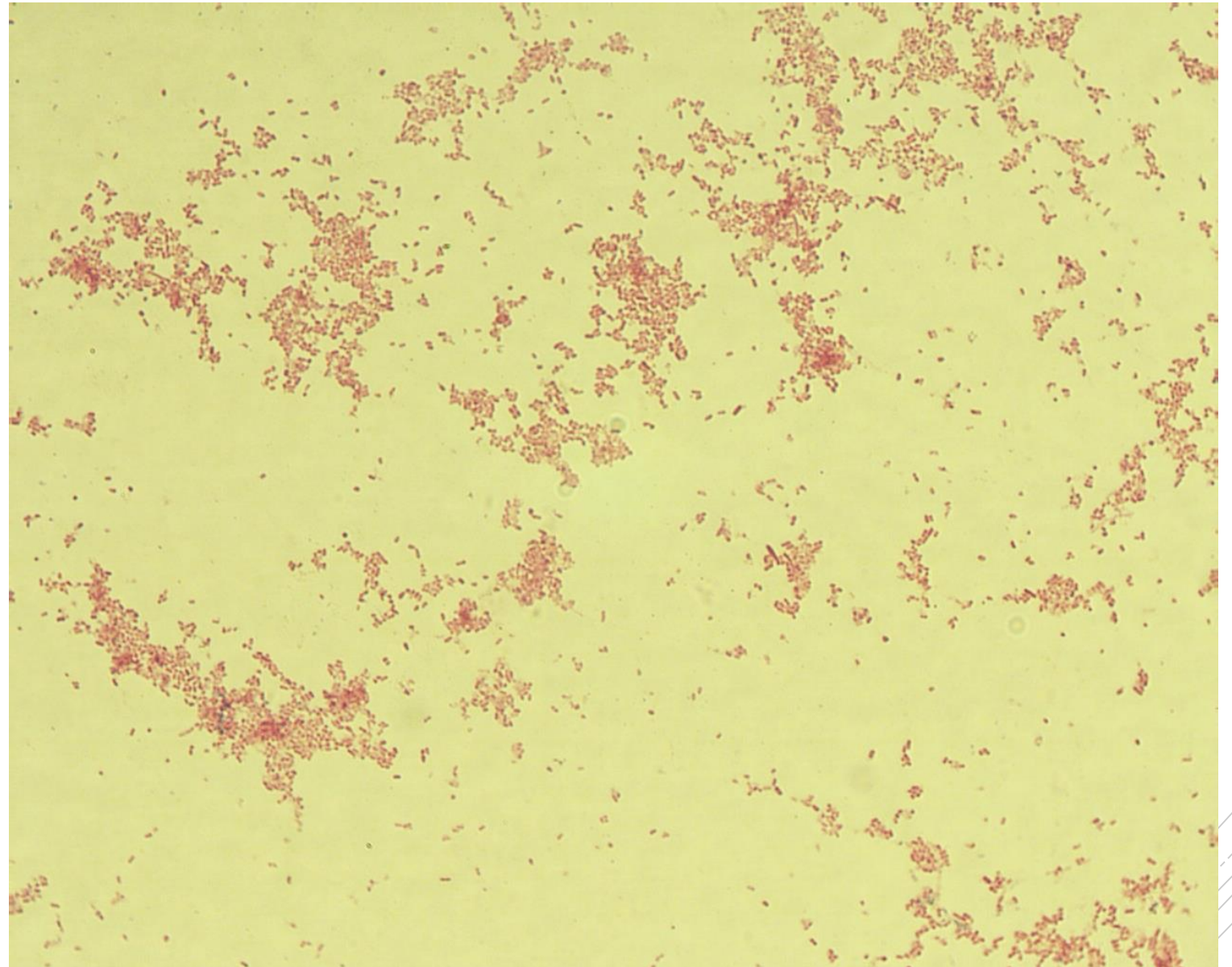
# *Yersinia enterocolitica*

**Specimen:** culture

**Patient:** female, 22 years old

**Dg.:** enterocolitis

**Microscopy:** Gram-negative rods



Author: MUDr. Alena Pířová



CHARLES UNIVERSITY  
Second Faculty of Medicine

Slide No. 37


# *Yersinia enterocolitica*

**Specimen:** culture

**Patient:** female, 22 years old

**Dg.:** enterocolitis

**Microscopy:** Gram-negative rods



Author: MUDr. Alena Pířová



CHARLES UNIVERSITY  
Second Faculty of Medicine

Slide No. 38

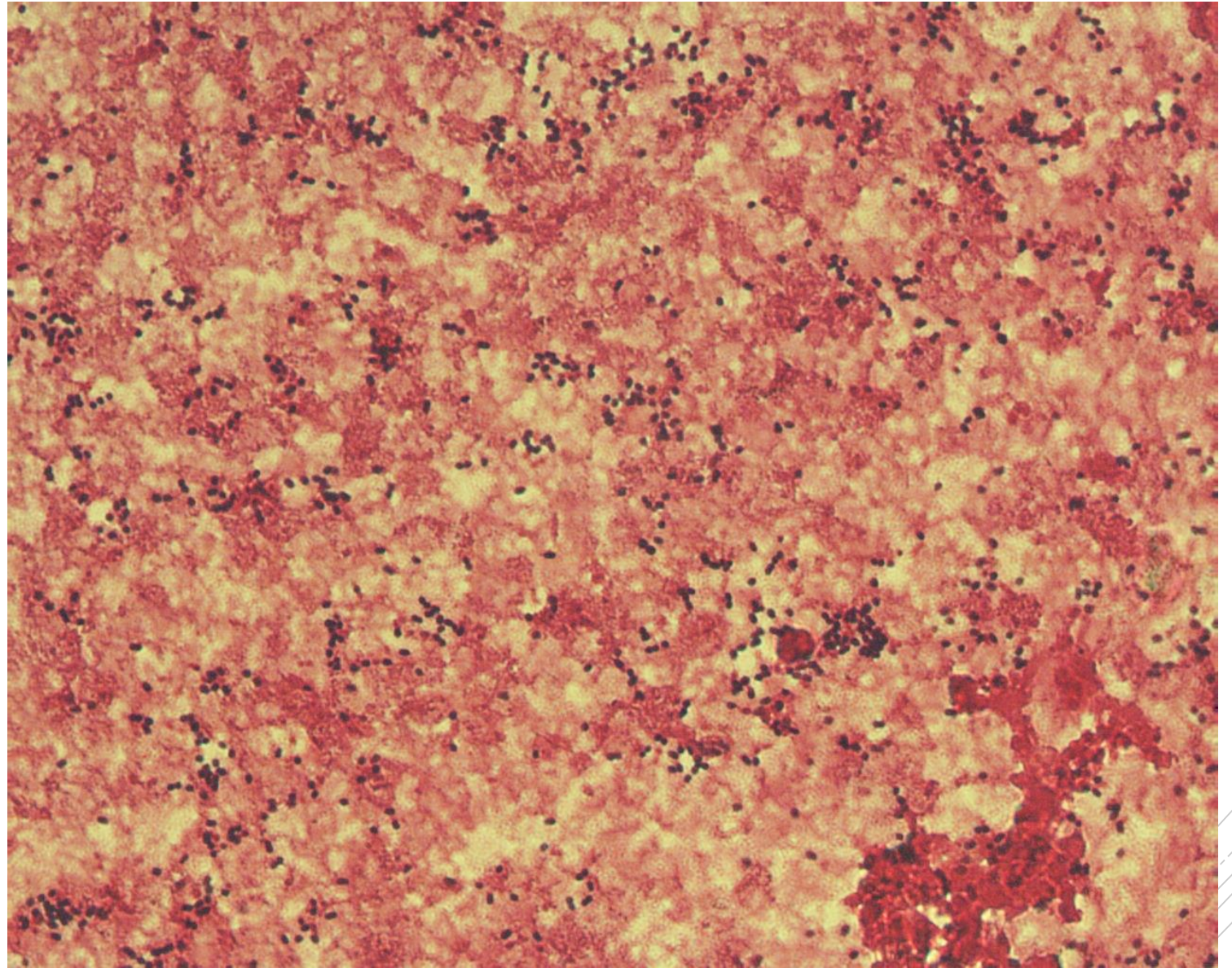
# *Streptococcus pneumoniae*

**Specimen:** blood culture

**Patient:** female, 63 years old

**Dg.:** pneumonia

**Microscopy:** Gram-positive diplococci



Authors: MUDr. Petra Kabelíková, Sandra Opálková



CHARLES UNIVERSITY  
Second Faculty of Medicine

Slide No. 38

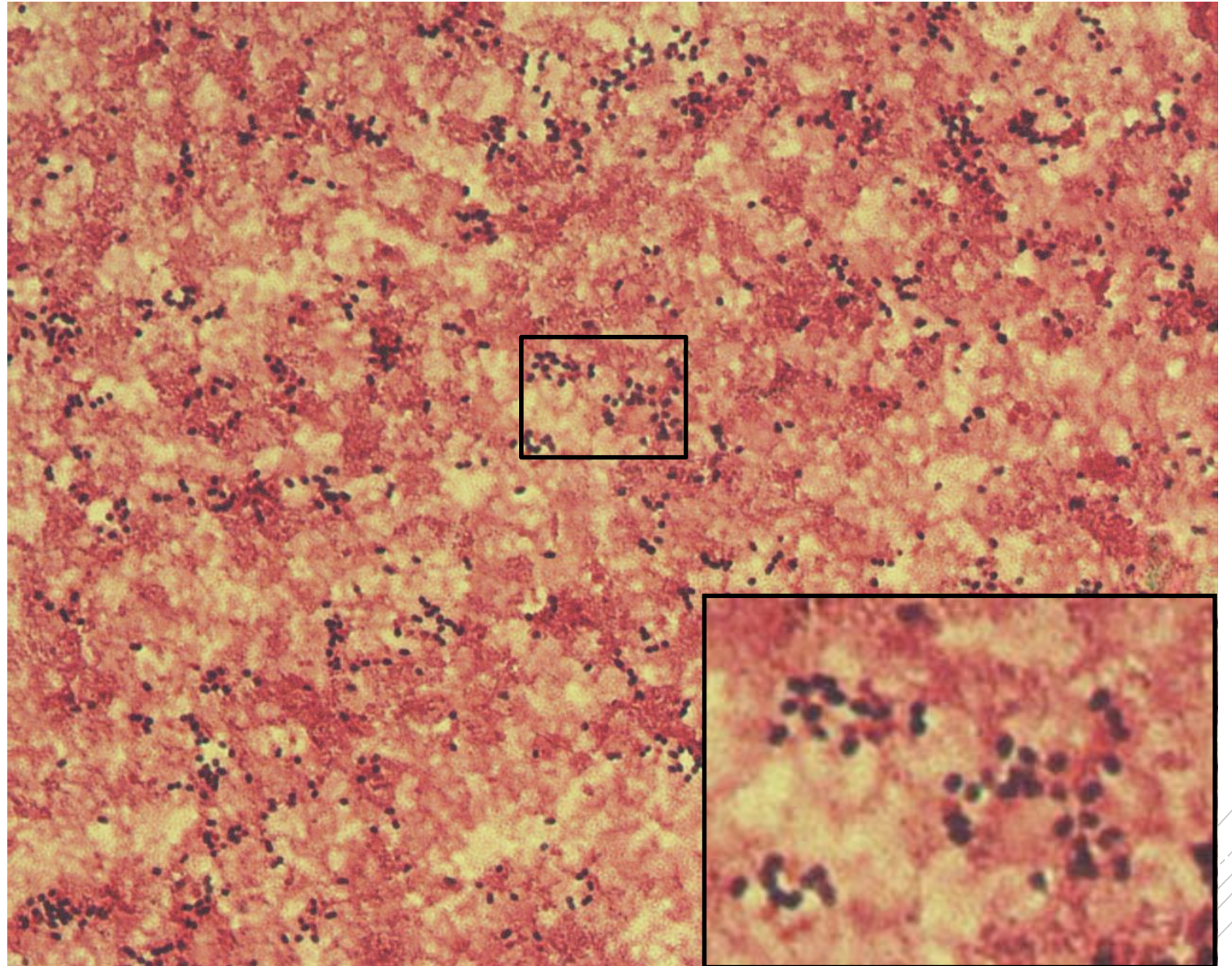
# *Streptococcus pneumoniae*

**Specimen:** blood culture

**Patient:** female, 63 years old

**Dg.:** pneumonia

**Microscopy:** Gram-positive diplococci



Authors: MUDr. Petra Kabelíková, Sandra Opálková



CHARLES UNIVERSITY  
Second Faculty of Medicine

Slide No. 39

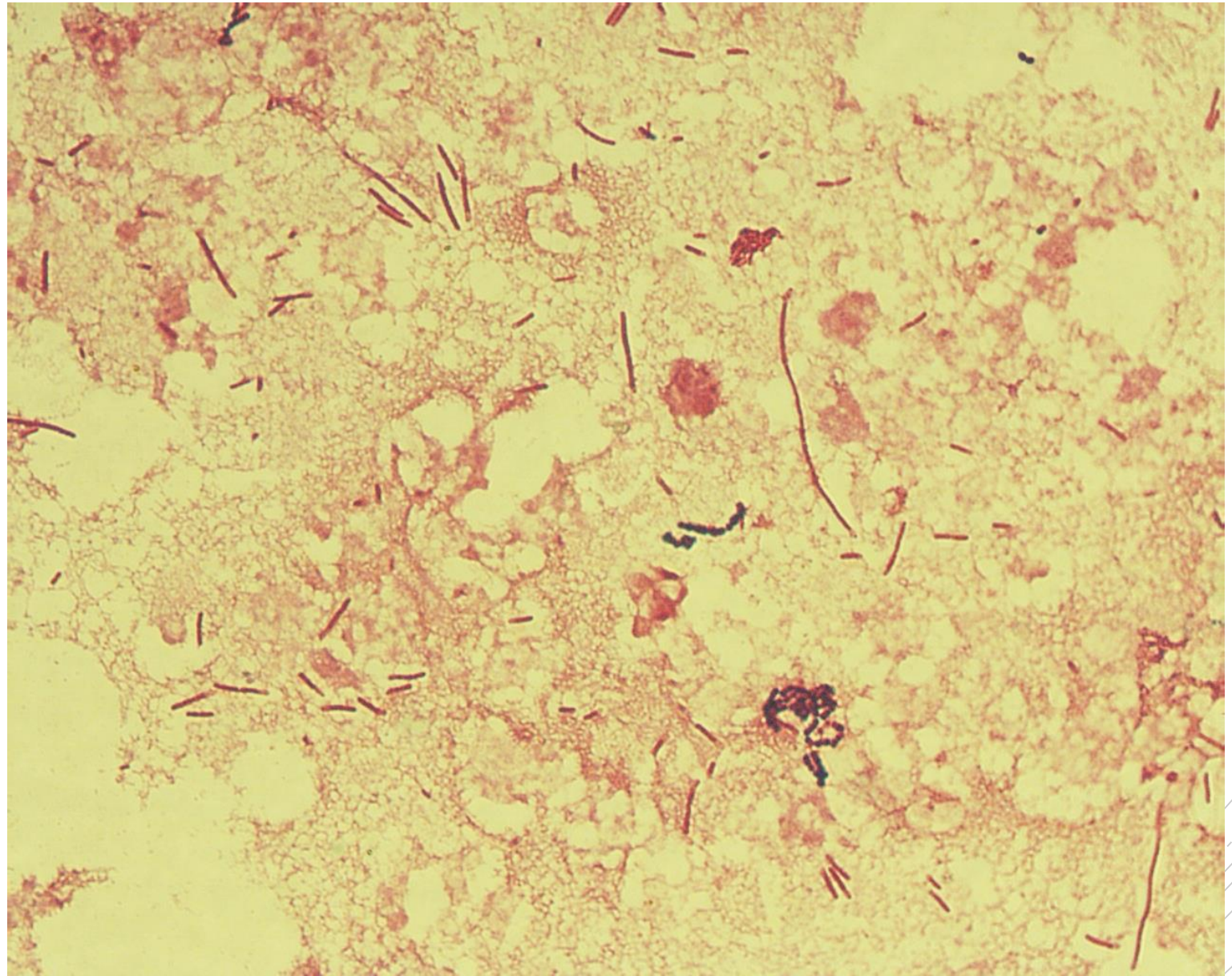
# *Citrobacter freundii*

**Specimen:** Pus

**Patient:** male, 70 years old

**Dg.:** pancreatic cancer

**Microscopy:** Gram-negative rods



Author: MUDr. Alena Pířová



CHARLES UNIVERSITY  
Second Faculty of Medicine

Slide No. 39

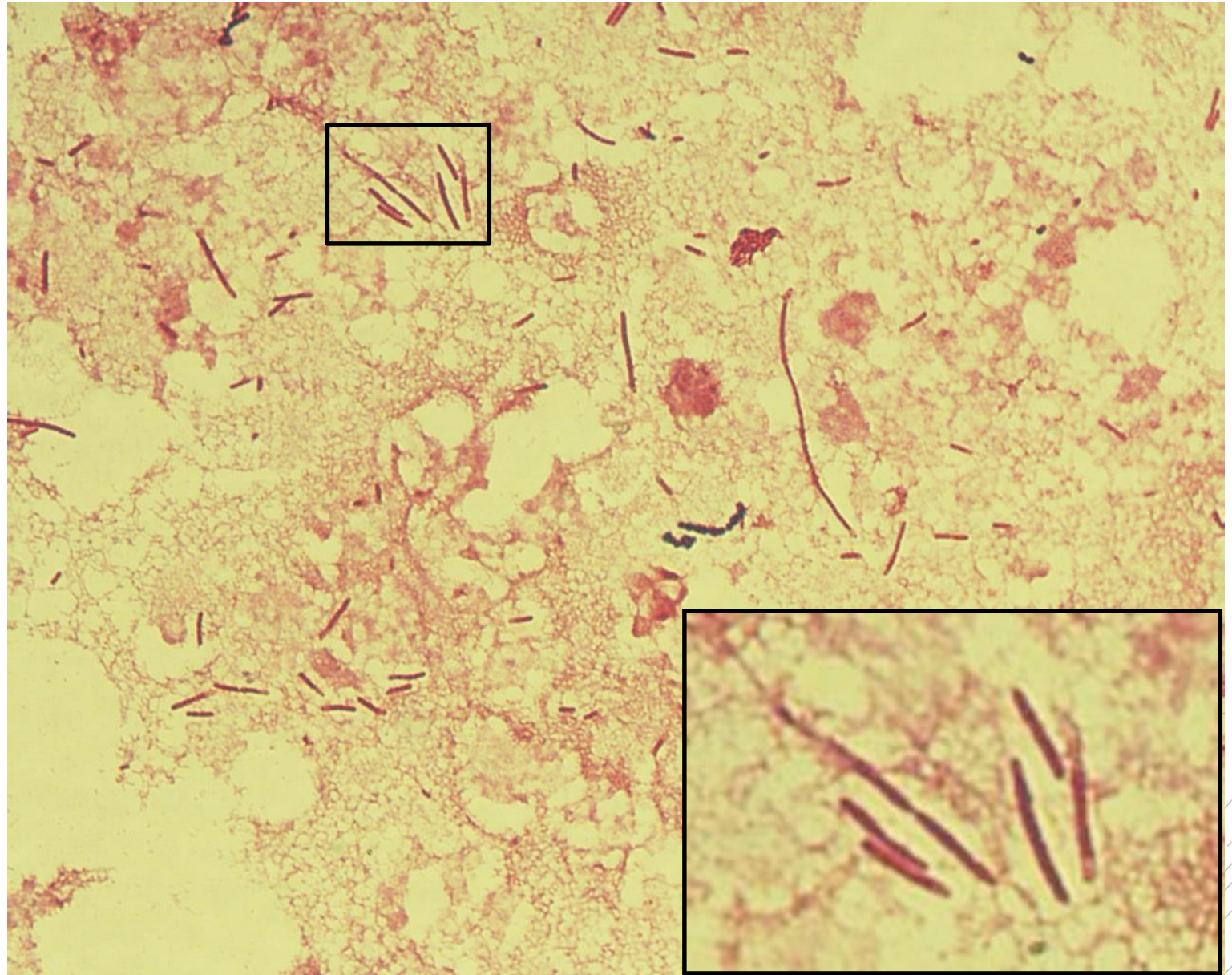
# *Citrobacter freundii*

**Specimen:** Pus

**Patient:** male, 70 years old

**Dg.:** pancreatic cancer

**Microscopy:** Gram-negative rods



Author: MUDr. Alena Pířová



CHARLES UNIVERSITY  
Second Faculty of Medicine

Slide No. 40

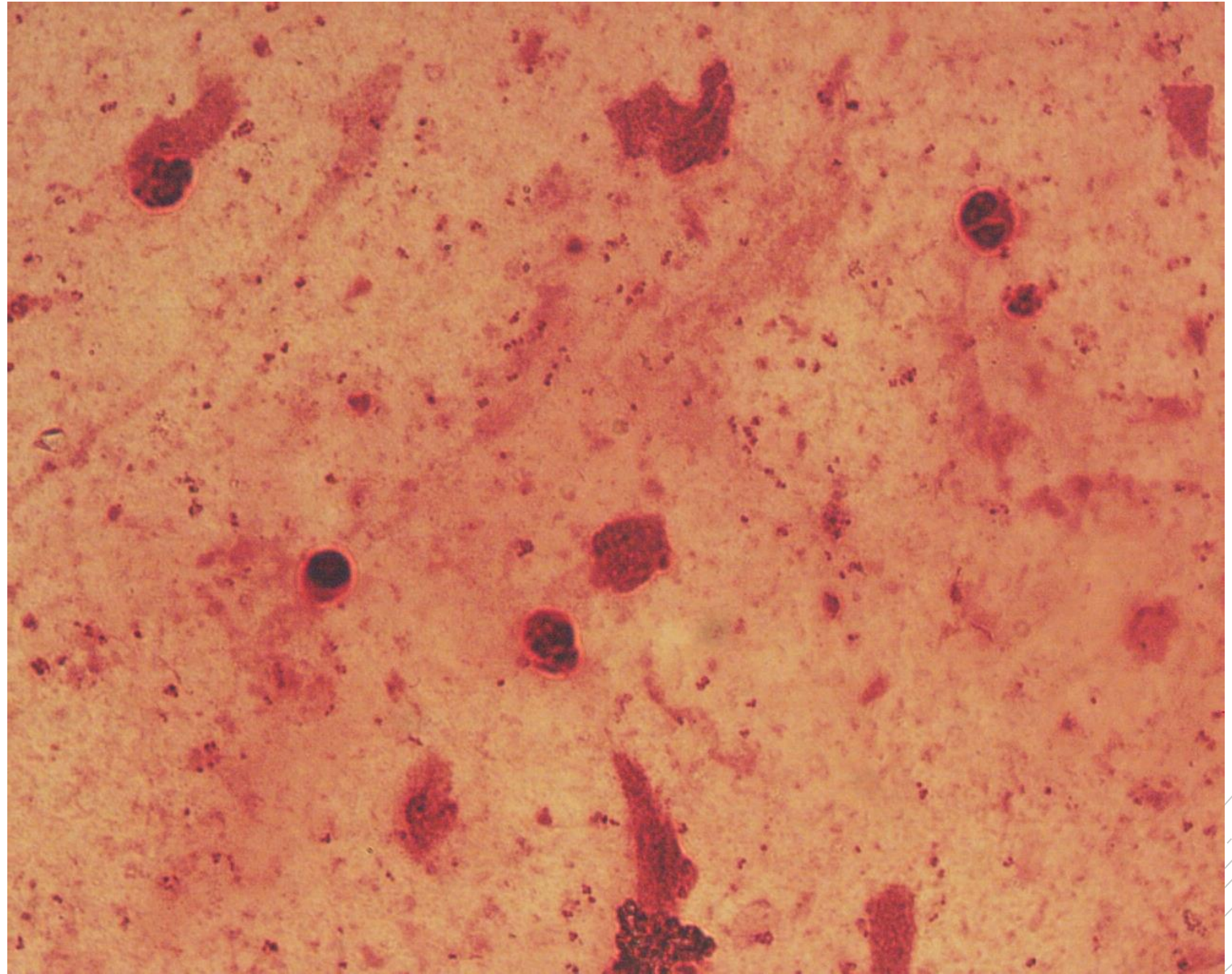
# *Neisseria meningitidis*

**Specimen:** CSF

**Patient:** male, 25 years old

**Dg.:** purulent meningitis

**Microscopy:** Gram-negative diplococci



Author: MUDr. Alena Pířová





CHARLES UNIVERSITY  
Second Faculty of Medicine

Slide No. 40

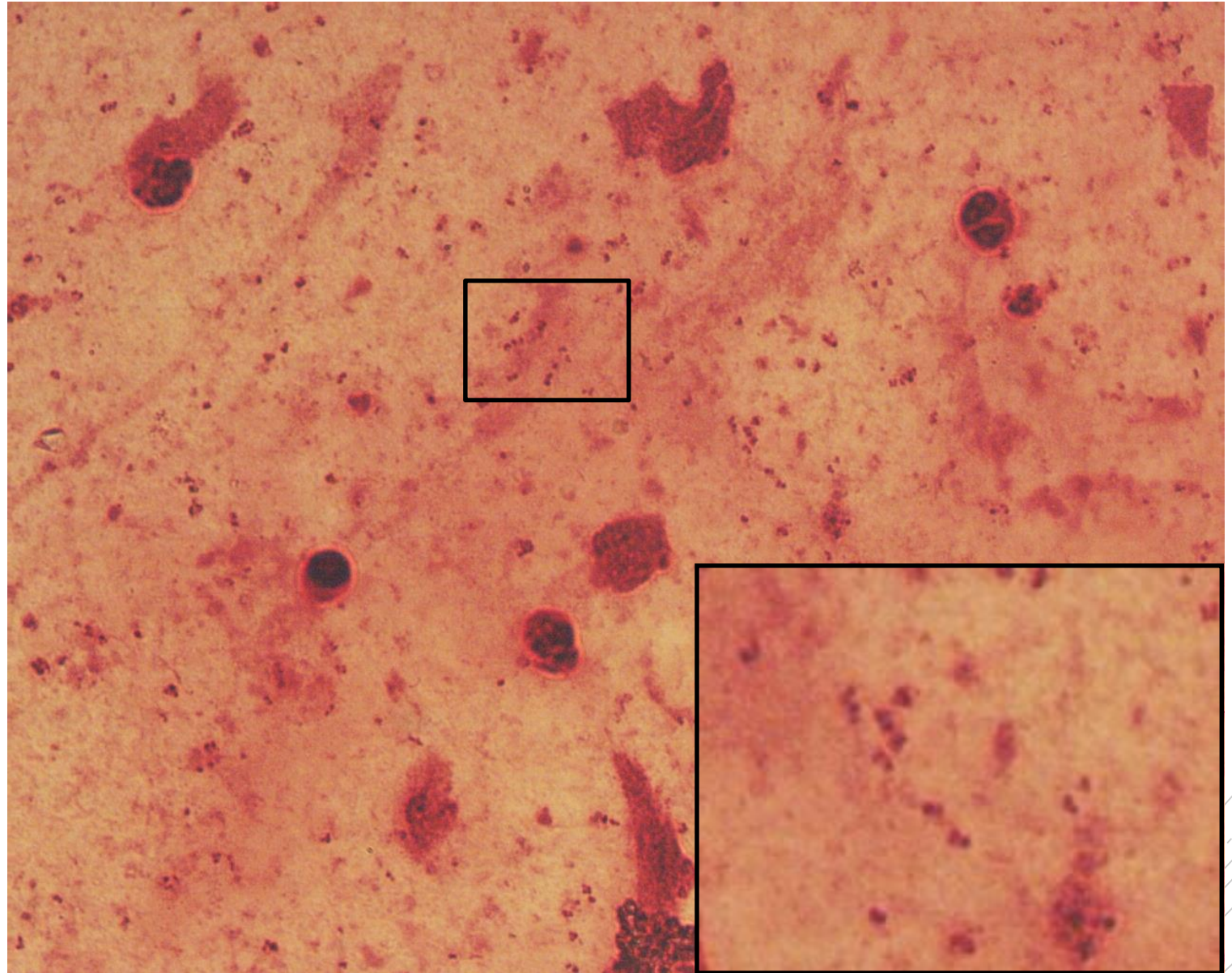
# *Neisseria meningitidis*

**Specimen:** CSF

**Patient:** male, 25 years old

**Dg.:** purulent meningitis

**Microscopy:** Gram-negative diplococci



Author: MUDr. Alena Pířová



CHARLES UNIVERSITY  
Second Faculty of Medicine

Slide No. 41

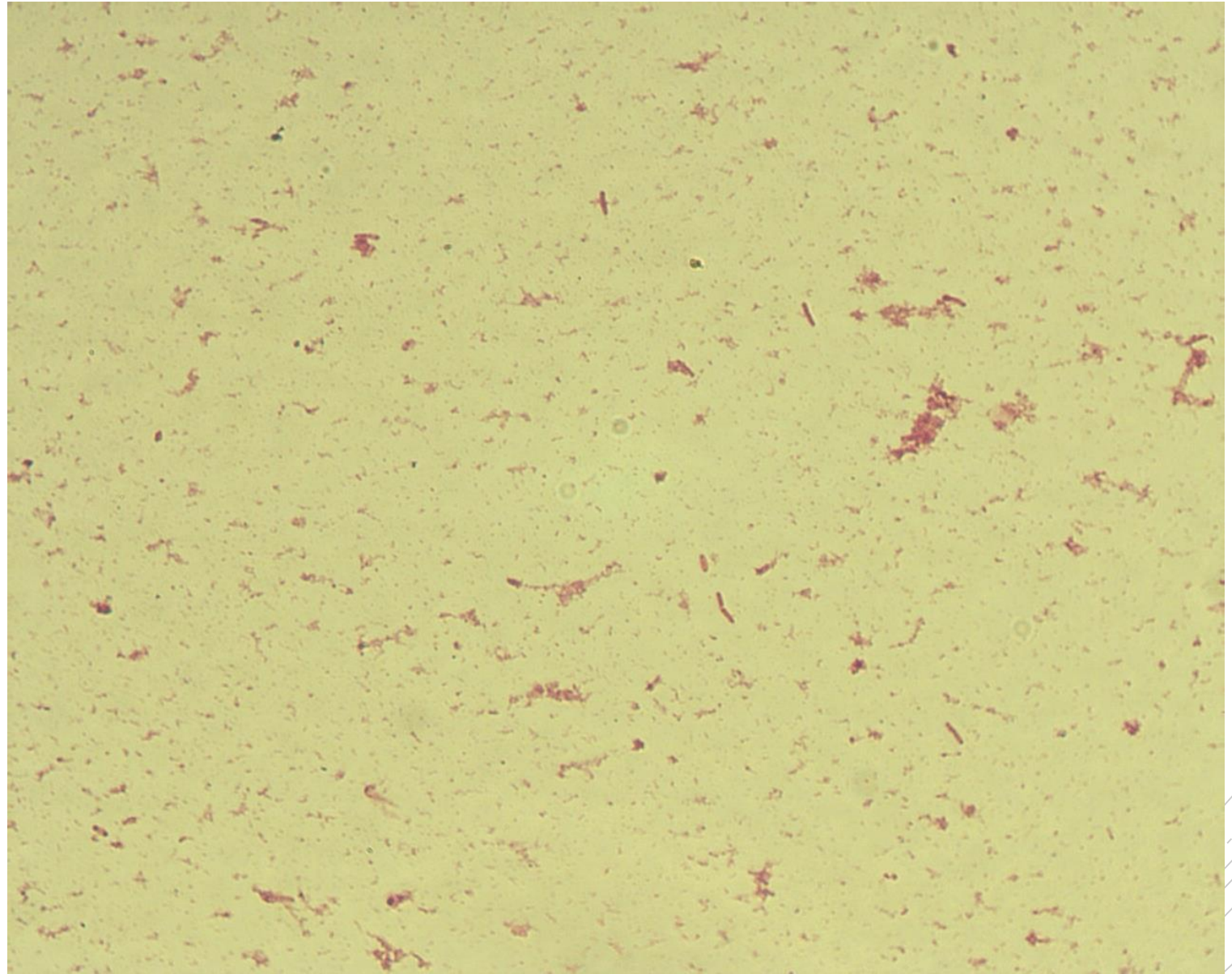
# *Salmonella* Typhi

**Specimen:** blood culture

**Patient:** male, 25 years old

**Dg.:** typhoid fever

**Microscopy:** Gram-negative rods



Authors: MUDr. Petra Kabelíková, Sandra Opálková



CHARLES UNIVERSITY  
Second Faculty of Medicine

Slide No. 41

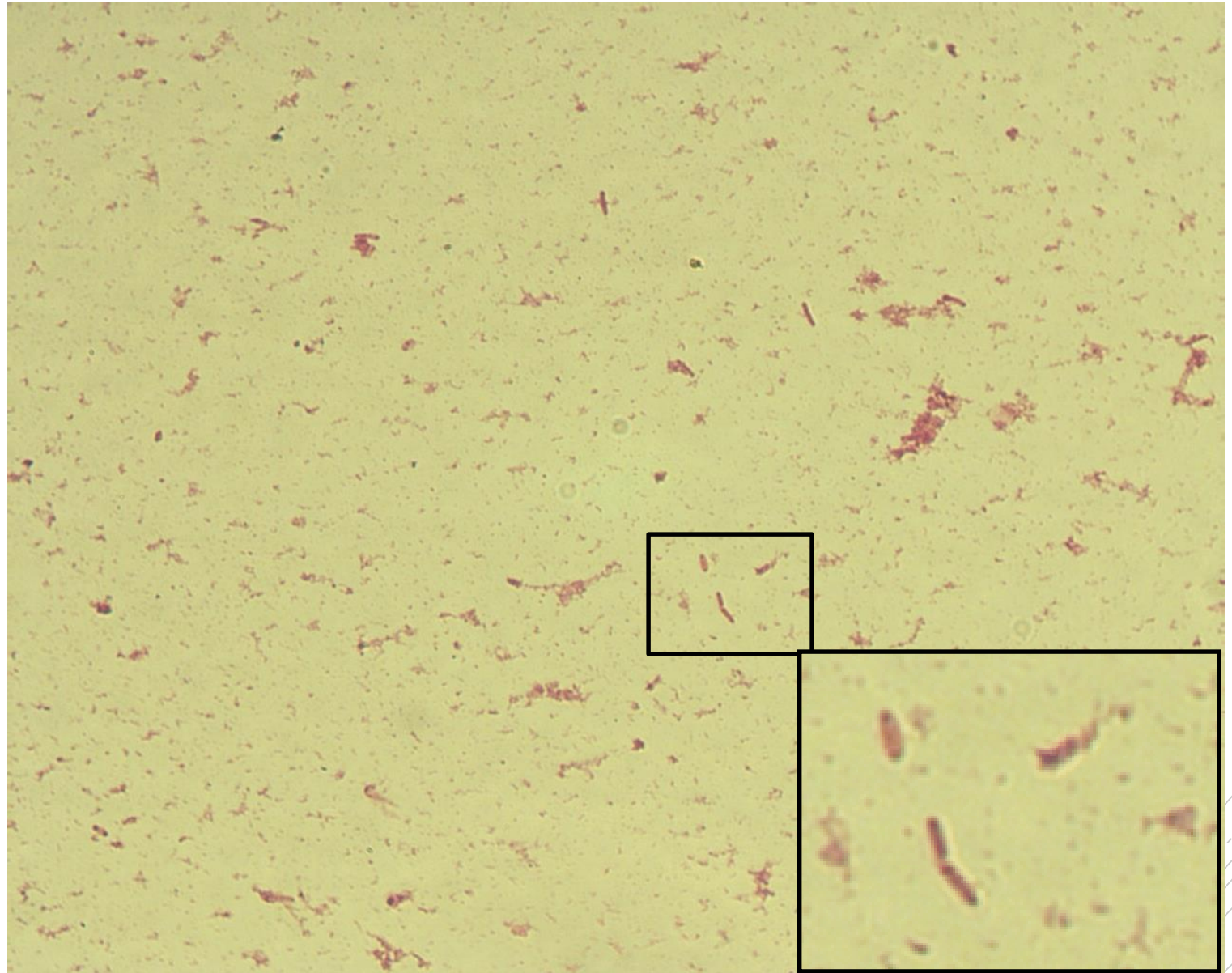
# *Salmonella* Typhi

**Specimen:** blood culture

**Patient:** male, 25 years old

**Dg.:** typhoid fever

**Microscopy:** Gram-negative rods



Authors: MUDr. Petra Kabelíková, Sandra Opálková



CHARLES UNIVERSITY  
Second Faculty of Medicine

Slide No. 42

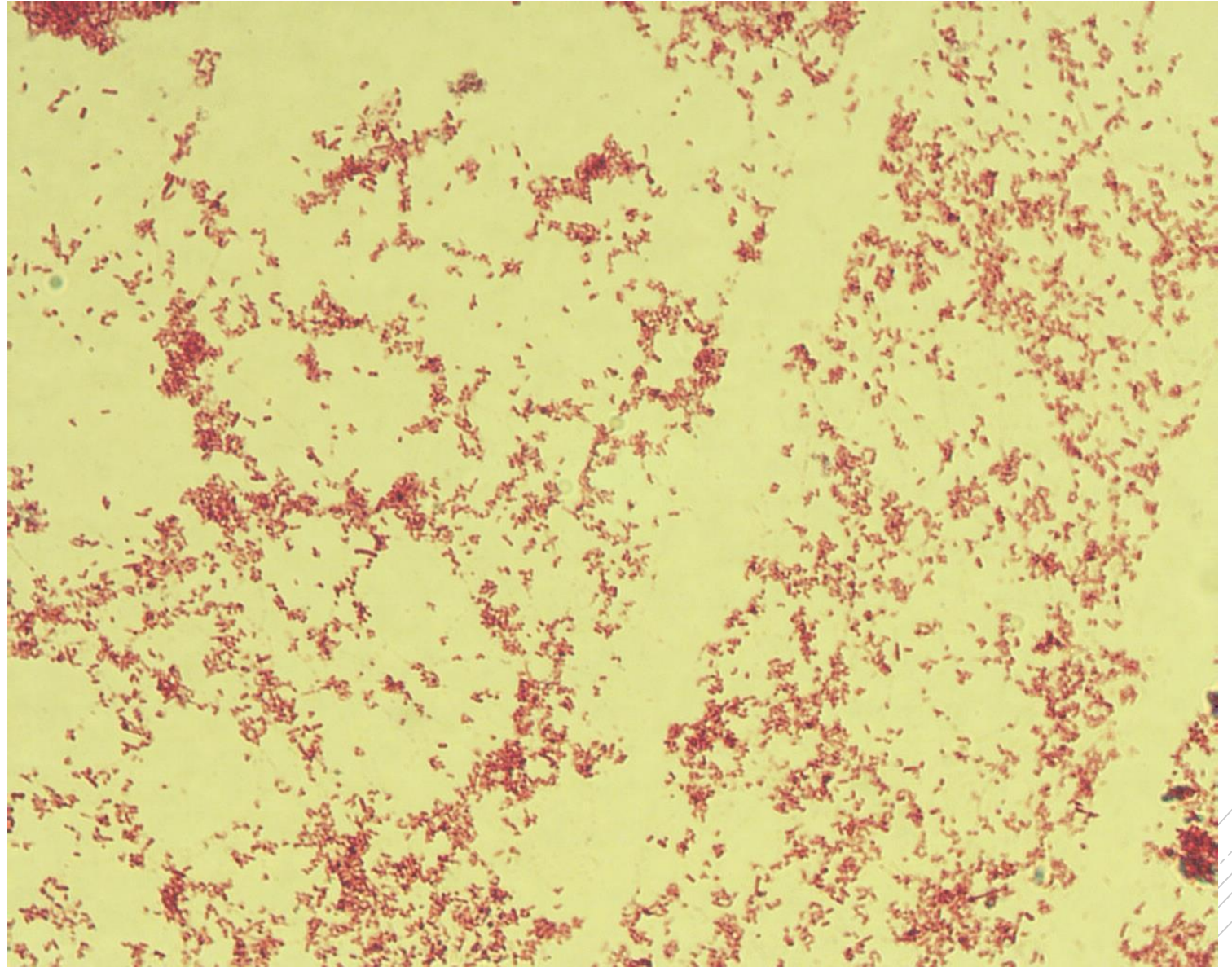
# *Salmonella* Typhi

**Specimen:** culture - stools

**Patient:** male, 32 years old

**Dg.:** typhoid fever

**Microscopy:** Gram-negative rods



Author: MUDr. Lenka Tritová



CHARLES UNIVERSITY  
Second Faculty of Medicine

Slide No. 42

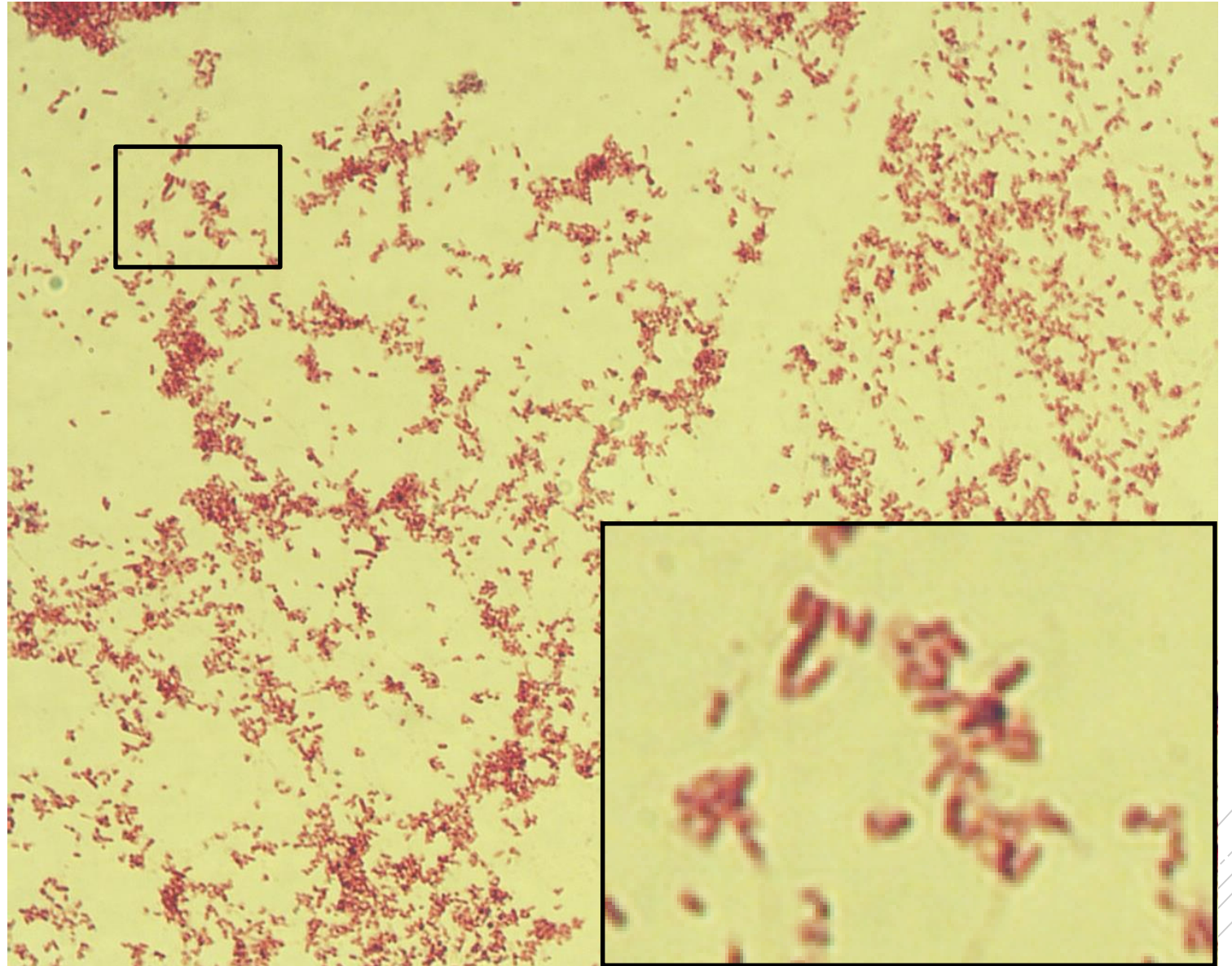
# *Salmonella* Typhi

**Specimen:** culture - stools

**Patient:** male, 32 years old

**Dg.:** typhoid fever

**Microscopy:** Gram-negative rods



Author: MUDr. Lenka Tritová



CHARLES UNIVERSITY  
Second Faculty of Medicine

Slide No. 43

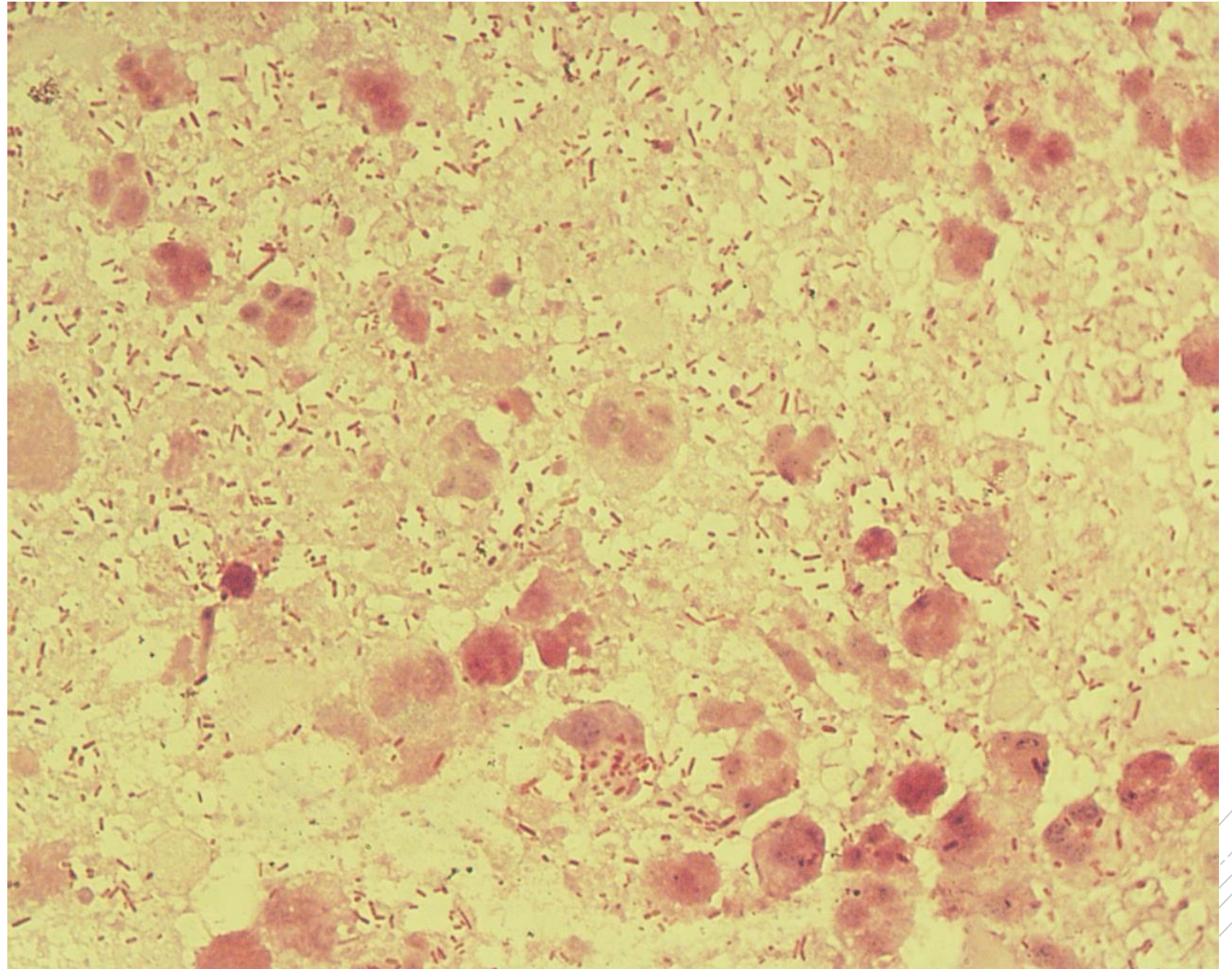
# *Escherichia coli*

**Specimen:** abdominal fluid

**Patient:** female, 43 years old

**Dg.:** peritonitis

**Microscopy:** Gram-negative rods



Author: MUDr. Alena Píšová



CHARLES UNIVERSITY  
Second Faculty of Medicine

Slide No. 43

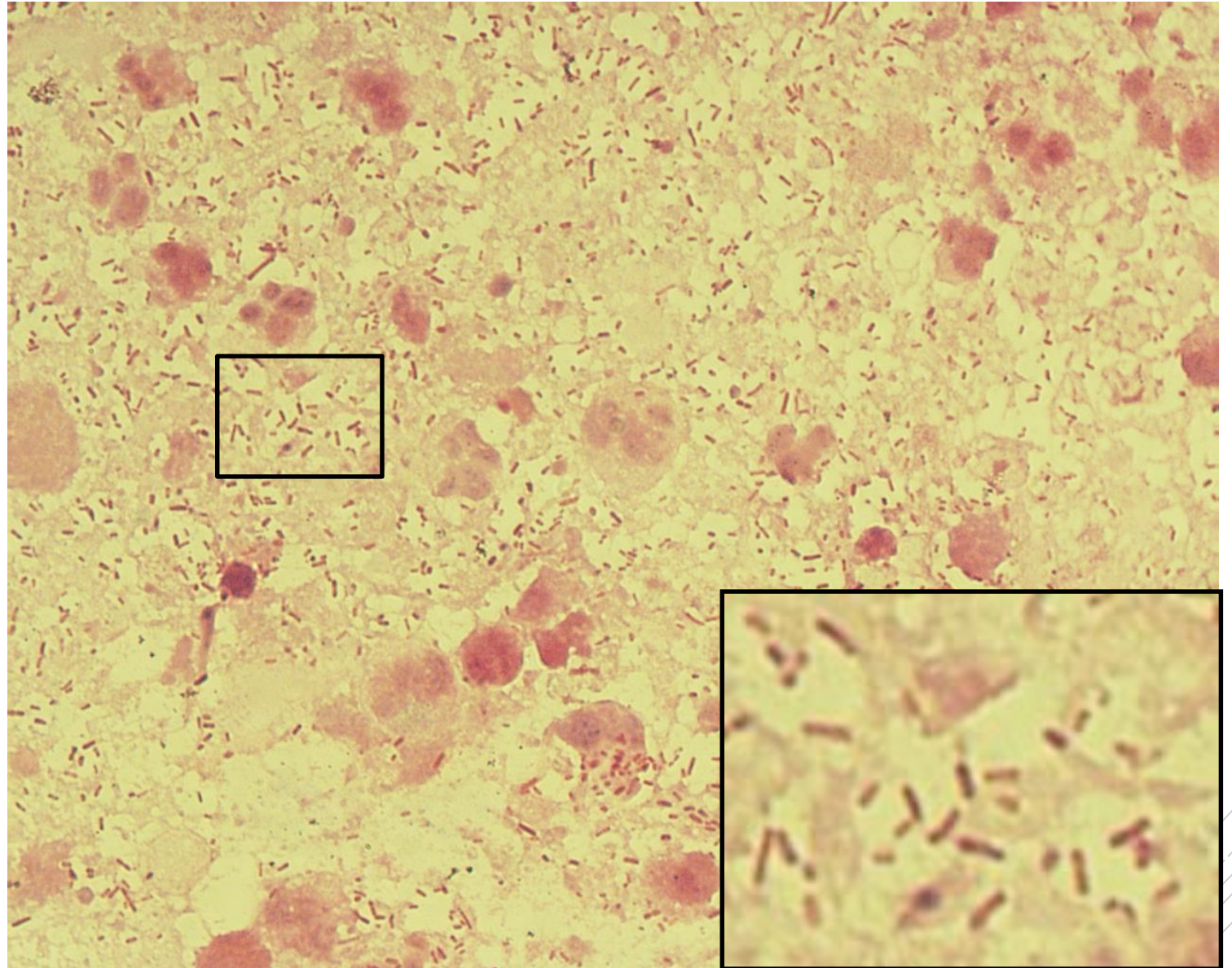
# *Escherichia coli*

**Specimen:** abdominal fluid

**Patient:** female, 43 years old

**Dg.:** peritonitis

**Microscopy:** Gram-negative rods



Author: MUDr. Alena Pířová



CHARLES UNIVERSITY  
Second Faculty of Medicine

Slide No. 44

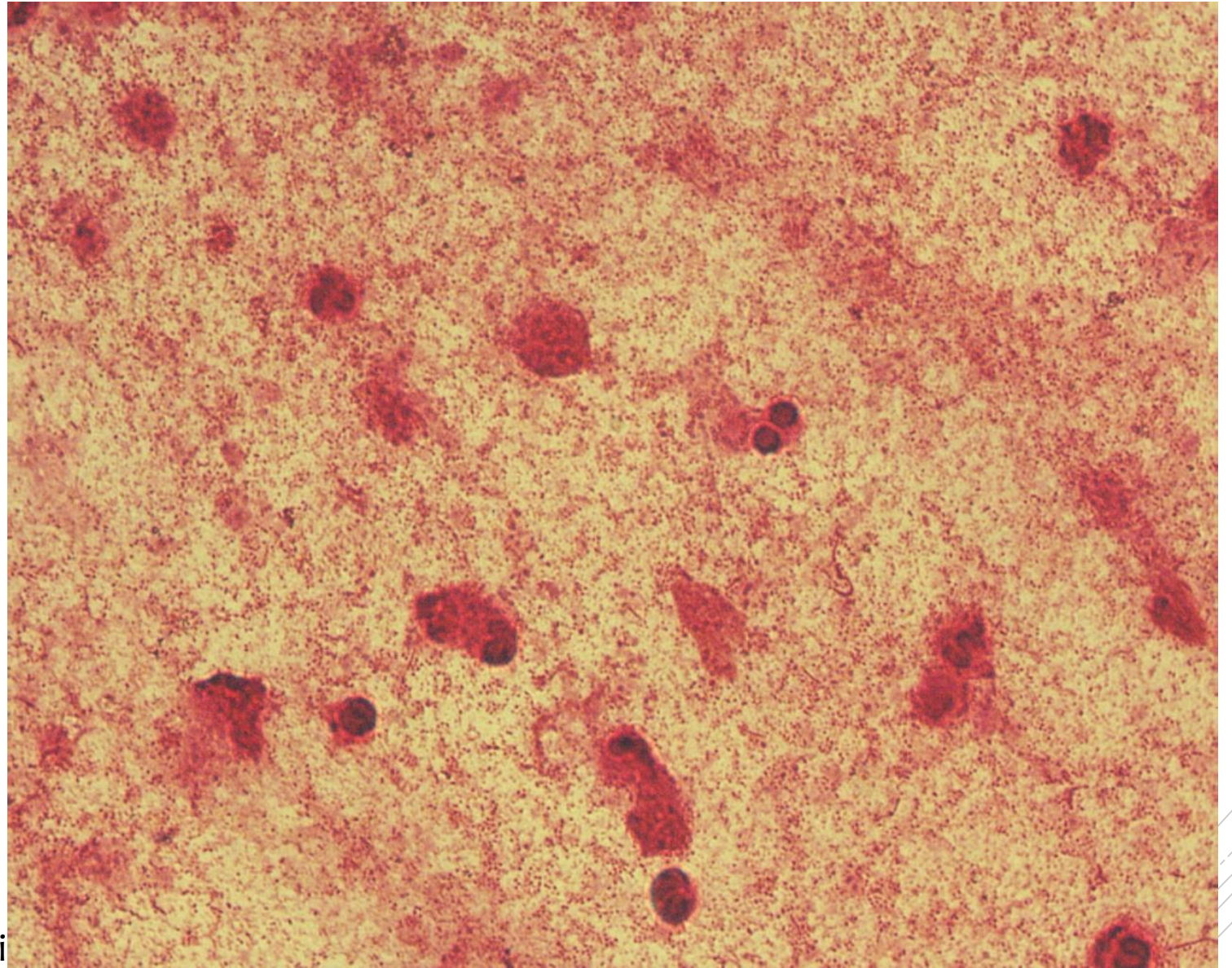
# *Pasteurella multocida*

**Specimen:** sputum

**Patient:** male, 53 years old

**Dg.:** pneumonia

**Microscopy:** Gram-negative coccobacilli



Author: MUDr. Daniela Lžičarová





CHARLES UNIVERSITY  
Second Faculty of Medicine

Slide No. 44

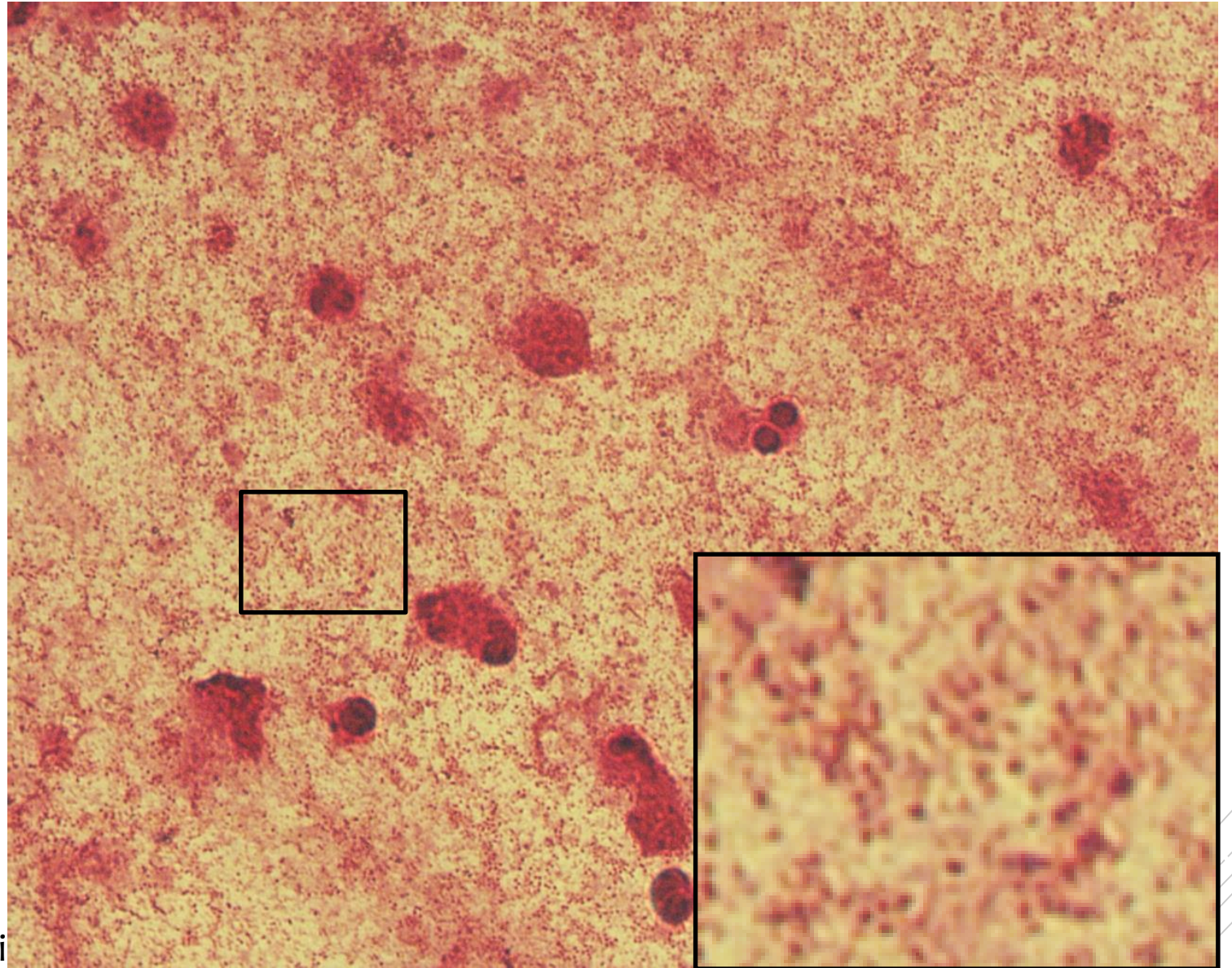
# *Pasteurella multocida*

**Specimen:** sputum

**Patient:** male, 53 years old

**Dg.:** pneumonia

**Microscopy:** Gram-negative coccobacilli



Author: MUDr. Daniela Lžičarová



CHARLES UNIVERSITY  
Second Faculty of Medicine

Slide No. 45

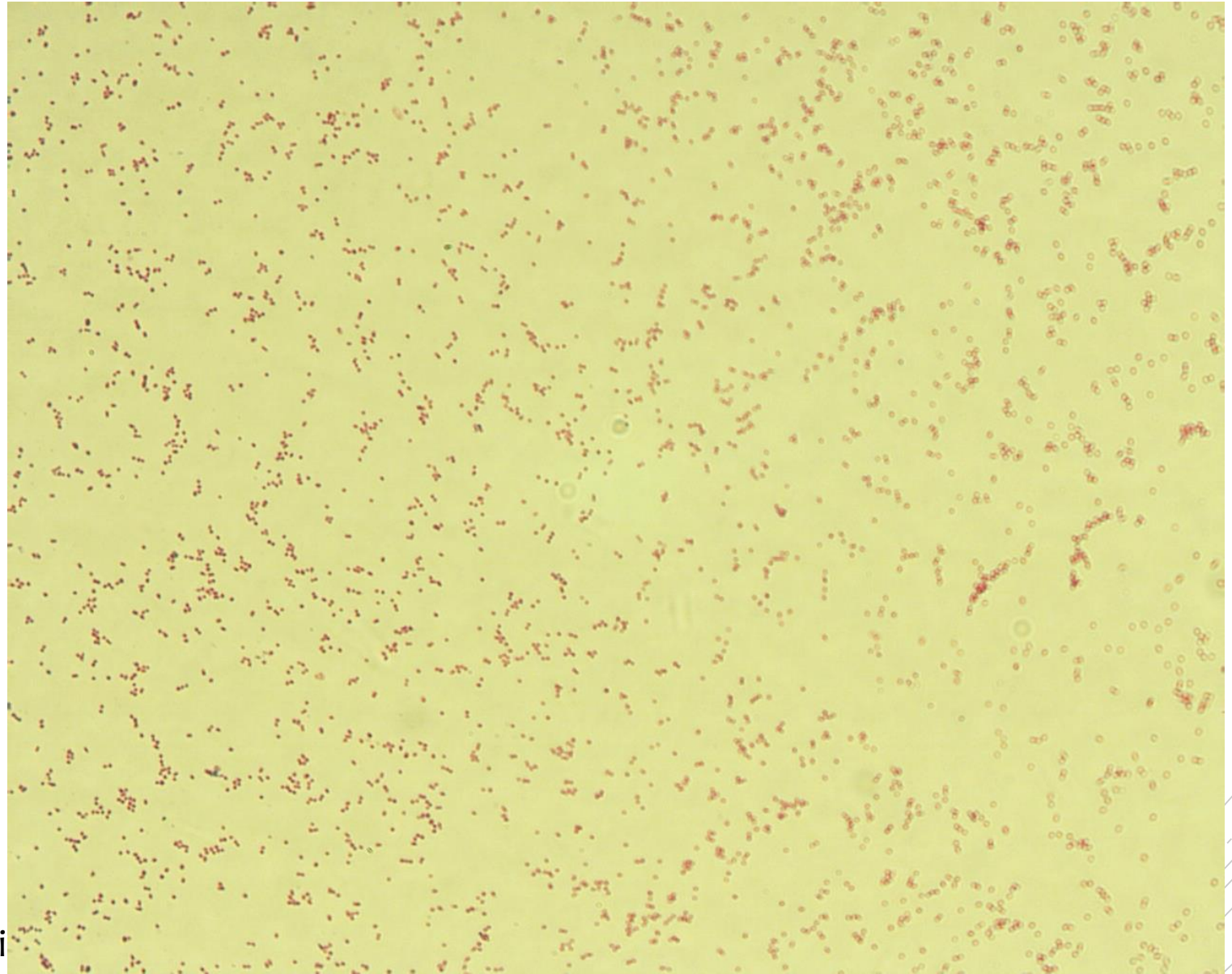
# *Pasteurella multocida*

**Specimen:** culture - sputum

**Patient:** male, 53 years old

**Dg.:** pneumonia

**Microscopy:** Gram-negative coccobacilli



Author: MUDr. Daniela Lžičarová



CHARLES UNIVERSITY  
Second Faculty of Medicine

Slide No. 45


# *Pasteurella multocida*

**Specimen:** culture - sputum

**Patient:** male, 53 years old

**Dg.:** pneumonia

**Microscopy:** Gram-negative coccobacilli



Author: MUDr. Daniela Lžičarová



CHARLES UNIVERSITY  
Second Faculty of Medicine

Slide No. 46

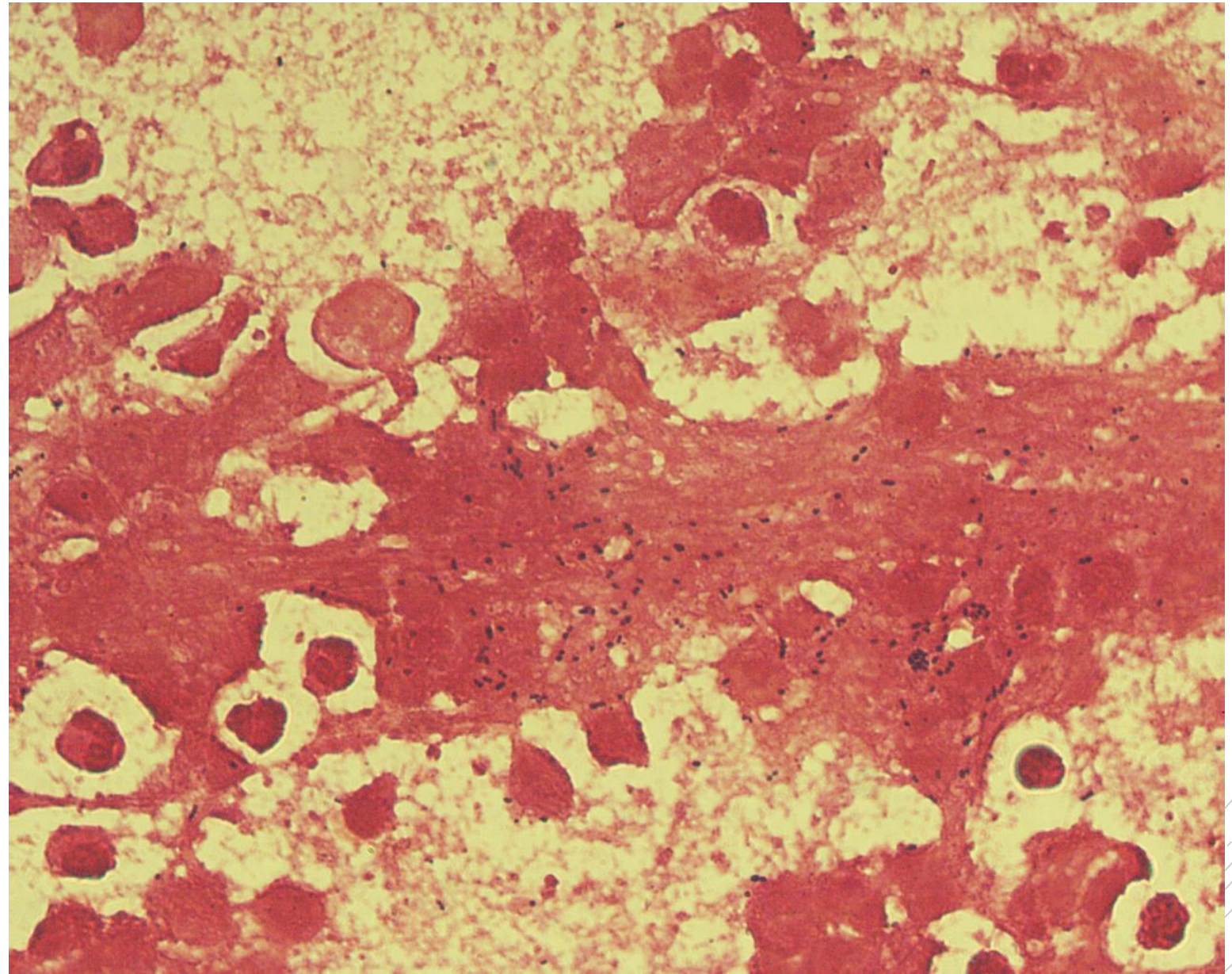
# *Streptococcus constellatus*

**Specimen:** Pus

**Patient:** male, 65 years old

**Dg.:** liver abscess

**Microscopy:** Gram-positive cocci



Author: MUDr. Alena Píšová



CHARLES UNIVERSITY  
Second Faculty of Medicine

Slide No. 46

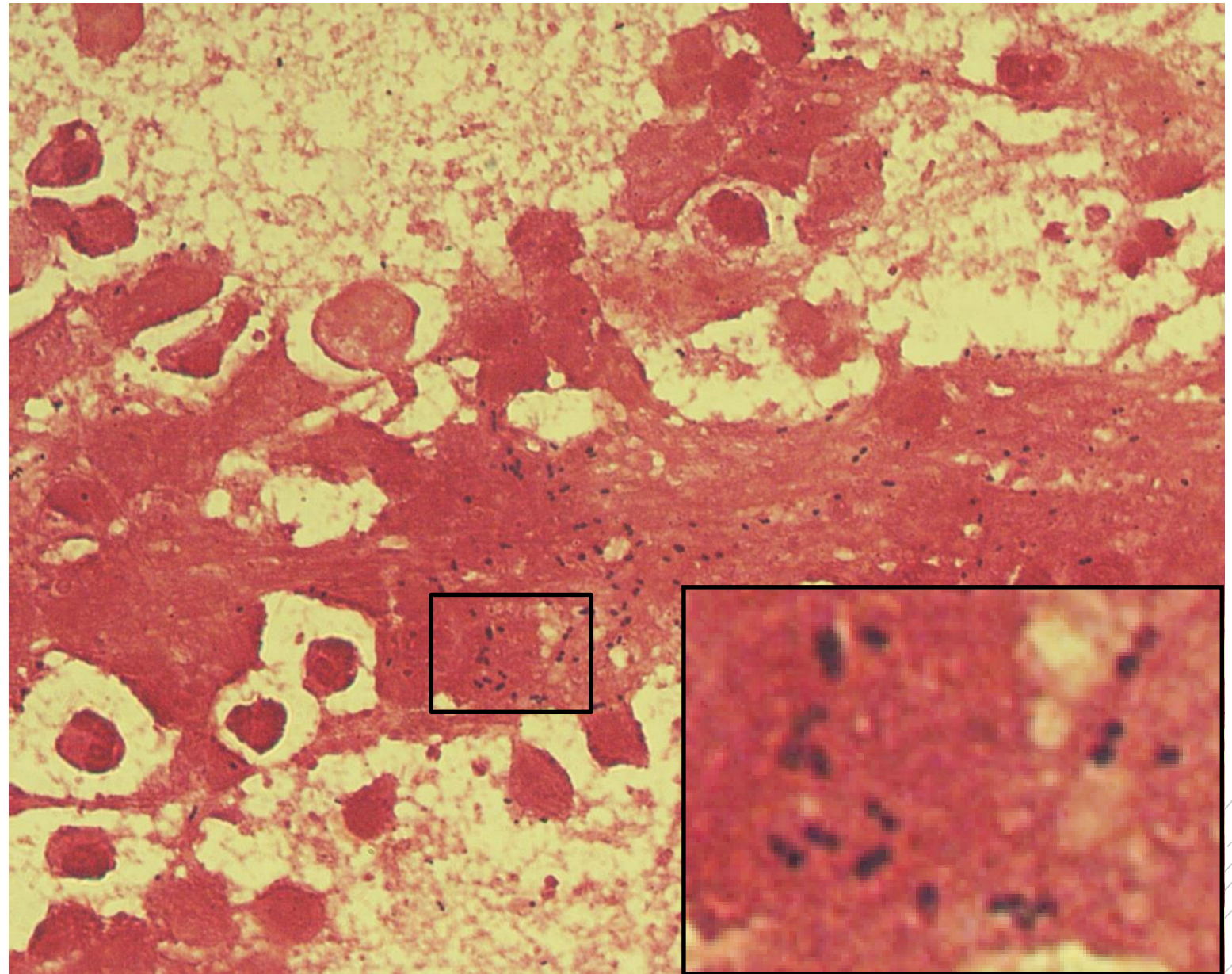
# *Streptococcus constellatus*

**Specimen:** Pus

**Patient:** male, 65 years old

**Dg.:** liver abscess

**Microscopy:** Gram-positive cocci



Author: MUDr. Alena Pířová



CHARLES UNIVERSITY  
Second Faculty of Medicine

Slide No. 47

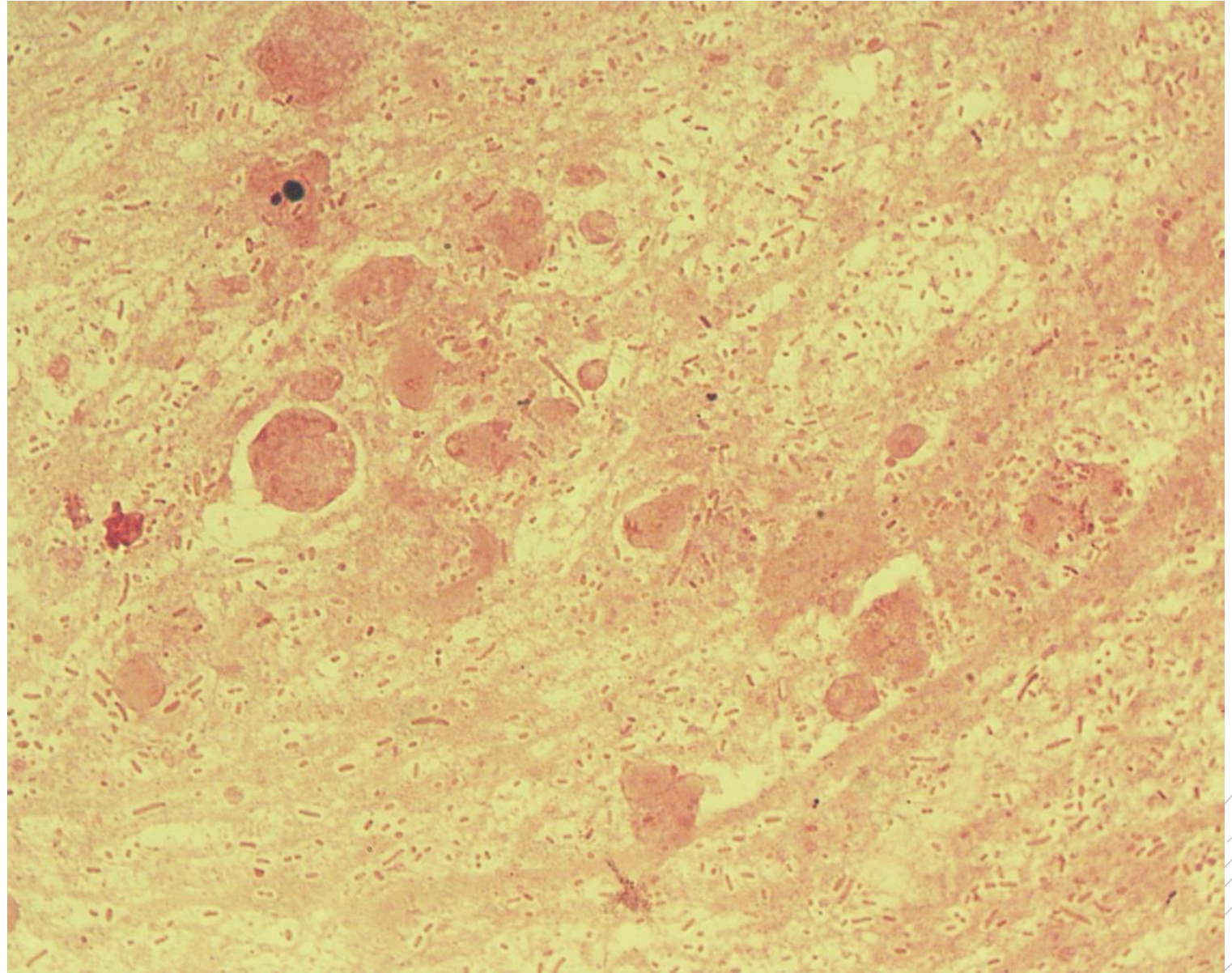
# *Klebsiella pneumoniae*

**Specimen:** sputum

**Patient:** female, 85 years old

**Dg.:** pneumonia

**Microscopy:** Gram-negative rods



Author: MUDr. Vanda Chrenková



CHARLES UNIVERSITY  
Second Faculty of Medicine

Slide No. 47

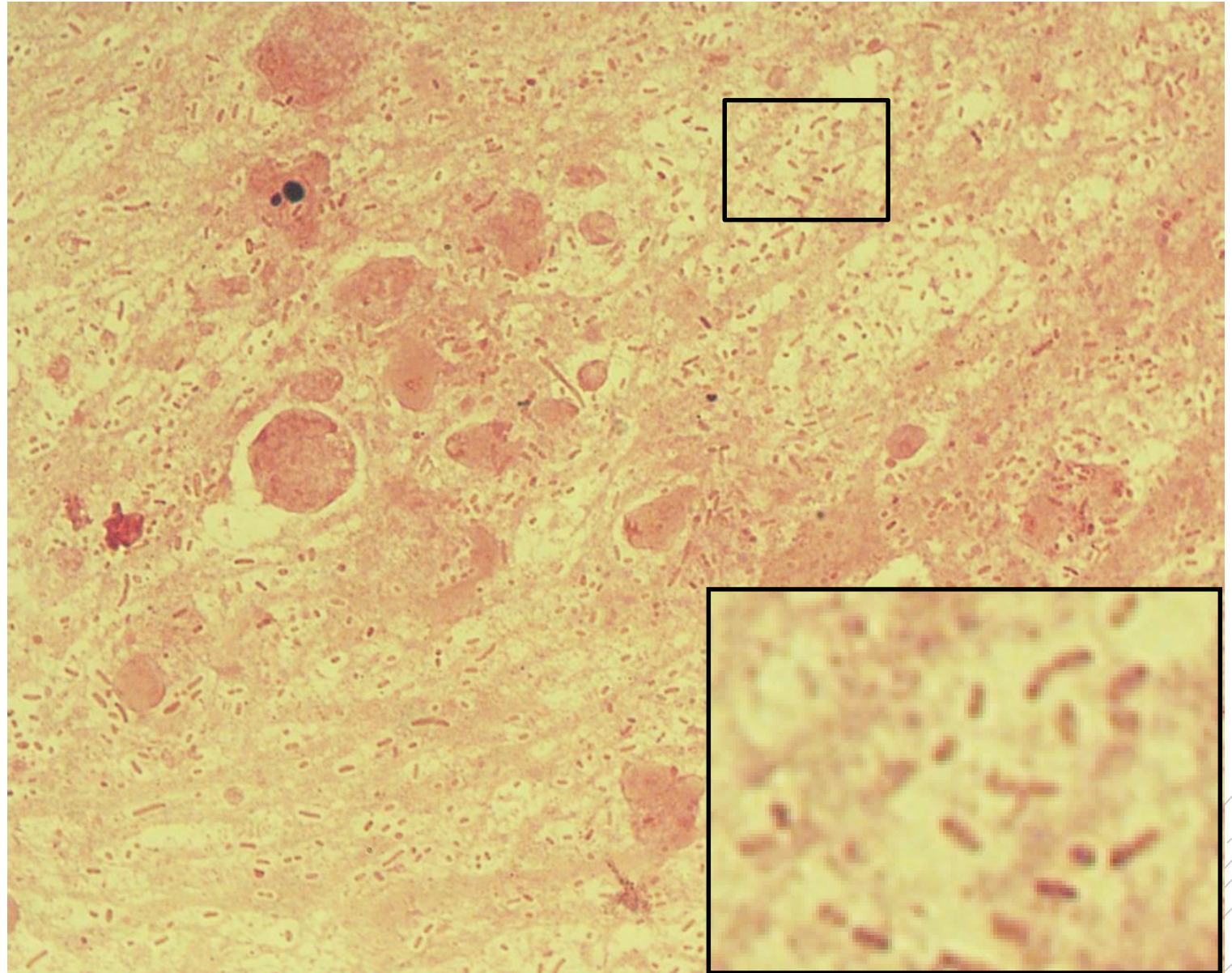
# *Klebsiella pneumoniae*

**Specimen:** sputum

**Patient:** female, 85 years old

**Dg.:** pneumonia

**Microscopy:** Gram-negative rods



Author: MUDr. Vanda Chrenková



CHARLES UNIVERSITY  
Second Faculty of Medicine

Slide No. 48

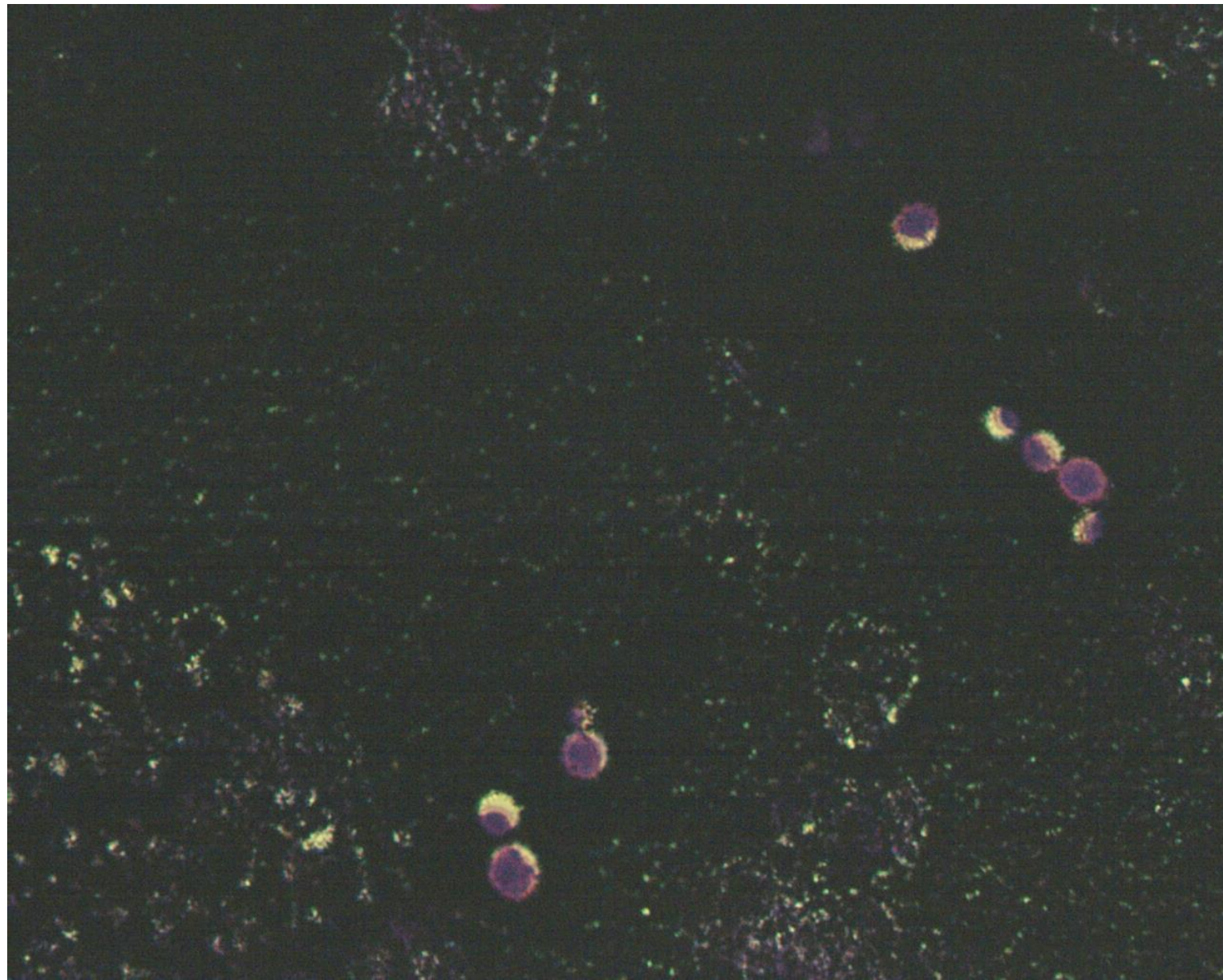
# *Cryptococcus neoformans*

**Specimen:** blood culture

**Patient:** male, 37 years old

**Dg.:** meningitis in HIV/AIDS

**Microscopy:** capsules in Burri stain



Authors: Markéta Šolarová, Hana Nekvasilová





CHARLES UNIVERSITY  
Second Faculty of Medicine

Slide No. 48

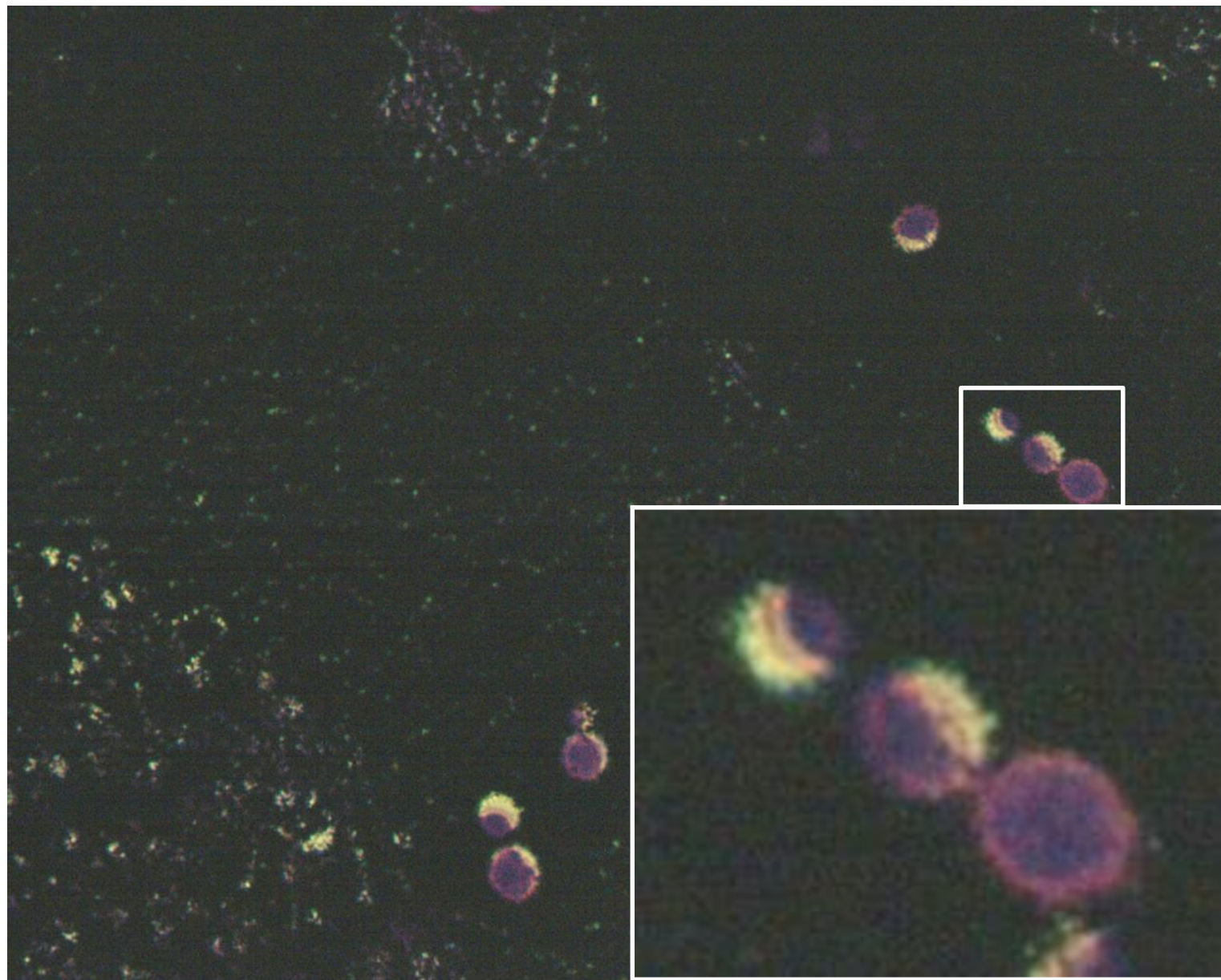
# *Cryptococcus neoformans*

**Specimen:** blood culture

**Patient:** male, 37 years old

**Dg.:** meningitis in HIV/AIDS

**Microscopy:** capsules in Burri stain



Authors: Markéta Šolarová, Hana Nekvasilová



CHARLES UNIVERSITY  
Second Faculty of Medicine

Slide No. 49

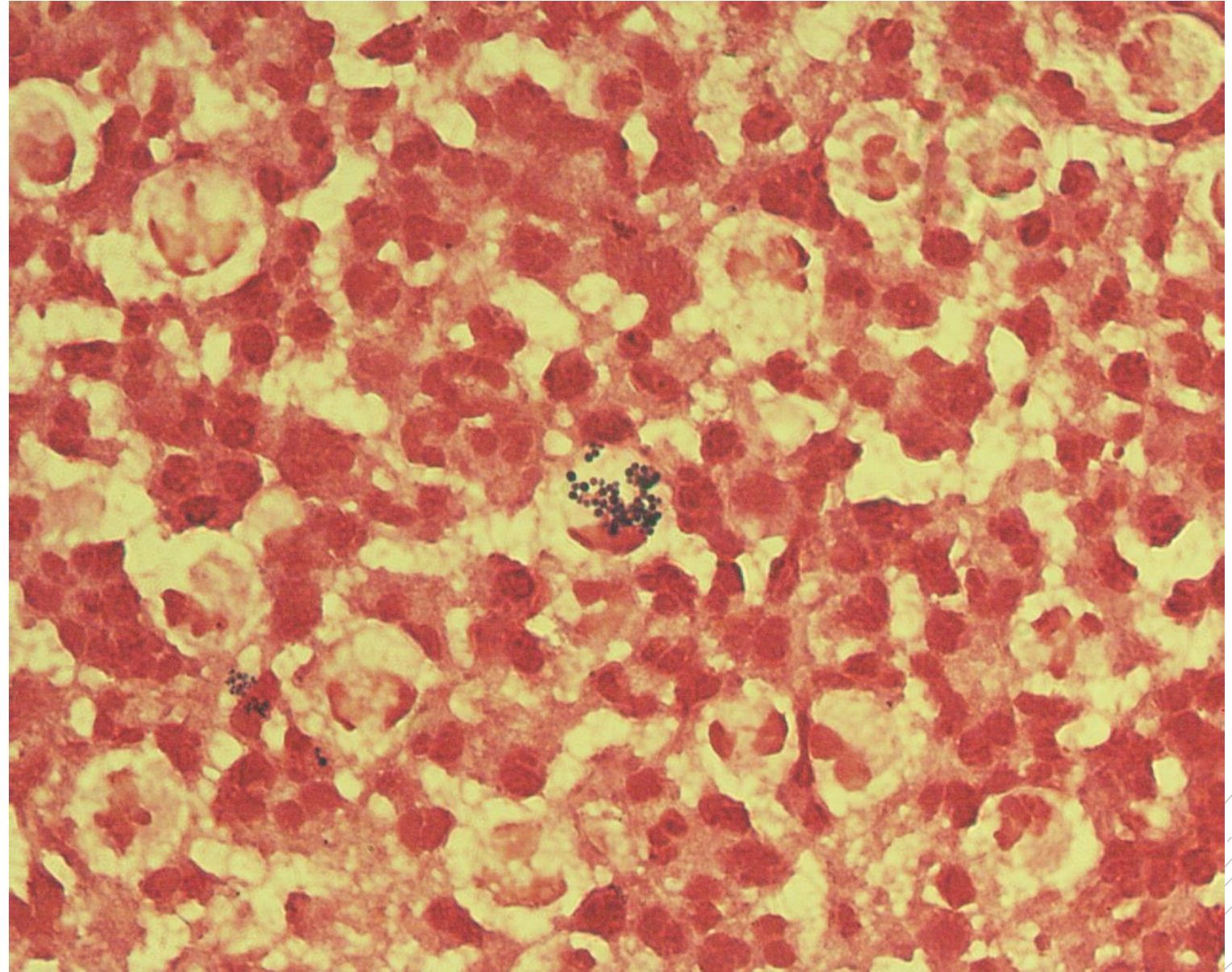
# *Staphylococcus aureus*

**Specimen:** Pus/wound

**Patient:** female, 1 year old

**Dg.:** face lymph node inflammation

**Microscopy:** Gram-positive cocci  
in clusters



Authors: MUDr. Petra Kabelíková, Sandra Opálková



CHARLES UNIVERSITY  
Second Faculty of Medicine

Slide No. 49

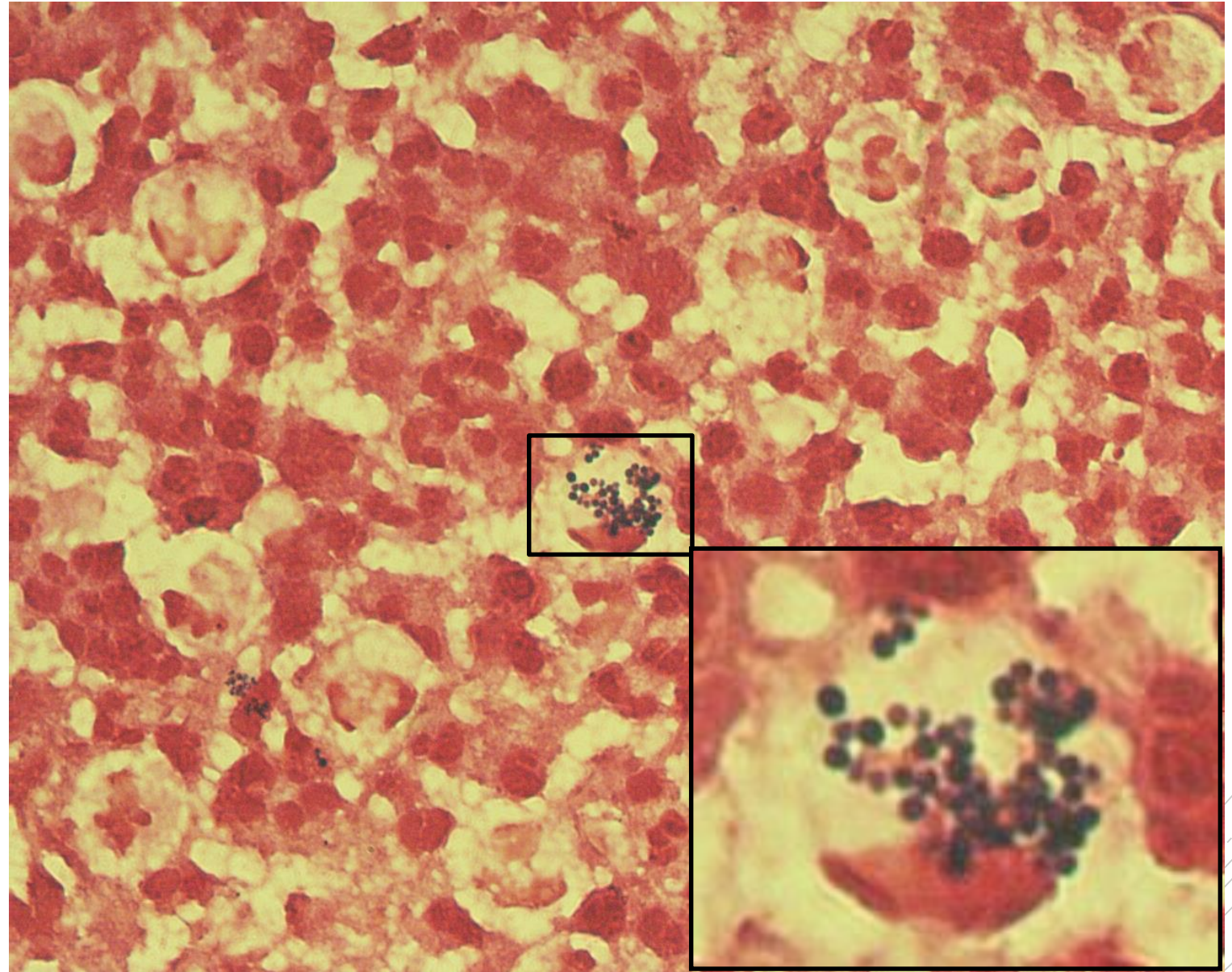
# *Staphylococcus aureus*

**Specimen:** Pus/wound

**Patient:** female, 1 year old

**Dg.:** face lymph node inflammation

**Microscopy:** Gram-positive cocci  
in clusters



Authors: MUDr. Petra Kabelíková, Sandra Opálková



CHARLES UNIVERSITY  
Second Faculty of Medicine

Slide No. 50

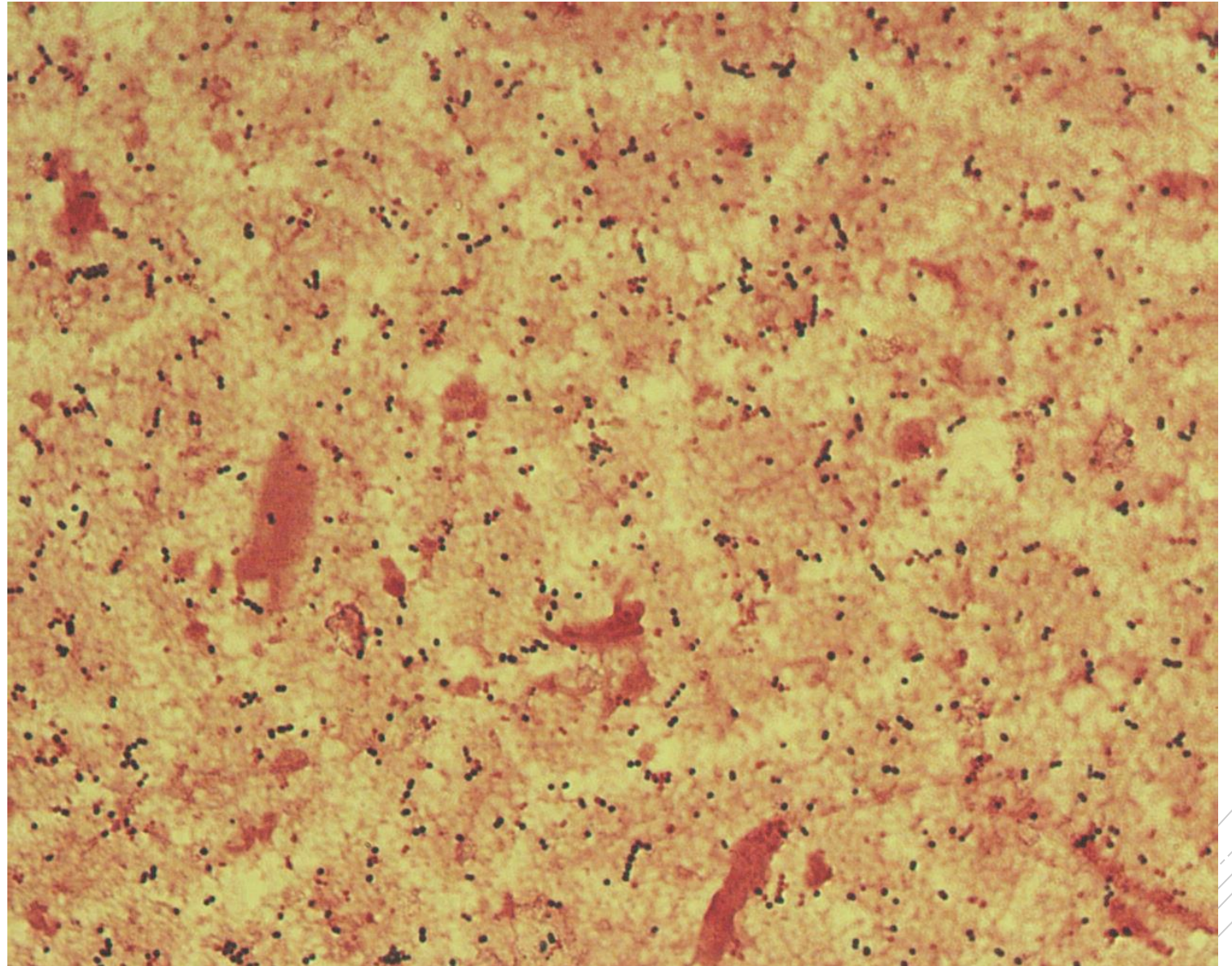
# *Streptococcus pyogenes*

**Specimen:** muscle

**Patient:** male, 63 years old

**Dg.:** necrotizing fasciitis

**Microscopy:** Gram-positive cocci  
in chains



Author: MUDr. Alena Pířová



CHARLES UNIVERSITY  
Second Faculty of Medicine

Slide No. 50

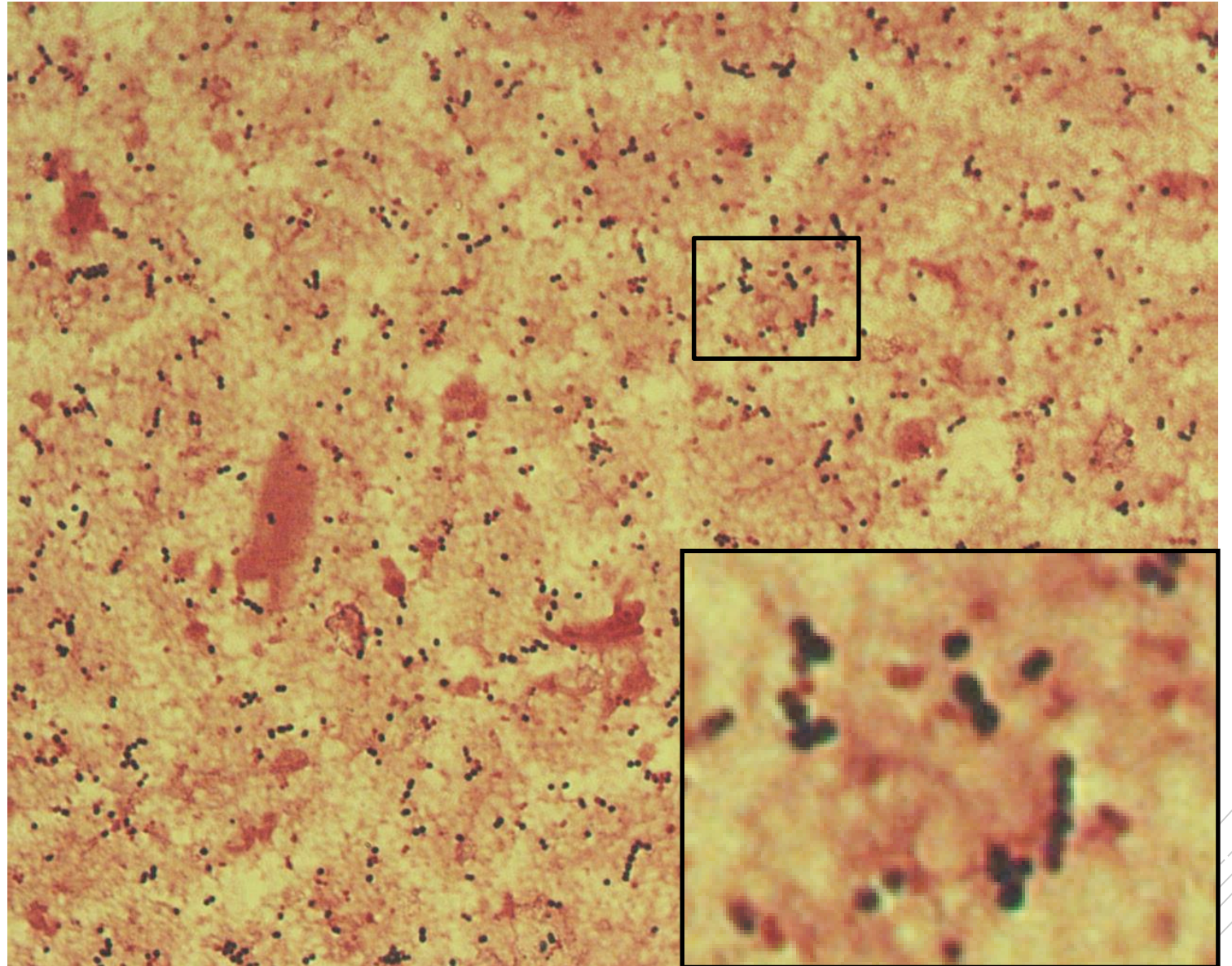
# *Streptococcus pyogenes*

**Specimen:** muscle

**Patient:** male, 63 years old

**Dg.:** necrotizing fasciitis

**Microscopy:** Gram-positive cocci  
in chains



Author: MUDr. Alena Pířová



CHARLES UNIVERSITY  
Second Faculty of Medicine

Slide No. 51

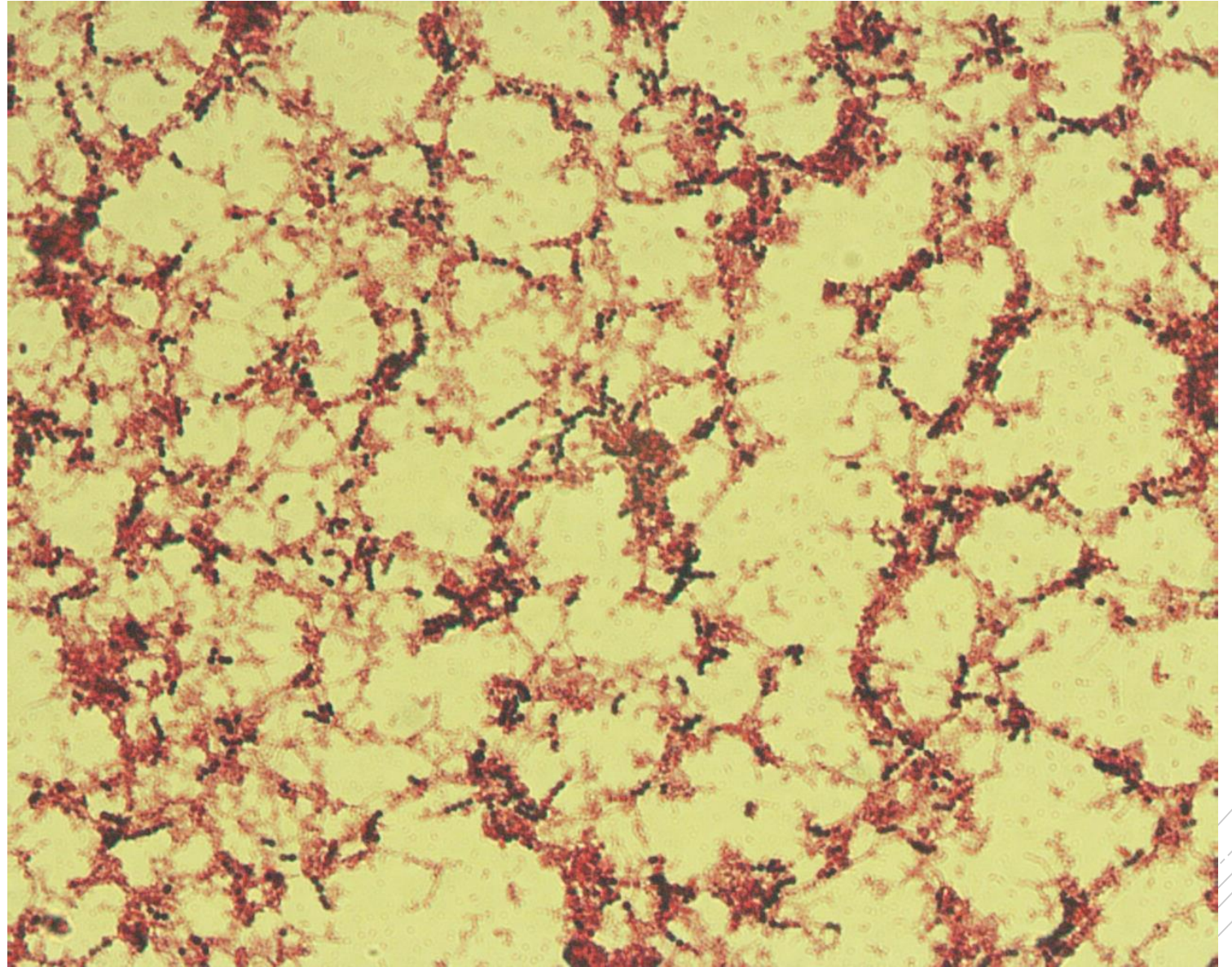
# *Streptococcus pyogenes*

**Specimen:** blood culture

**Patient:** male, 63 years old

**Dg.:** sepsis

**Microscopy:** Gram-positive cocci  
in chains



Authors: MUDr. Petra Kabelíková, Sandra Opálková



CHARLES UNIVERSITY  
Second Faculty of Medicine

Slide No. 51

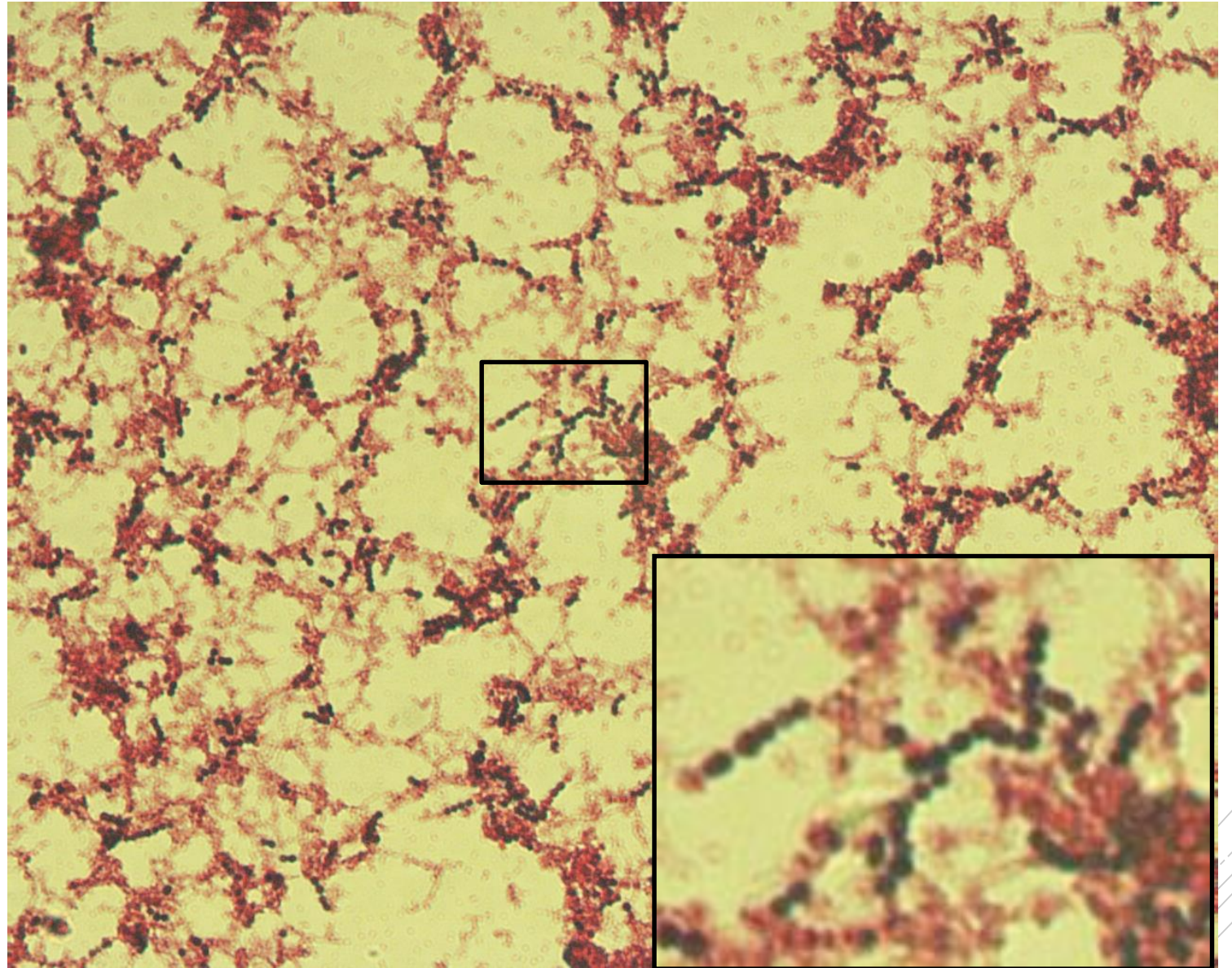
# *Streptococcus pyogenes*

**Specimen:** blood culture

**Patient:** male, 63 years old

**Dg.:** sepsis

**Microscopy:** Gram-positive cocci  
in chains



Authors: MUDr. Petra Kabelíková, Sandra Opálková



CHARLES UNIVERSITY  
Second Faculty of Medicine

Slide No. 52

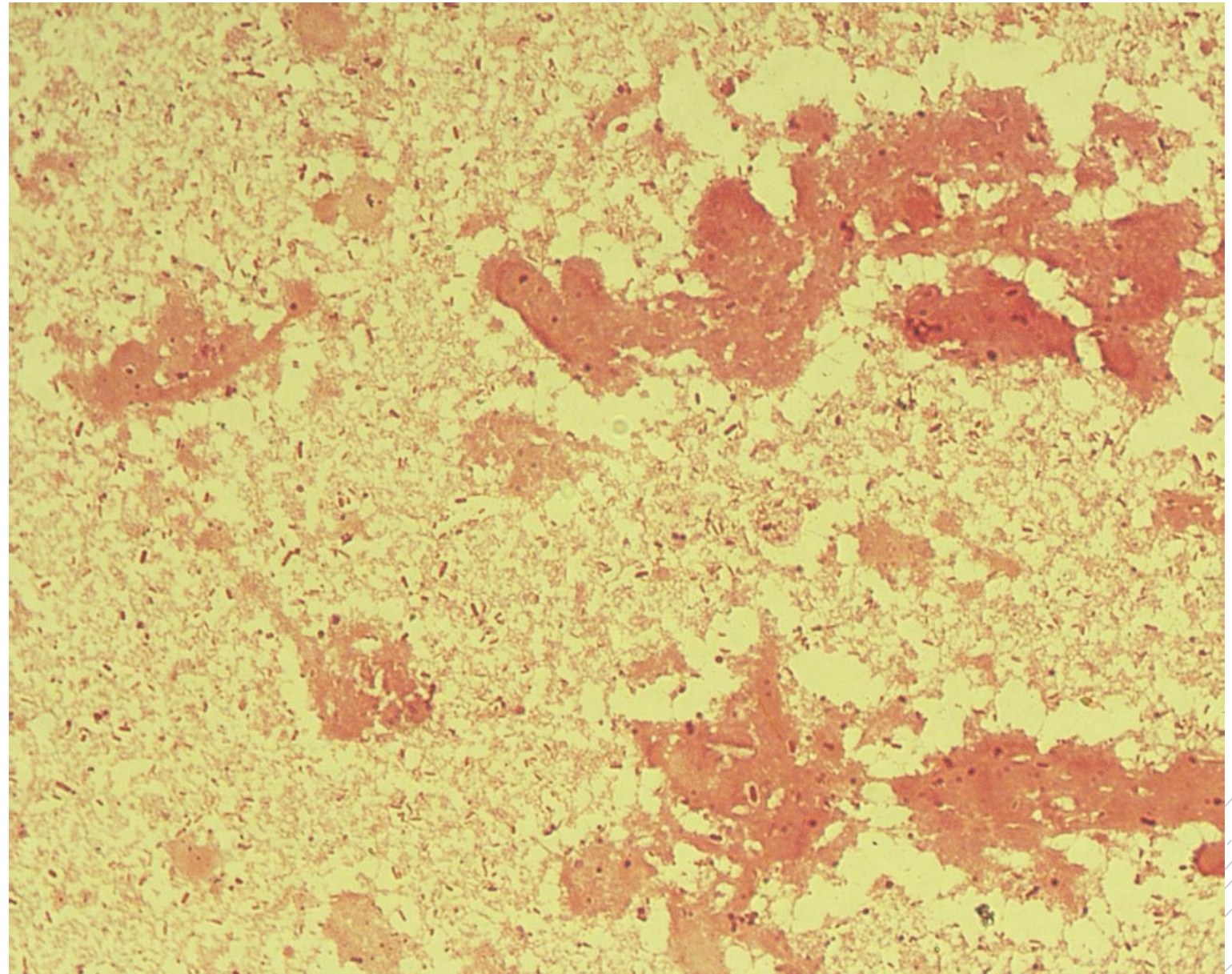
*Bacteroides fragilis*,  
*Klebsiella oxytoca*,  
*Escherichia coli*

**Specimen:** Pus

**Patient:** female, 44 years old

**Dg.:** liver abscess

**Microscopy:** Gram-negative rods



Author: MUDr. Alena Pířová





CHARLES UNIVERSITY  
Second Faculty of Medicine

Slide No. 52

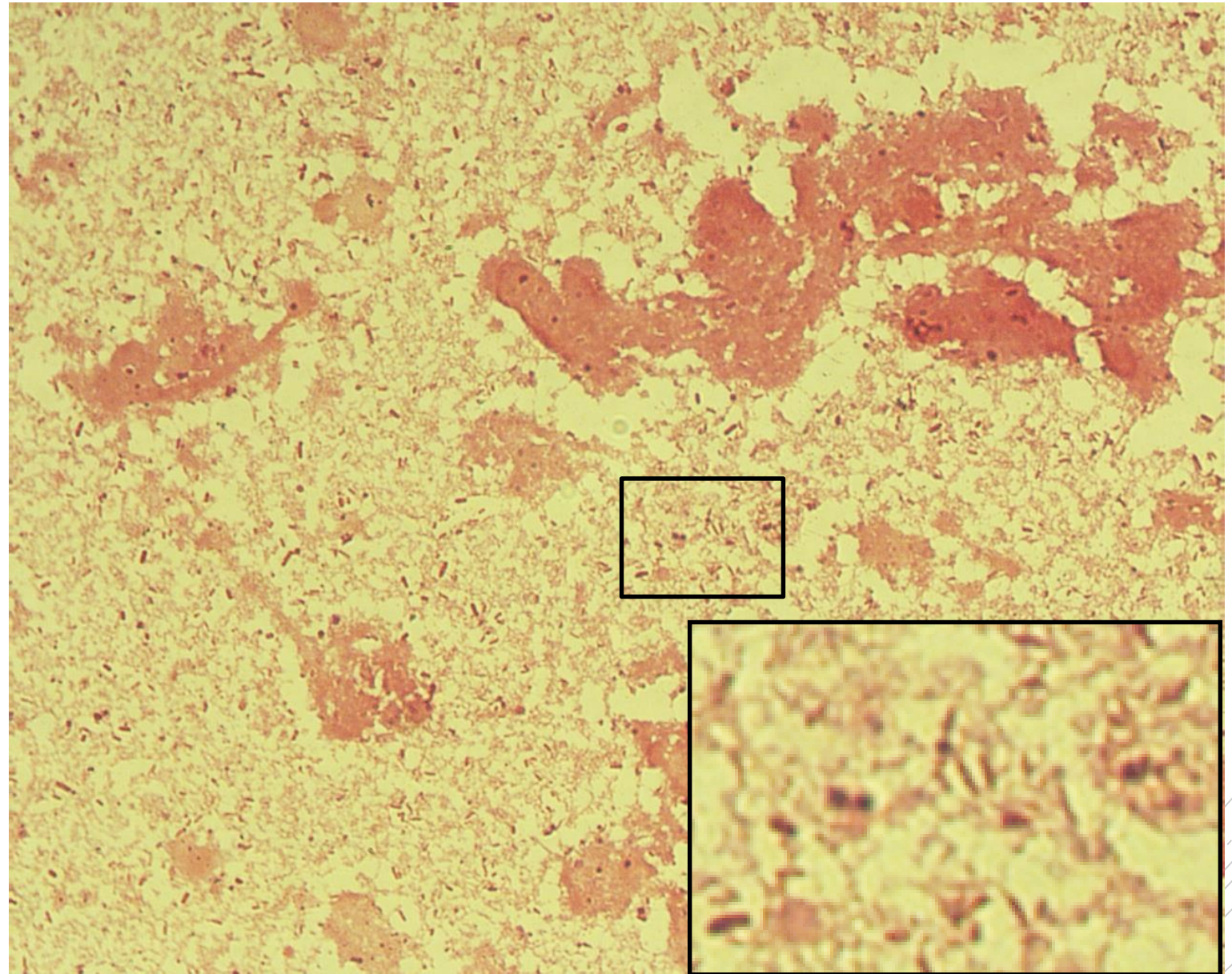
*Bacteroides fragilis*,  
*Klebsiella oxytoca*,  
*Escherichia coli*

**Specimen:** Pus

**Patient:** female, 44 years old

**Dg.:** liver abscess

**Microscopy:** Gram-negative rods



Author: MUDr. Alena Pířová



CHARLES UNIVERSITY  
Second Faculty of Medicine

Slide No. 53

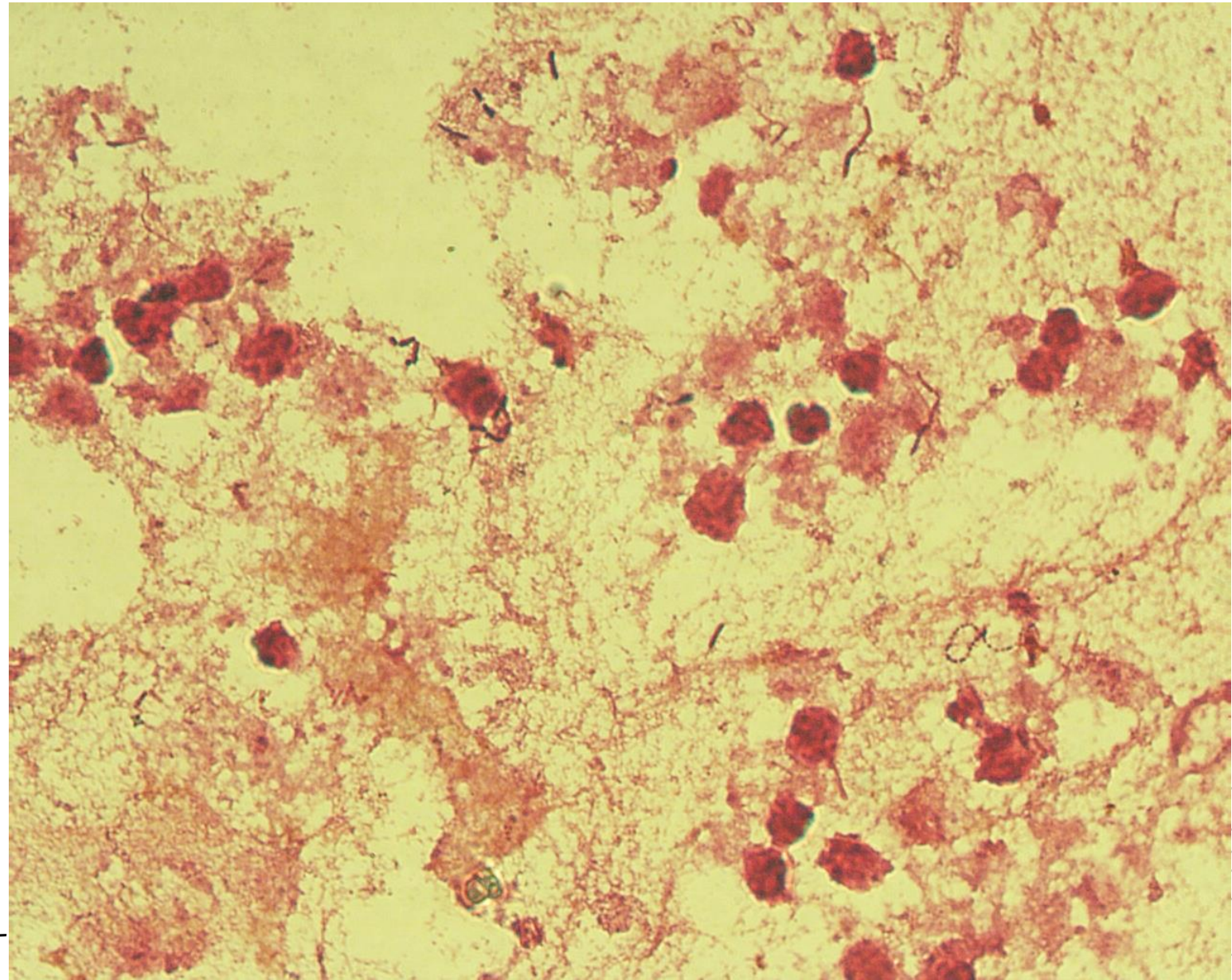
*Clostridium  
perfringens,  
Streptococcus  
sanguis*

**Specimen:** pus

**Patient:** female, 71 years old

**Dg.:** liver abscess

**Microscopy:** Gram-positive rods, Gram-positive cocci in clusters



Author: MUDr. Alena Pířová



CHARLES UNIVERSITY  
Second Faculty of Medicine

Slide No. 53

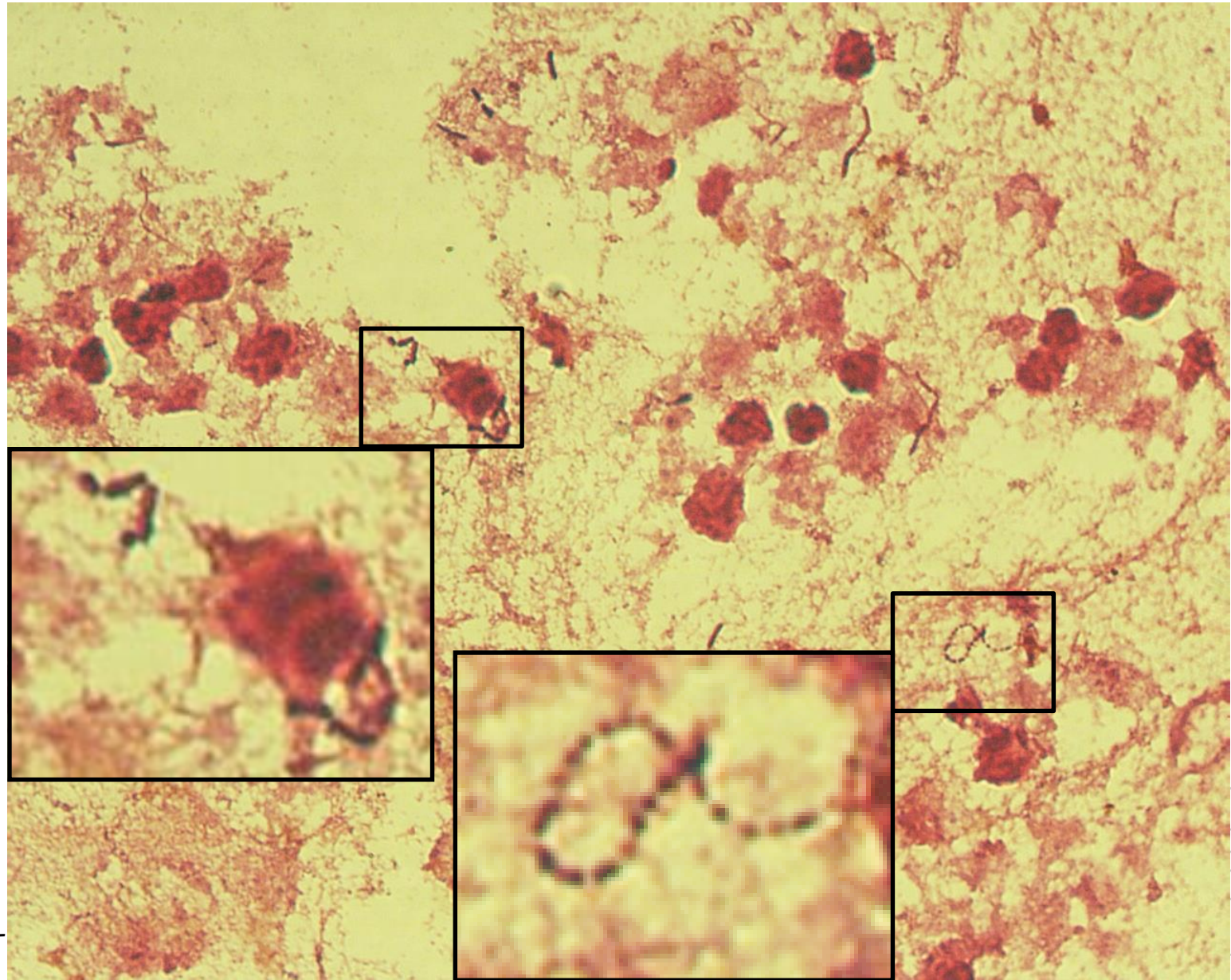
*Clostridium  
perfringens,  
Streptococcus  
sanguis*

**Specimen:** pus

**Patient:** female, 71 years old

**Dg.:** liver abscess

**Microscopy:** Gram-positive rods, Gram-positive cocci in clusters



Author: MUDr. Alena Pířová



CHARLES UNIVERSITY  
Second Faculty of Medicine

Slide No. 54

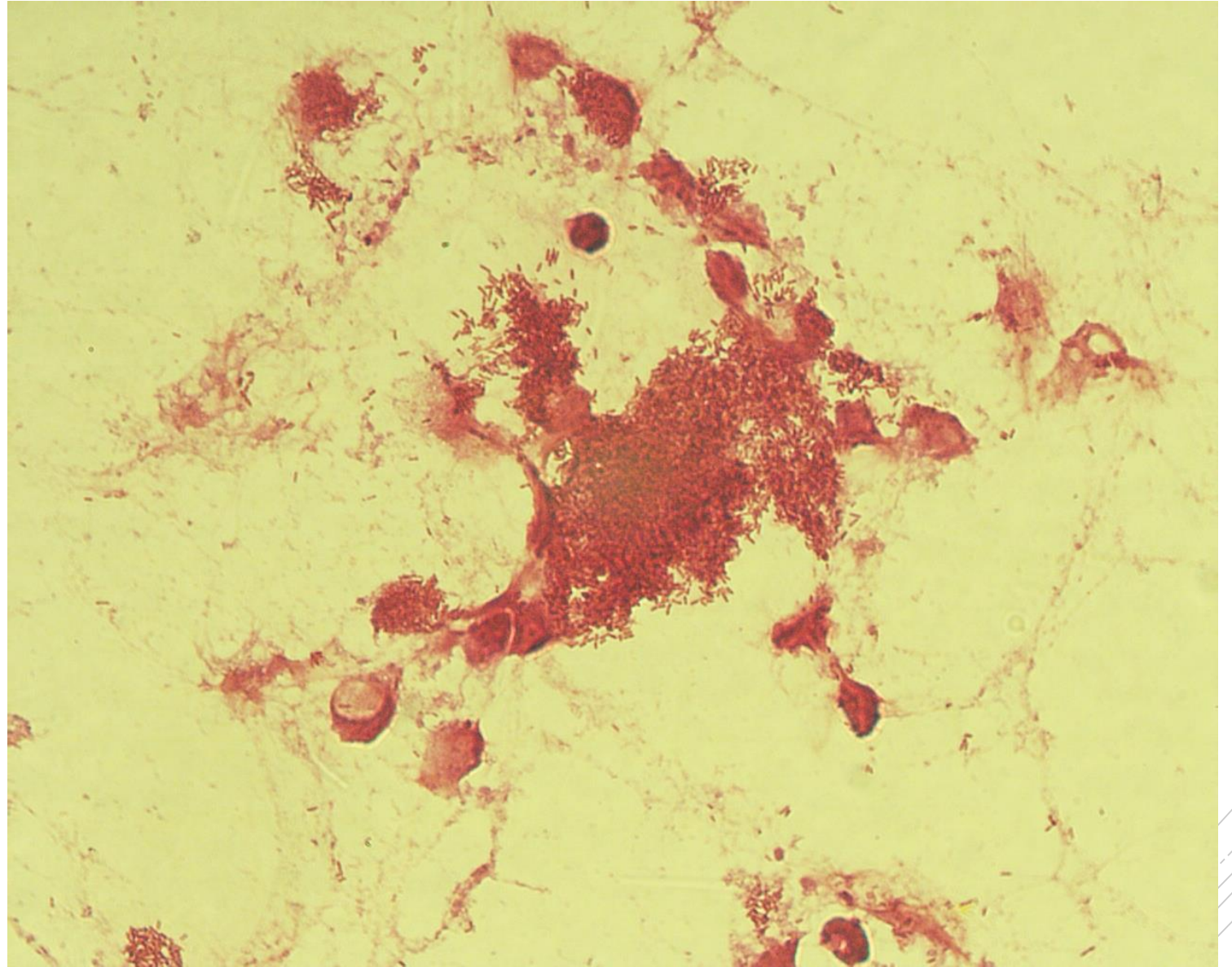
# *Stenotrophomonas maltophilia*

**Specimen:** pus

**Patient:** male, 30 years old

**Dg.:** acute pancreatitis

**Microscopy:** Gram-negative rods



Author: MUDr. Alena Píšová



CHARLES UNIVERSITY  
Second Faculty of Medicine

Slide No. 54

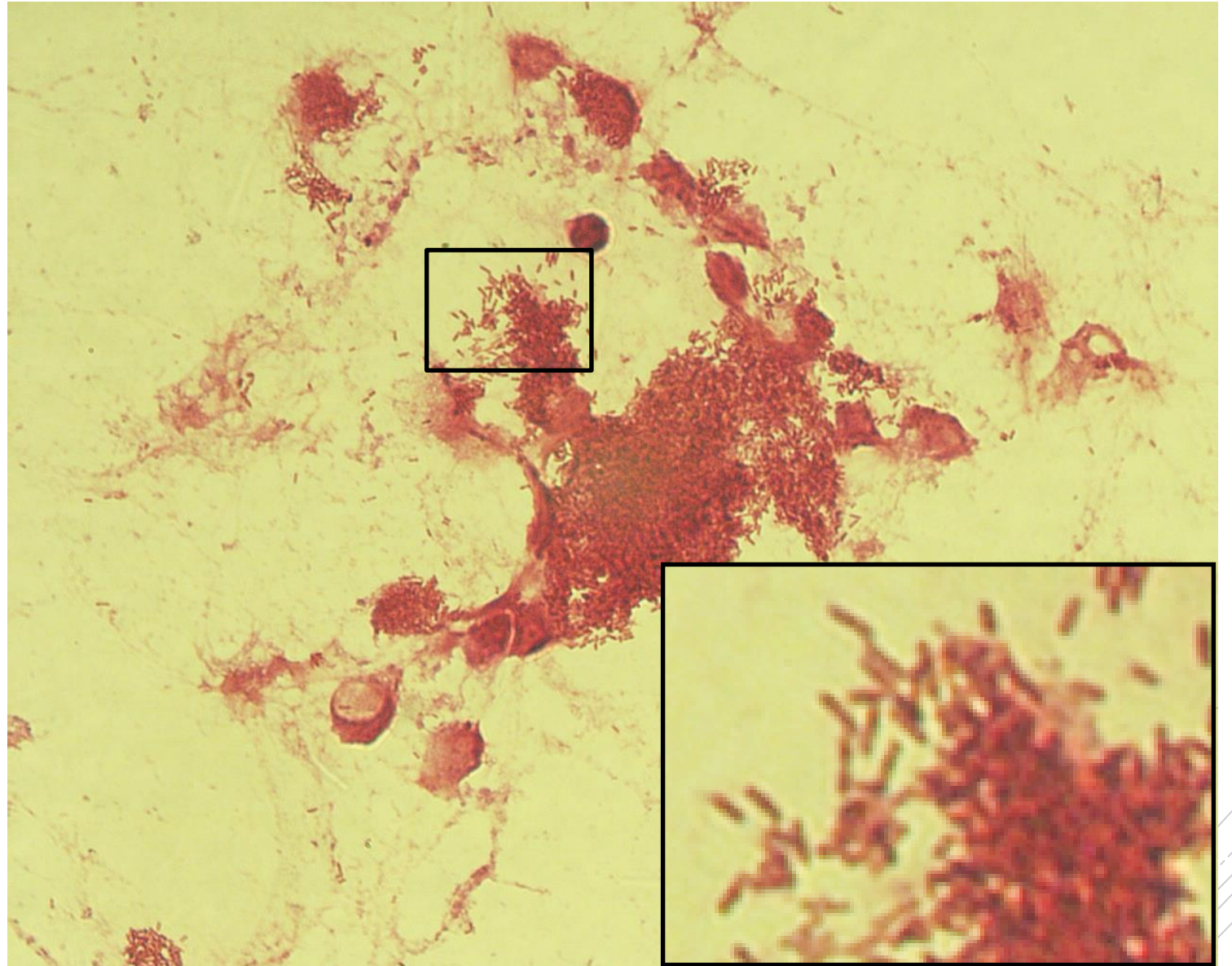
# *Stenotrophomonas maltophilia*

**Specimen:** pus

**Patient:** male, 30 years old

**Dg.:** acute pancreatitis

**Microscopy:** Gram-negative rods



Author: MUDr. Alena Píšová



CHARLES UNIVERSITY  
Second Faculty of Medicine

Slide No. 55

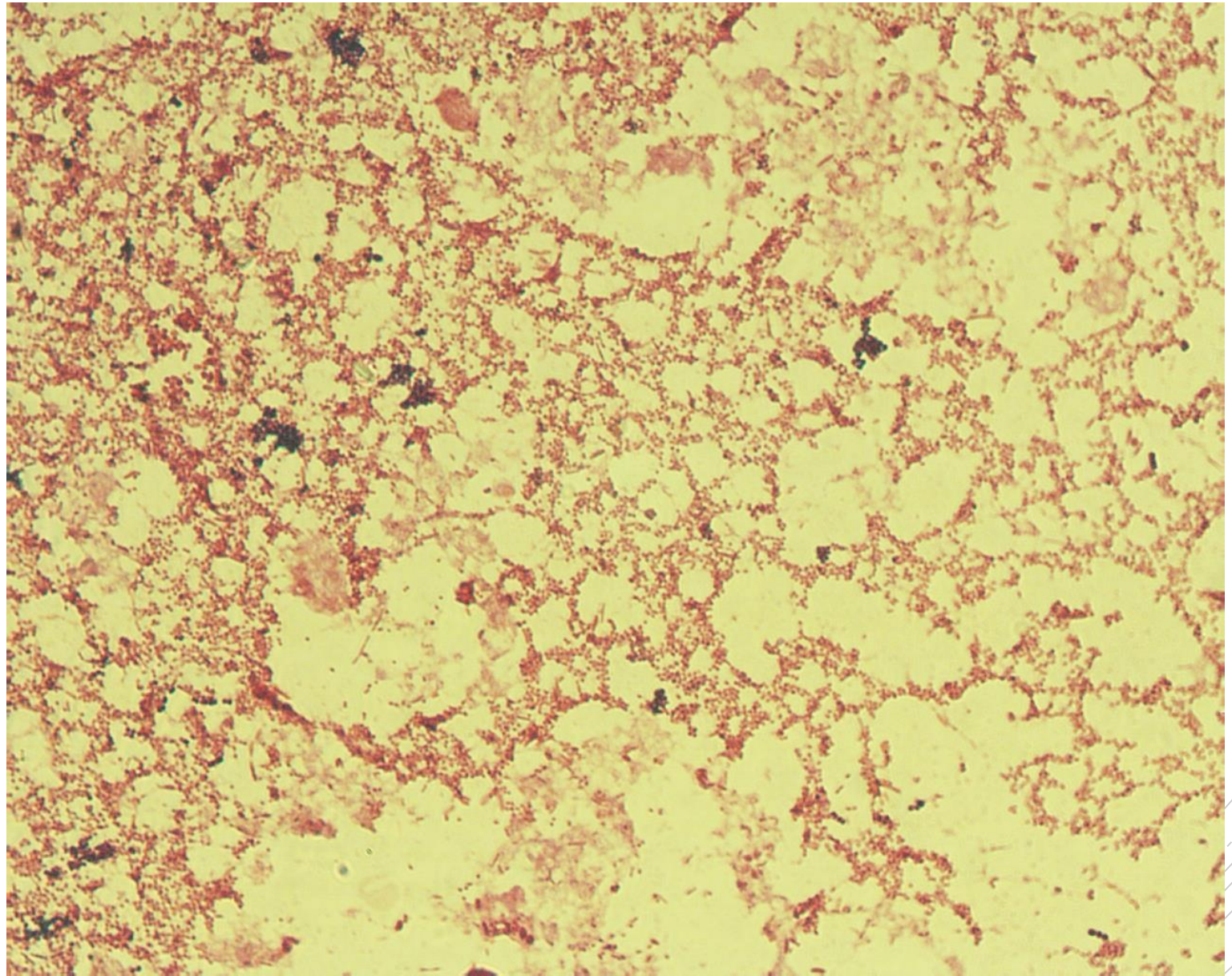
*Proteus mirabilis,*  
*Enterococcus*  
*raffinosis*

**Specimen:** Pus

**Patient:** female, 55 years old

**Dg.:** sepsis

**Microscopy:** Gram-negative rods,  
Gram-positive cocci



Author: MUDr. Alena Pířová



CHARLES UNIVERSITY  
Second Faculty of Medicine

Slide No. 55

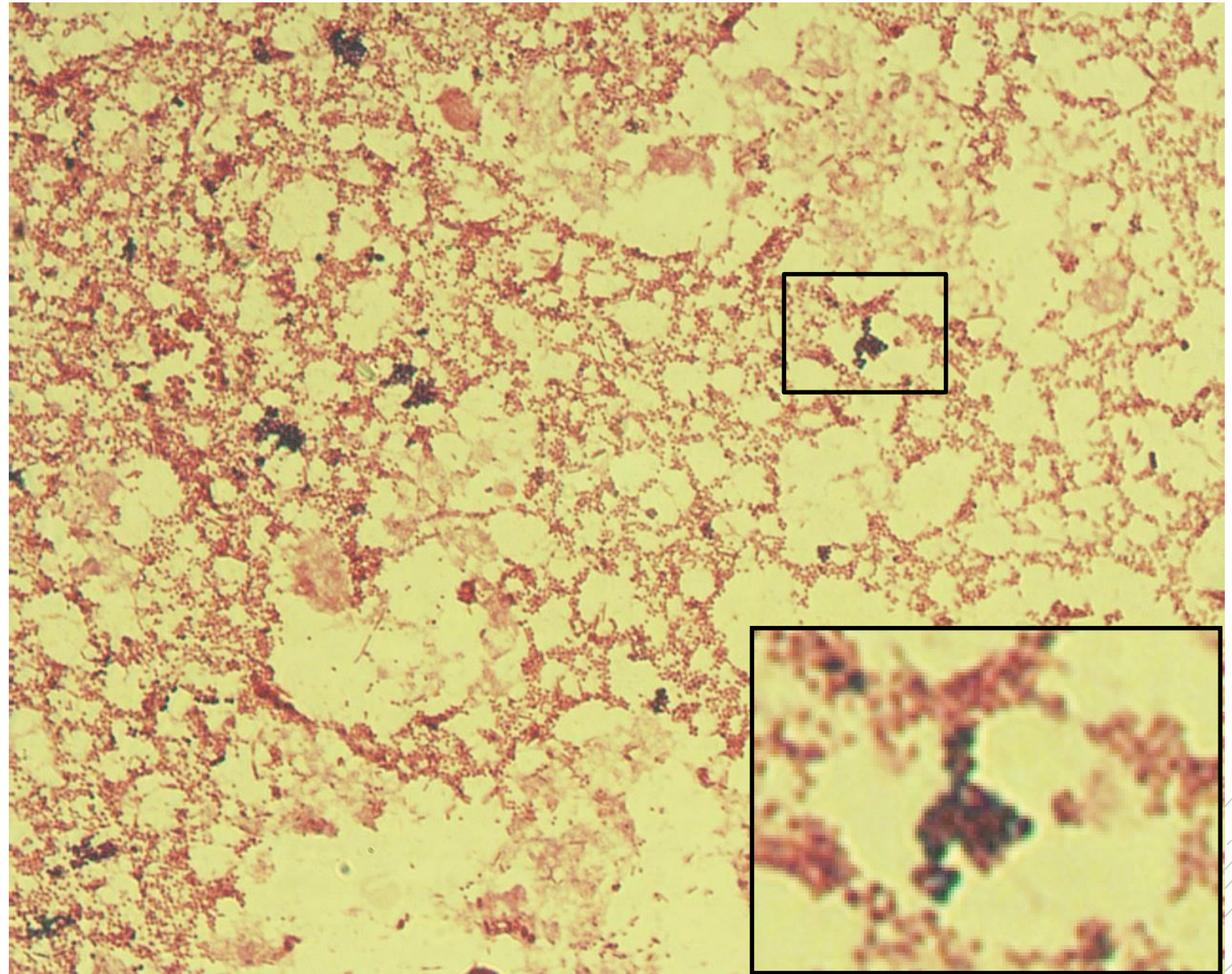
*Proteus mirabilis,*  
*Enterococcus*  
*raffinosis*

**Specimen:** Pus

**Patient:** female, 55 years old

**Dg.:** sepsis

**Microscopy:** Gram-negative rods,  
Gram-positive cocci



Author: MUDr. Alena Píšová



CHARLES UNIVERSITY  
Second Faculty of Medicine

Slide No. 56

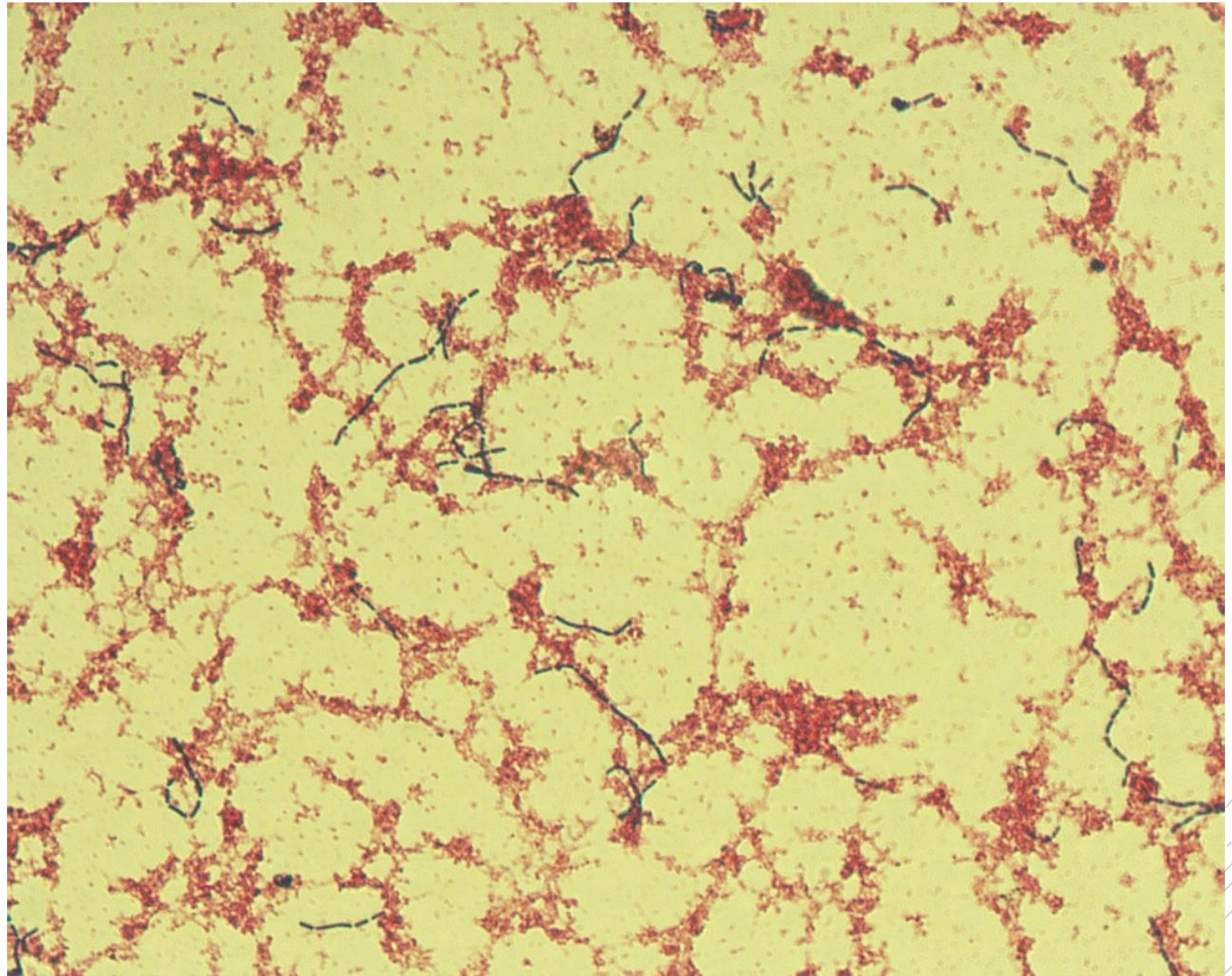
# *Lactobacillus rhamnosus*

**Specimen:** blood culture

**Patient:** male, 67 years old

**Dg.:** acute pancreatitis

**Microscopy:** thin Gram-positive rods



Author: MUDr. Petra Kabelíková, Sandra Opálková





CHARLES UNIVERSITY  
Second Faculty of Medicine

Slide No. 56a

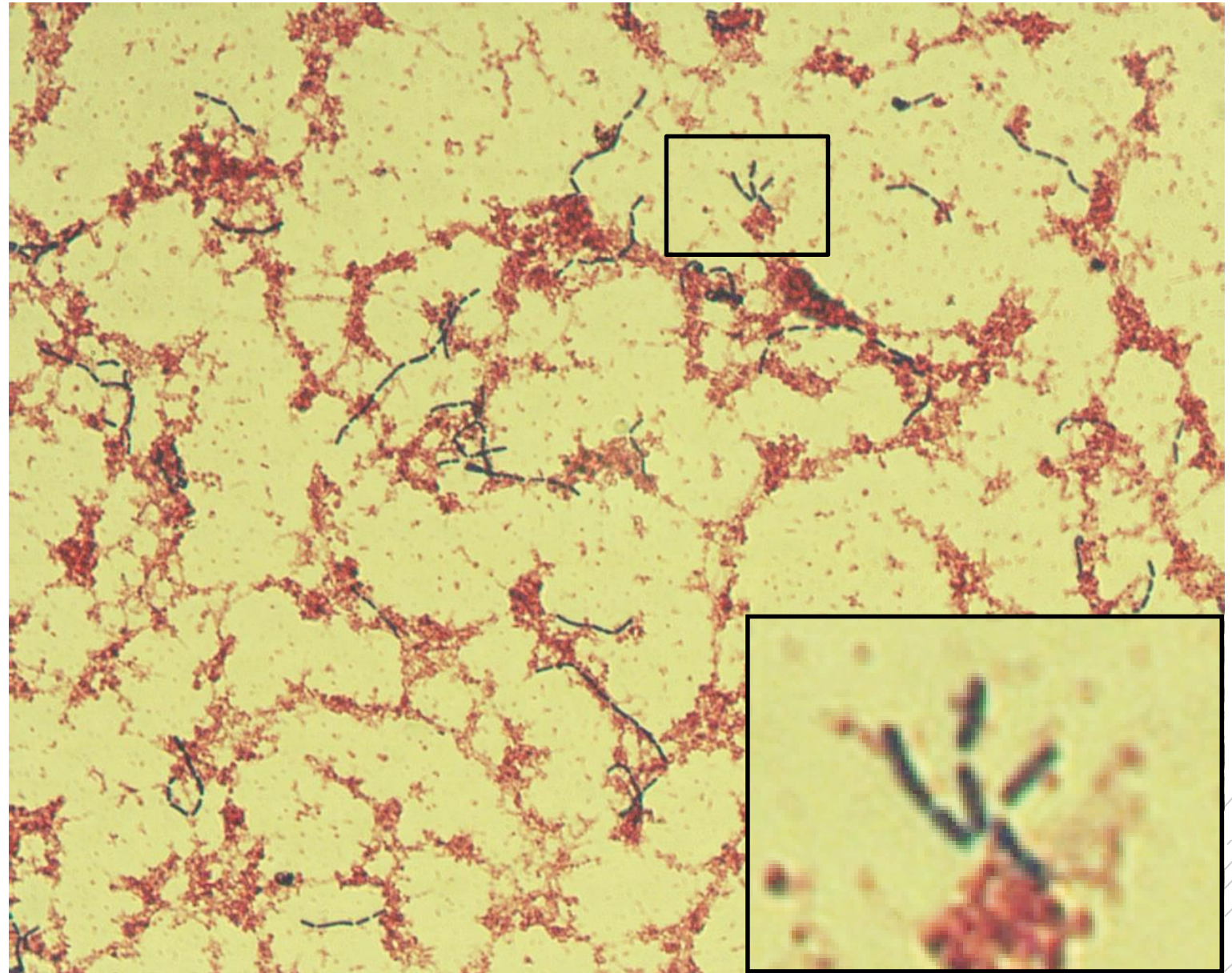
# *Lactobacillus rhamnosus*

**Specimen:** blood culture

**Patient:** male, 67 years old

**Dg.:** acute pancreatitis

**Microscopy:** thin Gram-positive rods



Author: MUDr. Petra Kabelíková, Sandra Opálková



CHARLES UNIVERSITY  
Second Faculty of Medicine

Slide No. 57

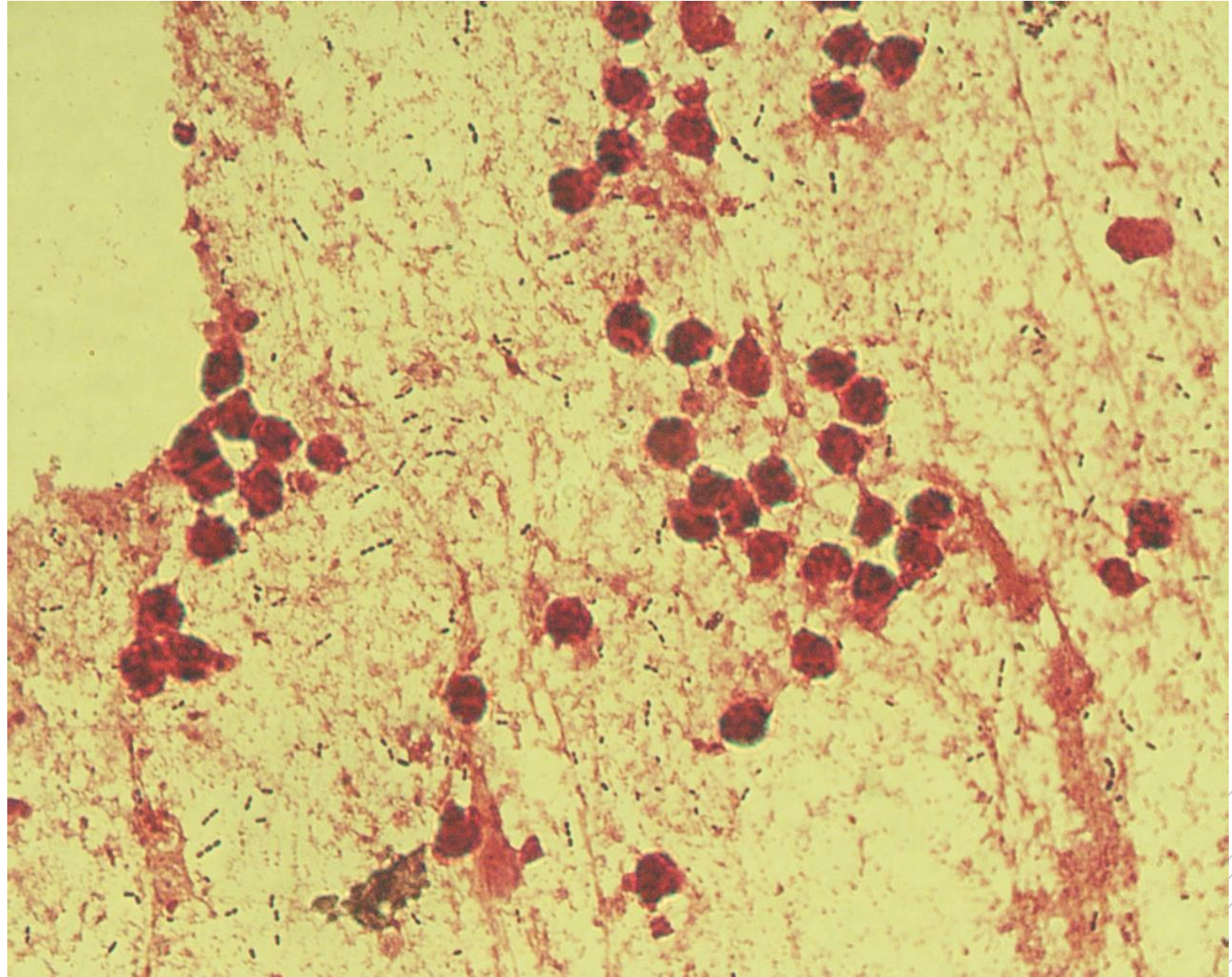
# *Streptococcus pneumoniae*

**Specimen:** sputum

**Patient:** female, 16 years old

**Dg.:** purulent bronchitis

**Microscopy:** Gram-positive diplococci



Author: MUDr. Lenka Tritová



CHARLES UNIVERSITY  
Second Faculty of Medicine

Slide No. 57

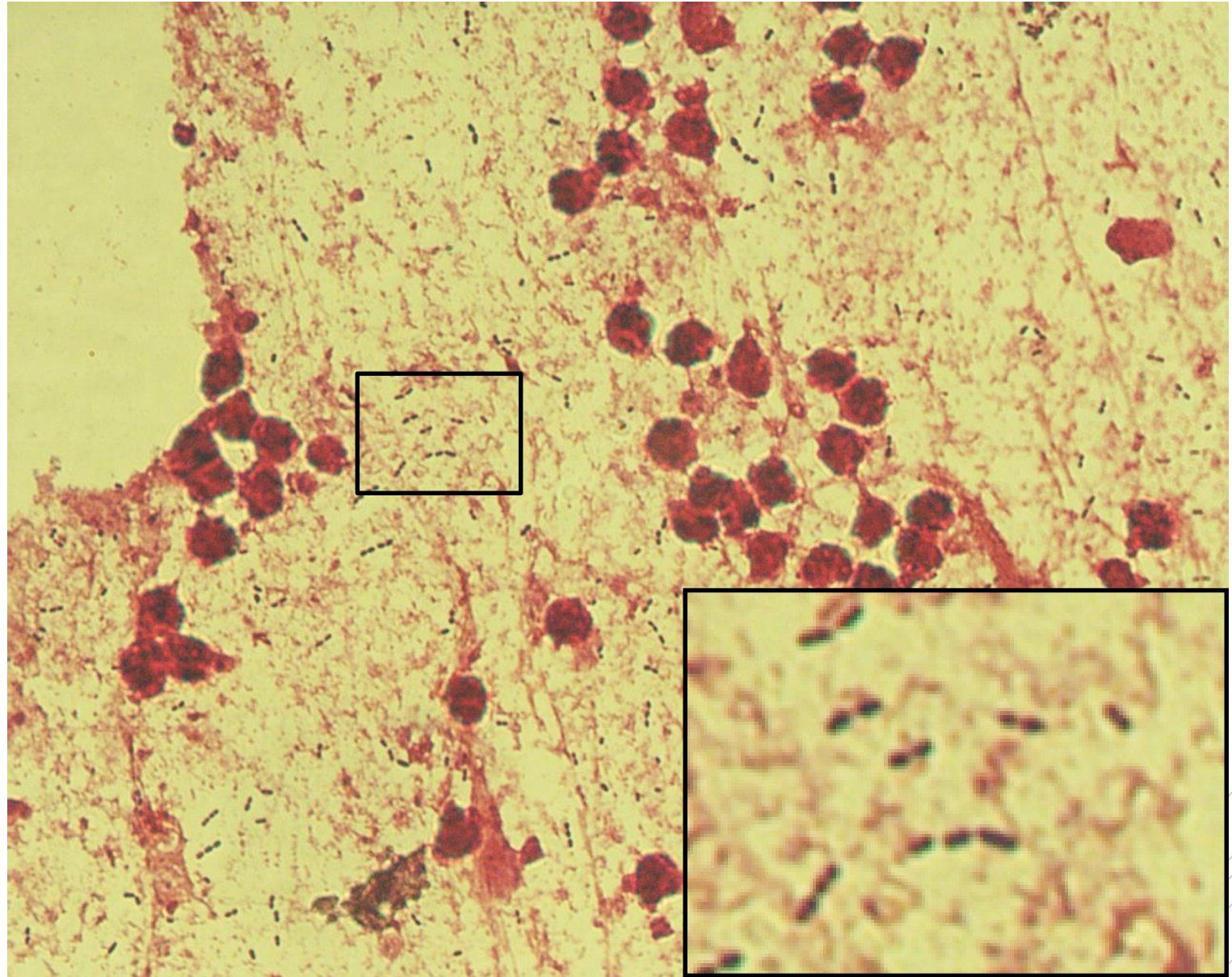
# *Streptococcus pneumoniae*

**Specimen:** sputum

**Patient:** female, 16 years old

**Dg.:** purulent bronchitis

**Microscopy:** Gram-positive diplococci



Author: MUDr. Lenka Tritová



CHARLES UNIVERSITY  
Second Faculty of Medicine

Slide No. 58

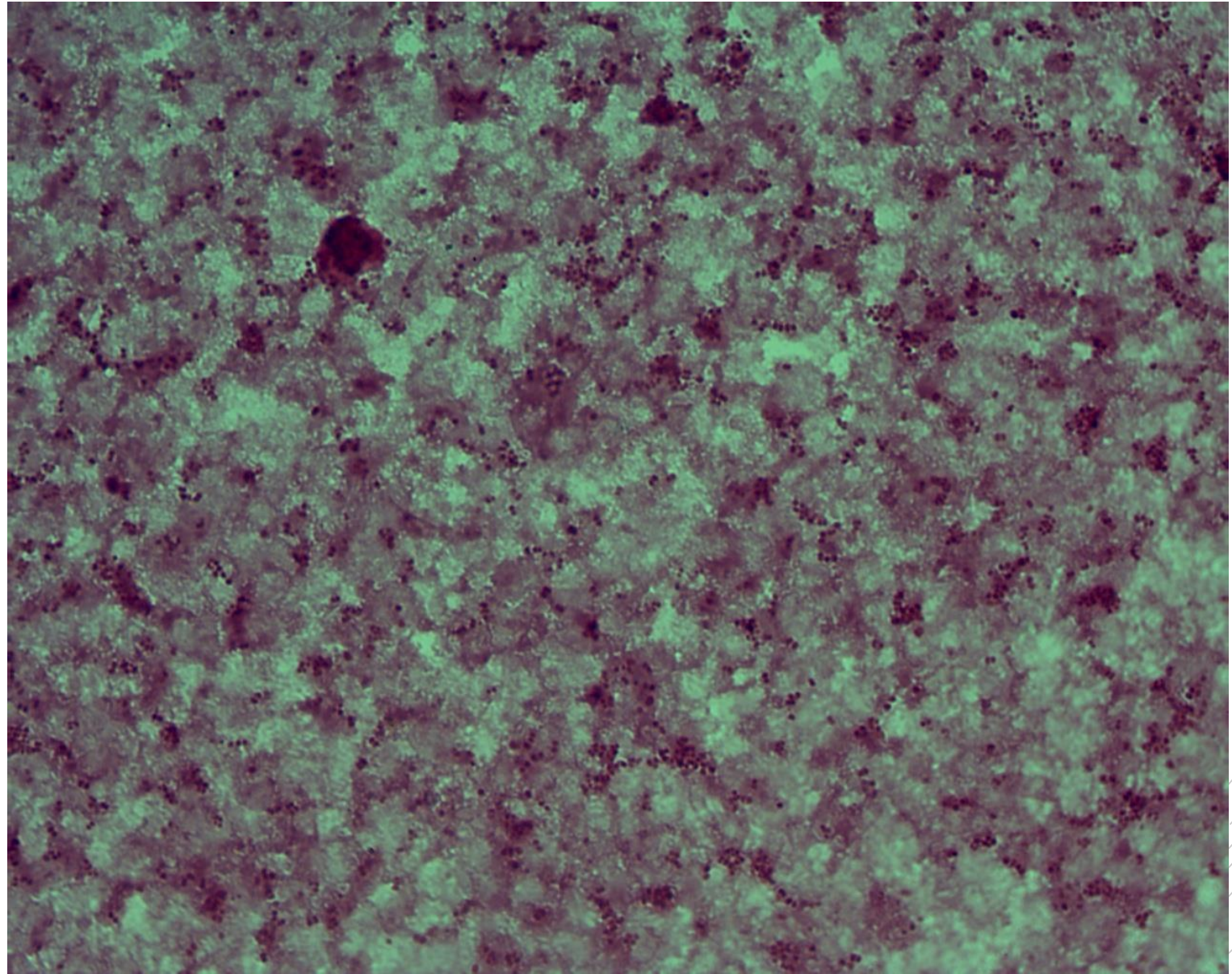
# *Neisseria meningitidis*

**Specimen:** blood culture

**Patient:** male, 52 years old

**Dg.:** purulent meningitis

**Microscopy:** Gram-negative diplococci



Author: MUDr. Petra Kabelíková, Sandra Opálková



CHARLES UNIVERSITY  
Second Faculty of Medicine

Slide No. 58


# *Neisseria meningitidis*

**Specimen:** blood culture

**Patient:** male, 52 years old

**Dg.:** purulent meningitis

**Microscopy:** Gram-negative diplococci



Author: MUDr. Petra Kabelíková, Sandra Opálková



CHARLES UNIVERSITY  
Second Faculty of Medicine

Slide No. 59

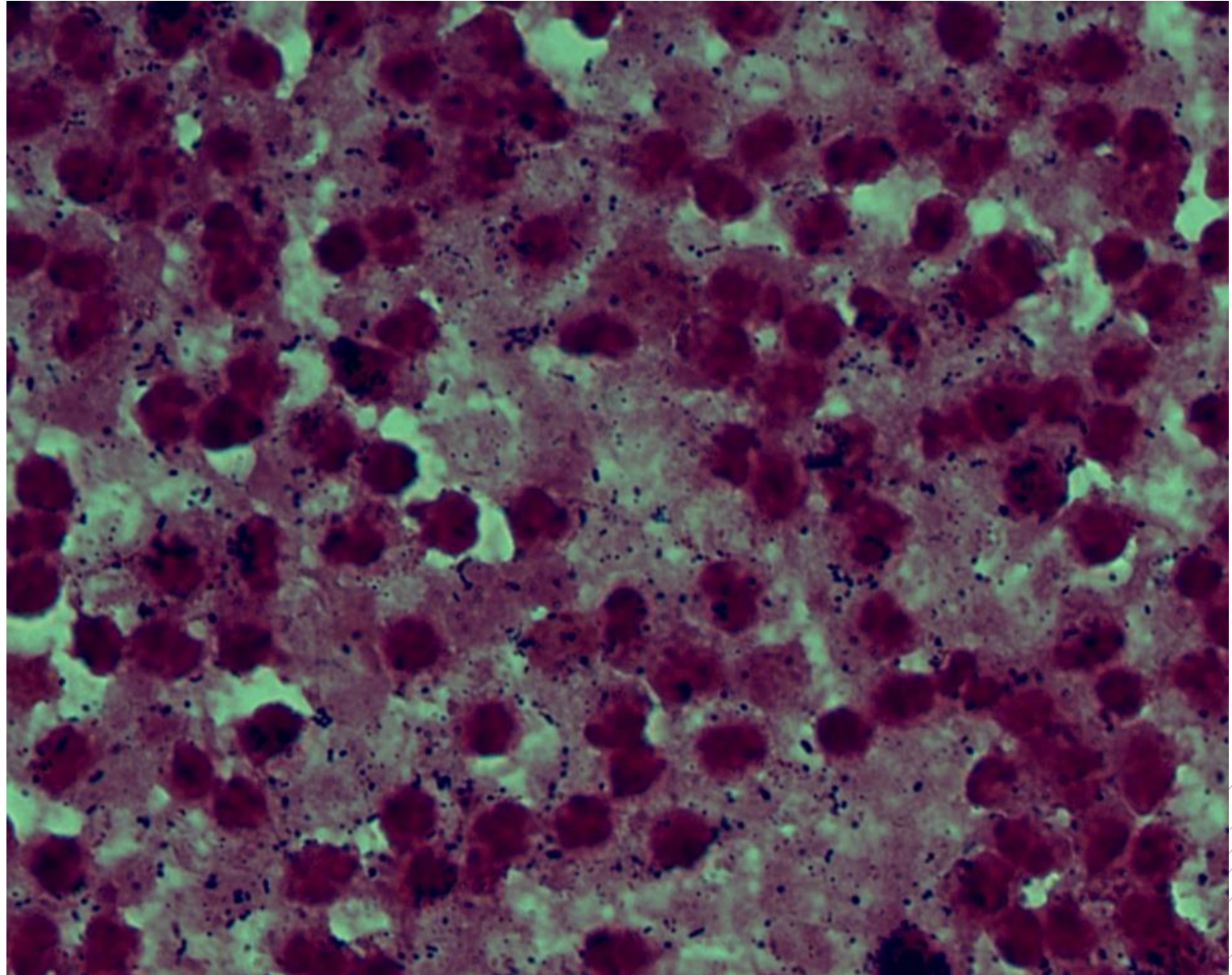
# *Streptococcus constellatus*

**Specimen:** pus

**Patient:** female, 19 years old

**Dg.:** purulent otitis media

**Microscopy:** Gram-positive cocci



Author: MUDr. Lenka Tritová



CHARLES UNIVERSITY  
Second Faculty of Medicine

Slide No. 59

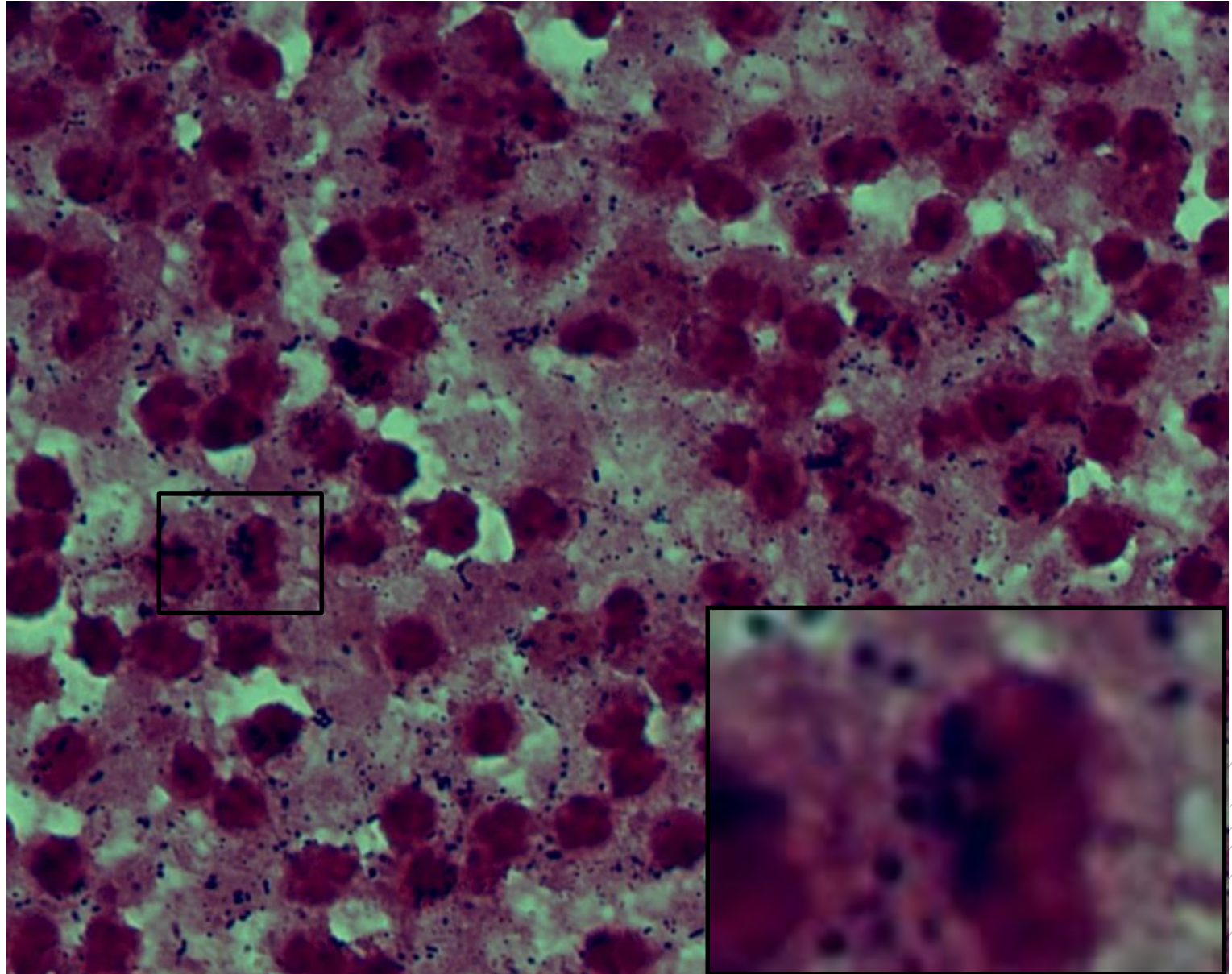
# *Streptococcus constellatus*

**Specimen:** pus

**Patient:** female, 19 years old

**Dg.:** purulent otitis media

**Microscopy:** Gram-positive cocci



Author: MUDr. Lenka Tritová



CHARLES UNIVERSITY  
Second Faculty of Medicine

Slide No. 60

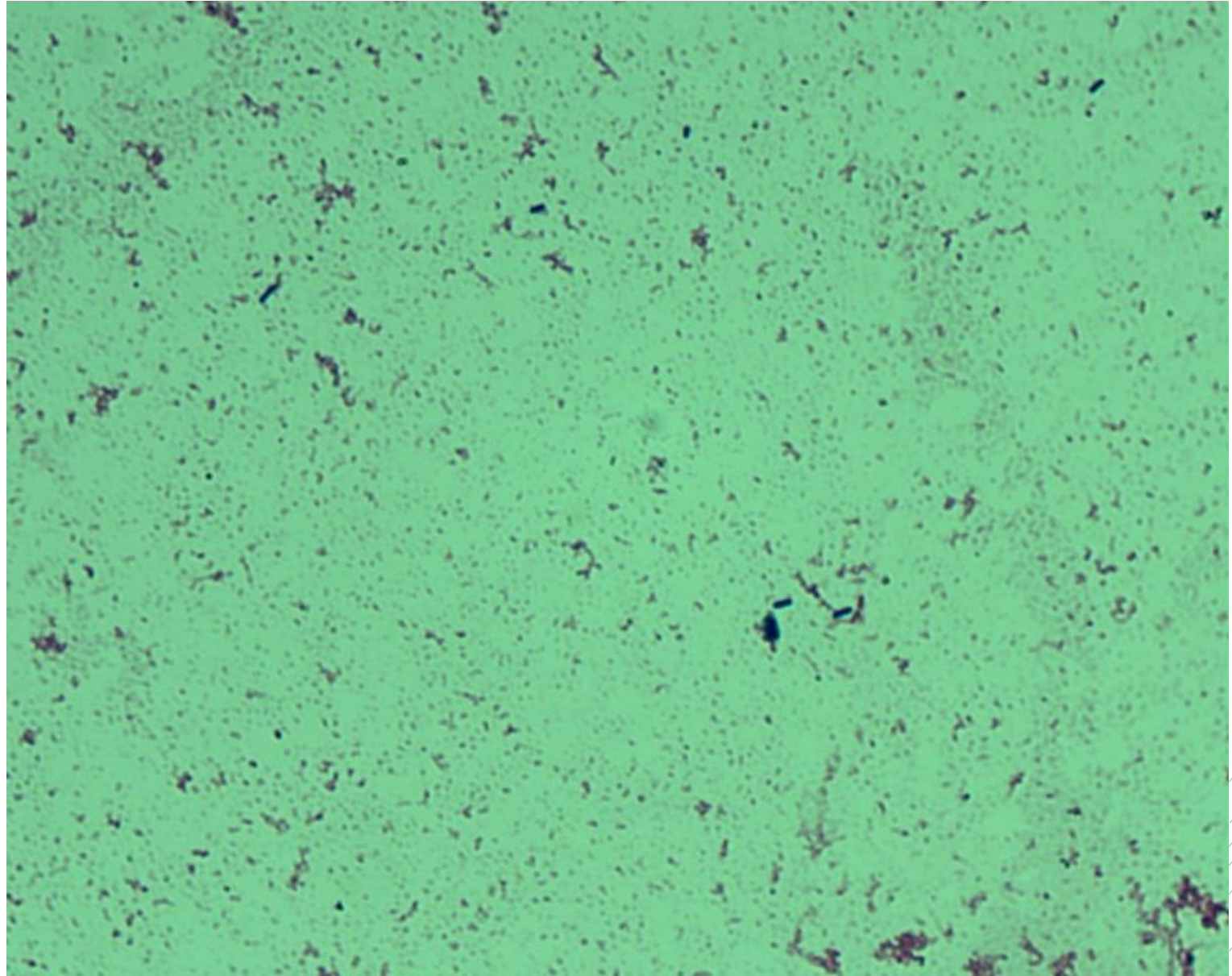
# *Listeria monocytogenes*

**Specimen:** blood culture

**Patient:** female, 74 years old

**Dg.:** sepsis

**Microscopy:** Gram-positive rods



Author: MUDr. Petra Kabelíková, Sandra Opálková





CHARLES UNIVERSITY  
Second Faculty of Medicine

Slide No. 60

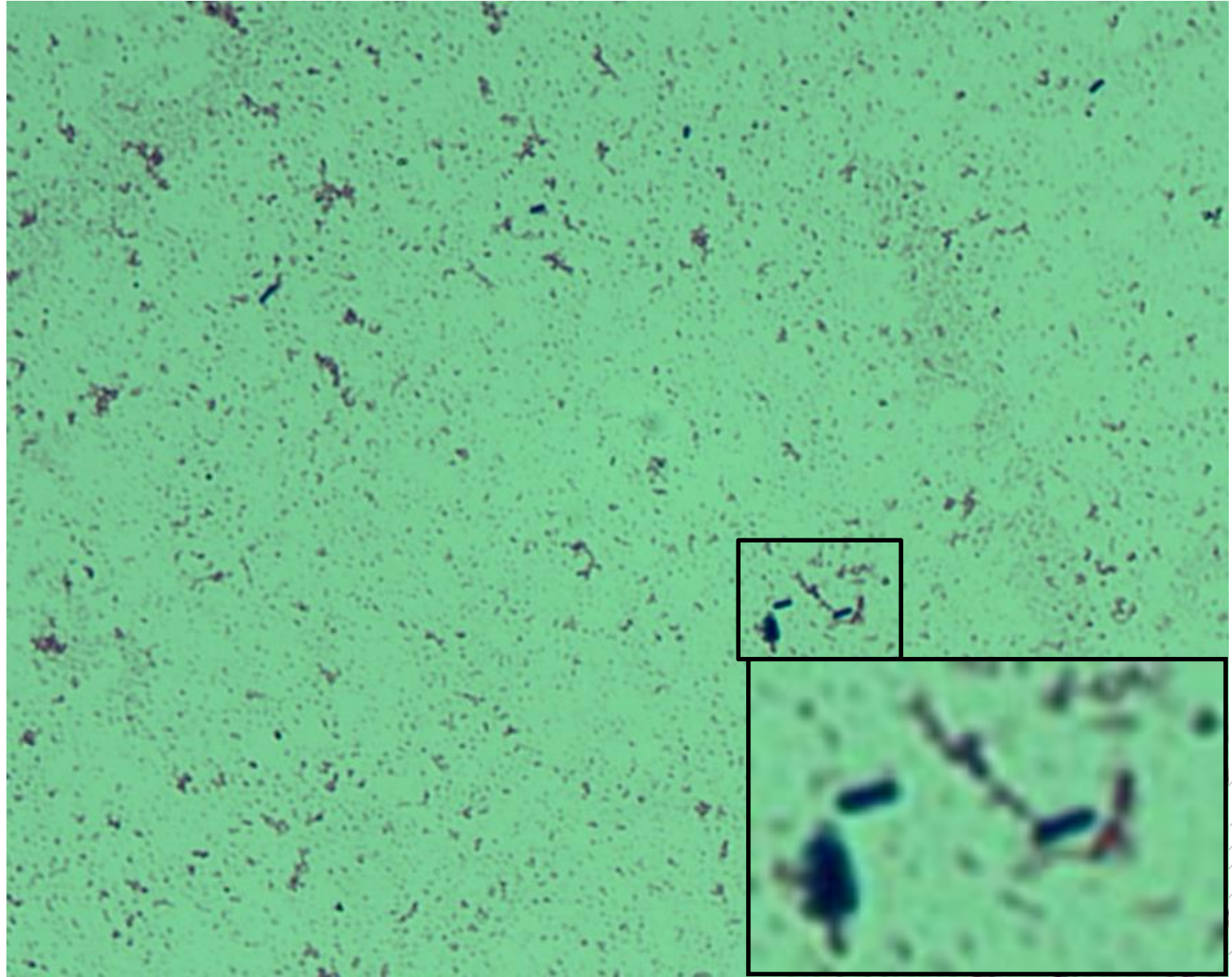
# *Listeria monocytogenes*

**Specimen:** blood culture

**Patient:** female, 74 years old

**Dg.:** sepsis

**Microscopy:** Gram-positive rods



Author: MUDr. Petra Kabelíková, Sandra Opálková



CHARLES UNIVERSITY  
Second Faculty of Medicine

Slide No. 61

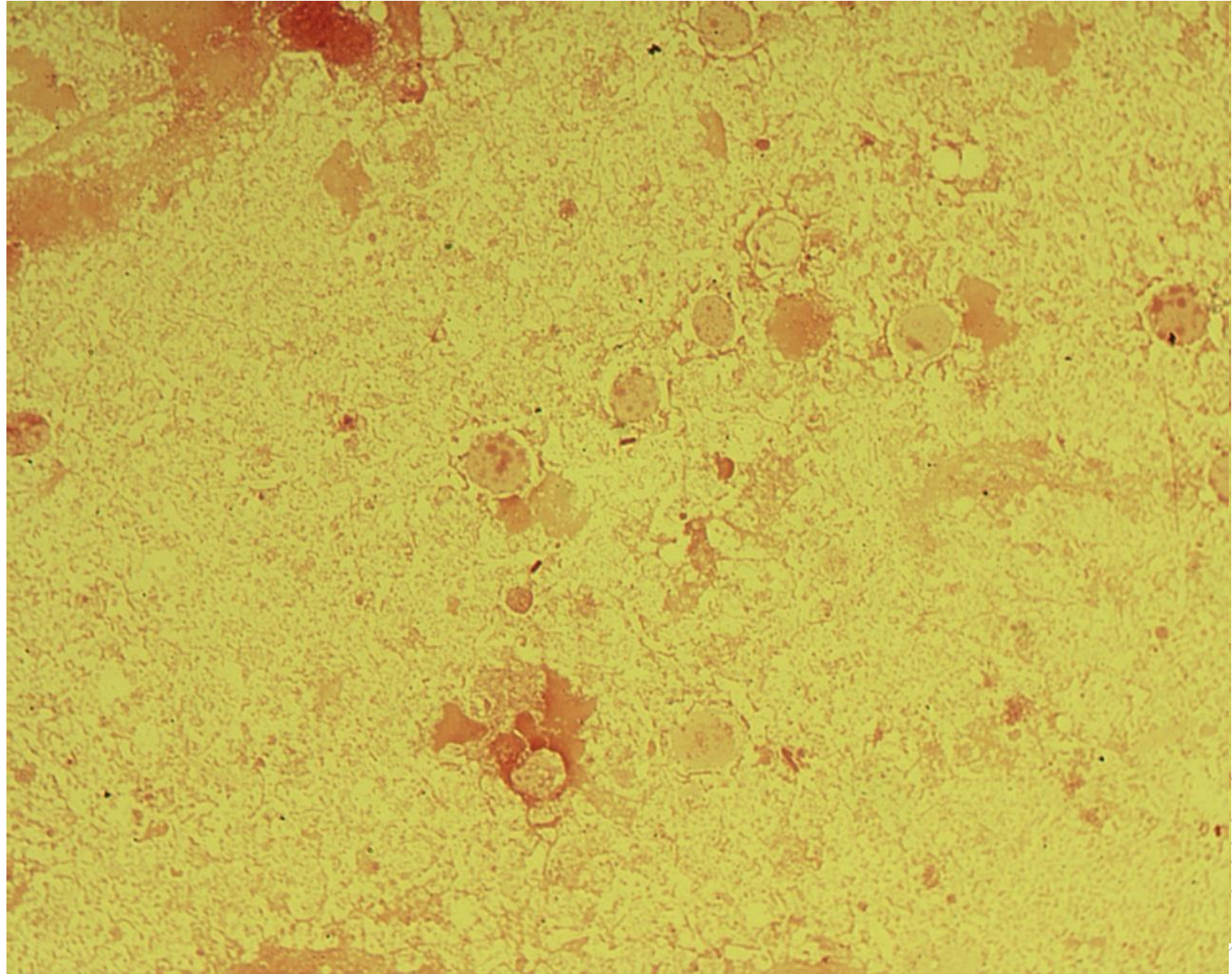
# *Pseudomonas aeruginosa*

**Specimen:** abscess

**Patient:** male, 78 years old

**Dg.:** diabetic foot

**Microscopy:** Gram-negative rods



Author: MUDr. Alena Pířová



CHARLES UNIVERSITY  
Second Faculty of Medicine

Slide No. 61


# *Pseudomonas aeruginosa*

**Specimen:** abscess

**Patient:** male, 78 years old

**Dg.:** diabetic foot

**Microscopy:** Gram-negative rods



Author: MUDr. Alena Pířová



CHARLES UNIVERSITY  
Second Faculty of Medicine

Slide No. 62

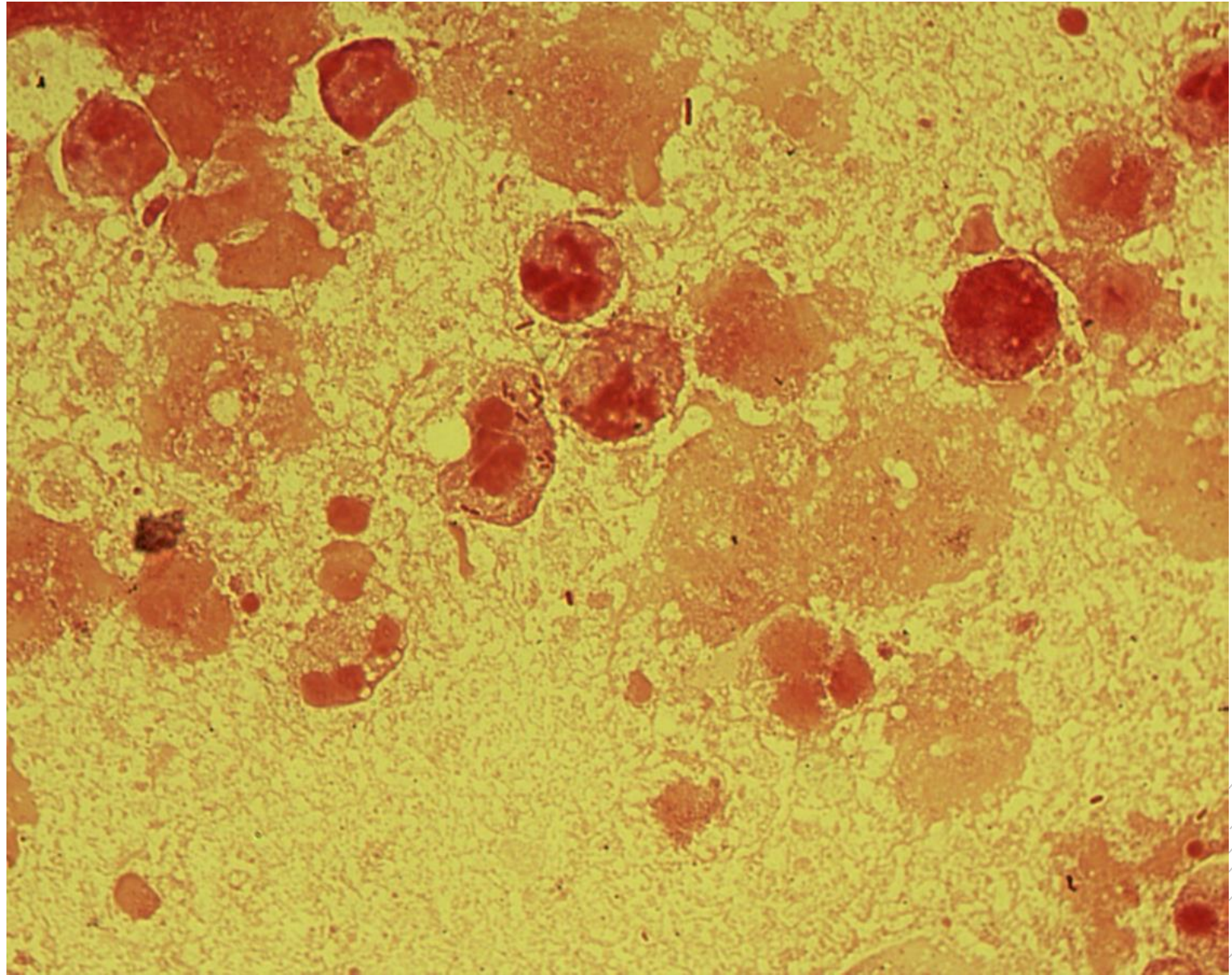
# *Escherichia coli*

**Specimen:** pus

**Patient:** female, 65 years old

**Dg.:** periappendicular abscess

**Microscopy:** Gram-negative rods



Author: MUDr. Alena Píšová



CHARLES UNIVERSITY  
Second Faculty of Medicine

Slide No. 62

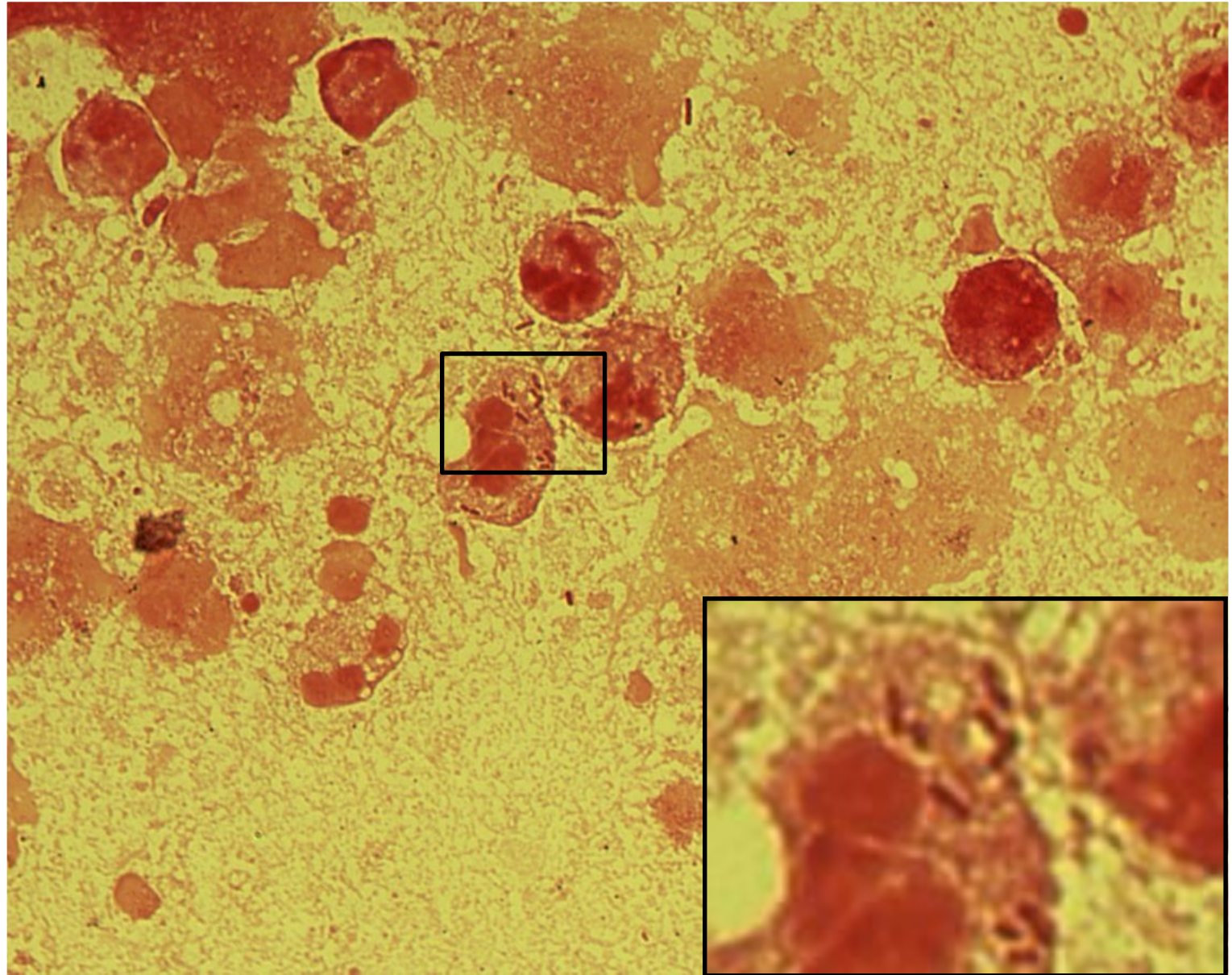
# *Escherichia coli*

**Specimen:** pus

**Patient:** female, 65 years old

**Dg.:** periappendicular abscess

**Microscopy:** Gram-negative rods



Author: MUDr. Alena Píšová



CHARLES UNIVERSITY  
Second Faculty of Medicine

Slide No. 63

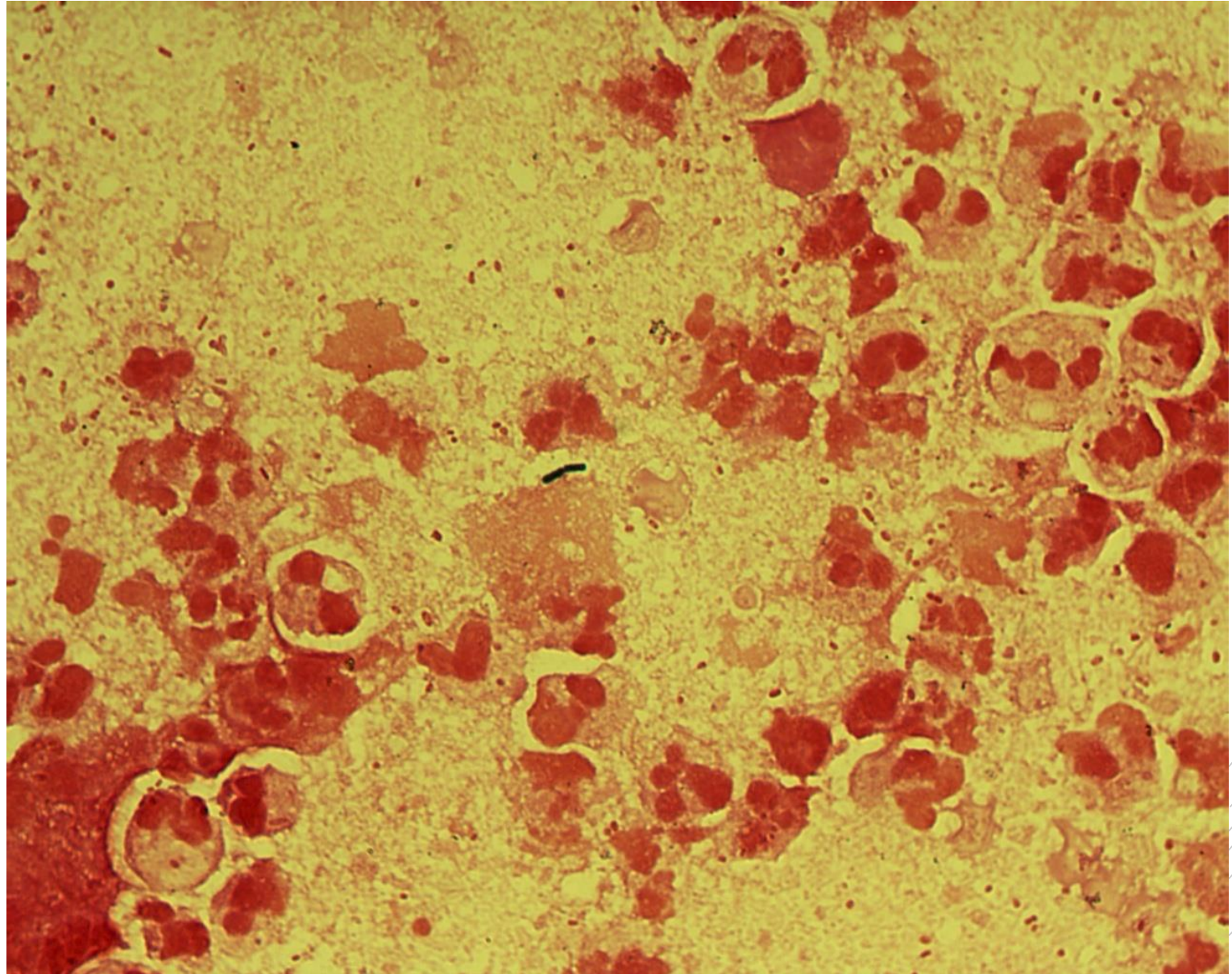
# *Escherichia coli*

**Specimen:** pus

**Patient:** male, 39 years old

**Dg.:** periproctal abscess

**Microscopy:** Gram-negative rods



Author: MUDr. Alena Pířová



CHARLES UNIVERSITY  
Second Faculty of Medicine

Slide No. 63

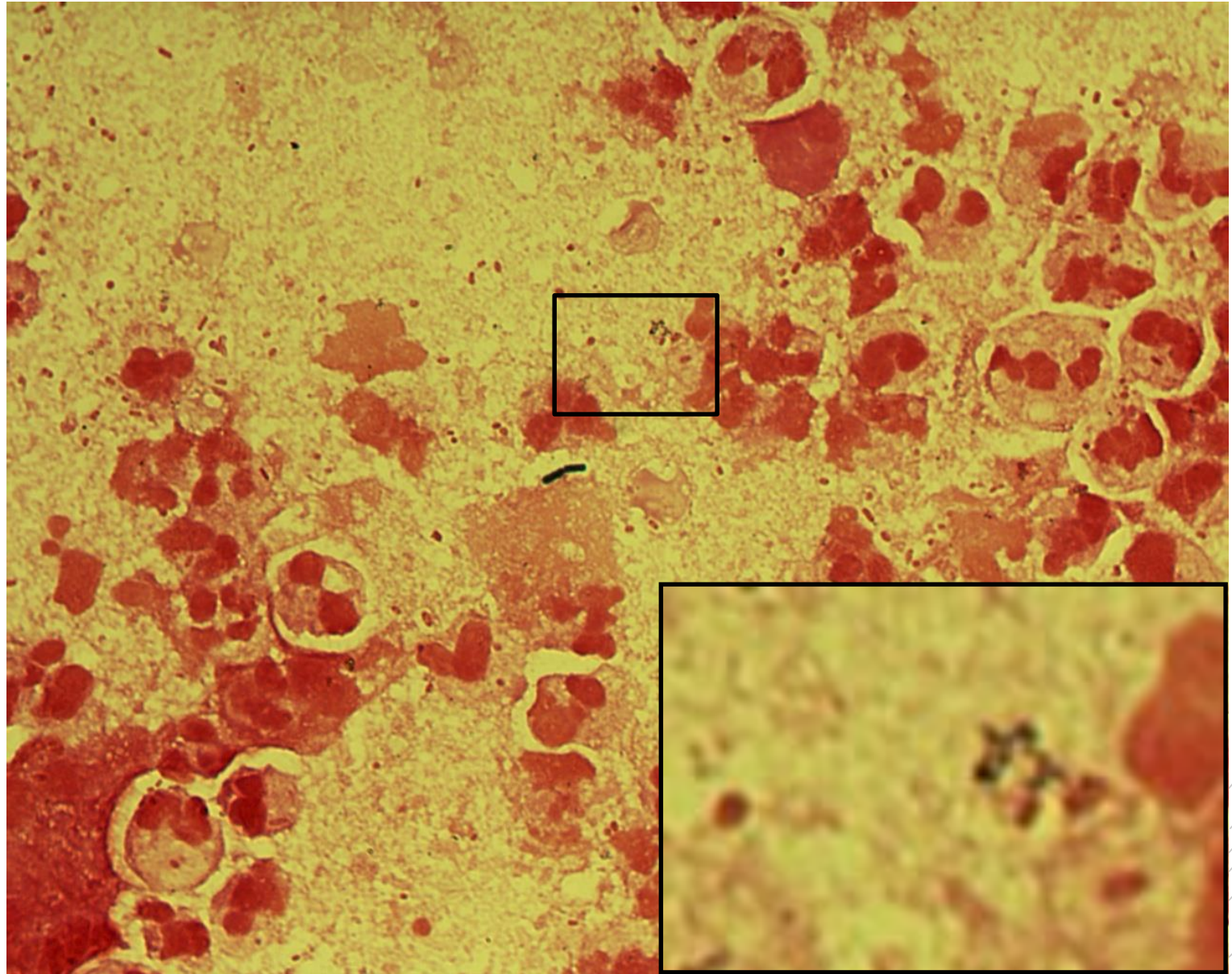
# *Escherichia coli*

**Specimen:** pus

**Patient:** male, 39 years old

**Dg.:** periproctal abscess

**Microscopy:** Gram-negative rods



Author: MUDr. Alena Píšová



CHARLES UNIVERSITY  
Second Faculty of Medicine

Slide No. 64

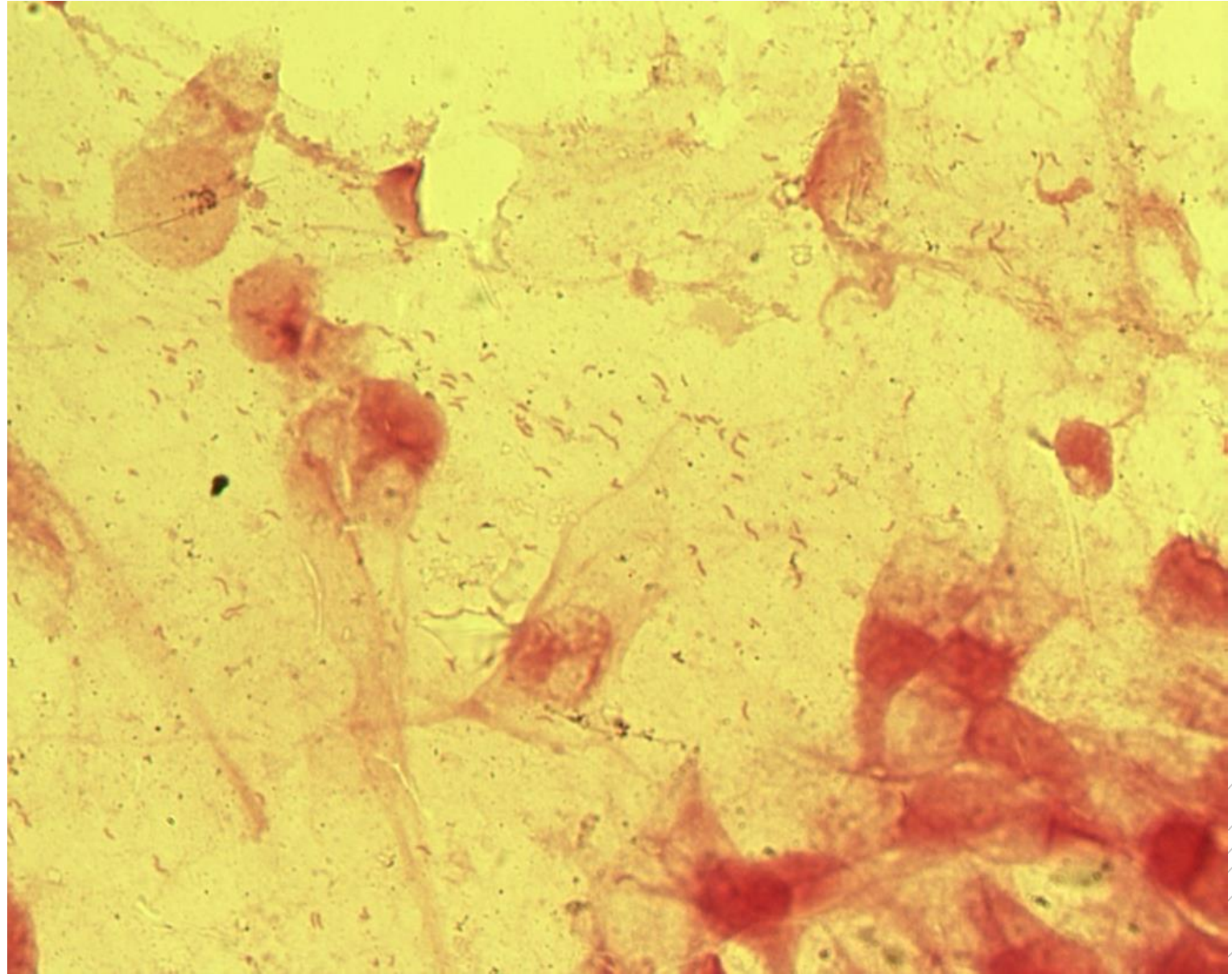
# *Helicobacter pylori*

**Specimen:** biopsy

**Patient:** female, 35 years old

**Dg.:** stomach ulcer

**Microscopy:** spiral and „flying bird“-  
shaped Gram-negative rods



Author: MUDr. Svojtková, MUDr. Šolarová





CHARLES UNIVERSITY  
Second Faculty of Medicine

Slide No. 64

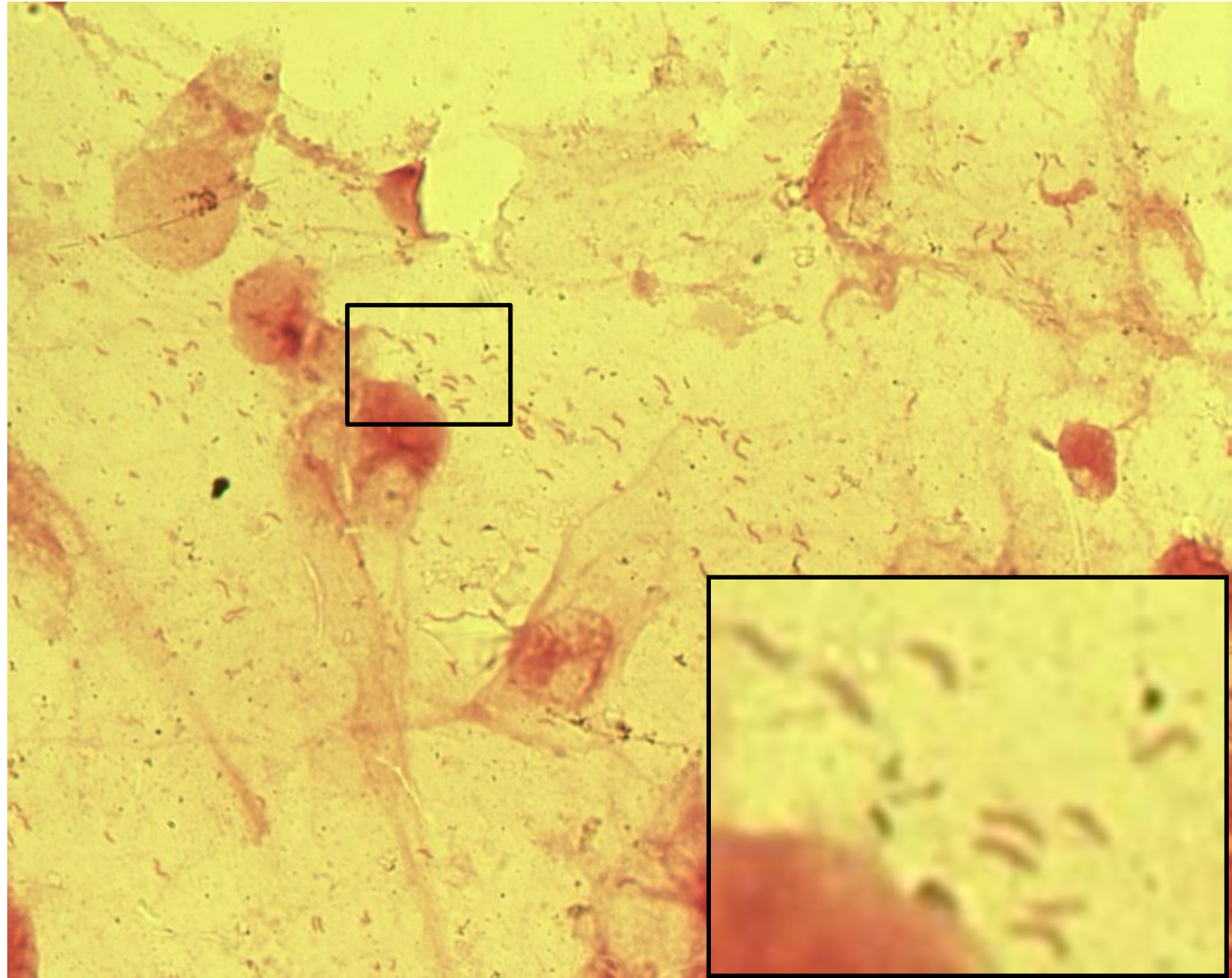
# *Helicobacter pylori*

**Specimen:** biopsy

**Patient:** female, 35 years old

**Dg.:** stomach ulcer

**Microscopy:** spiral and „flying bird“-  
shaped Gram-negative rods



Author: MUDr. Svojtková, MUDr. Šolarová



CHARLES UNIVERSITY  
Second Faculty of Medicine

Slide No. 65

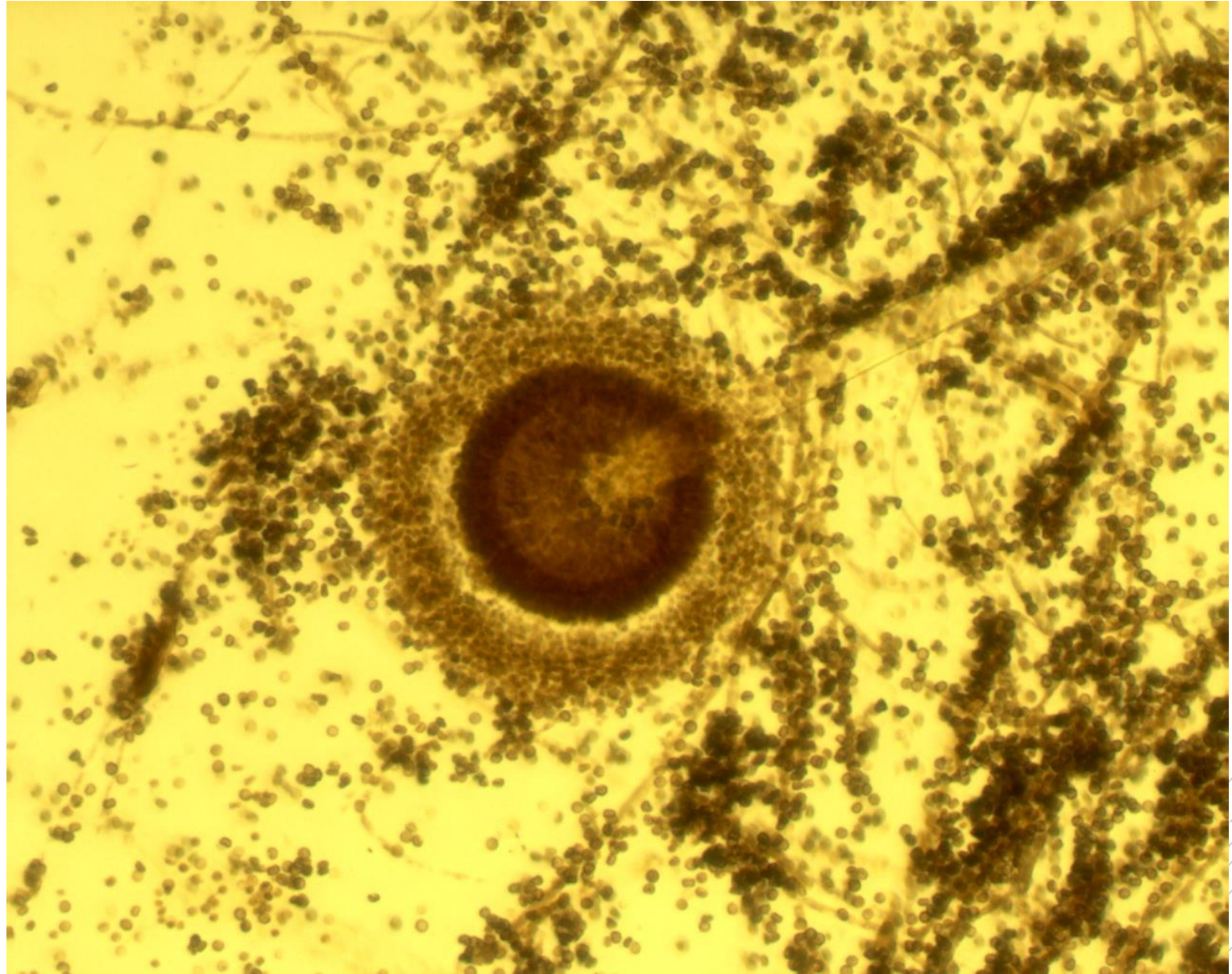
# *Aspergillus fumigatus*

**Specimen:** culture

**Patient:** male, 85 years old

**Dg.:** lung aspergilloma

**Microscopy:** a conidiophore with a vesicle and numerous conidia



Author: MUDr. Svojtková, MUDr. Šolarová



CHARLES UNIVERSITY  
Second Faculty of Medicine

Slide No. 65

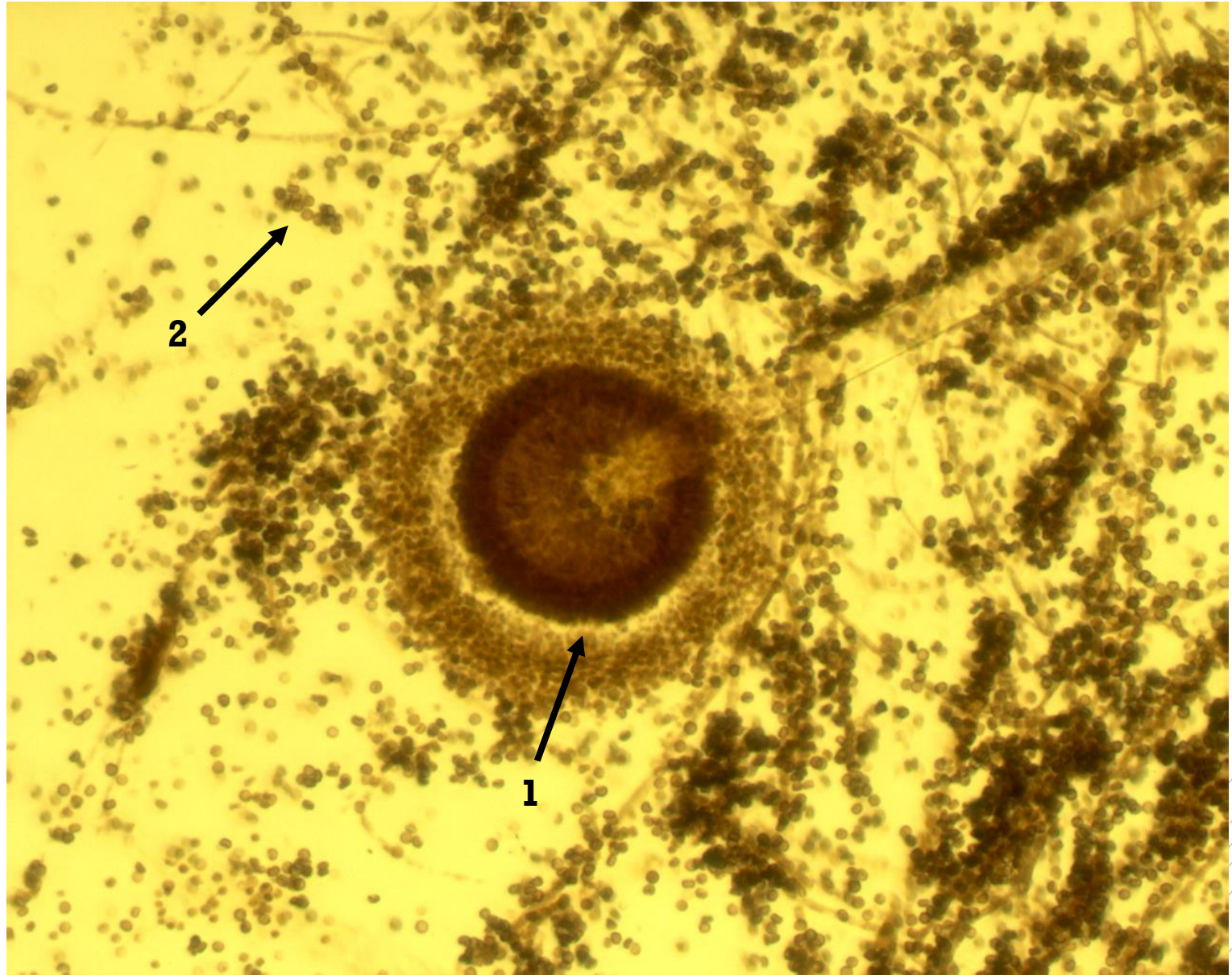# *Aspergillus fumigatus*

**Specimen:** culture

**Patient:** male, 85 years old

**Dg.:** lung aspergilloma

**Microscopy:** a conidiophore with a vesicle (1) and numerous conidia (2).



Author: MUDr. Svojtková, MUDr. Šolarová



CHARLES UNIVERSITY  
Second Faculty of Medicine

Slide No. 66

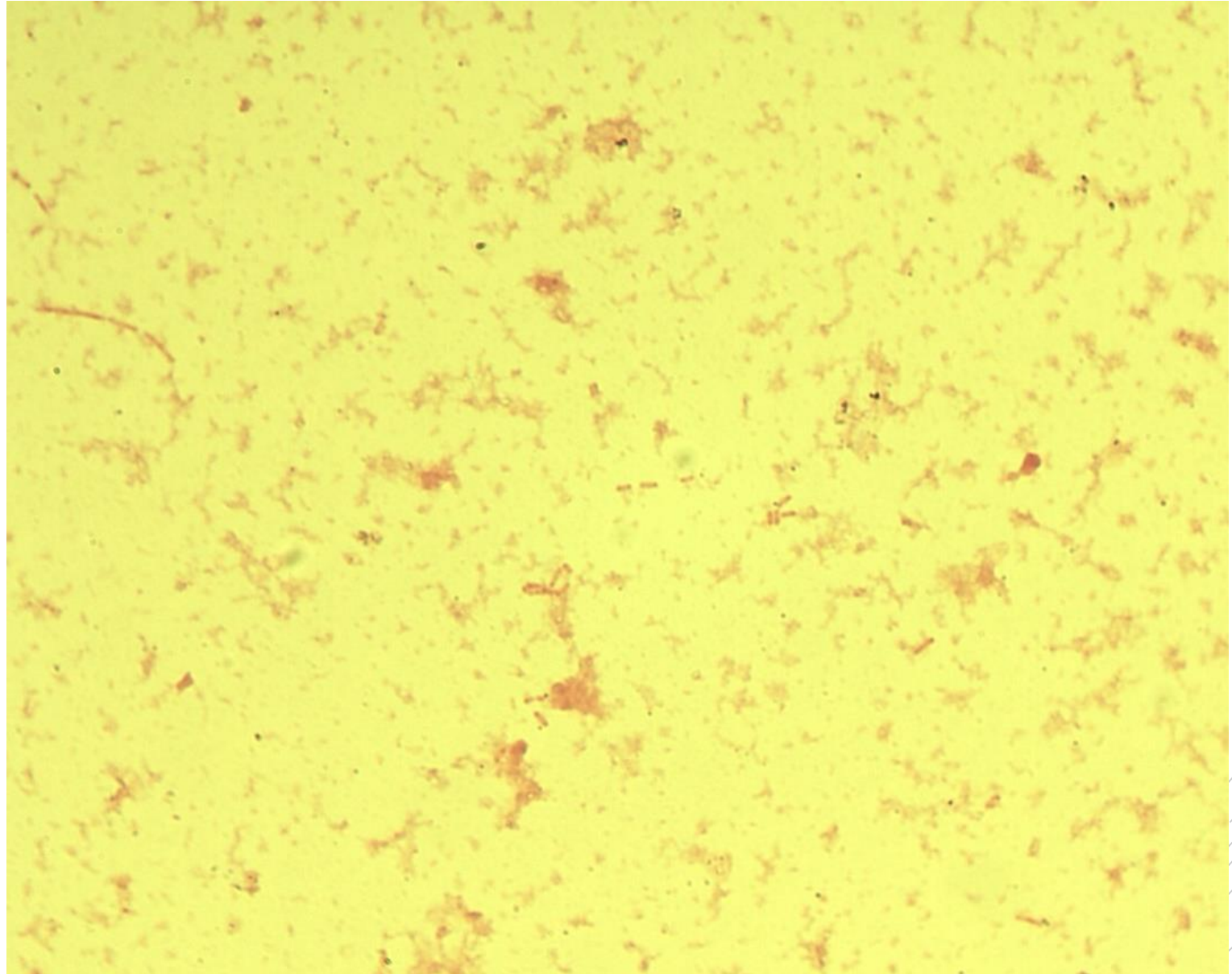
# *Escherichia coli*

**Specimen:** pus

**Patient:** female, 64 years old

**Dg.:** stomach cancer

**Microscopy:** Gram-negative rods



Author: MUDr. Alena Píšová



CHARLES UNIVERSITY  
Second Faculty of Medicine

Slide No. 66


# *Escherichia coli*

**Specimen:** pus

**Patient:** female, 64 years old

**Dg.:** stomach cancer

**Microscopy:** Gram-negative rods



Author: MUDr. Alena Píšová



CHARLES UNIVERSITY  
Second Faculty of Medicine

Slide No. 67

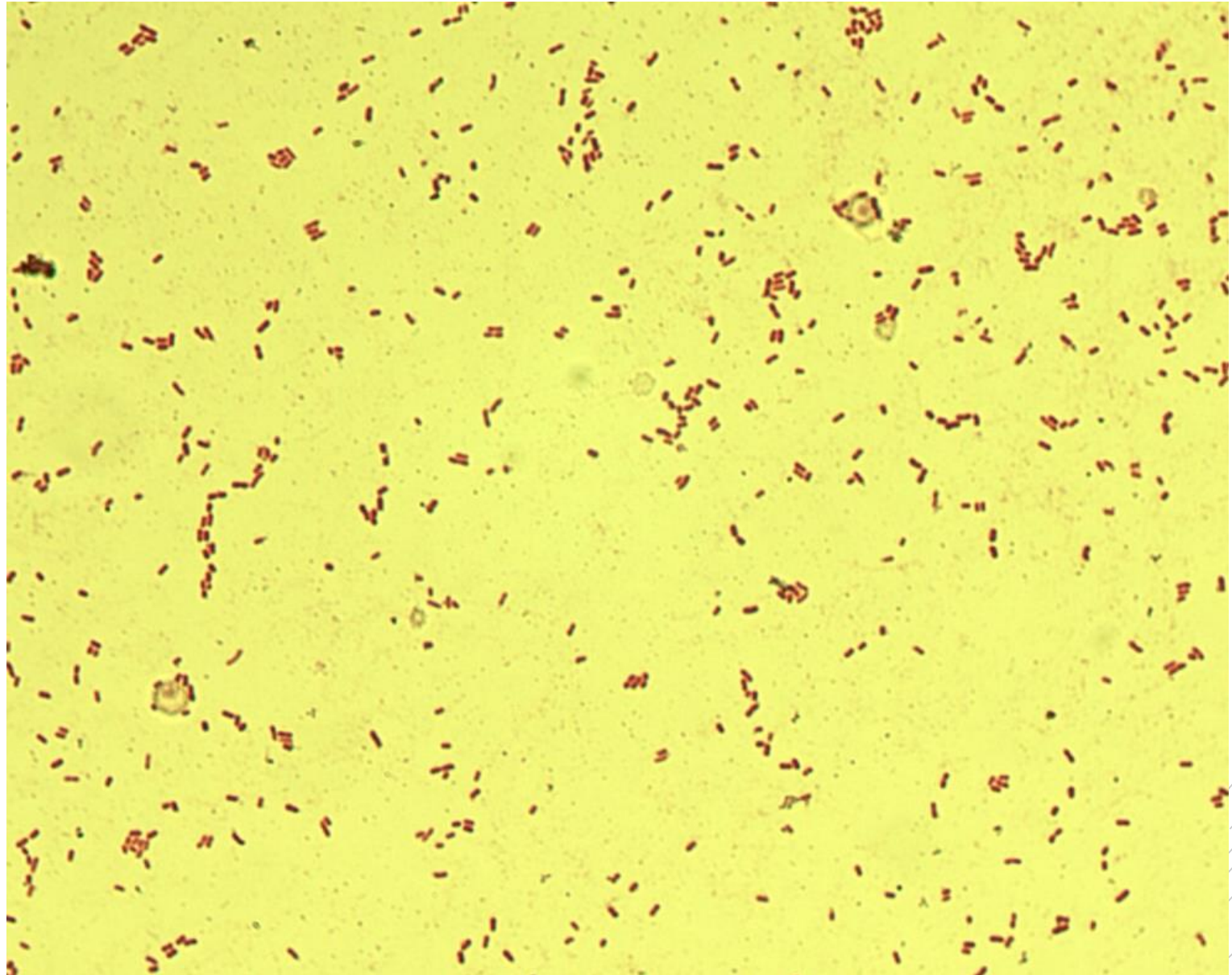
# *Klebsiella pneumoniae*

**Specimen:** gall aspirate

**Patient:** female, 64 years old

**Dg.:** gallbladder ulcer

**Microscopy:** Gram-negative rods



Author: MUDr. Alena Píšová



CHARLES UNIVERSITY  
Second Faculty of Medicine

Slide No. 67


# *Klebsiella pneumoniae*

**Specimen:** gall aspirate

**Patient:** female, 64 years old

**Dg.:** gallbladder ulcer

**Microscopy:** Gram-negative rods



Author: MUDr. Alena Píšová



CHARLES UNIVERSITY  
Second Faculty of Medicine

Slide No. 68

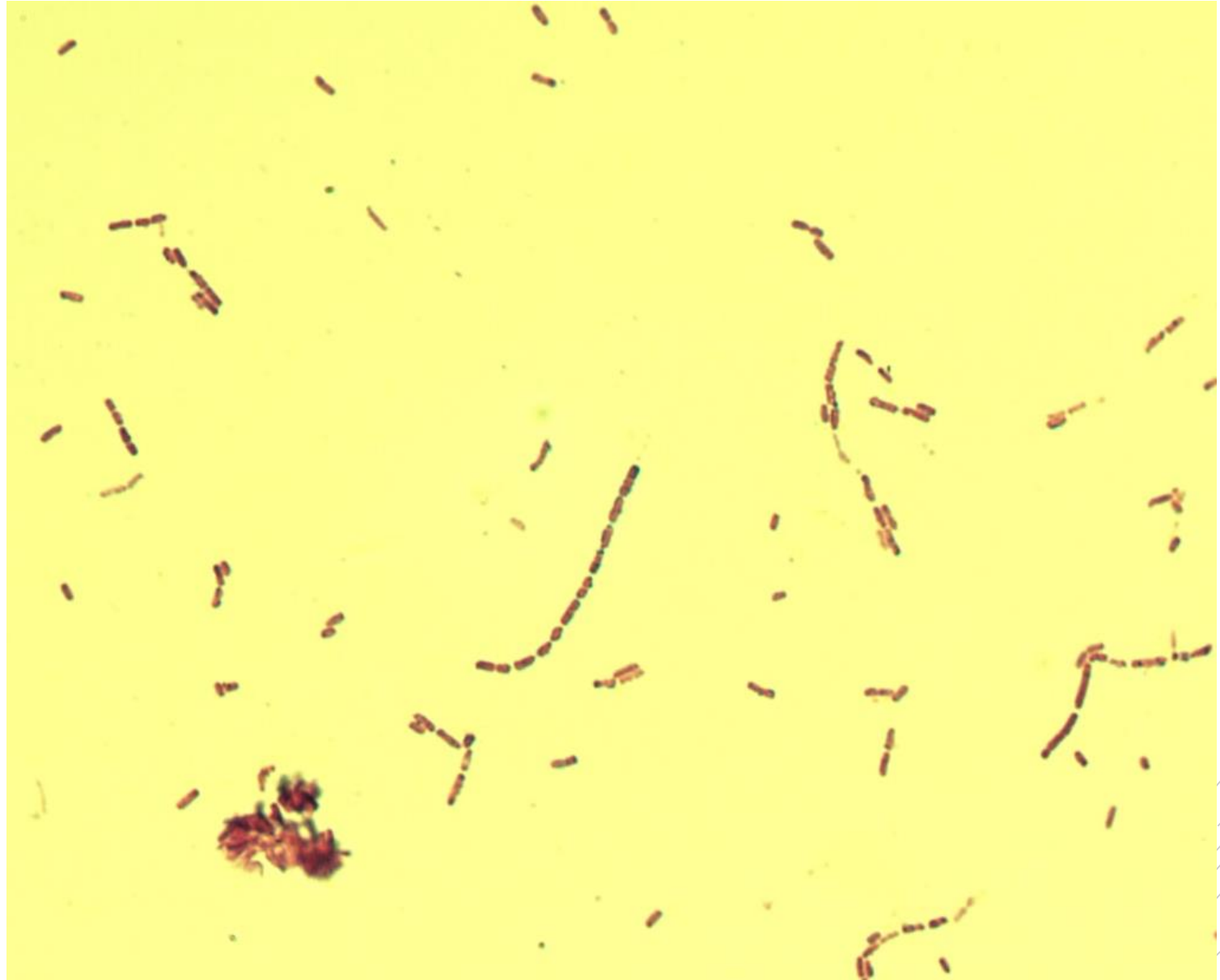
# *Bacillus cereus*

**Specimen:** blood culture

**Patient:** newborn

**Dg.:** sepsis

**Microscopy:** Gram-positive rods



Author: MUDr. Svojtková, MUDr. Šolarová





CHARLES UNIVERSITY  
Second Faculty of Medicine

Slide No. 68

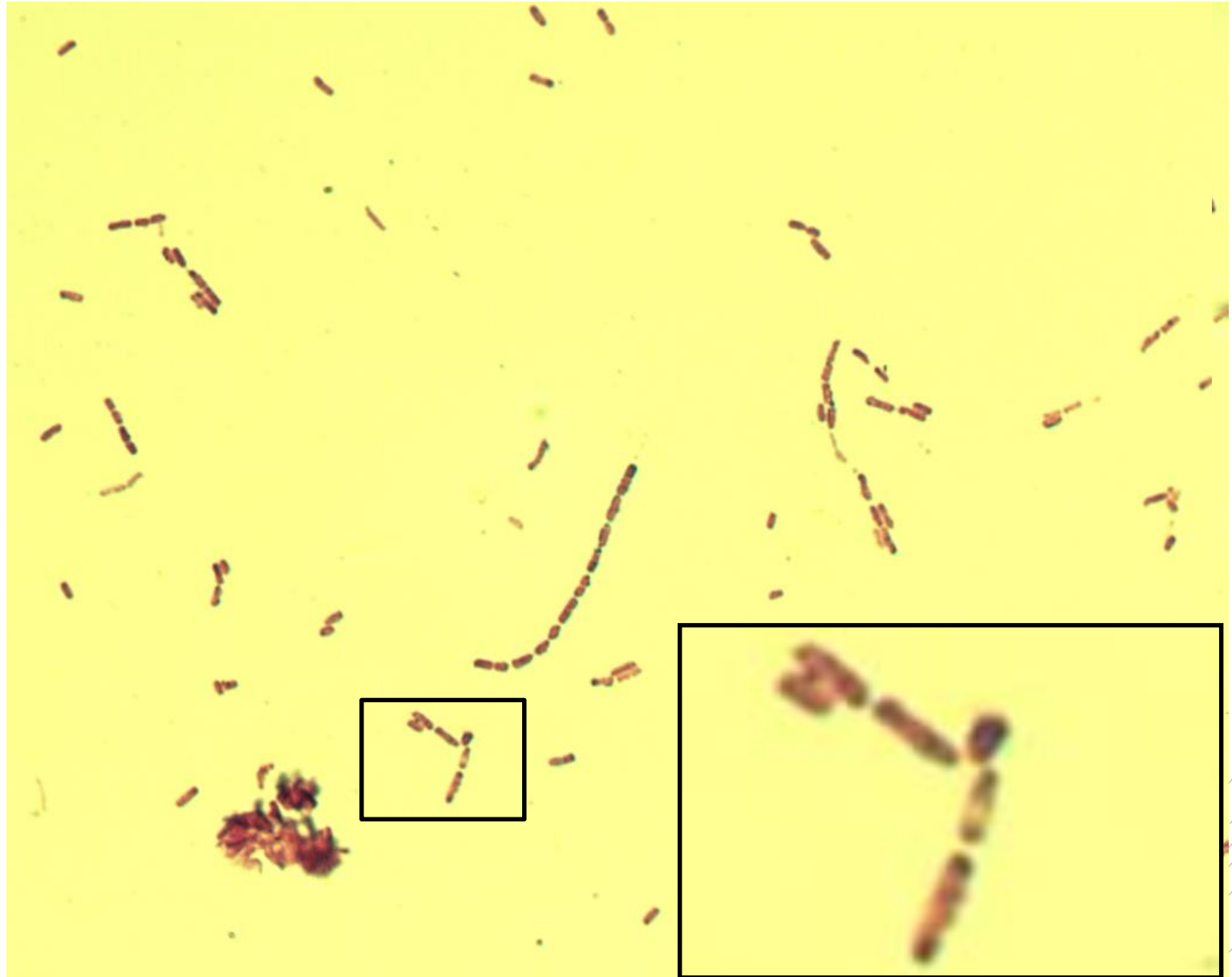
# *Bacillus cereus*

**Specimen:** blood culture

**Patient:** newborn

**Dg.:** sepsis

**Microscopy:** Gram-positive rods



Author: MUDr. Svojtková, MUDr. Šolarová



CHARLES UNIVERSITY  
Second Faculty of Medicine

Slide No. 69

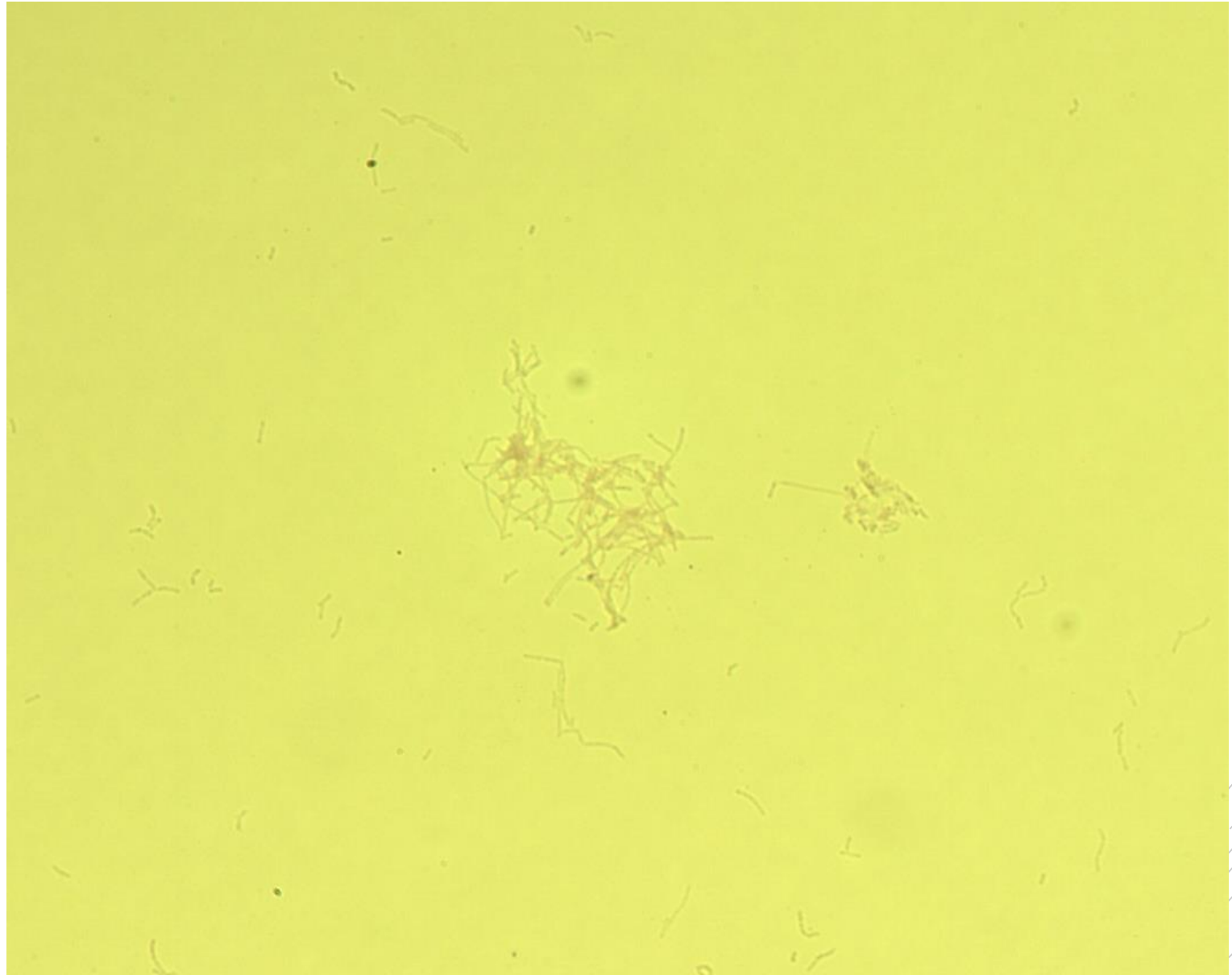
# *Nocardia faracinica*

**Specimen:** culture

**Patient:** male, 18 years old

**Dg.:** lung nocardiosis

**Microscopy:** filamentous rods  
(Ziehl-Neelsen stain)



Author: MUDr. Svojková, MUDr. Šolarová



CHARLES UNIVERSITY  
Second Faculty of Medicine

Slide No. 69


# *Nocardia faracinica*

**Specimen:** culture

**Patient:** male, 18 years old

**Dg.:** lung nocardiosis

**Microscopy:** filamentous rods  
(Ziehl-Neelsen stain)



Author: MUDr. Svojková, MUDr. Šolarová



CHARLES UNIVERSITY  
Second Faculty of Medicine

Slide No. 70

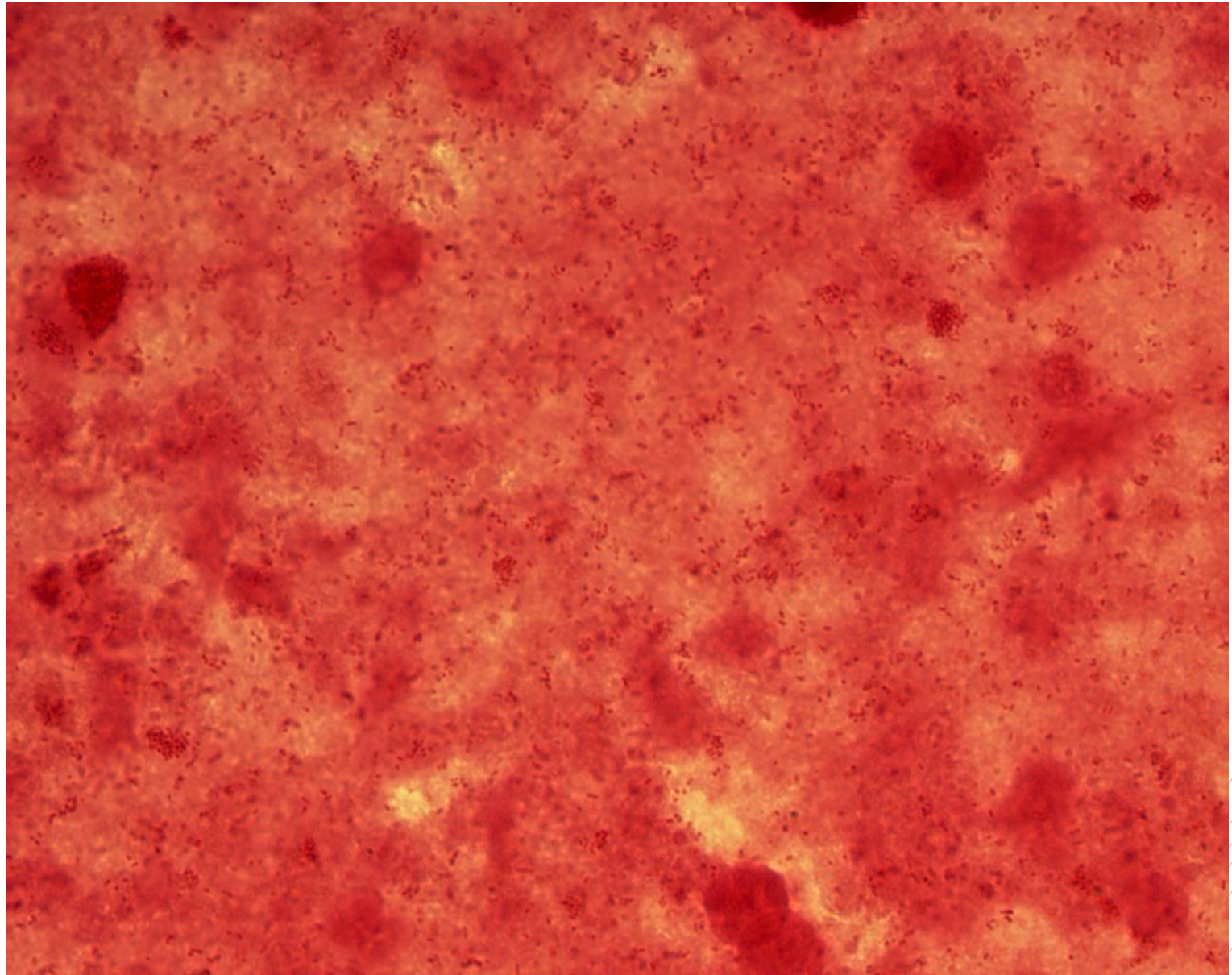
# *Prevotella melaninogenica*

**Specimen:** pus

**Patient:** male, 64 years old

**Dg.:** sinusitis

**Microscopy:** Gram-negative rods



Author: MUDr. Svojková, MUDr. Šolarová



CHARLES UNIVERSITY  
Second Faculty of Medicine

Slide No. 70


# *Prevotella melaninogenica*

**Specimen:** pus

**Patient:** male, 64 years old

**Dg.:** sinusitis

**Microscopy:** Gram-negative rods



Author: MUDr. Svojtková, MUDr. Šolarová



CHARLES UNIVERSITY  
Second Faculty of Medicine

Slide No. 71


# *Prevotella melaninogenica*

**Specimen:** culture

**Patient:** male, 64 years old

**Dg.:** sinusitis

**Microscopy:** Gram-negative rods



Author: MUDr. Svojková, MUDr. Šolarová



CHARLES UNIVERSITY  
Second Faculty of Medicine

Slide No. 71


# *Prevotella melaninogenica*

**Specimen:** culture

**Patient:** male, 64 years old

**Dg.:** sinusitis

**Microscopy:** Gram-negative rods



Author: MUDr. Svojková, MUDr. Šolarová



CHARLES UNIVERSITY  
Second Faculty of Medicine

Slide No. 72

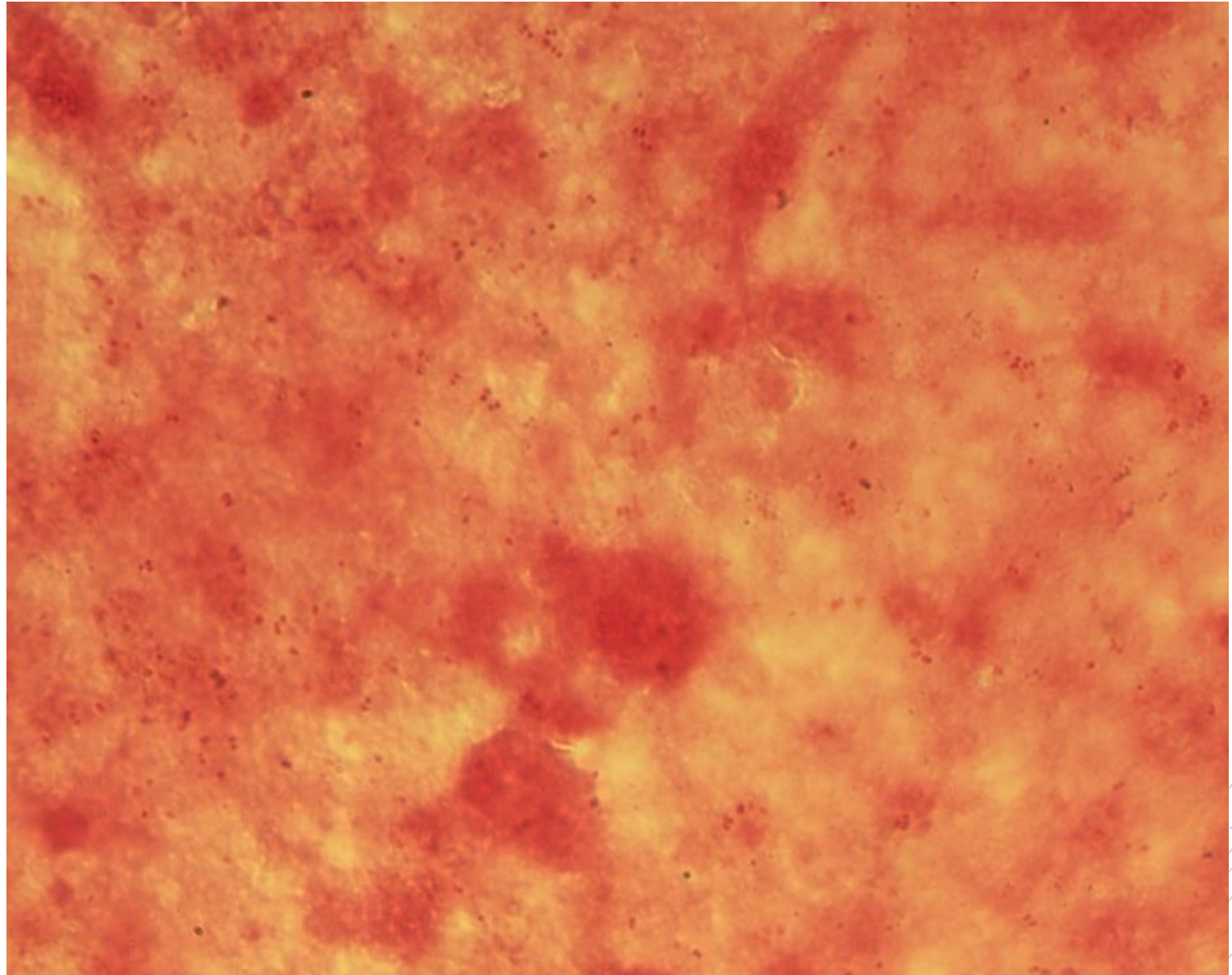
# *Neisseria gonorrhoeae*

**Specimen:** pus

**Patient:** male, 20 years old

**Dg.:** urethritis

**Microscopy:** Gram-negative diplococci



Author: MUDr. Svojtková, MUDr. Šolarová





CHARLES UNIVERSITY  
Second Faculty of Medicine

Slide No. 72


# *Neisseria gonorrhoeae*

**Specimen:** pus

**Patient:** male, 20 years old

**Dg.:** urethritis

**Microscopy:** Gram-negative diplococci



Author: MUDr. Svojtková, MUDr. Šolarová



CHARLES UNIVERSITY  
Second Faculty of Medicine

Slide No. 73


# *Neisseria gonorrhoeae*

**Specimen:** culture

**Patient:** male, 20 years old

**Dg.:** urethritis

**Microscopy:** Gram-negative diplococci



Author: MUDr. Svojtková, MUDr. Šolarová



CHARLES UNIVERSITY  
Second Faculty of Medicine

Slide No. 73

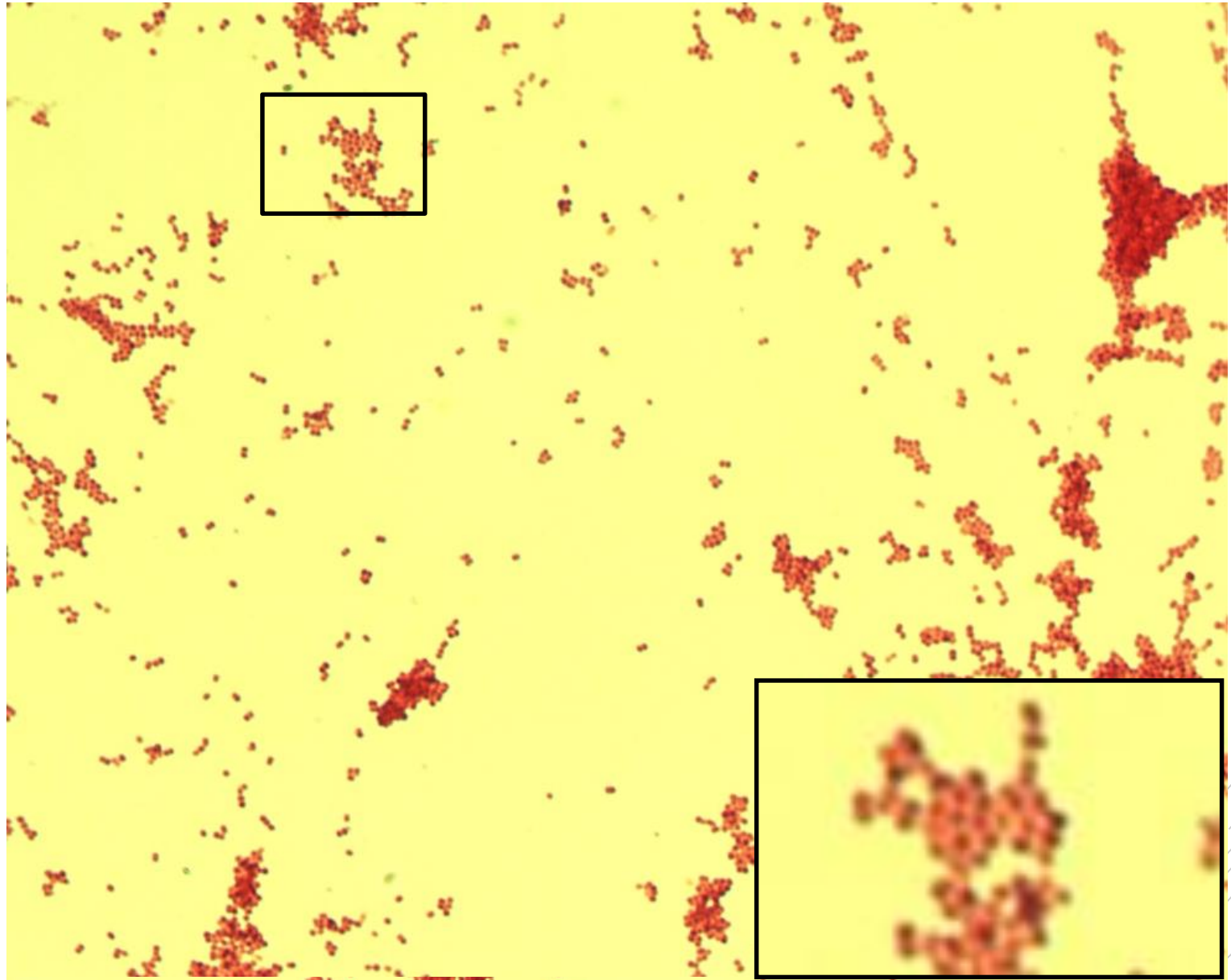
# *Neisseria gonorrhoeae*

**Specimen:** culture

**Patient:** male, 20 years old

**Dg.:** urethritis

**Microscopy:** Gram-negative diplococci



Author: MUDr. Svojtková, MUDr. Šolarová



CHARLES UNIVERSITY  
Second Faculty of Medicine

Slide No. 74


# *Bacteroides fragilis*

**Specimen:** pus

**Patient:** female, 73 years old

**Dg.:** gallbladder inflammation

**Microscopy:** Gram-negative rods



Author: MUDr. Svojtková, MUDr. Šolarová



CHARLES UNIVERSITY  
Second Faculty of Medicine

Slide No. 74


# *Bacteroides fragilis*

**Specimen:** pus

**Patient:** female, 73 years old

**Dg.:** gallbladder inflammation

**Microscopy:** Gram-negative rods



Author: MUDr. Svojtková, MUDr. Šolarová



CHARLES UNIVERSITY  
Second Faculty of Medicine

Slide No. 75

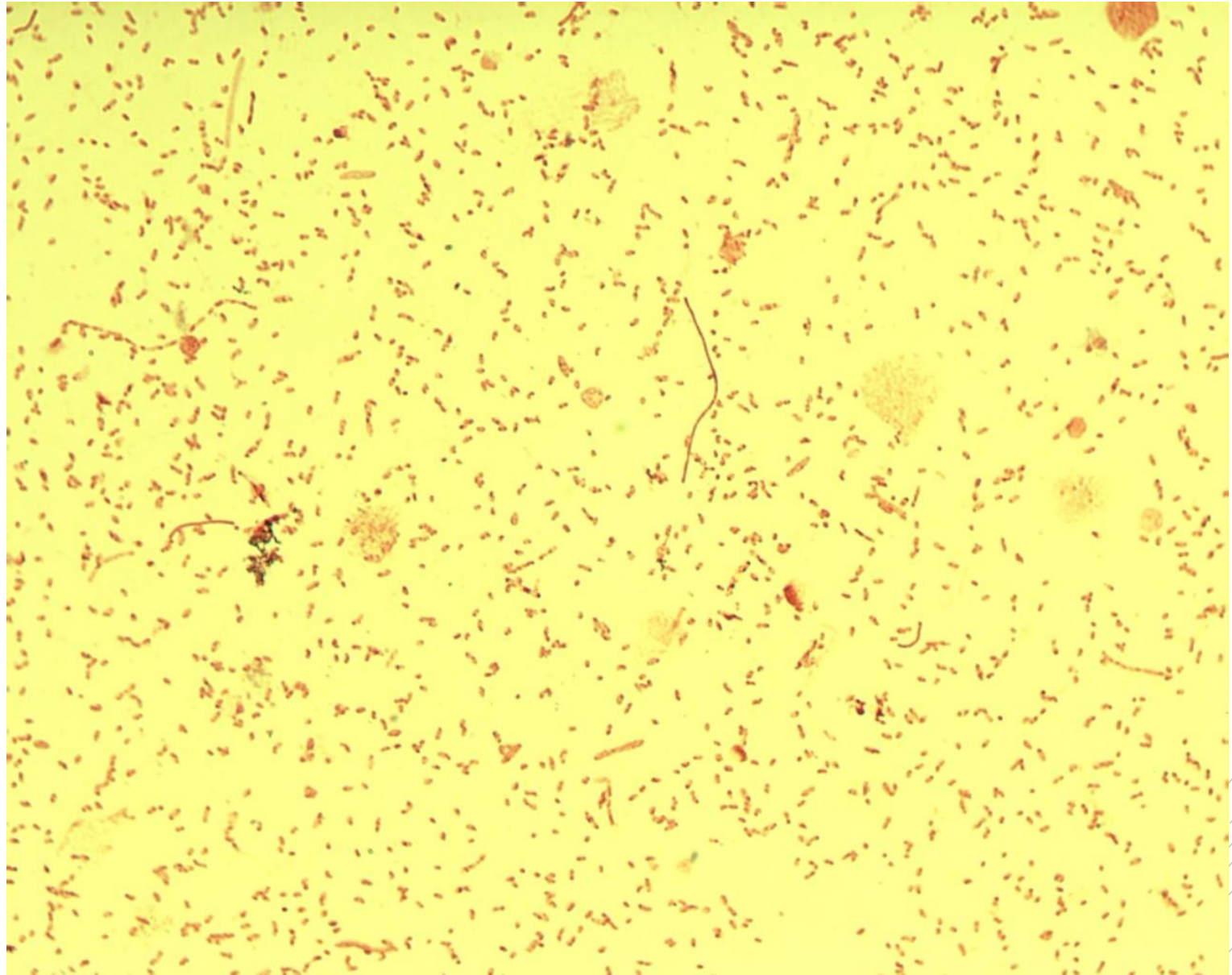
# *Bacteroides fragilis*

**Specimen:** culture

**Patient:** female, 73 years old

**Dg.:** gallbladder inflammation

**Microscopy:** Gram-negative coccobacilli and rods



Author: MUDr. Svojtková, MUDr. Šolarová



CHARLES UNIVERSITY  
Second Faculty of Medicine

Slide No. 75


# *Bacteroides fragilis*

**Specimen:** culture

**Patient:** female, 73 years old

**Dg.:** gallbladder inflammation

**Microscopy:** Gram-negative coccobacilli and rods



Author: MUDr. Svojtková, MUDr. Šolarová



CHARLES UNIVERSITY  
Second Faculty of Medicine

Slide No. 76

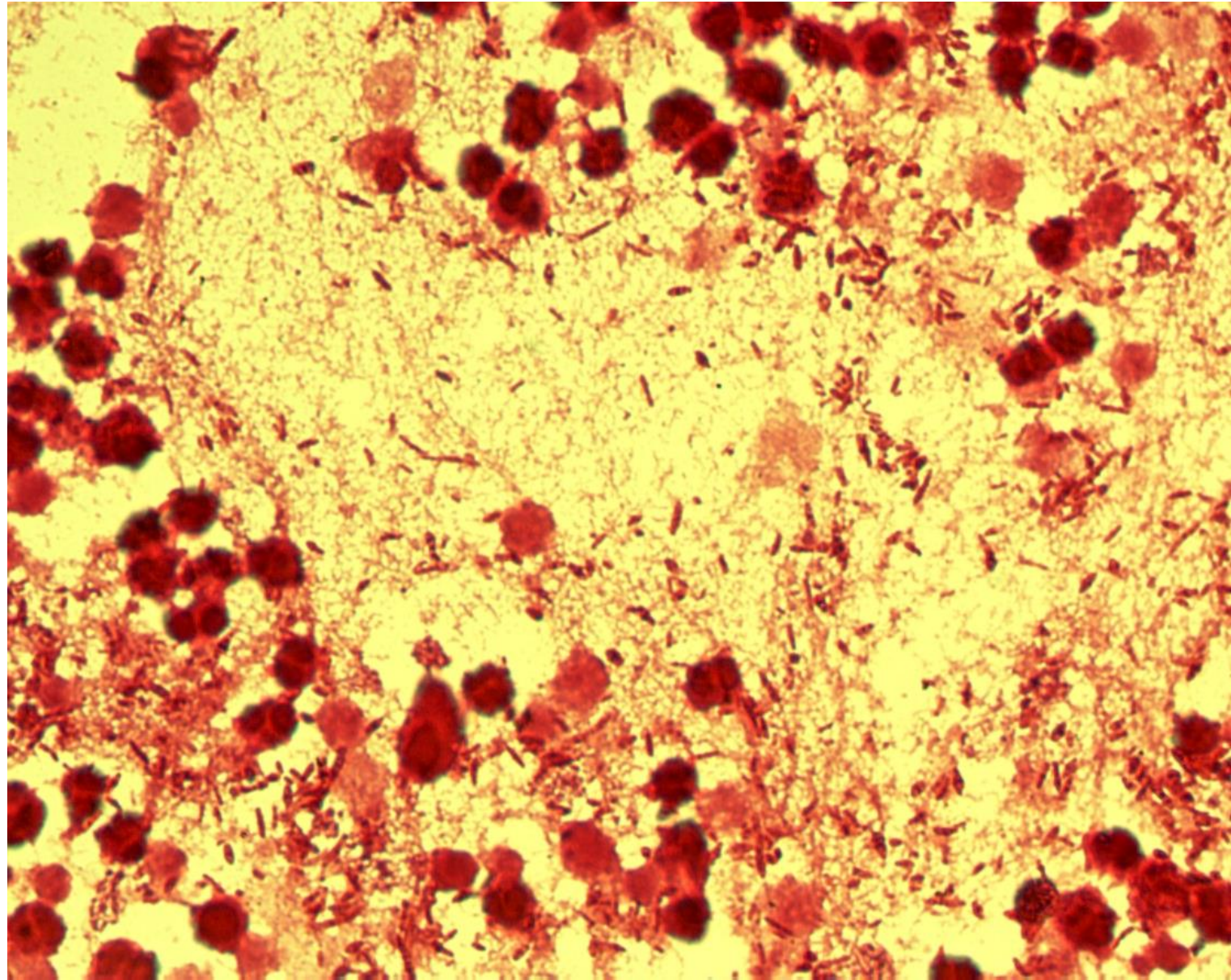
# *Proteus mirabilis*

**Specimen:** gall

**Patient:** female, 27 years old

**Dg.:** gallbladder inflammation

**Microscopy:** Gram-negative rods



Author: MUDr. Alena Píšová





CHARLES UNIVERSITY  
Second Faculty of Medicine

Slide No. 76

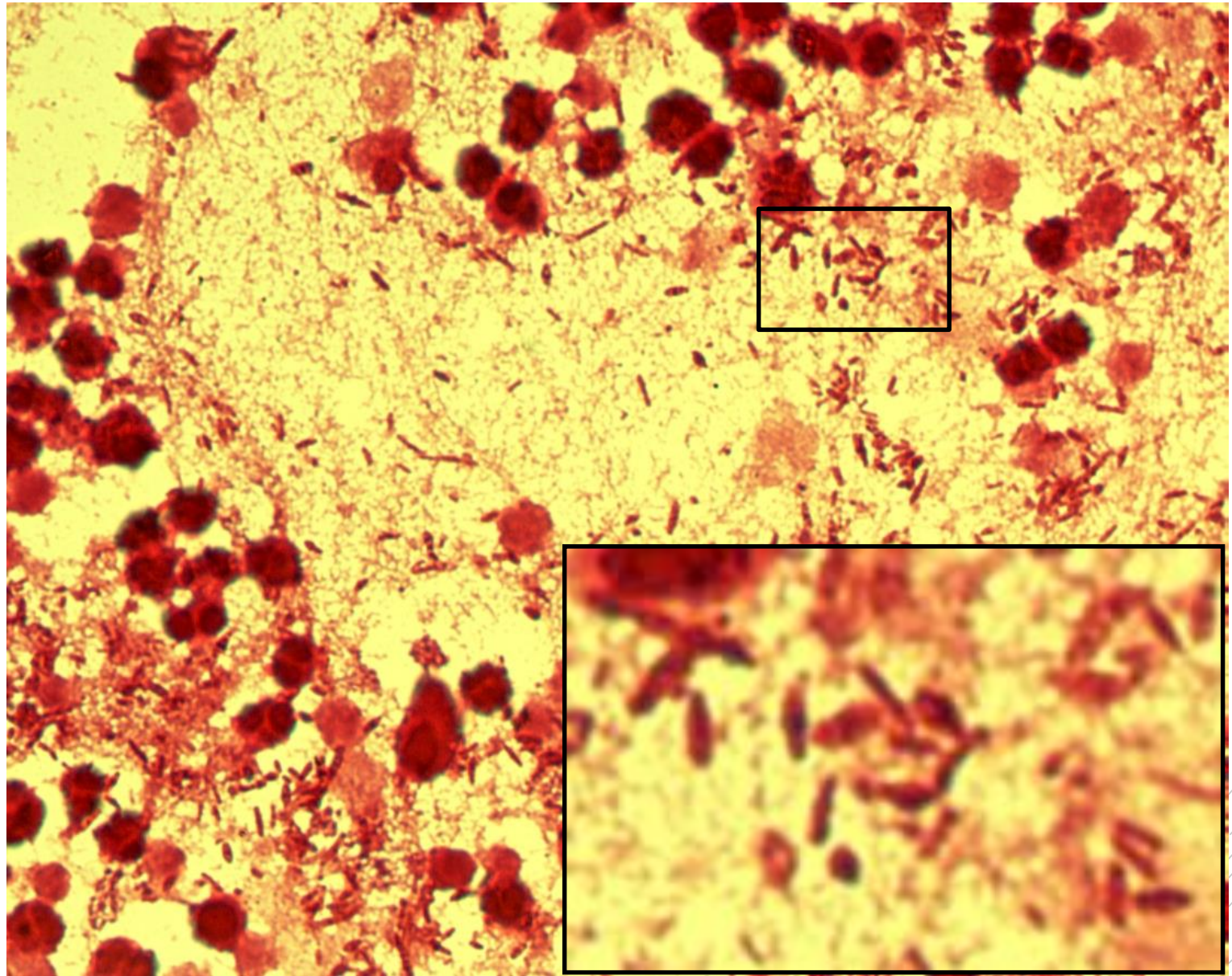
# *Proteus mirabilis*

**Specimen:** gall

**Patient:** female, 27 years old

**Dg.:** gallbladder inflammation

**Microscopy:** Gram-negative rods



Author: MUDr. Alena Píšová



CHARLES UNIVERSITY  
Second Faculty of Medicine

Slide No. 77

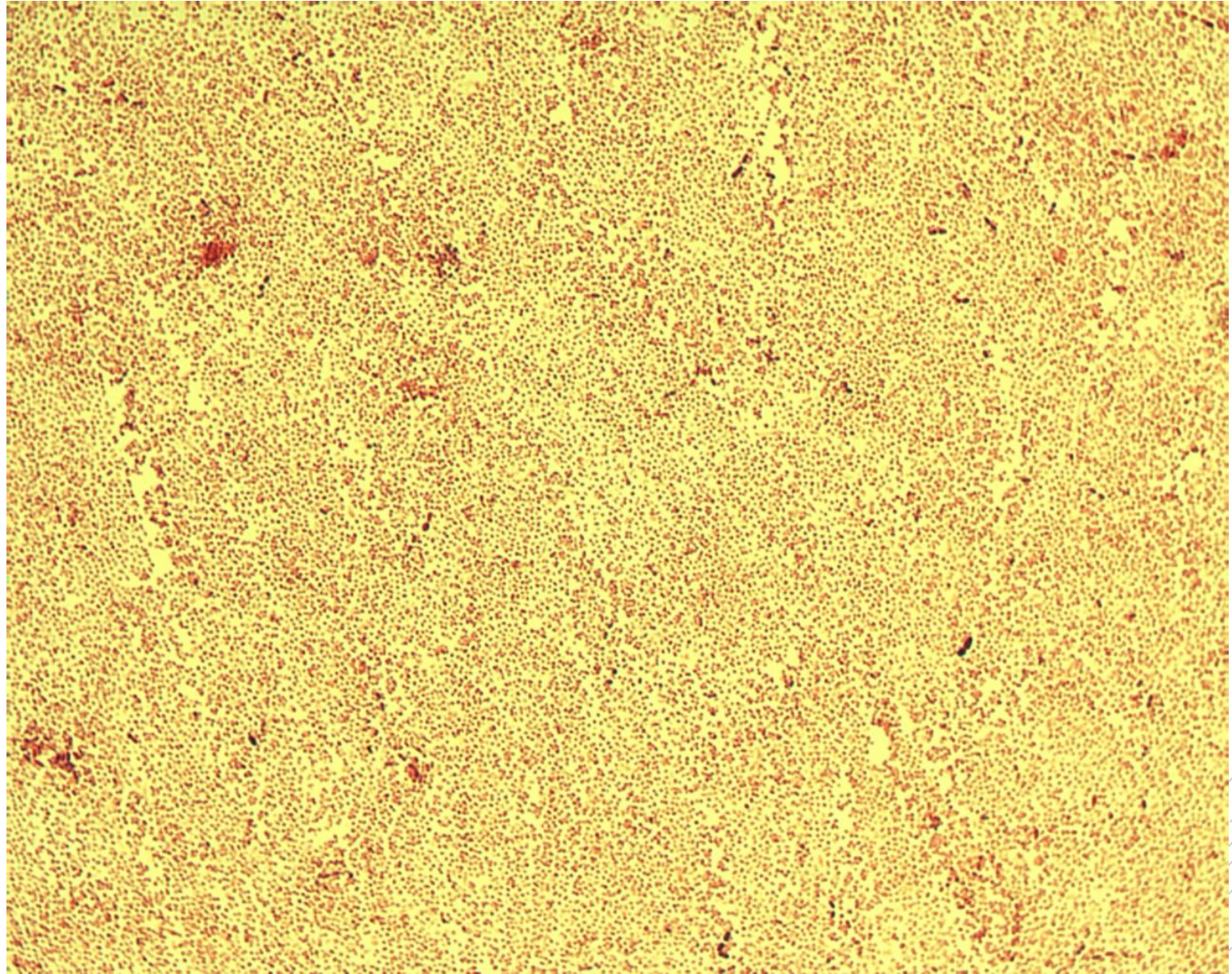
# *Pasteurella multocida*

**Specimen:** bronchial secretion

**Patient:** male, 10 years old

**Dg.:** pneumonia

**Microscopy:** Gram-negative coccobacilli



Author: MUDr. Lenka Tritová



CHARLES UNIVERSITY  
Second Faculty of Medicine

Slide No. 77

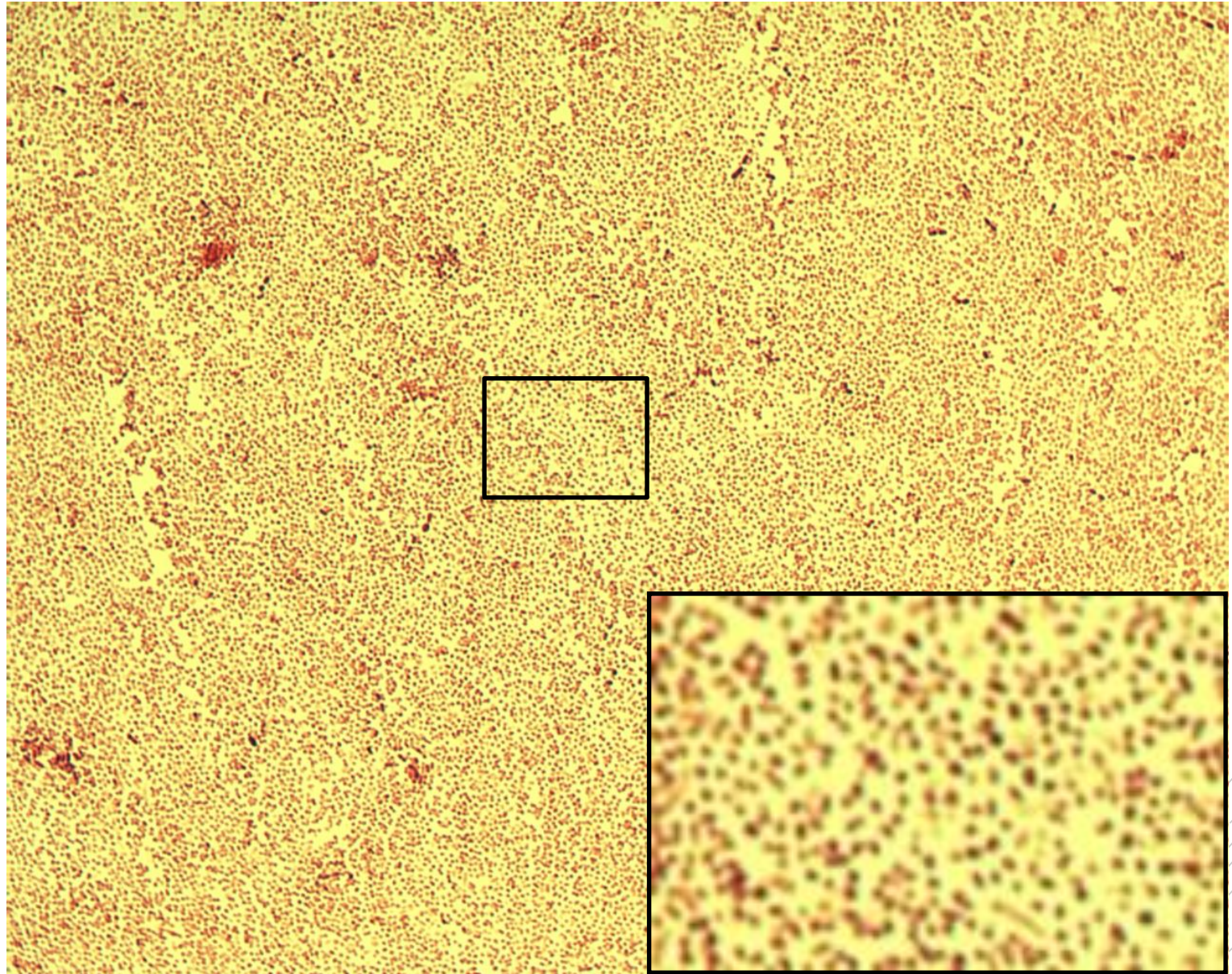
# *Pasteurella multocida*

**Specimen:** bronchial secretion

**Patient:** male, 10 years old

**Dg.:** pneumonia

**Microscopy:** Gram-negative coccobacilli



Author: MUDr. Lenka Tritová



CHARLES UNIVERSITY  
Second Faculty of Medicine

Slide No. 78

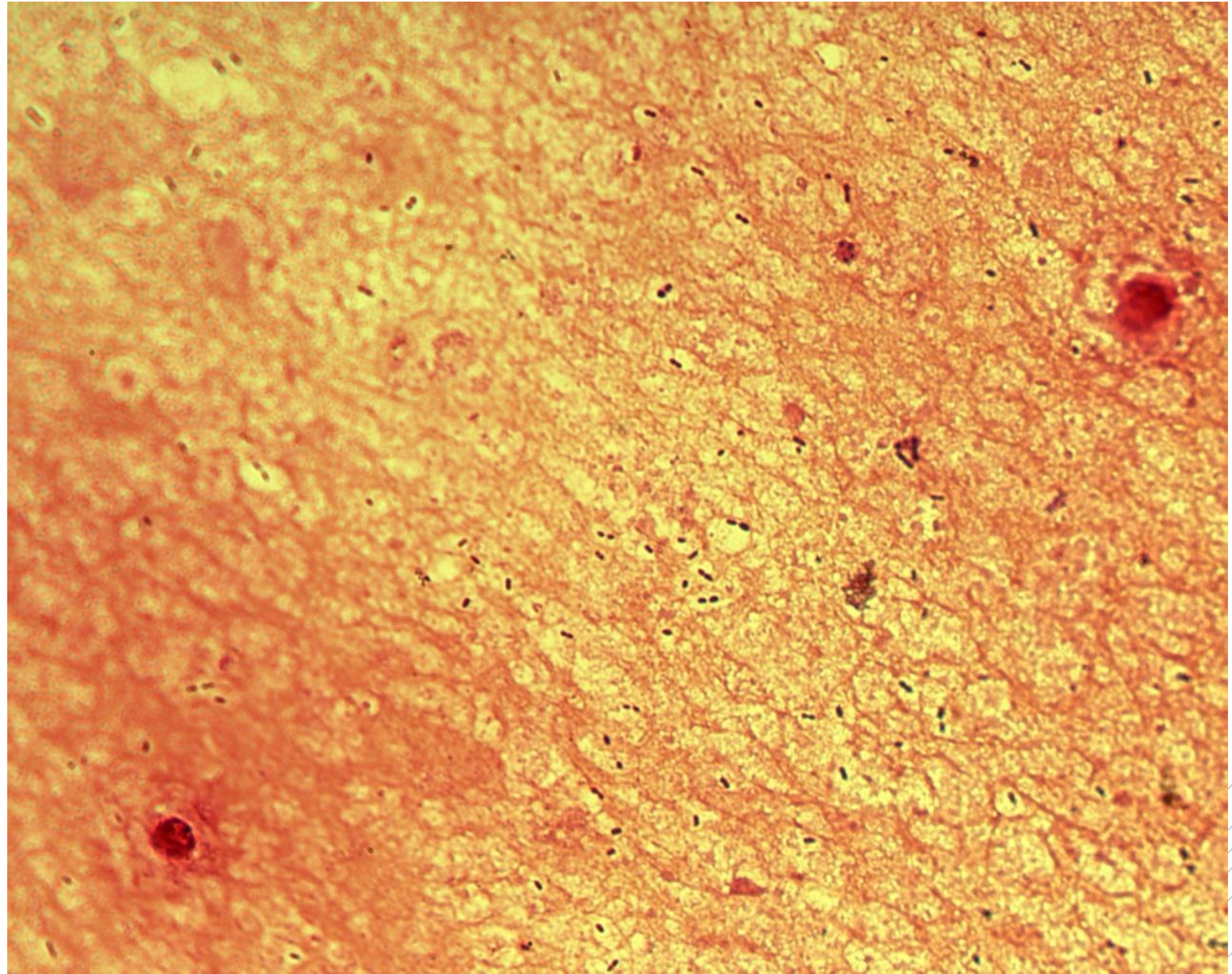
# *Streptococcus pneumoniae*

**Specimen:** sputum

**Patient:** female, 28 years old

**Dg.:** pneumonia

**Microscopy:** encapsulated  
Gram-positive diplococci



Author: MUDr. Svojtková, MUDr. Šolarová



CHARLES UNIVERSITY  
Second Faculty of Medicine

Slide No. 78

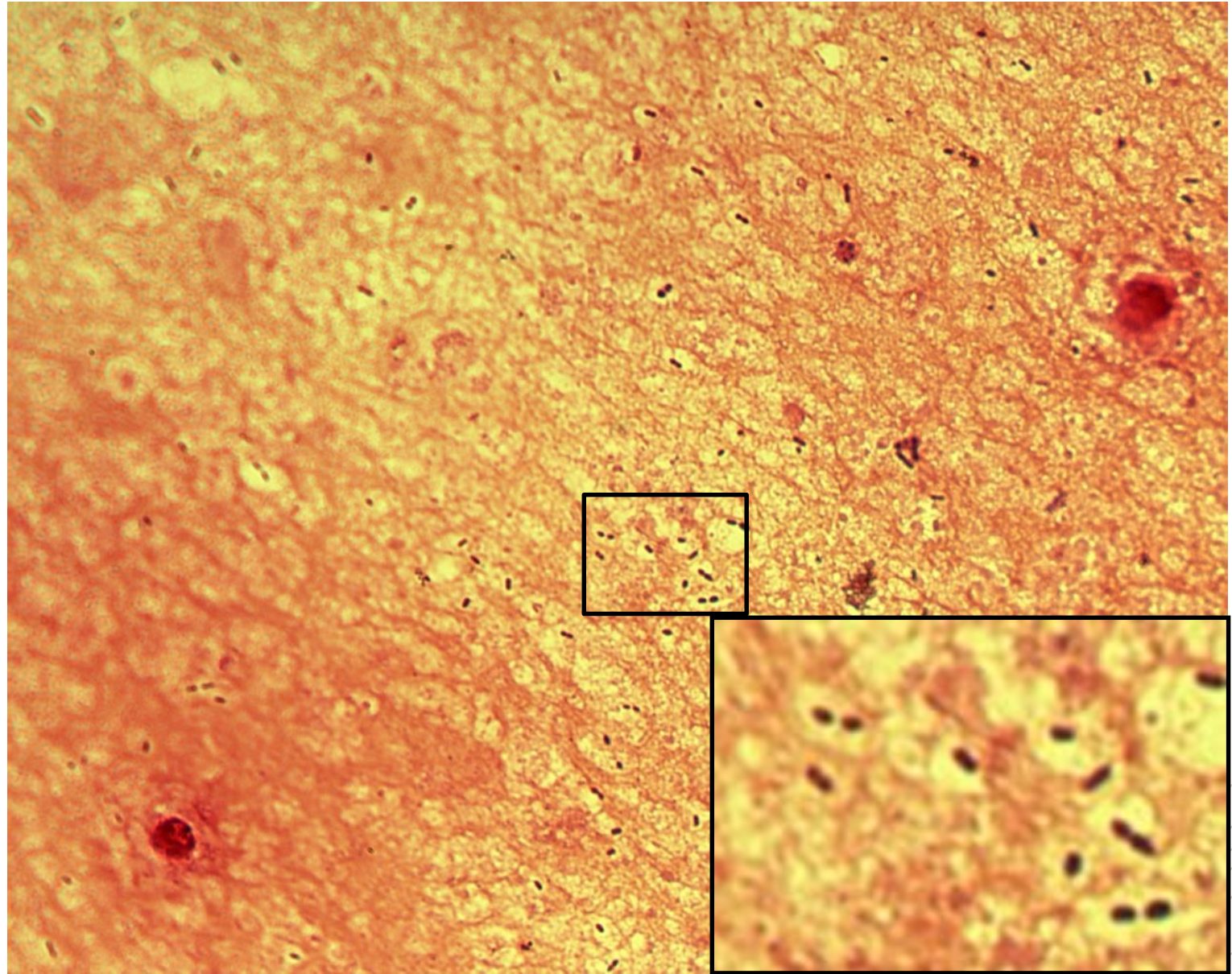
# *Streptococcus pneumoniae*

**Specimen:** sputum

**Patient:** female, 28 years old

**Dg.:** pneumonia

**Microscopy:** encapsulated  
Gram-positive diplococci



Author: MUDr. Svojtková, MUDr. Šolarová



CHARLES UNIVERSITY  
Second Faculty of Medicine

Slide No. 79

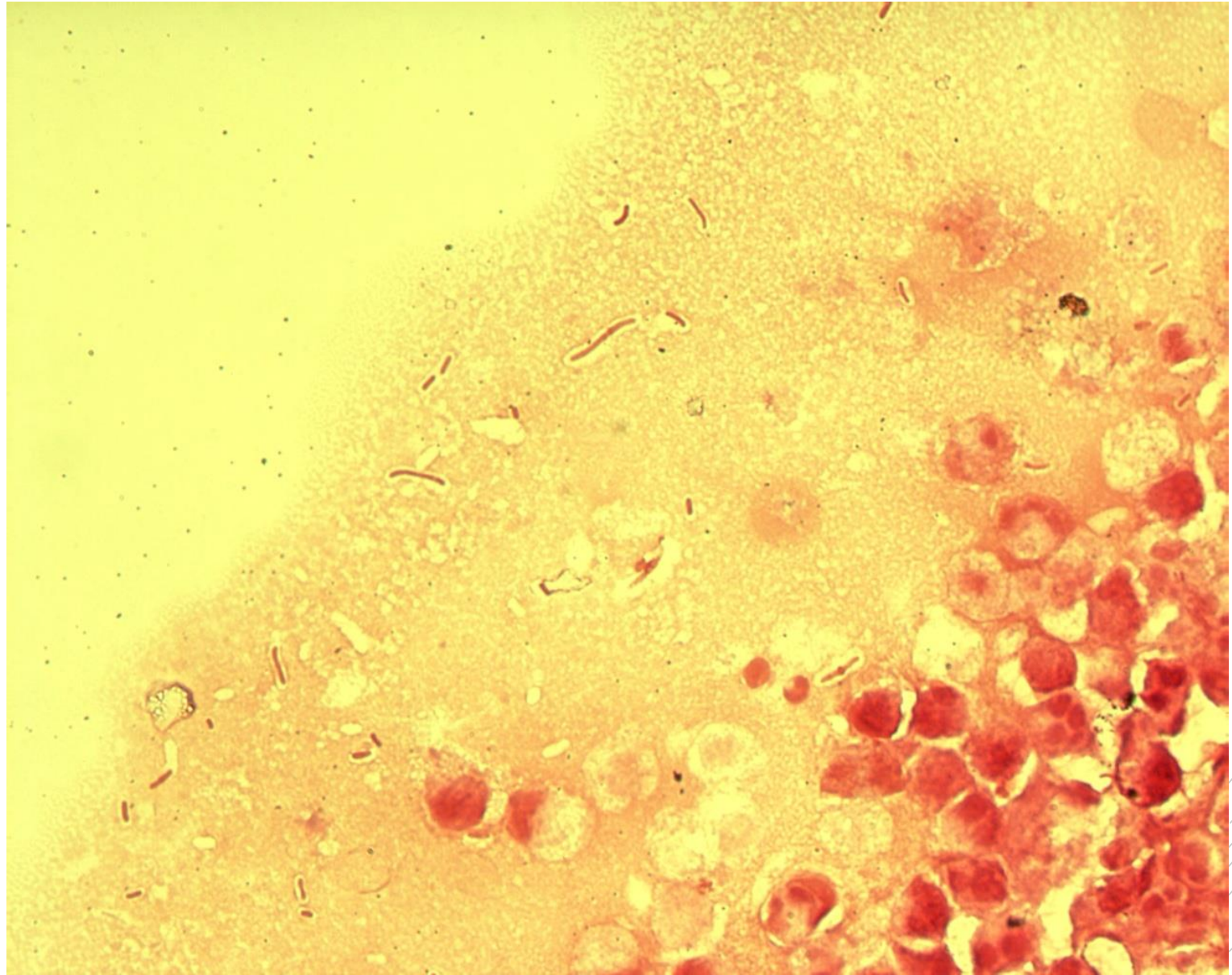
# *Klebsiella pneumoniae*

**Specimen:** gall

**Patient:** female, 62 years old

**Dg.:** gallbladder inflammation

**Microscopy:** Gram-negative rods



Author: MUDr. Alena Pířová



CHARLES UNIVERSITY  
Second Faculty of Medicine

Slide No. 79

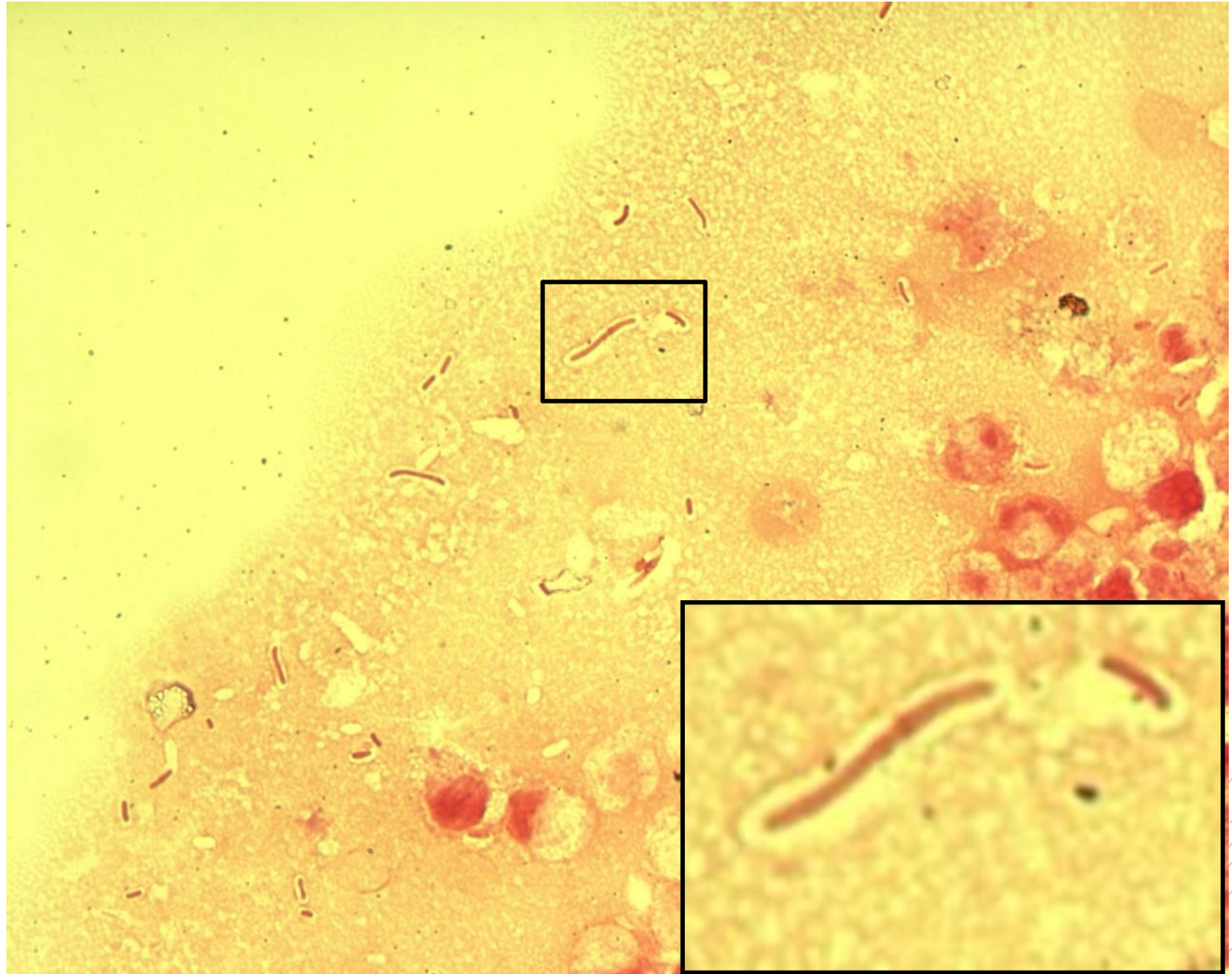
# *Klebsiella pneumoniae*

**Specimen:** gall

**Patient:** female, 62 years old

**Dg.:** gallbladder inflammation

**Microscopy:** Gram-negative rods



Author: MUDr. Alena Pířová



CHARLES UNIVERSITY  
Second Faculty of Medicine

Slide No. 80

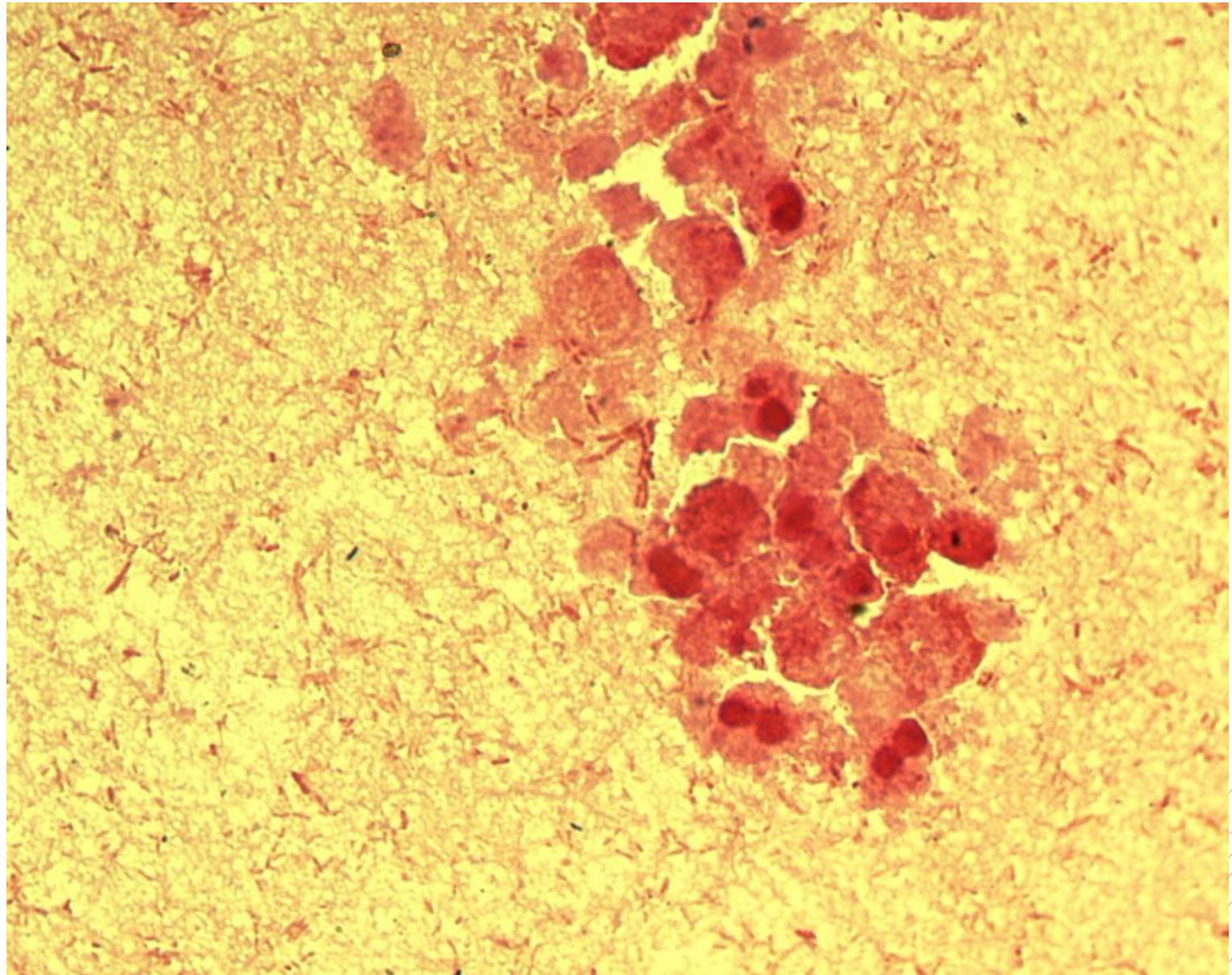
# *Morganella morganii*

**Specimen:** pus

**Patient:** male, 86 years old

**Dg.:** acute peritonitis

**Microscopy:** Gram-negative rods



Author: MUDr. Alena Píšová





CHARLES UNIVERSITY  
Second Faculty of Medicine

Slide No. 80

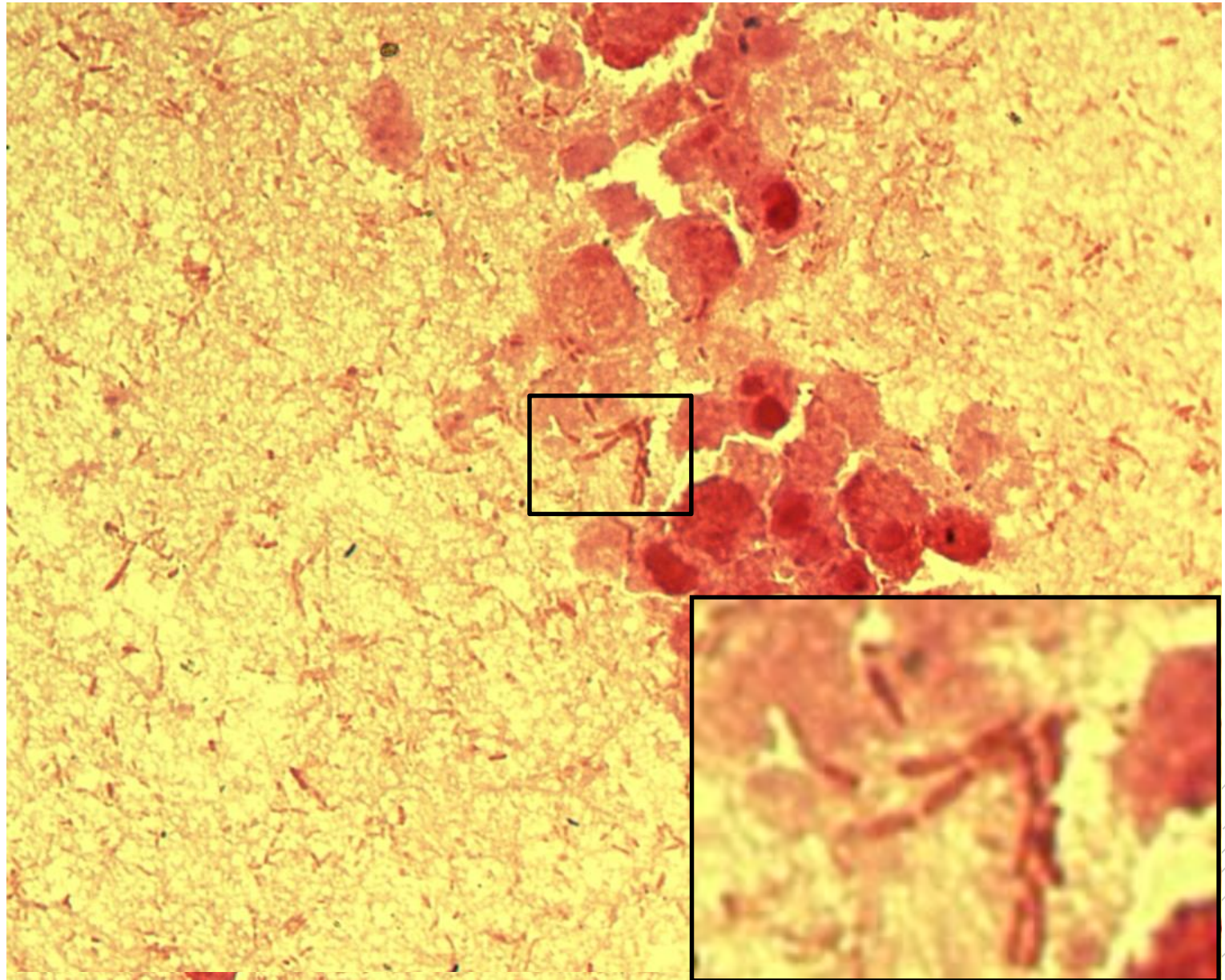
# *Morganella morganii*

**Specimen:** pus

**Patient:** male, 86 years old

**Dg.:** acute peritonitis

**Microscopy:** Gram-negative rods



Author: MUDr. Alena Pířová



CHARLES UNIVERSITY  
Second Faculty of Medicine

Slide No. 81

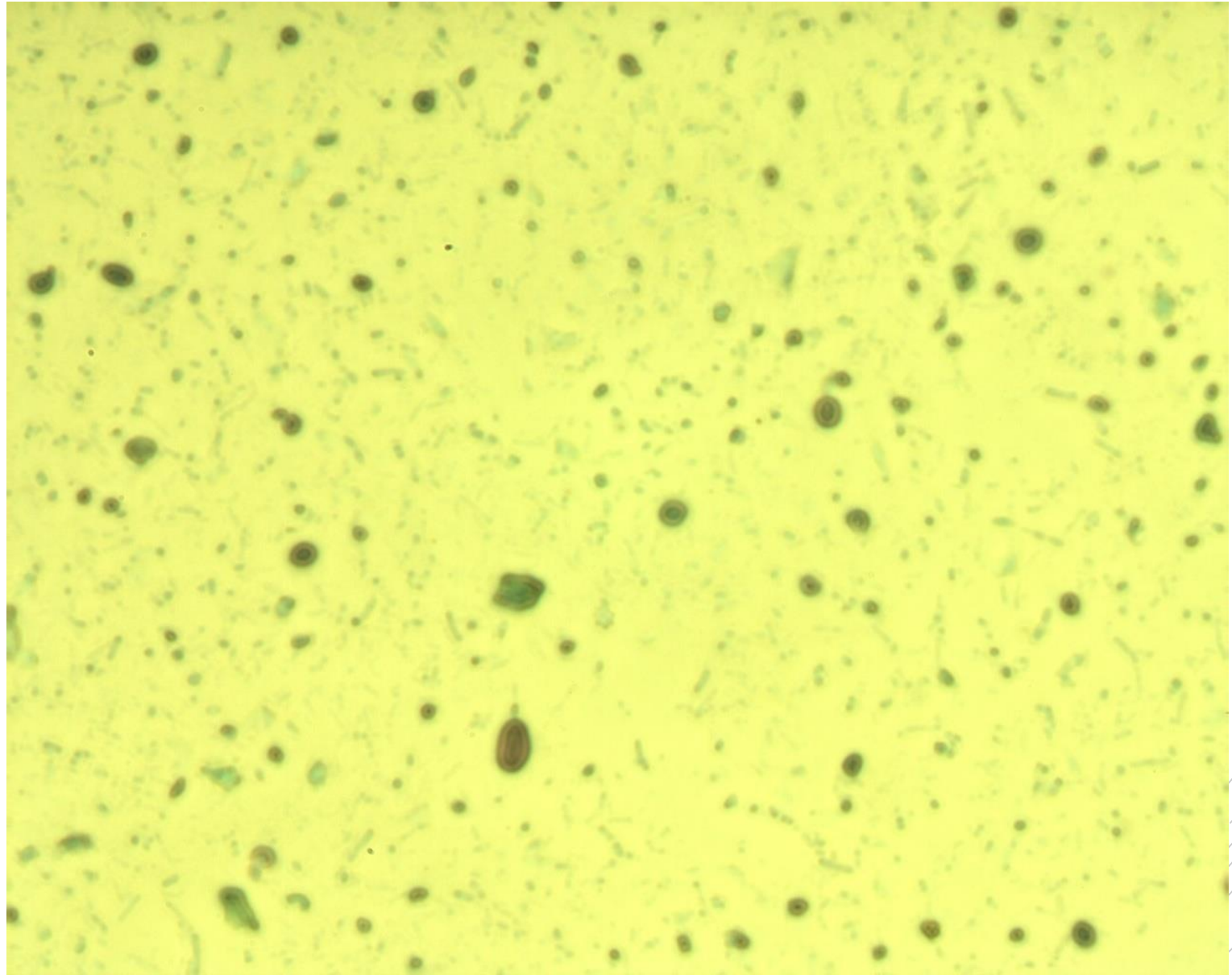
# *Cryptosporidium* *spp.*

**Specimen:** stools

**Patient:** female, 28 years old

**Dg.:** gastroenteritis

**Microscopy:** oocysts



Author: MUDr. Kamila Dundrová

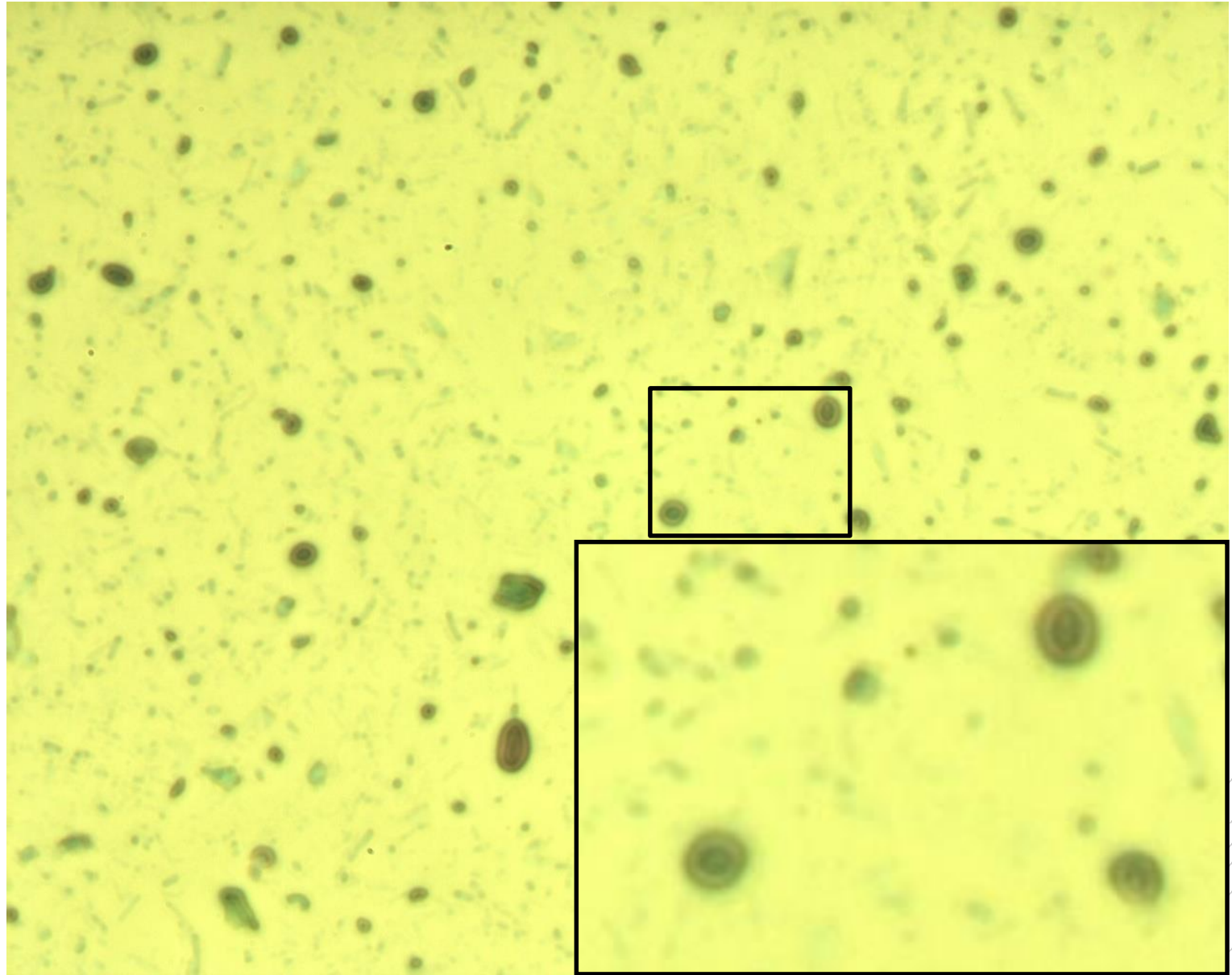


CHARLES UNIVERSITY  
Second Faculty of Medicine

Slide No. 81

# *Cryptosporidium* *spp.*

**Specimen:** stools  
**Patient:** female, 28 years old  
**Dg.:** gastroenteritis  
**Microscopy:** oocysts



Author: MUDr. Kamila Dundrová



CHARLES UNIVERSITY  
Second Faculty of Medicine

Slide No. 82

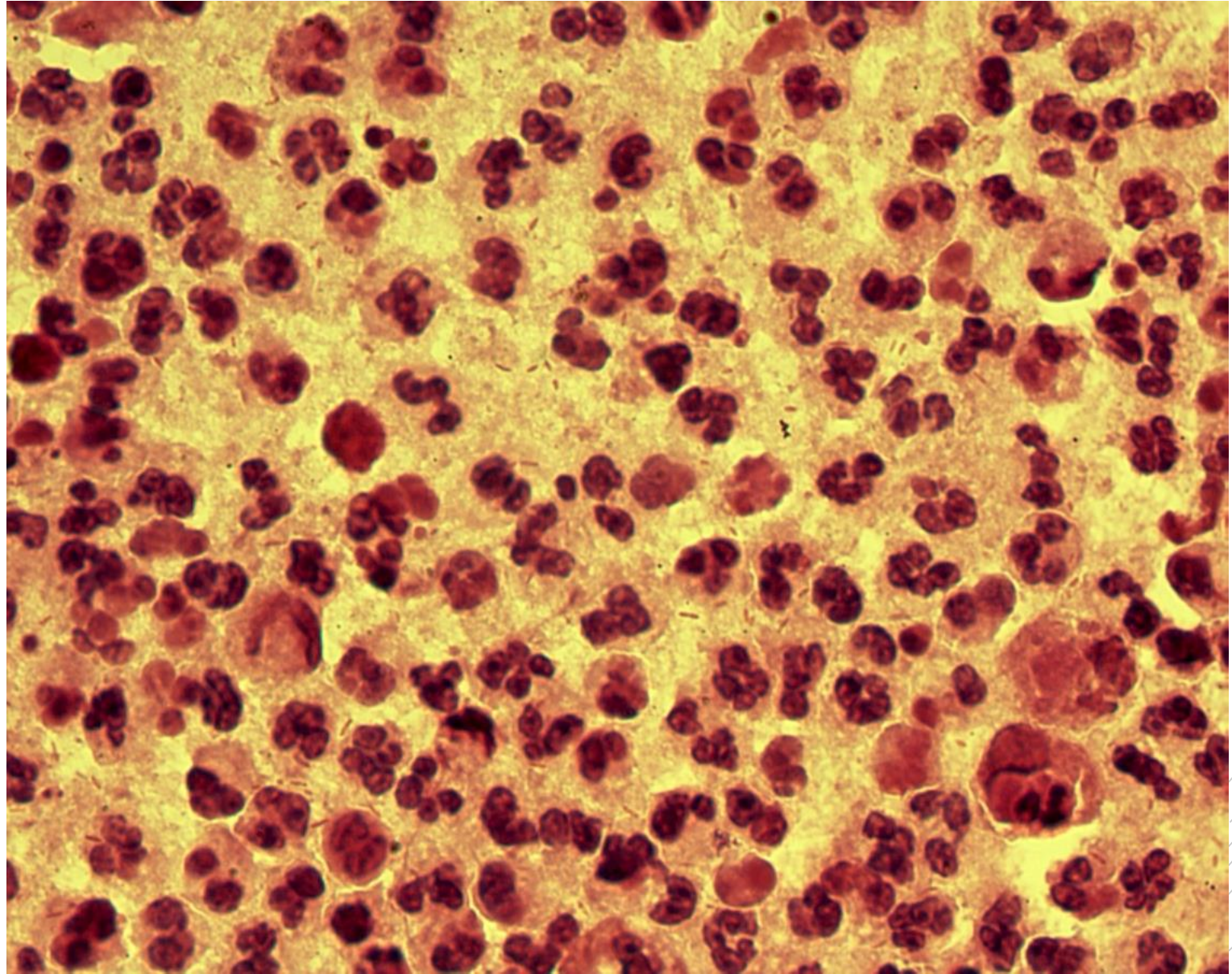
# *Bacteroides fragilis*

**Specimen:** pus

**Patient:** female, 39 years old

**Dg.:** rectal abscess

**Microscopy:** Gram-negative rods



Author: MUDr. Alena Pířová



CHARLES UNIVERSITY  
Second Faculty of Medicine

Slide No. 82

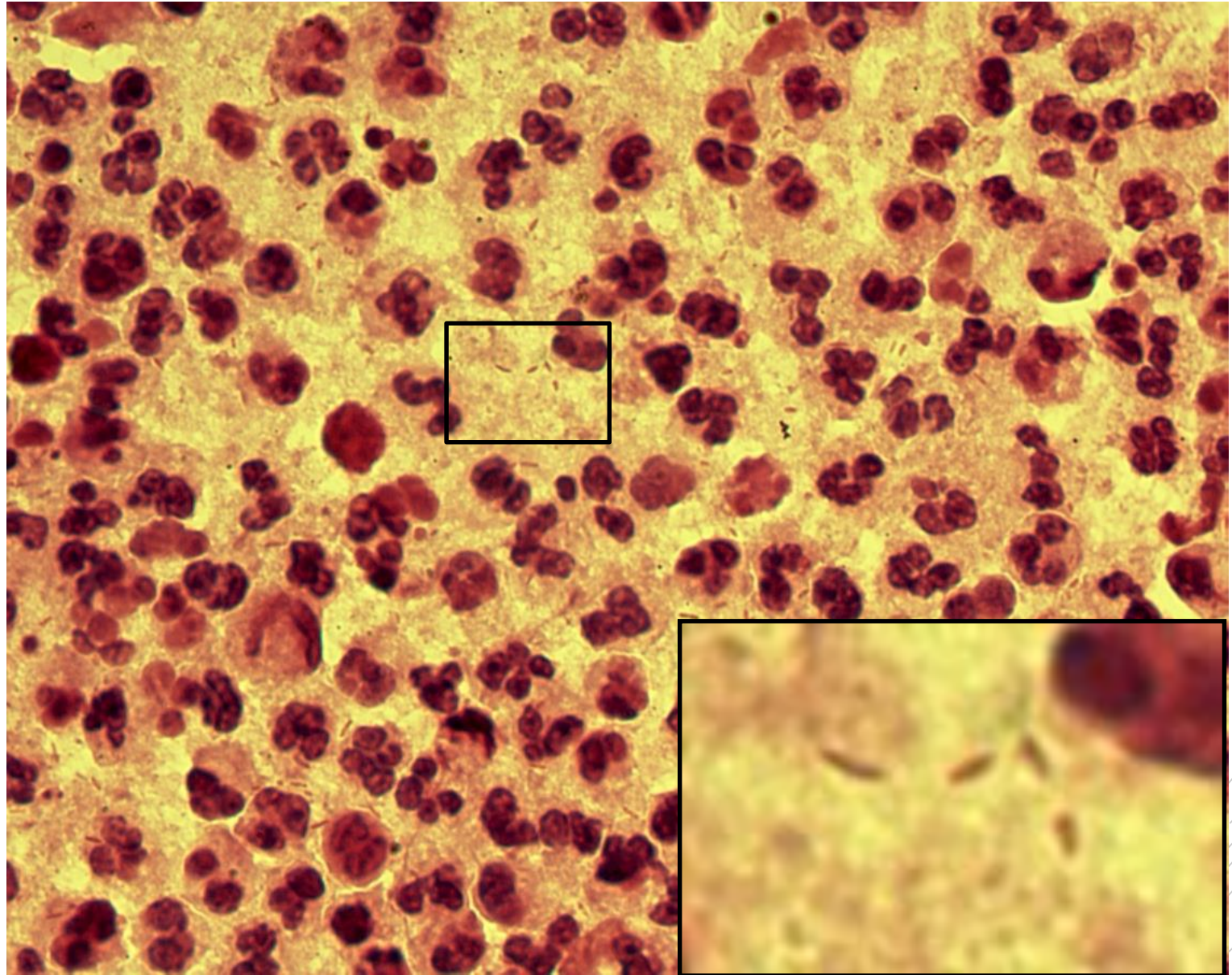
# *Bacteroides fragilis*

**Specimen:** pus

**Patient:** female, 39 years old

**Dg.:** rectal abscess

**Microscopy:** Gram-negative rods



Author: MUDr. Alena Pířová



CHARLES UNIVERSITY  
Second Faculty of Medicine

Slide No. 83

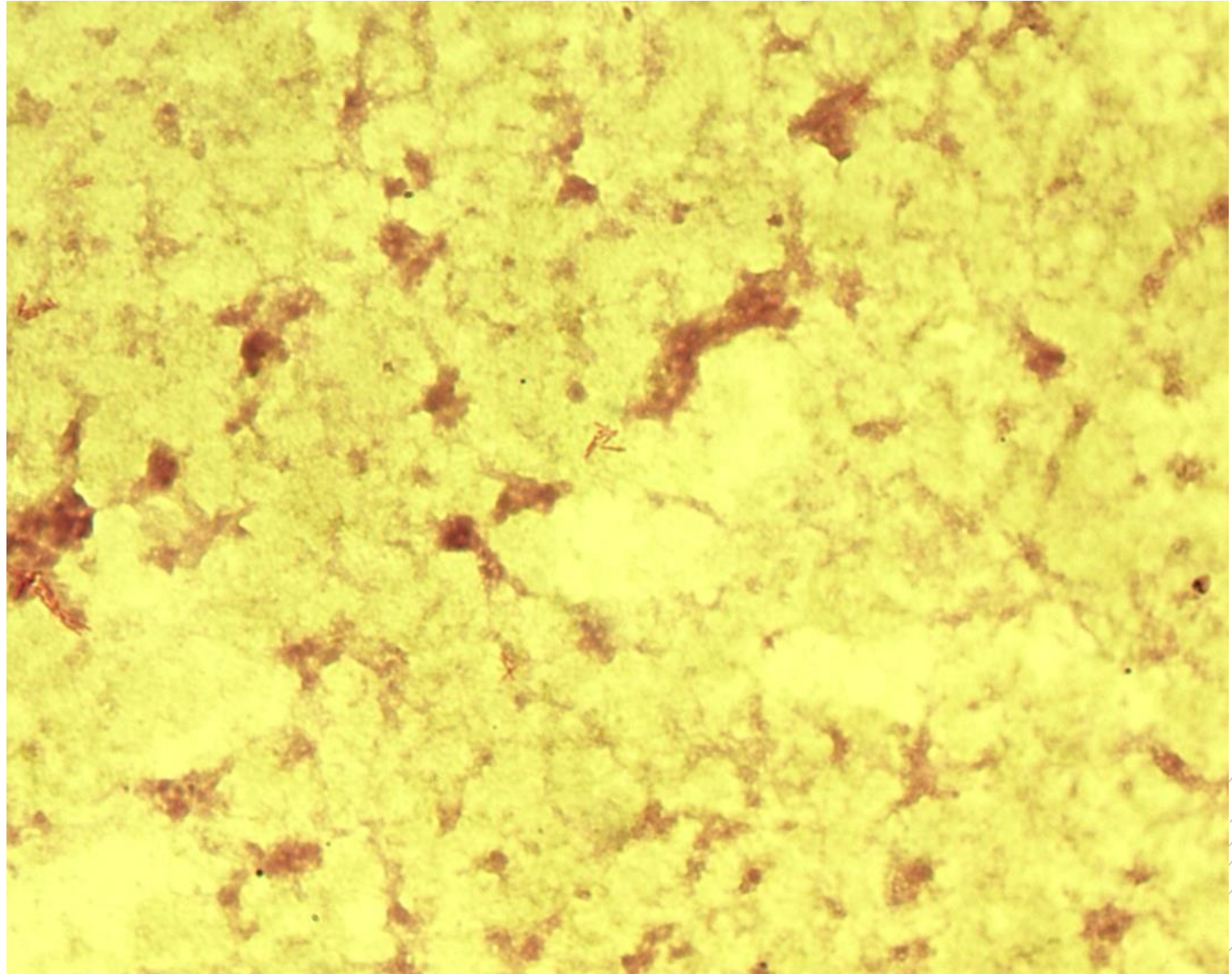
# *Mycobacterium abscessus*

**Specimen:** pus

**Patient:** female, 20 years old

**Dg.:** lung abscess

**Microscopy:** acidoresistant rods,  
Ziehl-Neelsen stain



Author: MUDr. Alena Pířová



CHARLES UNIVERSITY  
Second Faculty of Medicine

Slide No. 83

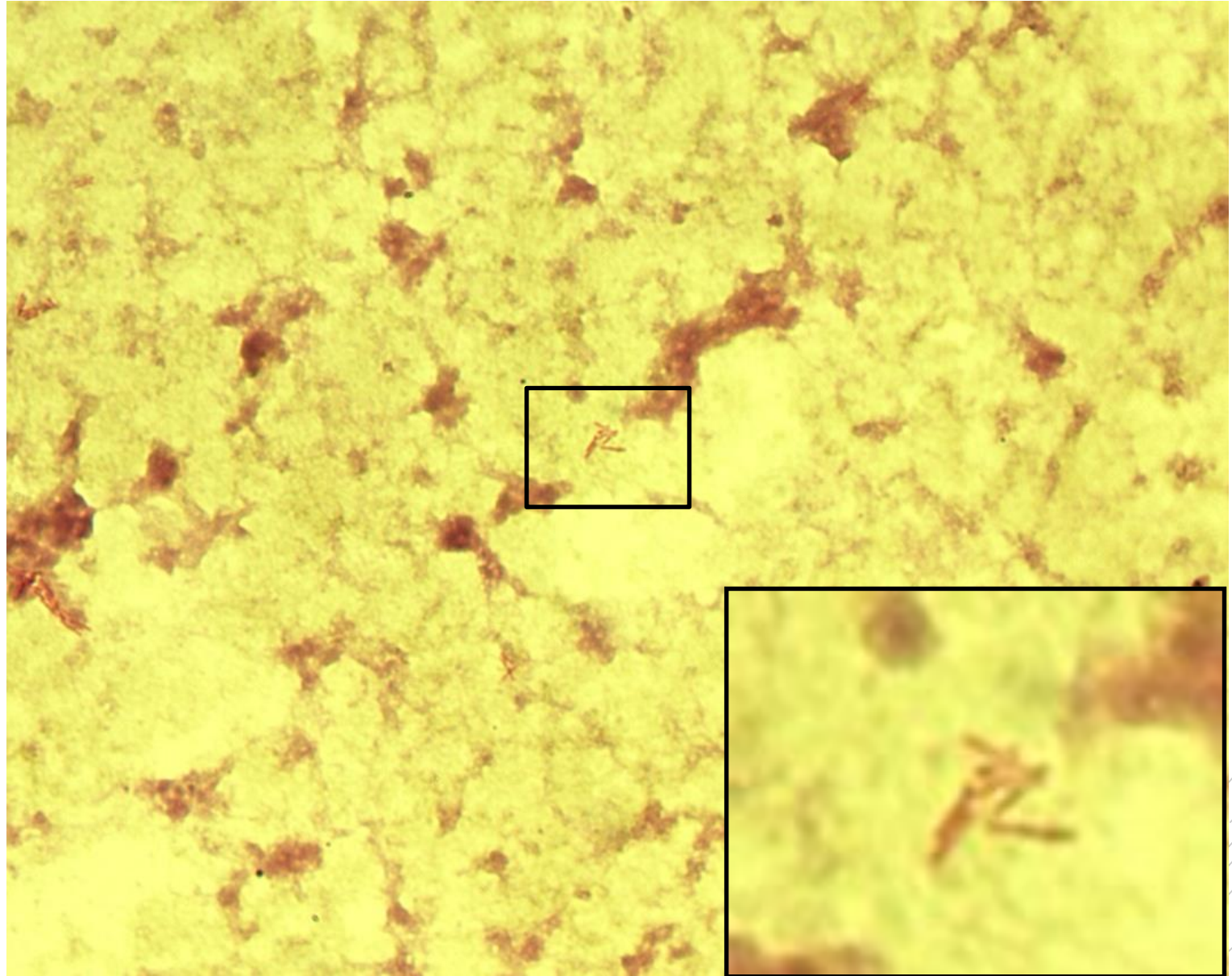
# *Mycobacterium abscessus*

**Specimen:** pus

**Patient:** female, 20 years old

**Dg.:** lung abscess

**Microscopy:** acidoresistant rods,  
Ziehl-Neelsen stain



Author: MUDr. Alena Pířová



CHARLES UNIVERSITY  
Second Faculty of Medicine

Slide No. 84

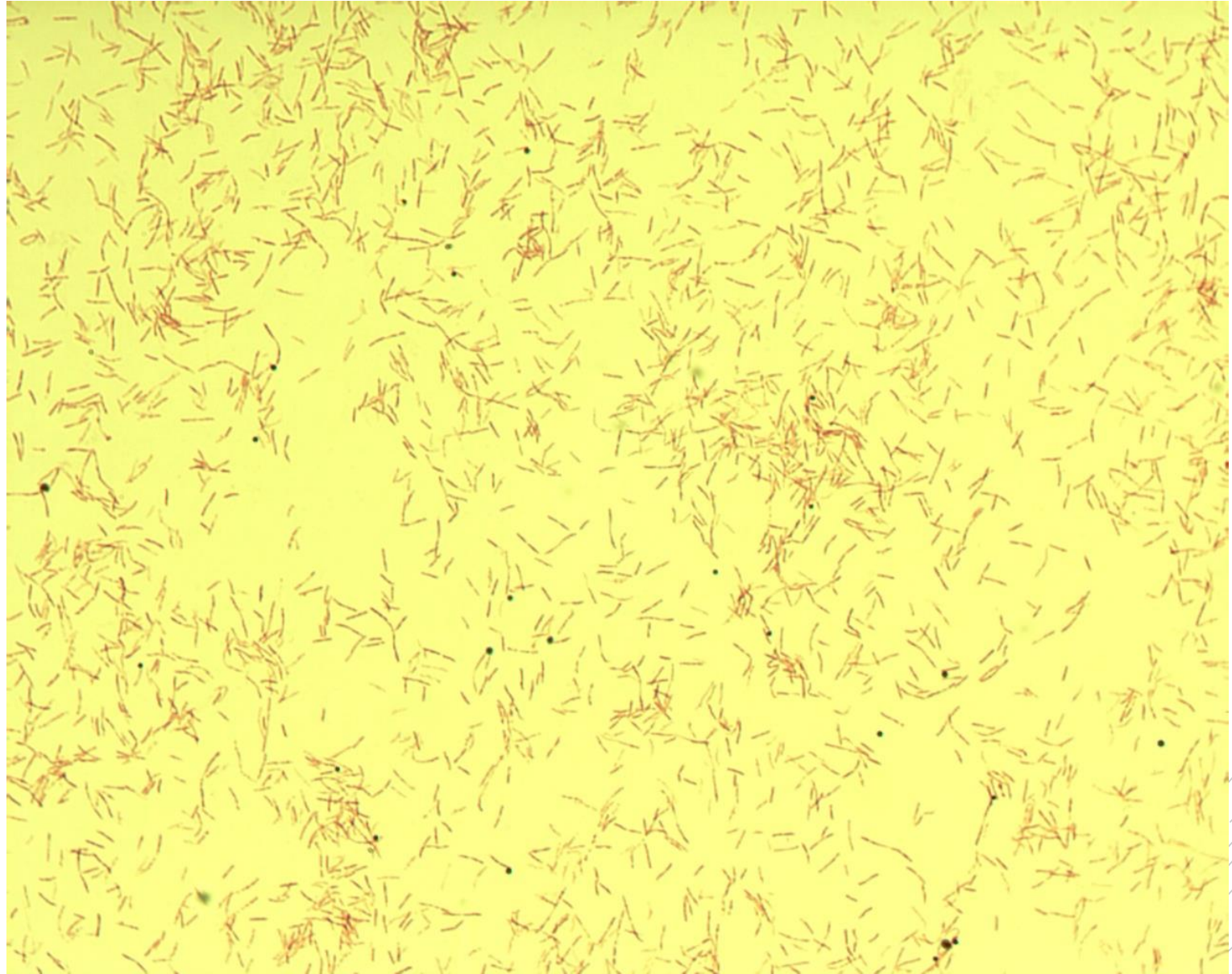
# *Legionella pneumophila*

**Specimen:** sputum

**Patient:** male, 65 years old

**Dg.:** pneumonia

**Microscopy:** Gram-negative rods



Author: doc. MVDr. Oto Melter, PhD.





CHARLES UNIVERSITY  
Second Faculty of Medicine

Slide No. 84


# *Legionella pneumophila*

**Specimen:** sputum

**Patient:** male, 65 years old

**Dg.:** pneumonia

**Microscopy:** Gram-negative rods



Author: doc. MVDr. Oto Melter, PhD.



CHARLES UNIVERSITY  
Second Faculty of Medicine

Slide No. 85

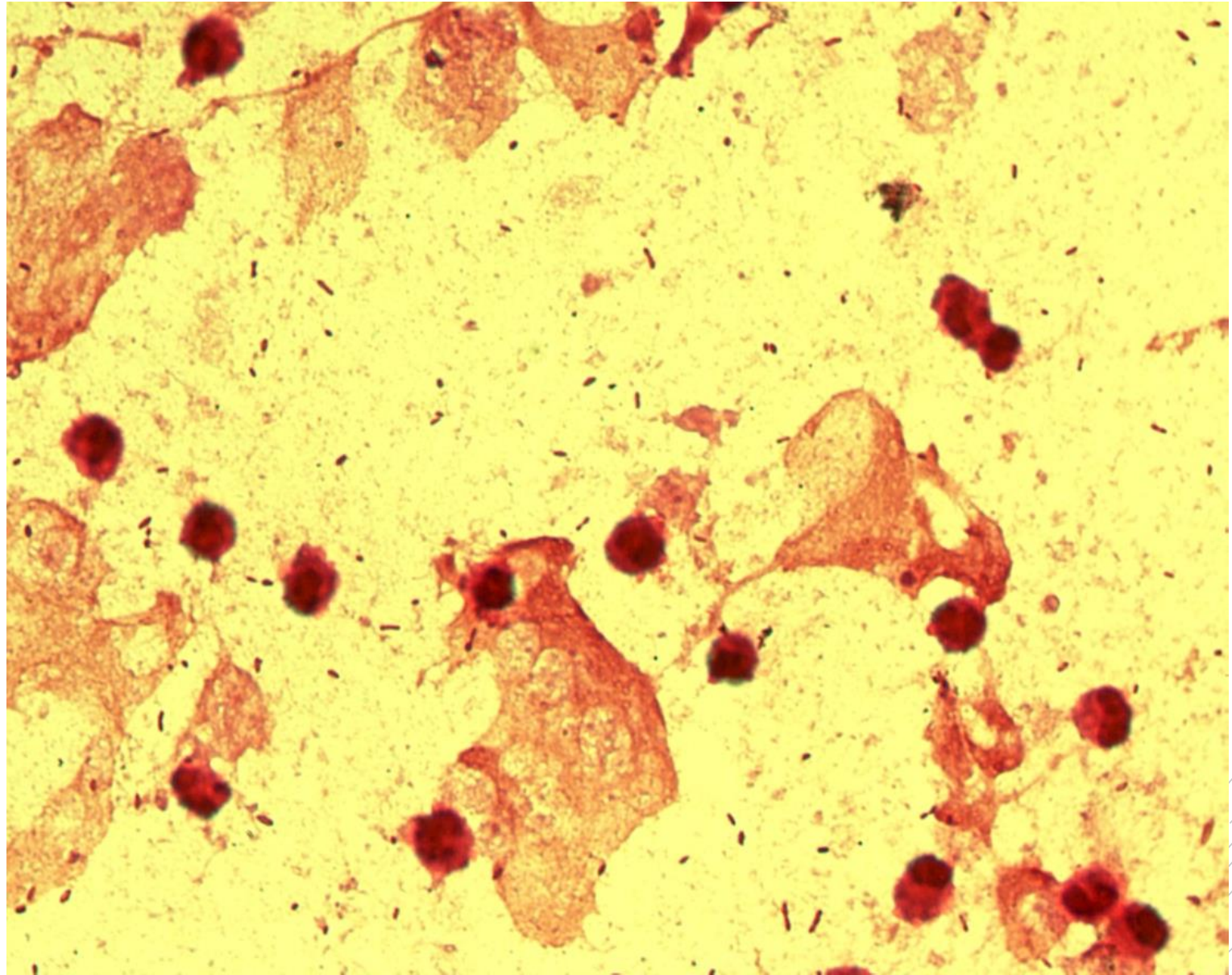
# *Haemophilus influenzae*

**Specimen:** sputum

**Patient:** male, 58 years old

**Dg.:** pneumonia

**Microscopy:** Gram-negative rods



Author: MUDr. Alena Pířová



CHARLES UNIVERSITY  
Second Faculty of Medicine

Slide No. 85

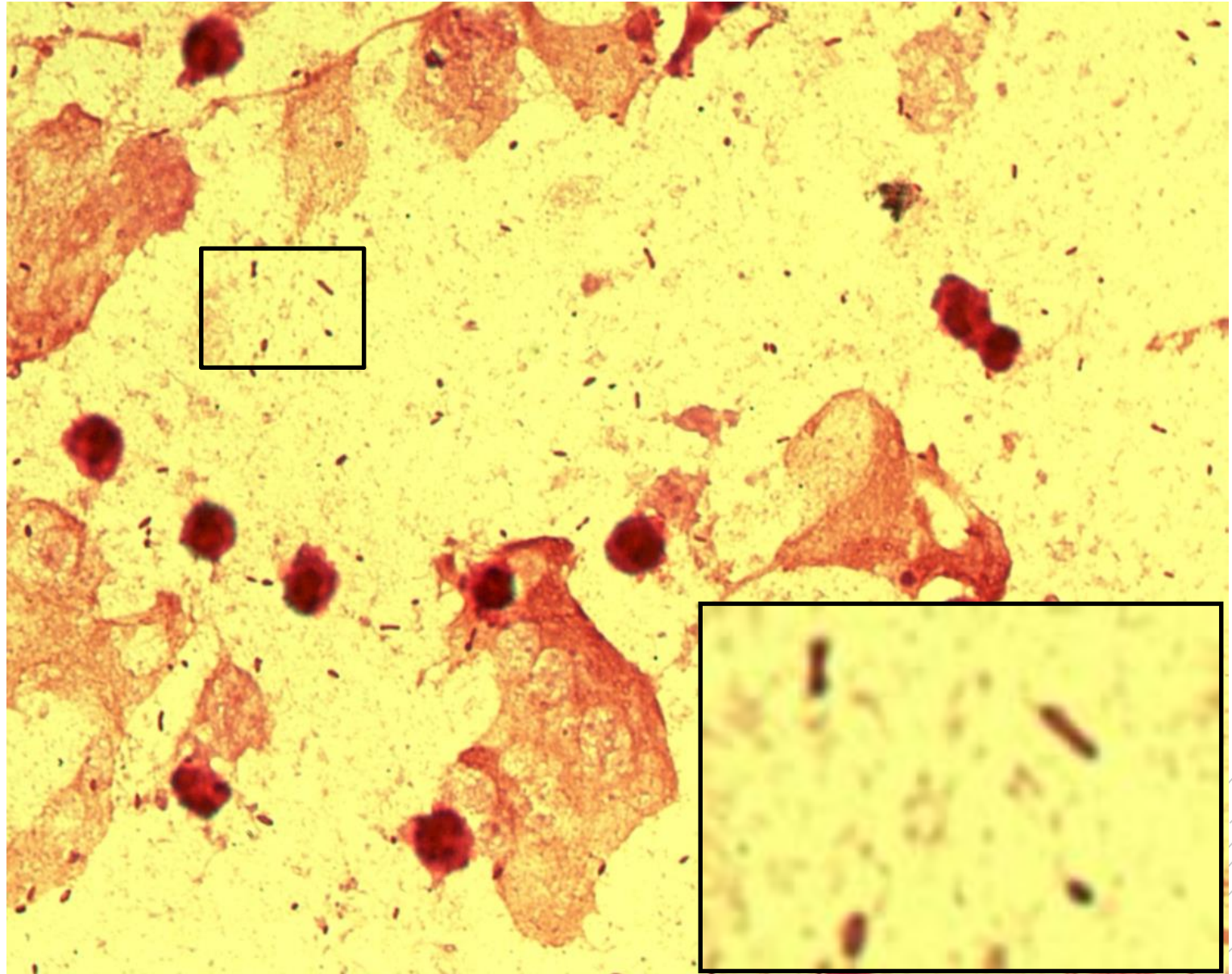
# *Haemophilus influenzae*

**Specimen:** sputum

**Patient:** male, 58 years old

**Dg.:** pneumonia

**Microscopy:** Gram-negative rods



Author: MUDr. Alena Píšová



CHARLES UNIVERSITY  
Second Faculty of Medicine

Slide No. 86

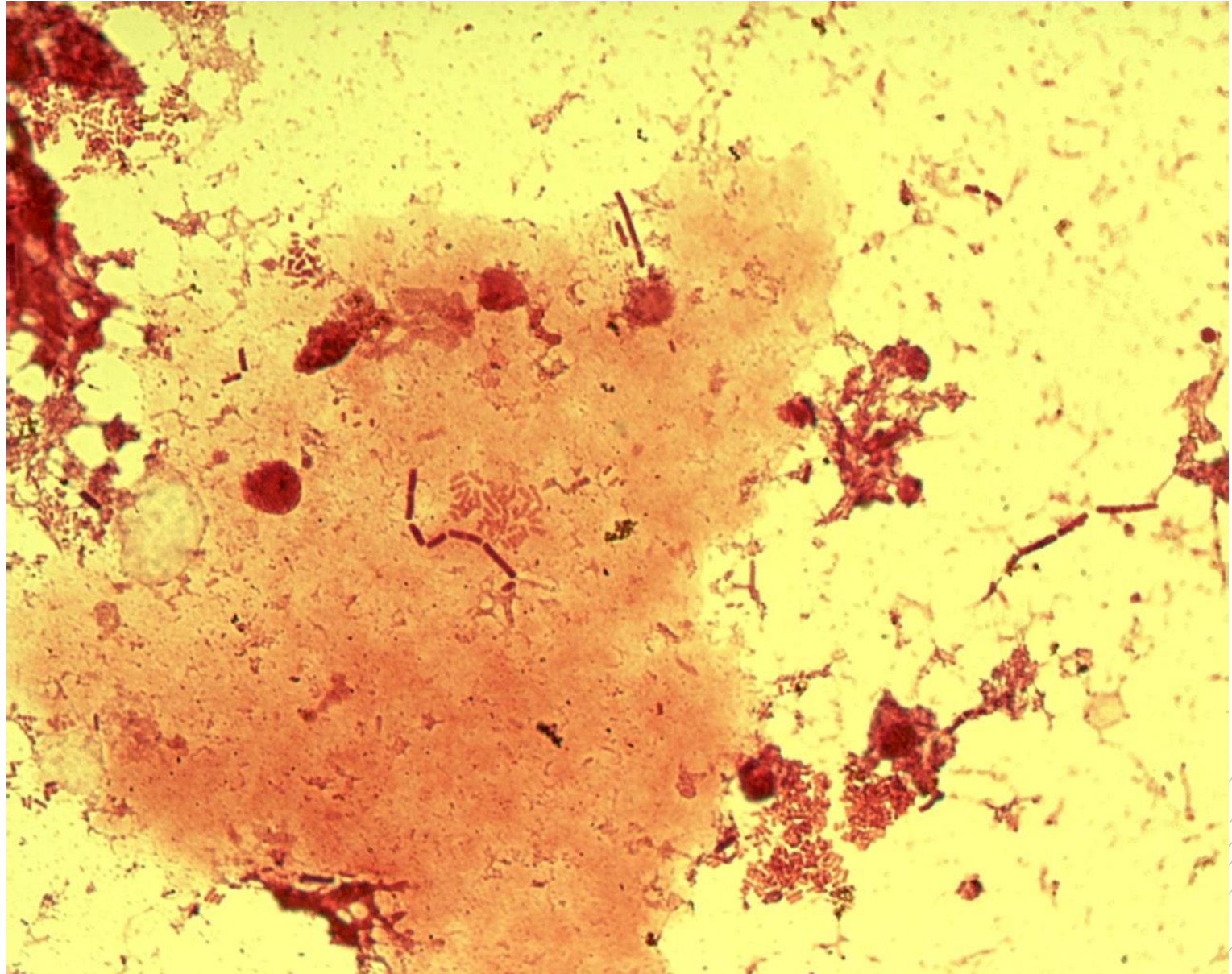
*Escherichia coli,*  
*Bacteroides*  
*fragilis*

**Specimen:** gall

**Patient:** female, 60 years old

**Dg.:** gallbladder inflammation

**Microscopy:** Gram-negative rods



Author: MUDr. Alena Pířová



CHARLES UNIVERSITY  
Second Faculty of Medicine

Slide No. 86

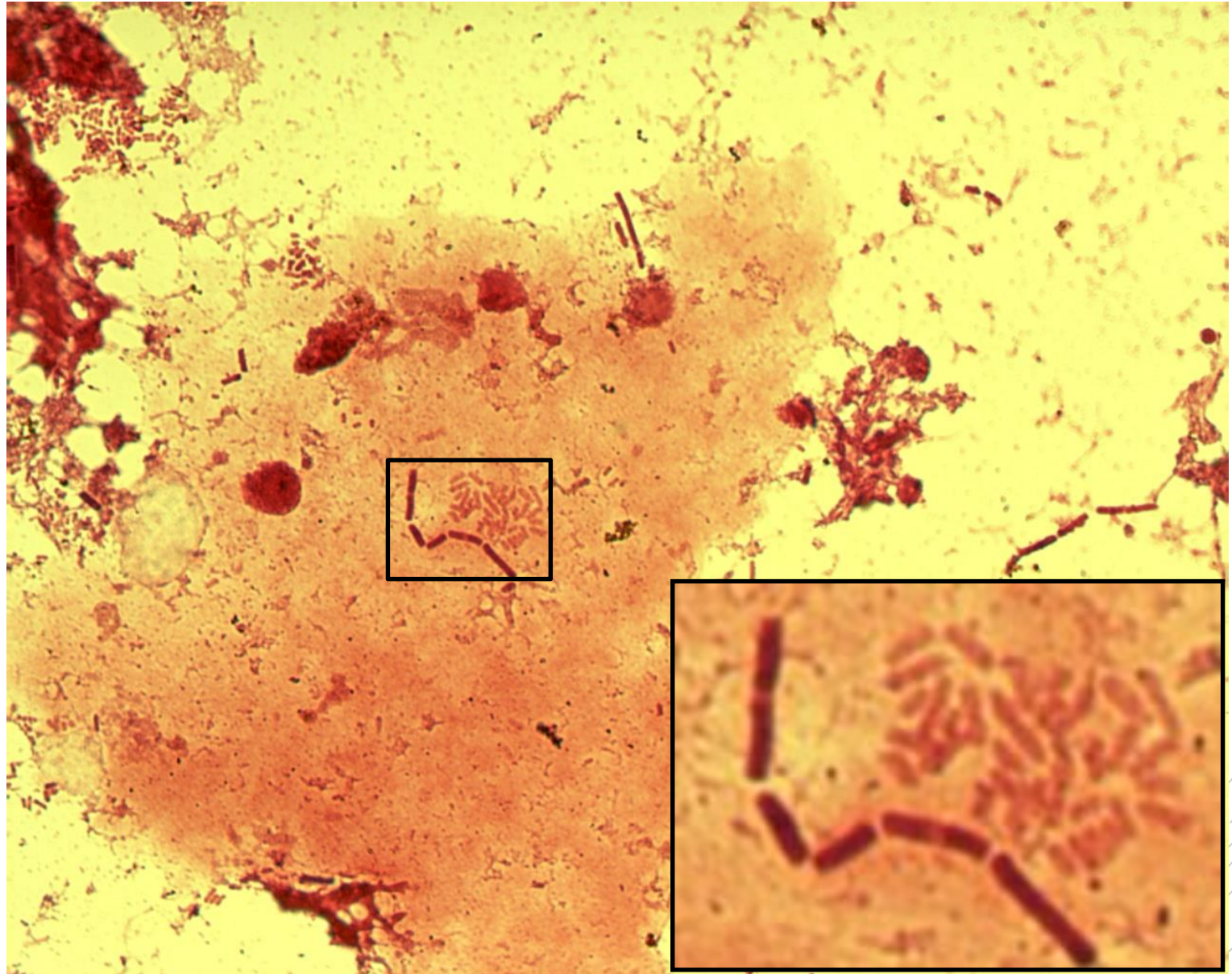
*Escherichia coli*,  
*Bacteroides*  
*fragilis*

**Specimen:** gall

**Patient:** female, 60 years old

**Dg.:** gallbladder inflammation

**Microscopy:** Gram-negative rods



Author: MUDr. Alena Pířová



CHARLES UNIVERSITY  
Second Faculty of Medicine

Slide No. 87

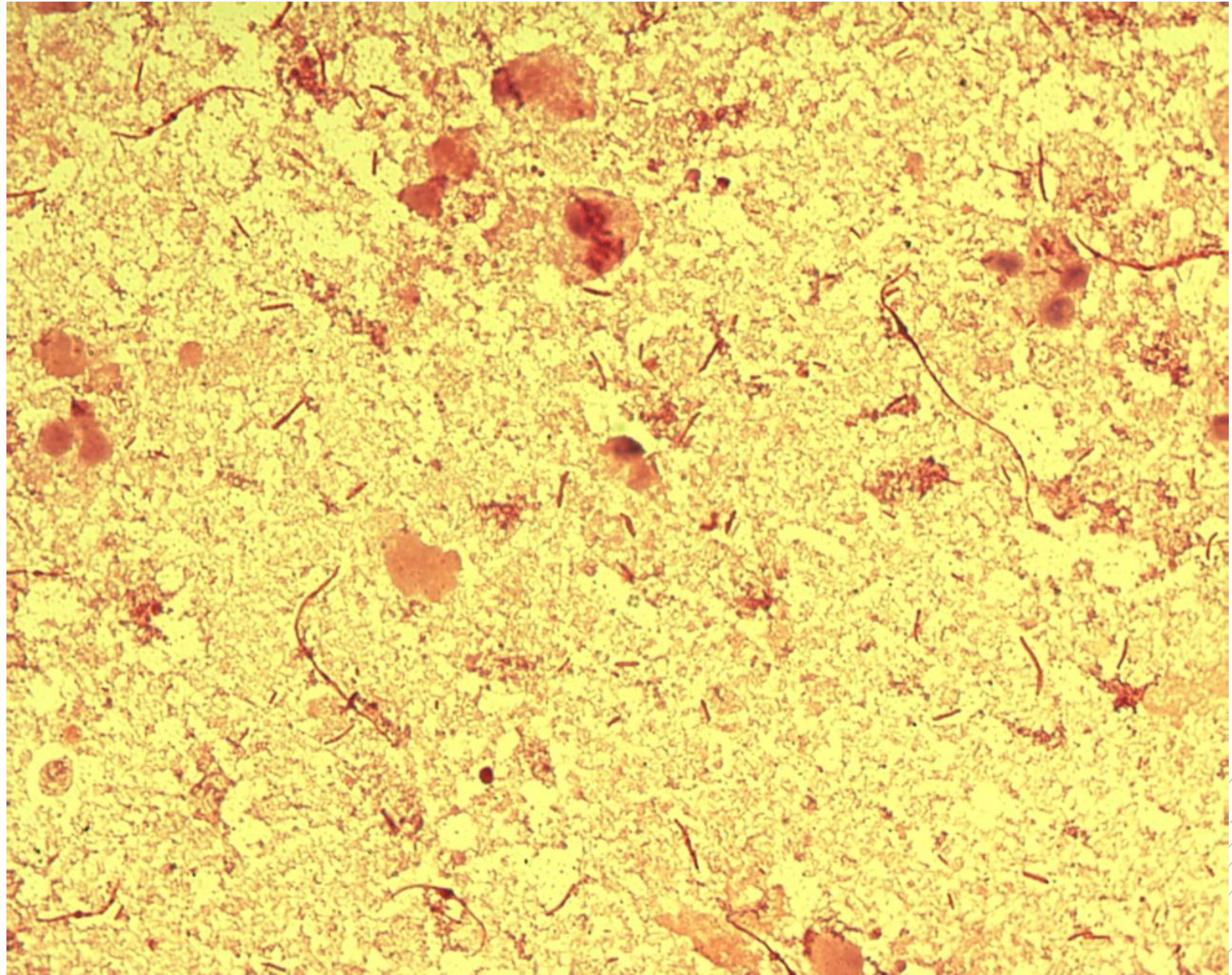
# *Proteus mirabilis*

**Specimen:** Urine

**Patient:** female, 85 years old

**Dg.:** acute nephritis

**Microscopy:** Gram-negative rods



Author: MUDr. Alena Pířová



CHARLES UNIVERSITY  
Second Faculty of Medicine

Slide No. 87

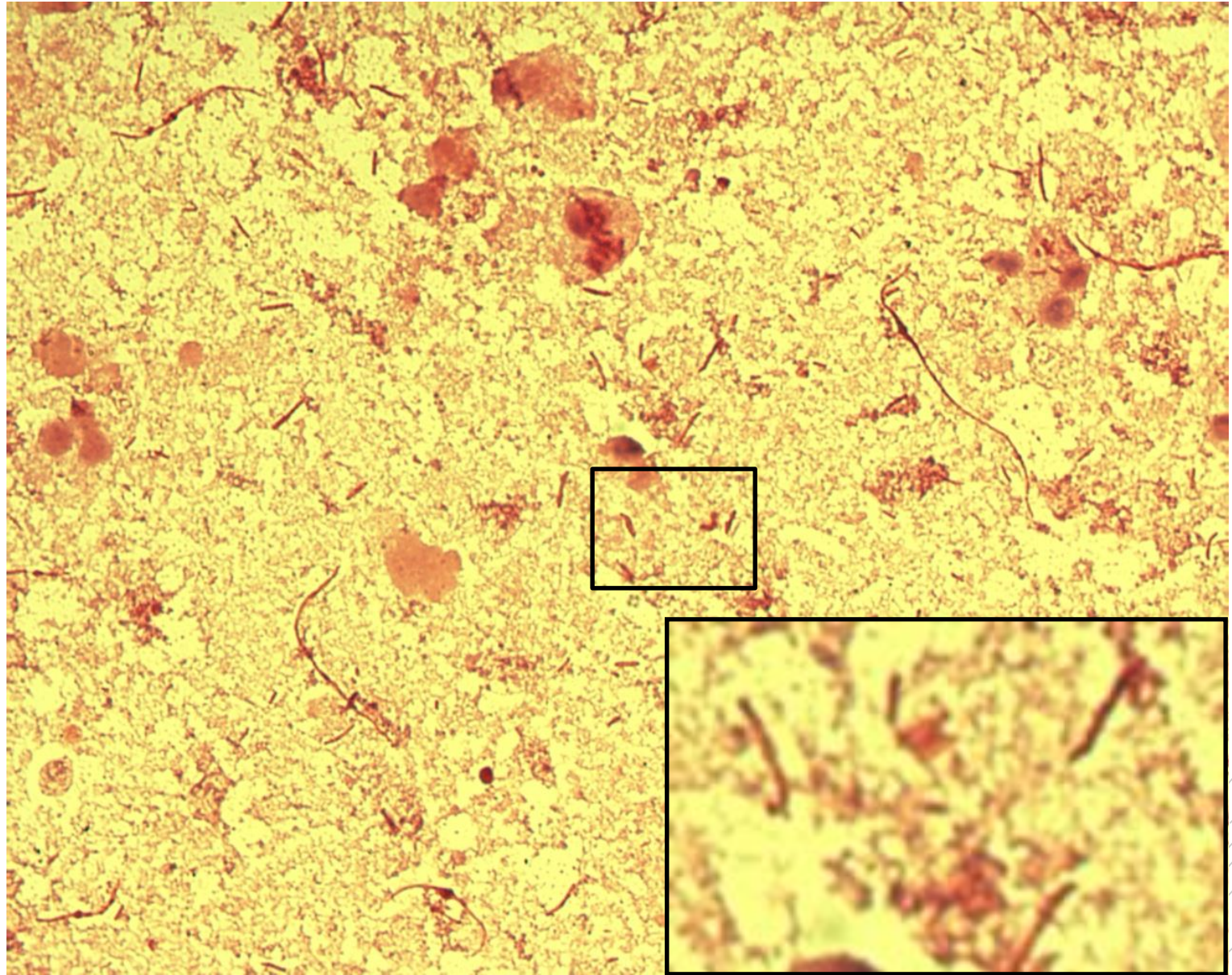
# *Proteus mirabilis*

**Specimen:** Urine

**Patient:** female, 85 years old

**Dg.:** acute nephritis

**Microscopy:** Gram-negative rods



Author: MUDr. Alena Pířová



CHARLES UNIVERSITY  
Second Faculty of Medicine

Slide No. 88

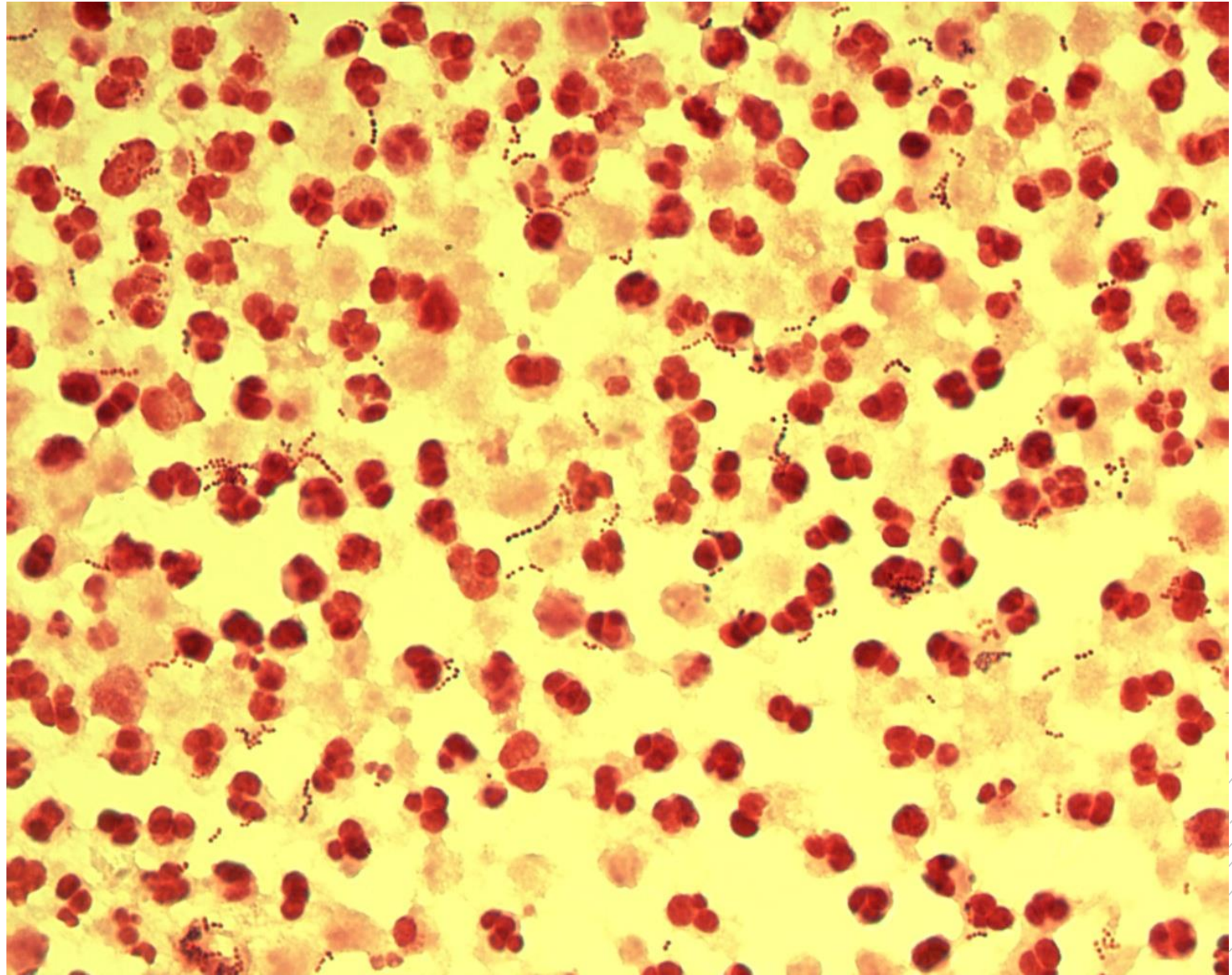
# *Streptococcus agalactiae*

**Specimen:** pus

**Patient:** male, 68 years old

**Dg.:** abscess

**Microscopy:** Gram-positive cocci  
in chains



Author: MUDr. Alena Pířová





CHARLES UNIVERSITY  
Second Faculty of Medicine

Slide No. 88


# *Streptococcus agalactiae*

**Specimen:** pus

**Patient:** male, 68 years old

**Dg.:** abscess

**Microscopy:** Gram-positive cocci  
in chains



Author: MUDr. Alena Pířová



CHARLES UNIVERSITY  
Second Faculty of Medicine

Slide No. 89

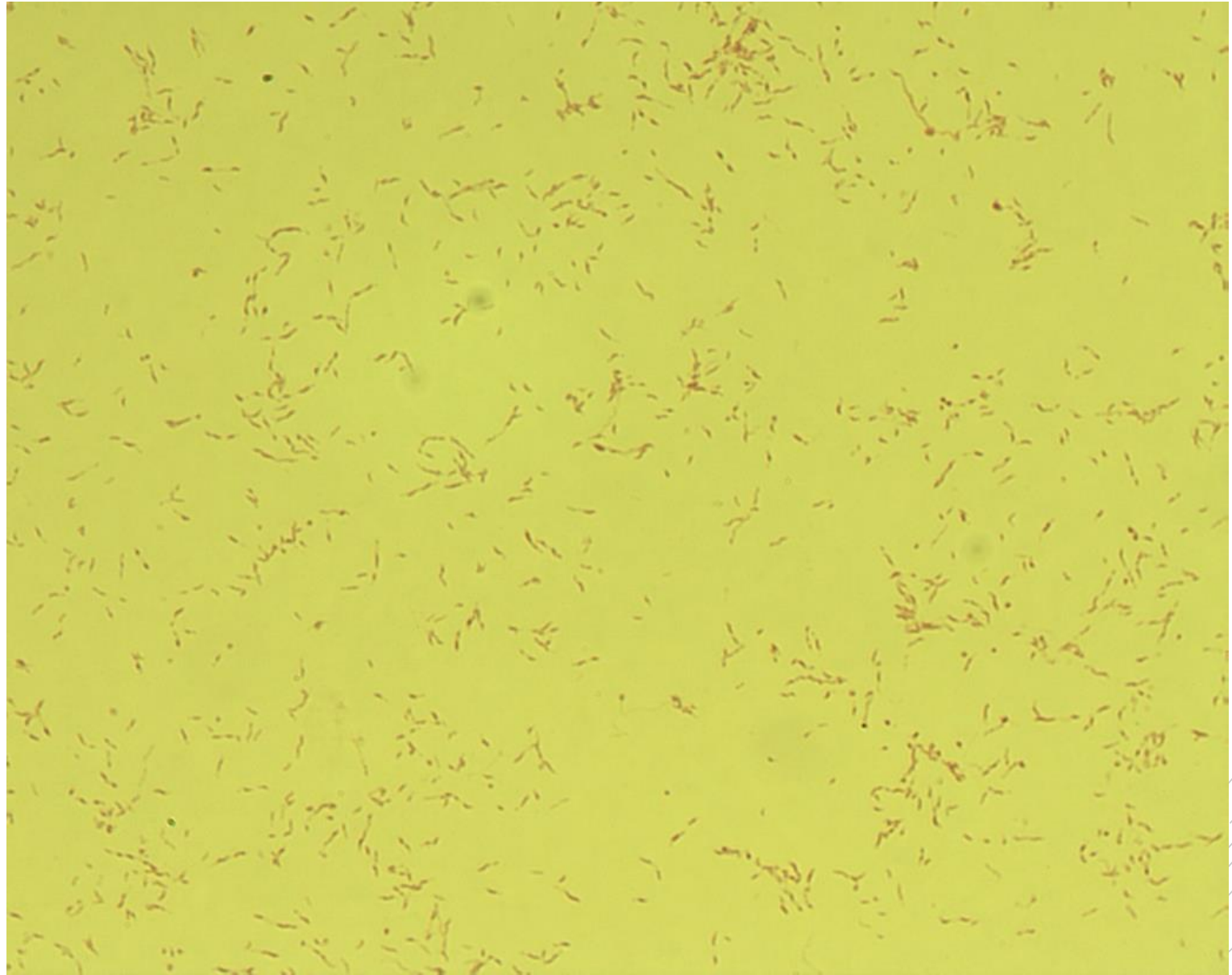
# *Campylobacter jejuni*

**Specimen:** culture

**Patient:** male, 21 years old

**Dg.:** diarrhoea

**Microscopy:** spiral-shaped  
Gram-negative rods



Author: MUDr. Svojtková, MUDr. Šolarová



CHARLES UNIVERSITY  
Second Faculty of Medicine

Slide No. 89


# *Campylobacter jejuni*

**Specimen:** culture

**Patient:** male, 21 years old

**Dg.:** diarrhoea

**Microscopy:** spiral-shaped  
Gram-negative rods



Author: MUDr. Svojtková, MUDr. Šolarová



CHARLES UNIVERSITY  
Second Faculty of Medicine

Slide No. 90

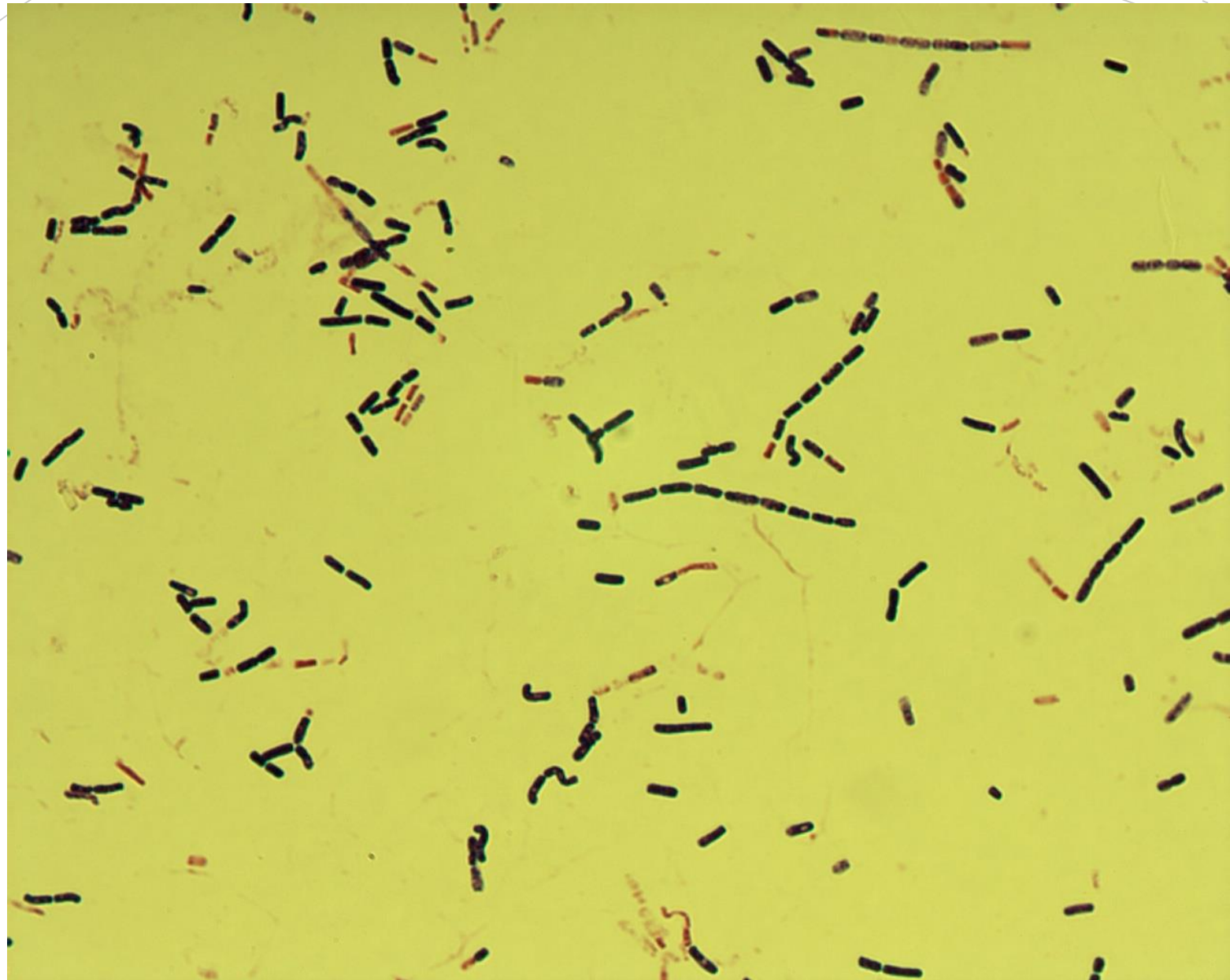
# *Bacillus cereus*

**Specimen:** culture, suspected meal source

**Patient:** female, 38 years old

**Dg.:** enterotoxigenic

**Microscopy:** Gram-positive rod



Autor: Markéta Šolarová, Hanka Svojtková



CHARLES UNIVERSITY  
Second Faculty of Medicine

Slide No. 90

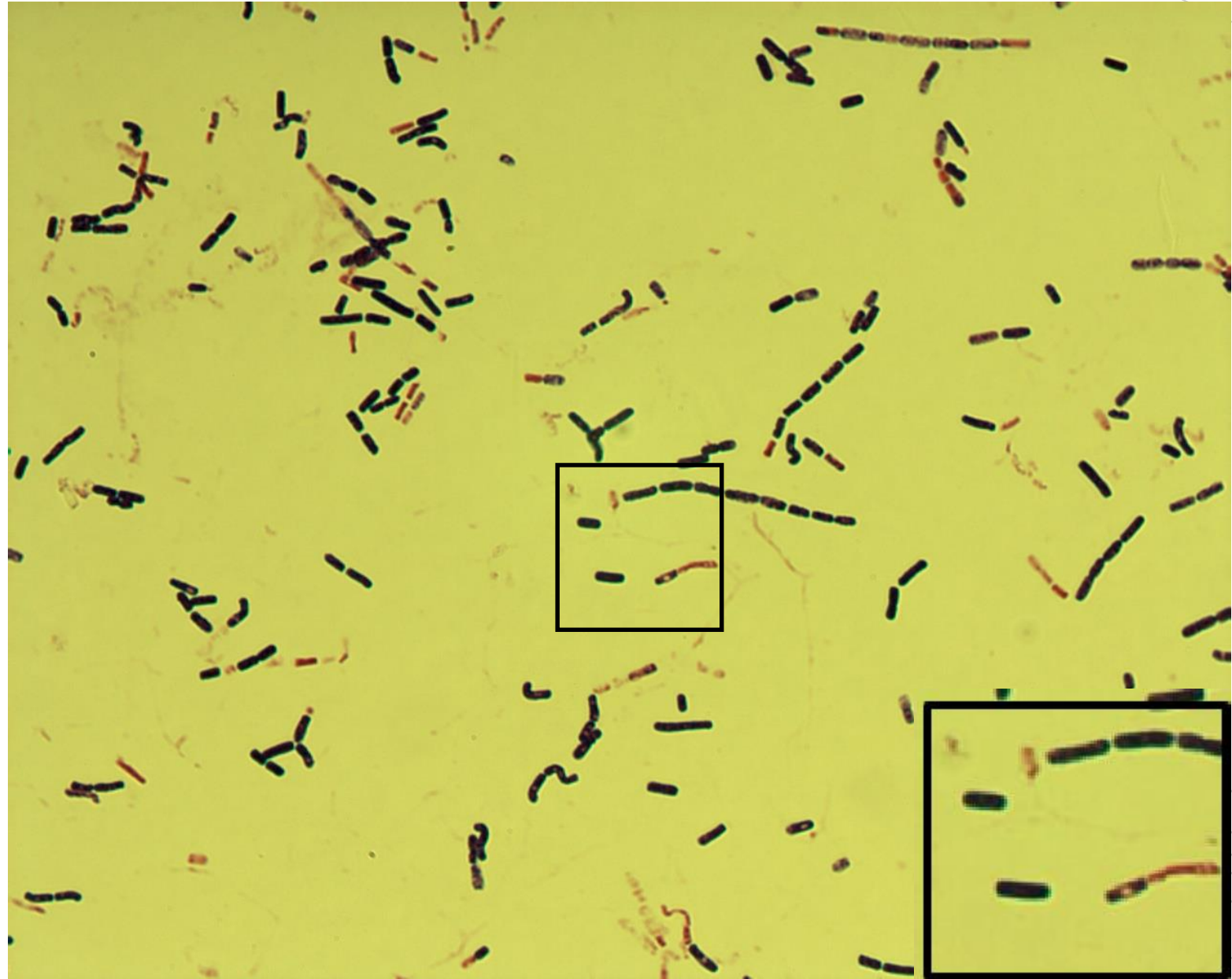
# *Bacillus cereus*

**Specimen:** culture, suspected meal source

**Patient:** female, 38 years old

**Dg.:** enterotoxigenic

**Microscopy:** Gram-positive rod



Autor: Markéta Šolarová, Hanka Svojtková



CHARLES UNIVERSITY  
Second Faculty of Medicine

Slide No. 91


# *Acinetobacter baumannii*

**Specimen:** pus

**Patient:** male, 44 years old

**Dg.:** perforation of esophagus

**Microscopy:** Gram-negative rod



Autor: Markéta Šolarová, Hanka Svojtková



CHARLES UNIVERSITY  
Second Faculty of Medicine

Slide No. 91


# *Acinetobacter baumannii*

**Specimen:** pus

**Patient:** male, 44 years old

**Dg.:** perforation of esophagus

**Microscopy:** Gram-negative rod



Autor: Markéta Šolarová, Hanka Svojtková



CHARLES UNIVERSITY  
Second Faculty of Medicine

Slide No. 92

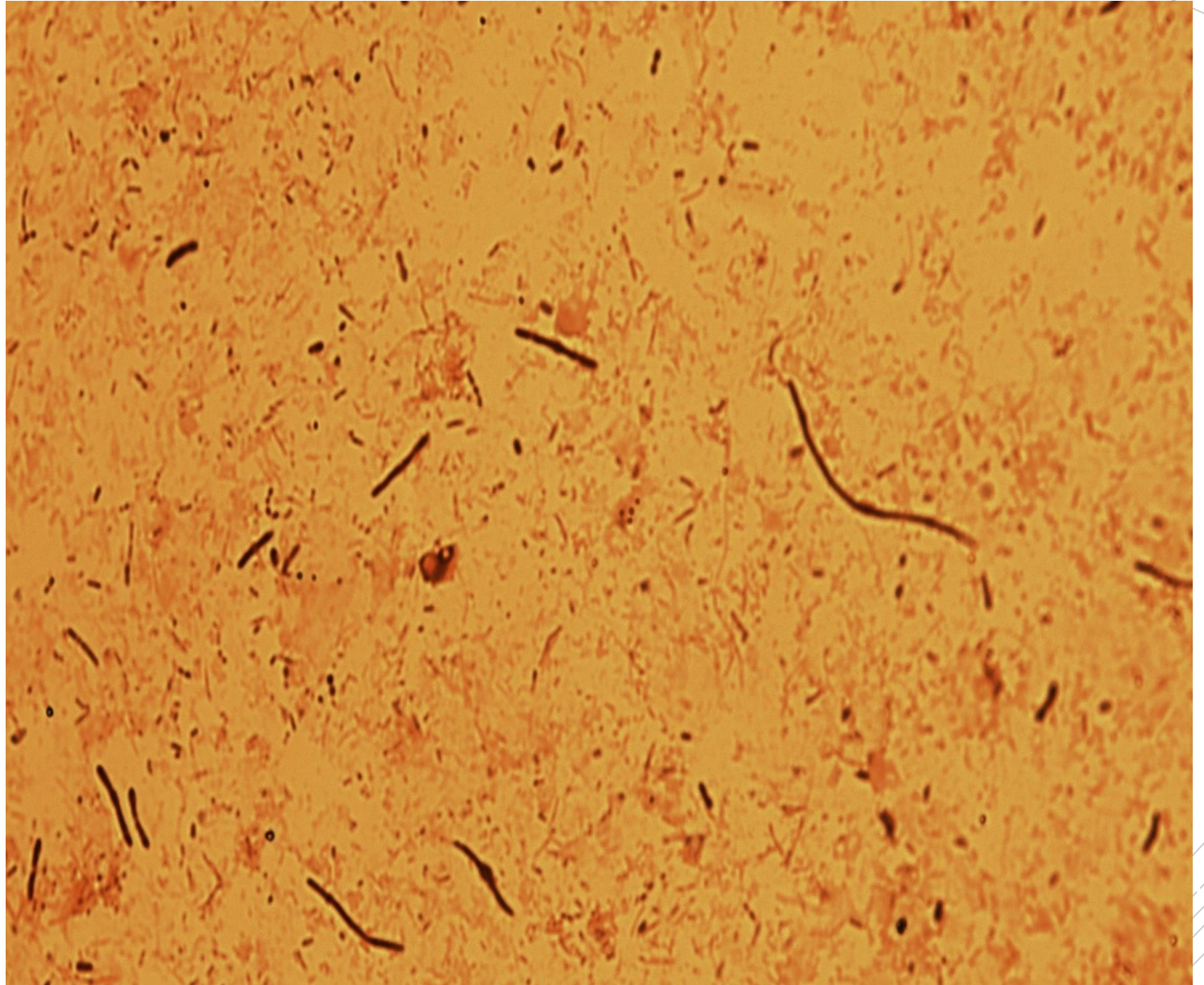
*Escherichia*,  
*Klebsiella*,  
*Enterococcus*,  
*C. perfringens*

**Specimen:** pus

**Patient:** male, 64 years old

**Dg.:** rectal abscess

**Microscopy:** polymicrobial flora



Autor: MUDr. Alena Píšová





CHARLES UNIVERSITY  
Second Faculty of Medicine

Slide No. 92

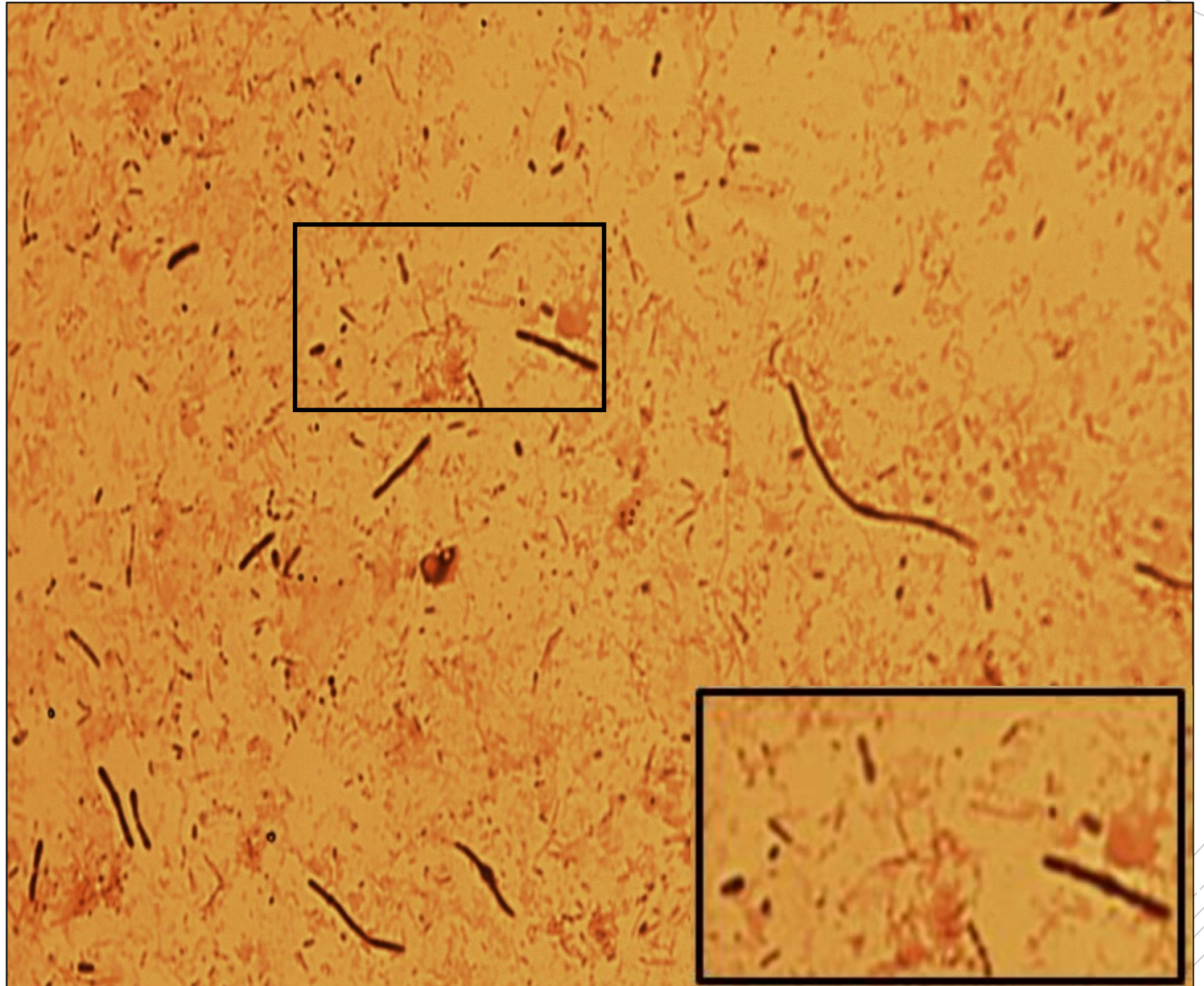
*Escherichia*,  
*Klebsiella*,  
*Enterococcus*,  
*C. perfringens*

**Specimen:** pus

**Patient:** male, 64 years old

**Dg.:** rectal abscess

**Microscopy:** polymicrobial flora



Autor: MUDr. Alena Pířová



CHARLES UNIVERSITY  
Second Faculty of Medicine

Slide No. 93

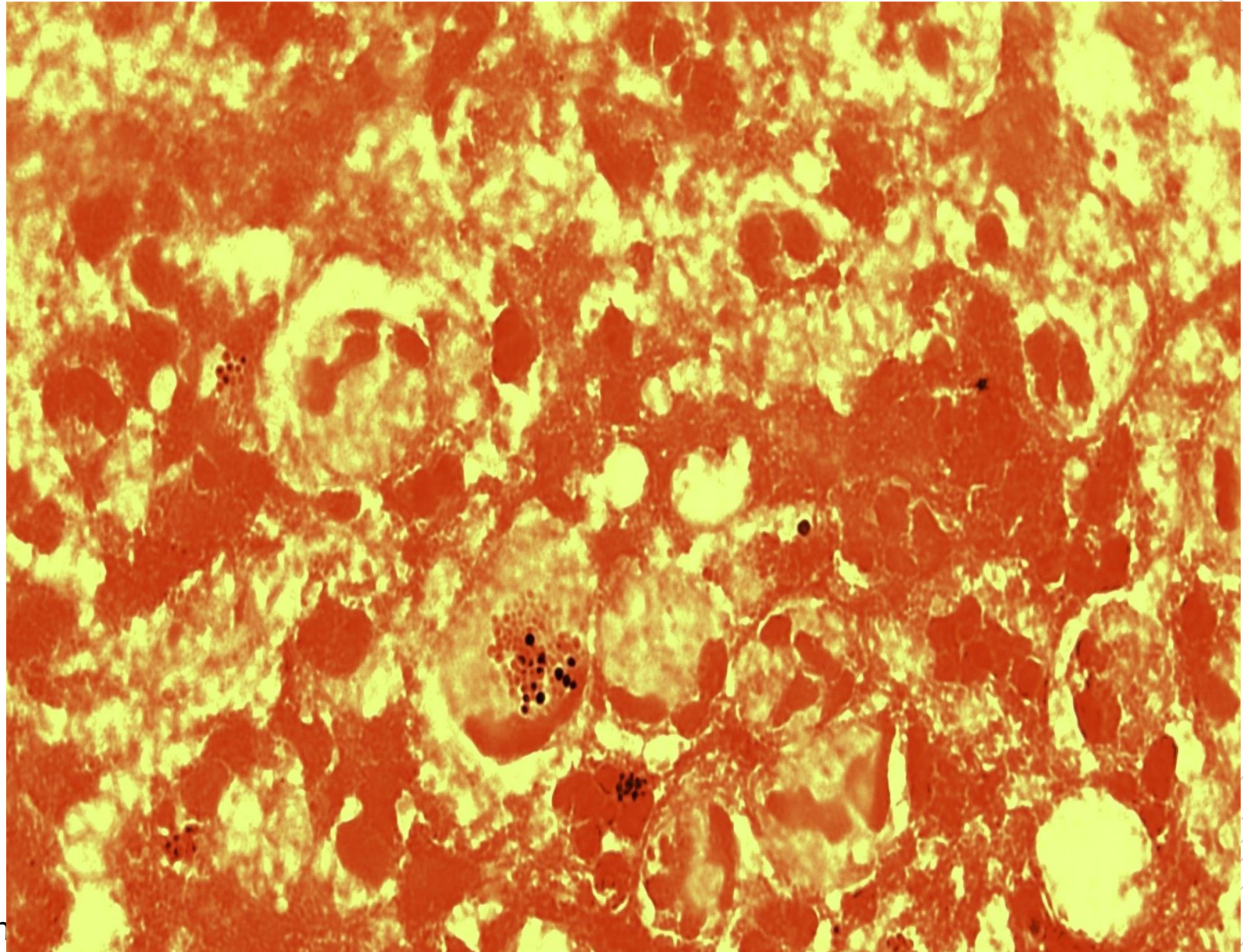
# *Staphylococcus aureus*

**Specimen:** pus

**Patient:** male, 57 years old

**Dg.:** brain abscess

**Microscopy:** Gram-positive cocci (gram labile cocci within leukocytes)



Autor: MUDr. Alena Pířová



CHARLES UNIVERSITY  
Second Faculty of Medicine

Slide No. 93


# *Staphylococcus aureus*

**Specimen:** pus

**Patient:** male, 57 years old

**Dg.:** brain abscess

**Microscopy:** Gram-positive cocci (gram-labile cocci within leukocytes)



Autor: MUDr. Alena Pířová



CHARLES UNIVERSITY  
Second Faculty of Medicine

Slide No. 94

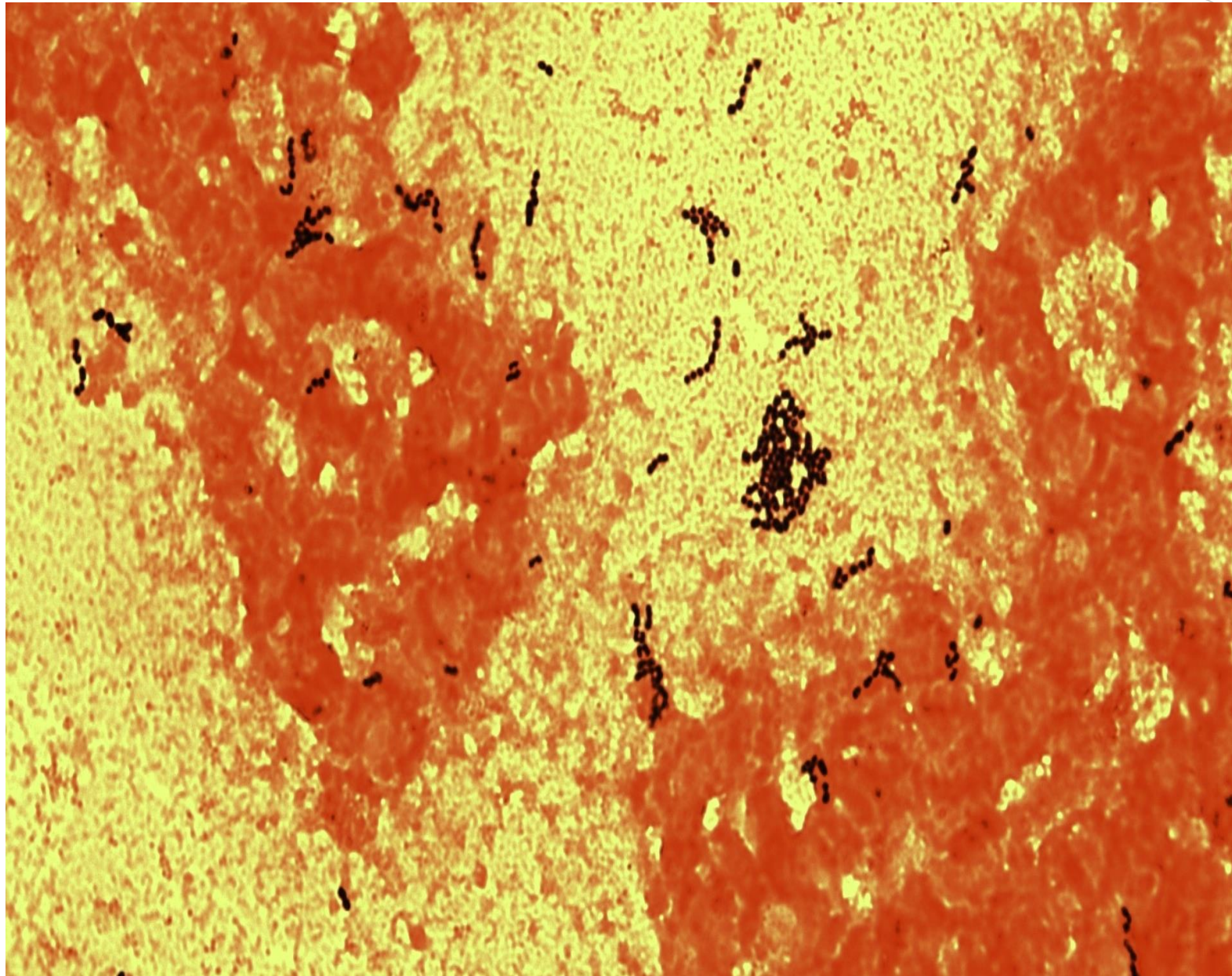
# *Streptococcus anginosus*

**Specimen:** hemoculture

**Patient:** female, 44 years old

**Dg.:** Crohn's disease

**Microscopy:** Gram-positive cocci



Autor: MUDr. Petra Kabelíková



CHARLES UNIVERSITY  
Second Faculty of Medicine

Slide No. 94


# *Streptococcus anginosus*

**Specimen:** hemoculture

**Patient:** female, 44 years old

**Dg.:** Crohn's disease

**Microscopy:** Gram-positive cocci



Autor: MUDr. Petra Kabelíková



CHARLES UNIVERSITY  
Second Faculty of Medicine

Slide No. 95

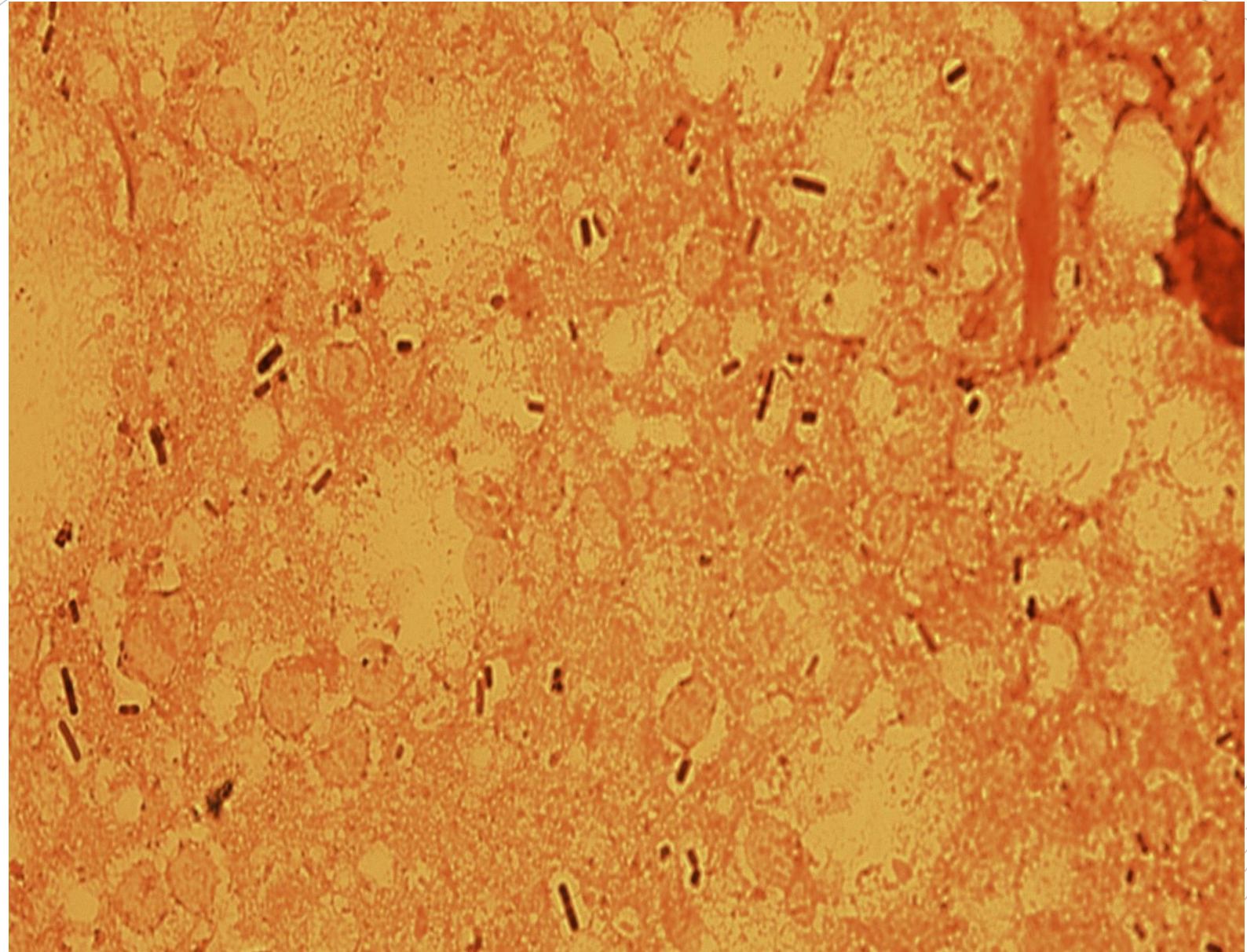
*Clostridium  
perfringens,  
Staphylococcus  
hominis*

**Specimen:** tissue biopsy

**Patient:** female, 76 years old

**Dg.:** atherosclerosis of the end artery

**Microscopy:** gram-positive rods and cocci



Autor: MUDr. Alena Píšová



CHARLES UNIVERSITY  
Second Faculty of Medicine

Slide No. 95

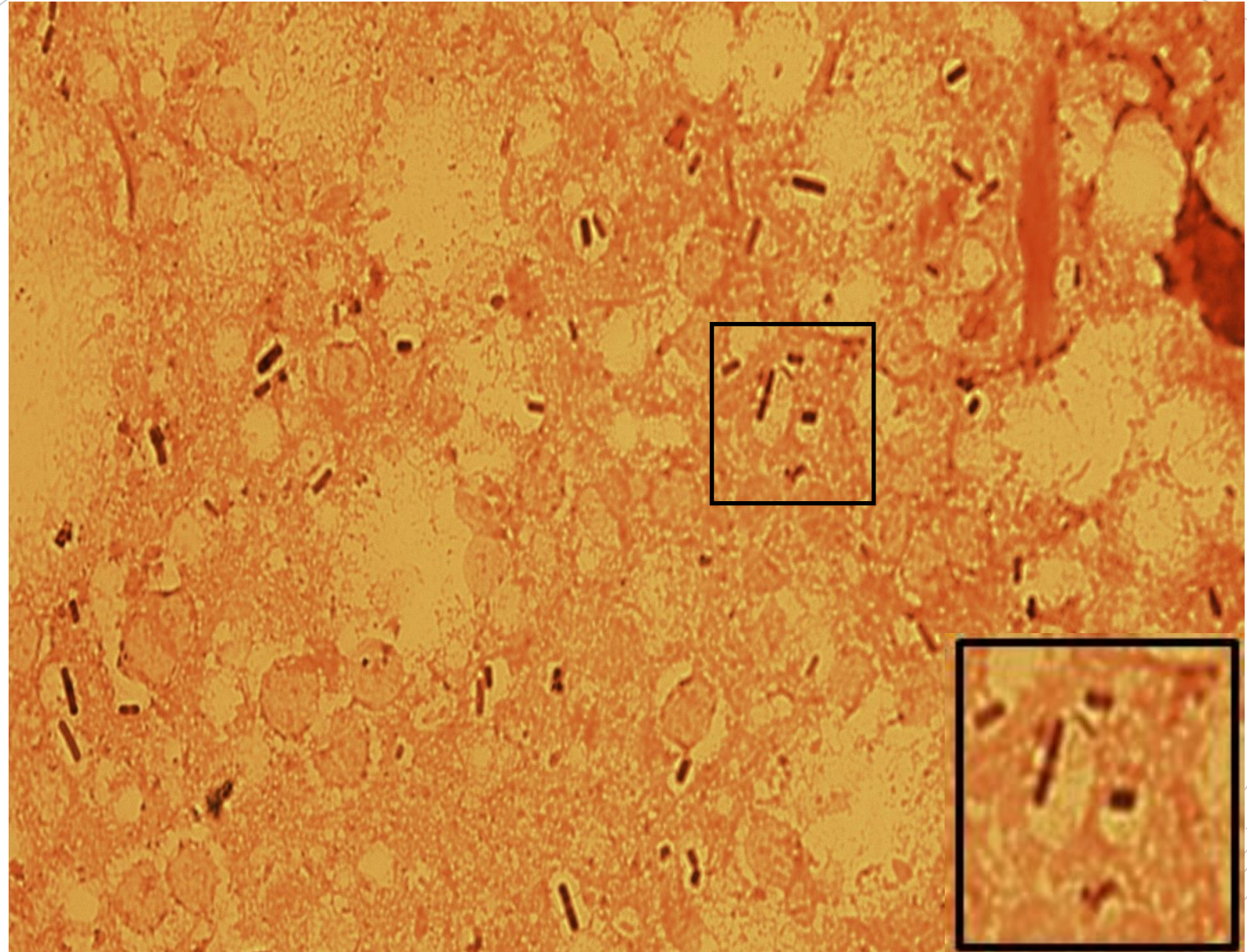
*Clostridium  
perfringens,  
Staphylococcus  
hominis*

**Specimen:** tissue biopsy

**Patient:** female, 76 years old

**Dg.:** atherosclerosis of the end artery

**Microscopy:** gram-positive rods and cocci



Autor: MUDr. Alena Pířová



CHARLES UNIVERSITY  
Second Faculty of Medicine

Slide No. 96

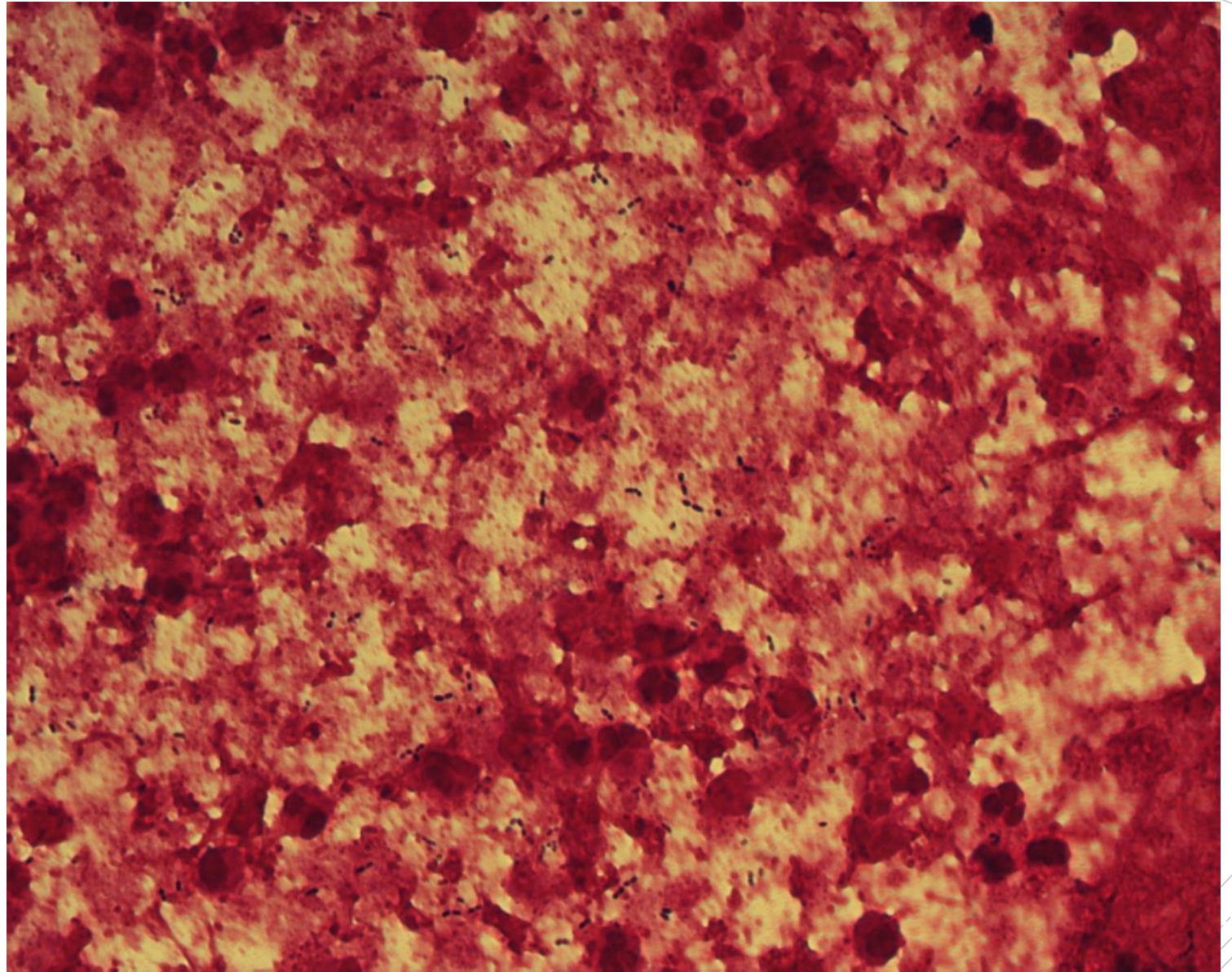
# *Streptococcus pneumoniae*

**Specimen:** tissue

**Patient:** female, 57 years old

**Dg.:** meningitis

**Microscopy:** Gram-positive diplococci



Autor: MUDr. Alena Píšová





CHARLES UNIVERSITY  
Second Faculty of Medicine

Slide No. 96


# *Streptococcus pneumoniae*

**Specimen:** tissue

**Patient:** female, 57 years old

**Dg.:** meningitis

**Microscopy:** Gram-positive diplococci



Autor: MUDr. Alena Pířov



CHARLES UNIVERSITY  
Second Faculty of Medicine

Slide No. 97

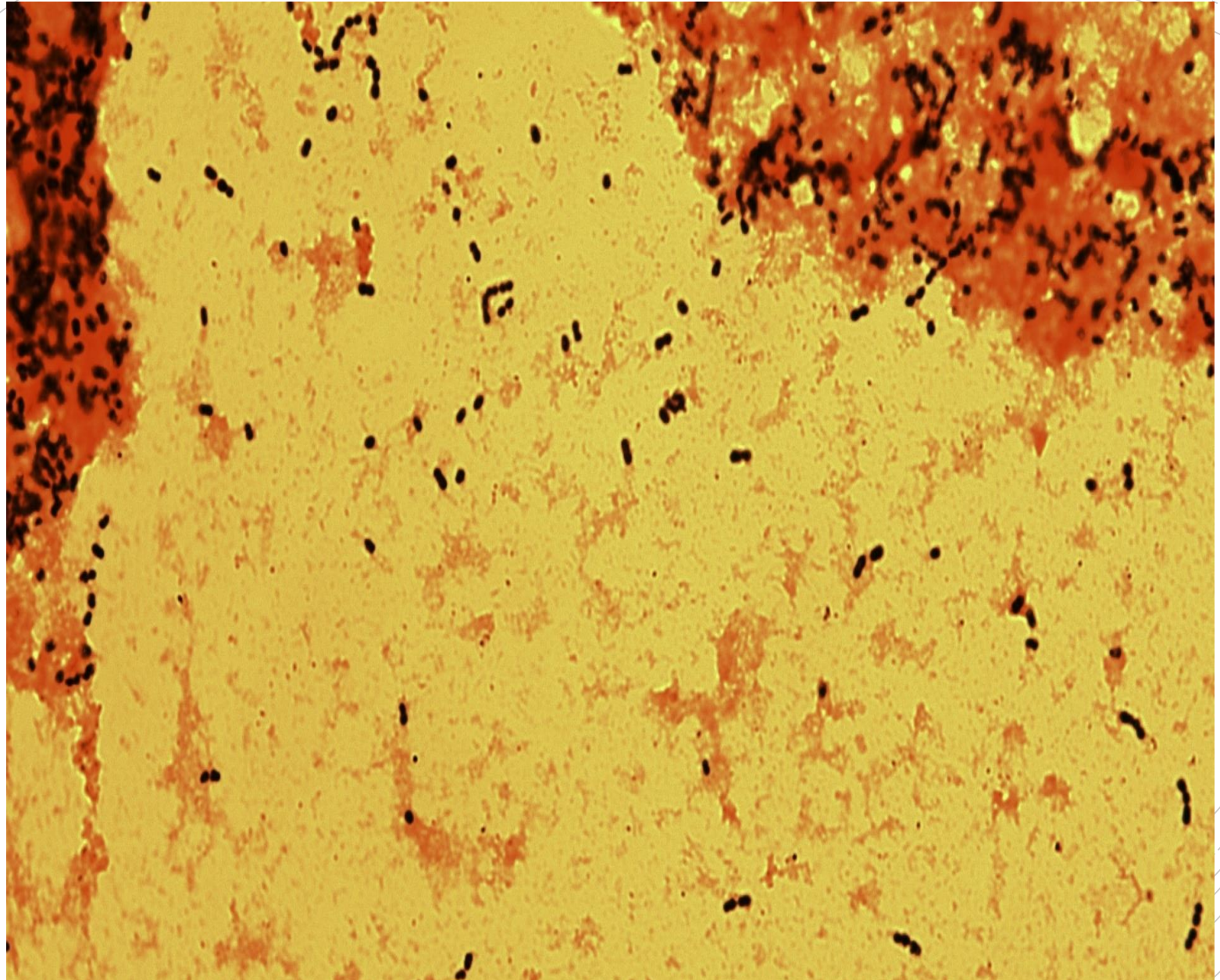
# *Streptococcus pneumoniae*

**Specimen:** tissue

**Patient:** female, 57 years old

**Dg.:** meningitis

**Microscopy:** Gram-positive cocci and diplococci



Autor: MUDr. Alena Pířová



CHARLES UNIVERSITY  
Second Faculty of Medicine

Slide No. 97


# *Streptococcus pneumoniae*

**Specimen:** tissue

**Patient:** female, 57 years old

**Dg.:** meningitis

**Microscopy:** Gram-positive cocci and diplococci



Autor: MUDr. Alena Pířová



CHARLES UNIVERSITY  
Second Faculty of Medicine

Slide No. 98


# *Escherichia coli*

**Specimen:** urine

**Patient:** female, 80 years old

**Dg.:** urolithiasis

**Microscopy:** Gram-negative rods



Autor: MUDr. Alena Píšová



CHARLES UNIVERSITY  
Second Faculty of Medicine

Slide No. 98


# *Escherichia coli*

**Specimen:** urine

**Patient:** female, 80 years old

**Dg.:** urolithiasis

**Microscopy:** Gram-negative rods



Autor: MUDr. Alena Pířová



CHARLES UNIVERSITY  
Second Faculty of Medicine

Slide No. 99

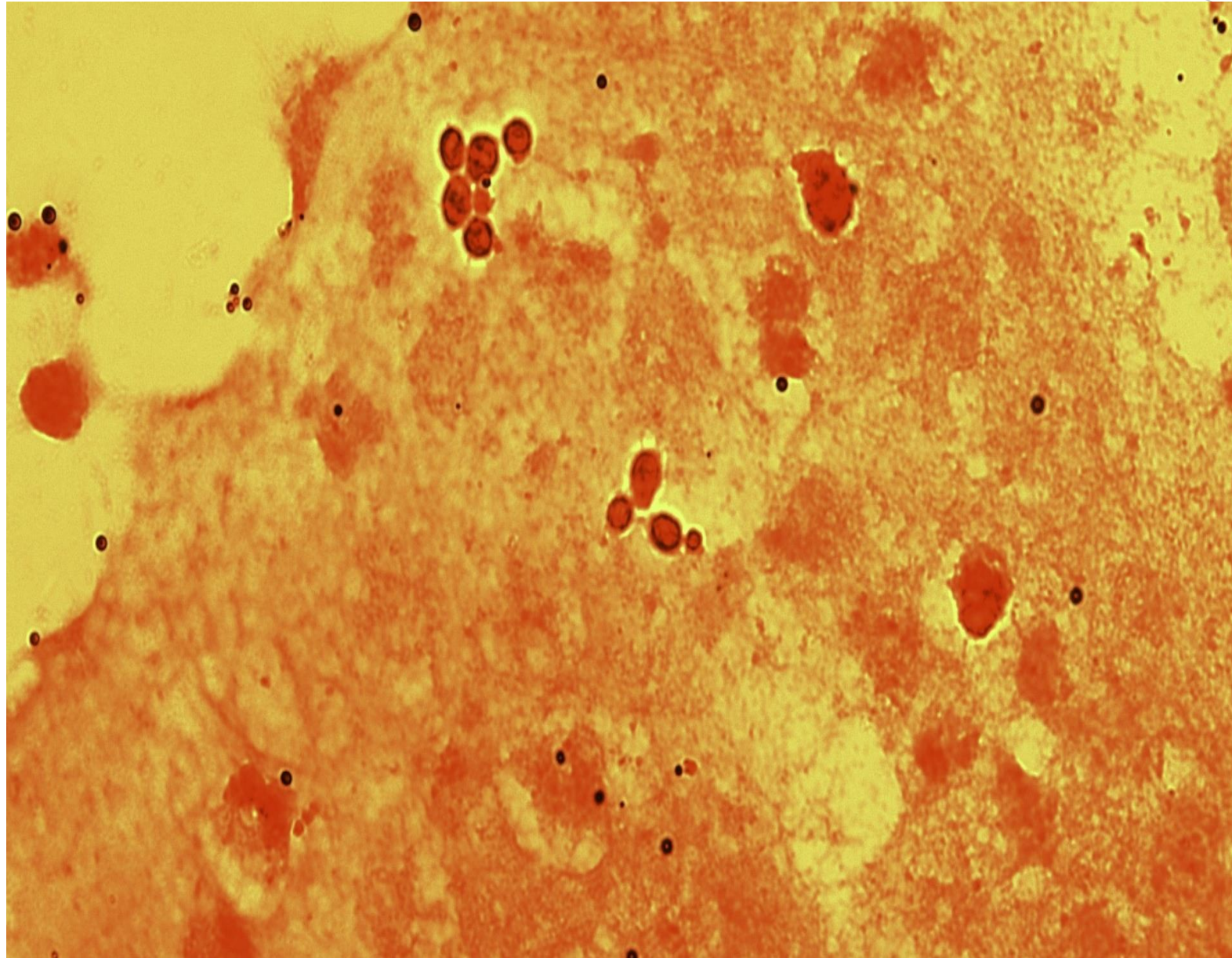
# *Candida albicans*

**Specimen:** bile

**Patient:** female, 53 years old

**Dg.:** malignant tumor of the large intestines

**Microscopy:** blastospores



Autor: MUDr. Alena Pířová



CHARLES UNIVERSITY  
Second Faculty of Medicine

Slide No. 99

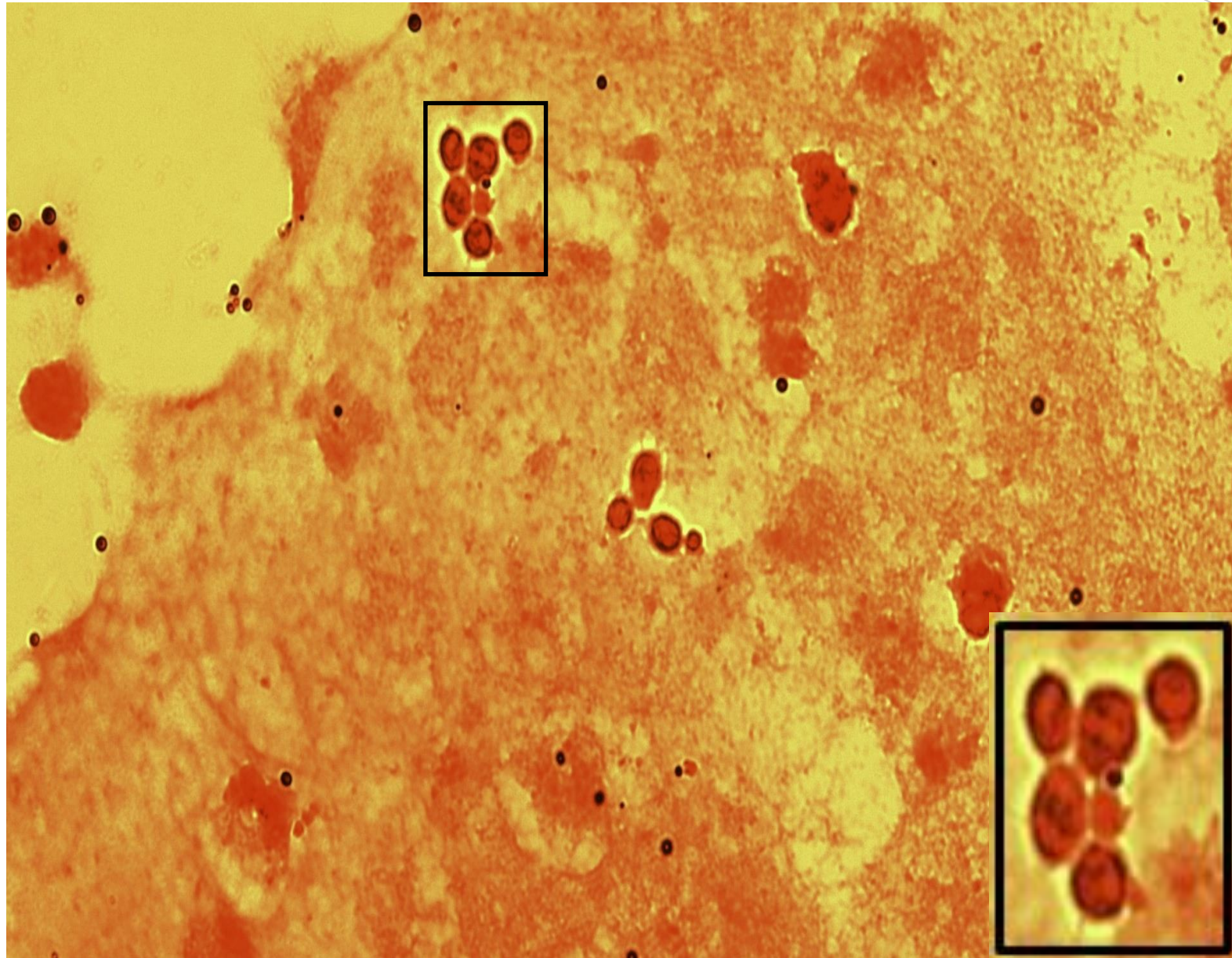
# *Candida albicans*

**Specimen:** bile

**Patient:** female, 53 years old

**Dg.:** malignant tumor of the large intestines

**Microscopy:** blastospores



Autor: MUDr. Alena Pířov



CHARLES UNIVERSITY  
Second Faculty of Medicine

Slide No. 100

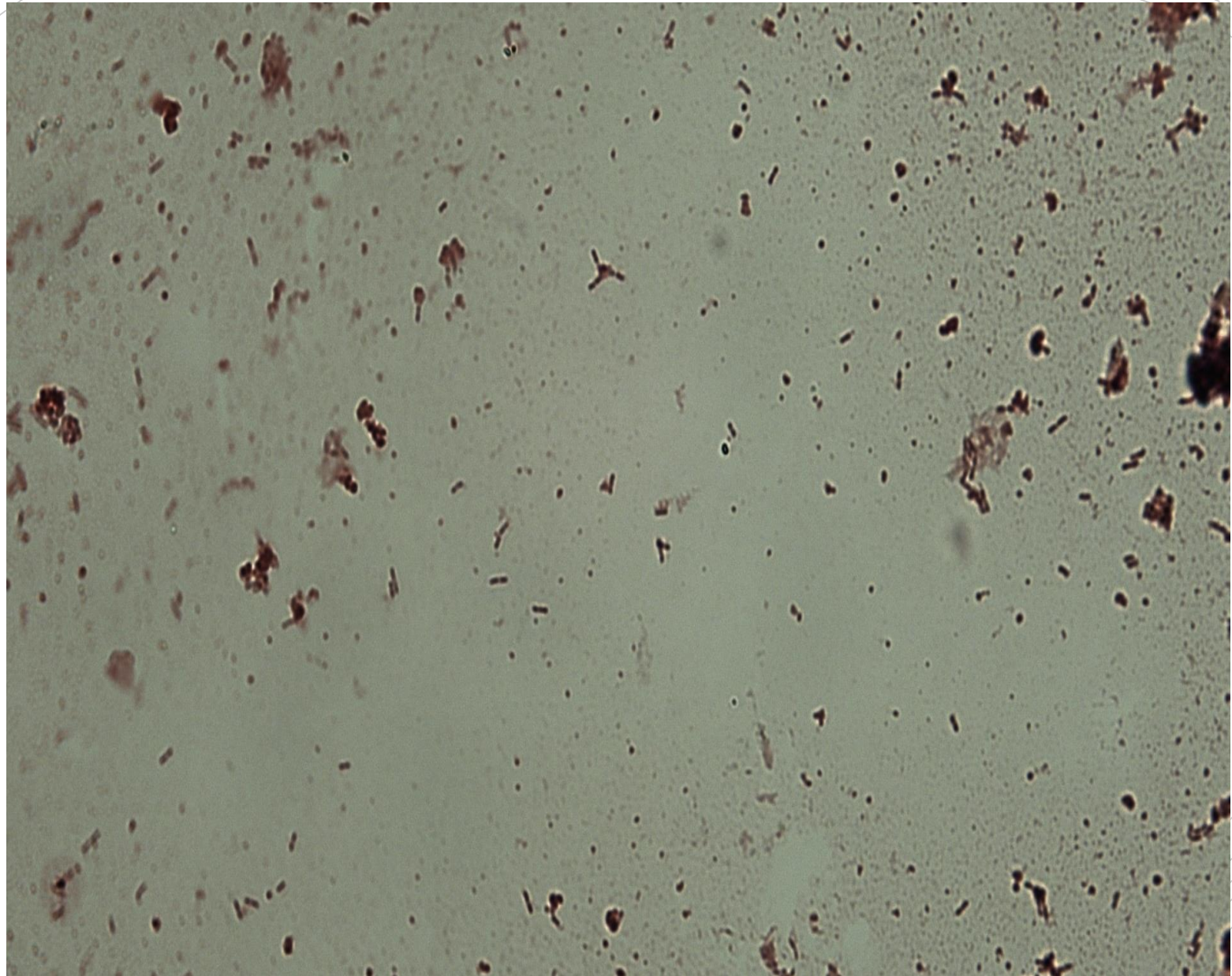
# *Listeria monocytogenes*

**Specimen:** hemoculture

**Patient:** male, 78 years old

**Dg.:** sepsis

**Microscopy:** gram-positive rods (in the sample they are forming clusters)



Autor: MUDr. Alena Pišová





CHARLES UNIVERSITY  
Second Faculty of Medicine

Slide No. 100


# *Listeria monocytogenes*

**Specimen:** hemoculture

**Patient:** male, 78 years old

**Dg.:** sepsis

**Microscopy:** gram-positive rods (in the sample they are forming clusters)



Autor: MUDr. Alena Pišová