

PROTOZOA

Oto Melter

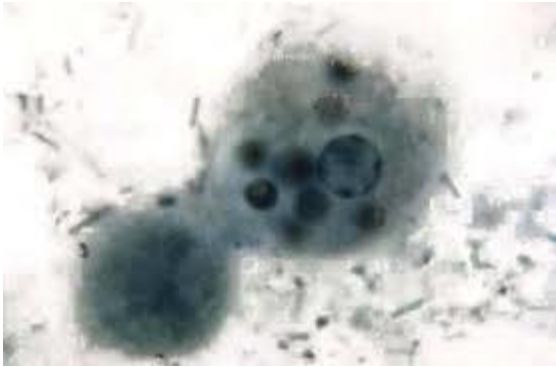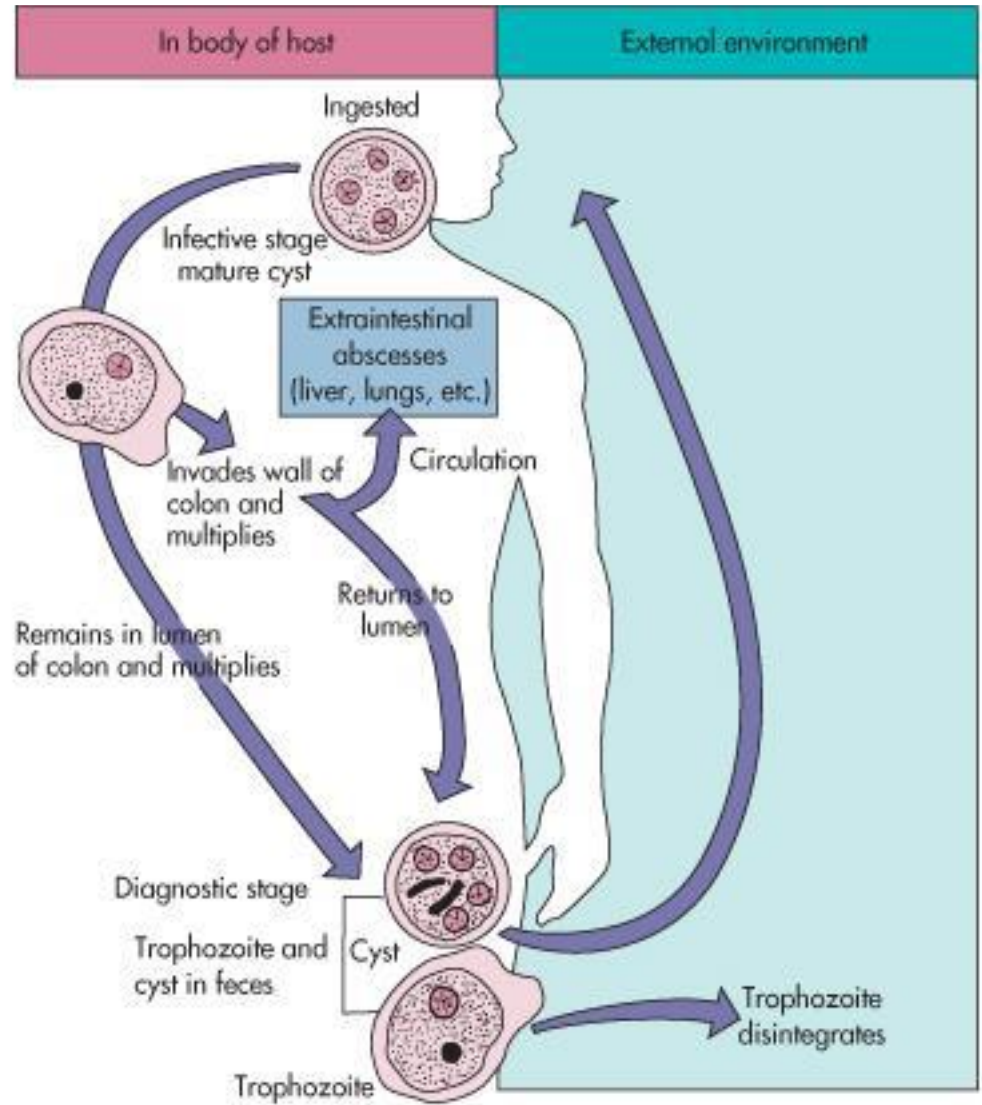
Taxonomy - classification

- A. **Amebas** - pseudopodia – moving and feeding. The **important pathogens** belonging to this group are ***Entamoeba histolytica*, *Naegleria fowleri*** and ***Acanthameba***.
- B. **Flagellates** – flagella – moving, cytostome - feeding. ***Trichomonas vaginalis*, *Giardia lamblia*, *Trypanosoma* species and *Leishmania* species** belong to this group.
- C. **Ciliates** - move by beating of cilia synchronously and have a more complex digestive system. In fact, they have a cytostome, a cytopharynx and vacuoles where they digest (***Balantidium coli*** – rare human GIT infection).
- D. **Sporozoa (apicomplexa)** - are obligate intracellular parasites that have a complex life cycle with more than one host and generally have a non motile adult form. Pathogens belonging to this group are: ***Cryptosporidium*, *Plasmodium* species and *Toxoplasma gondii***.

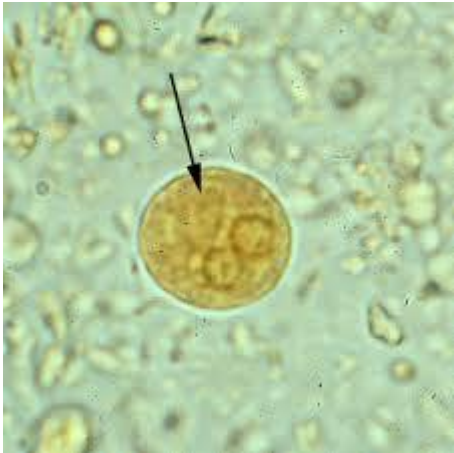Amebas – infections, diagnosis, treatment

- A. Amebas - pseudopodia – moving and feeding. The **important pathogens** belonging to this group are ***Entamoeba histolytica***, ***Naegleria fowleri*** and ***Acanthameba***.
- ***Entamoeba histolytica*** – *Amebic dysentery or liver abscess*, **source** – cysts in contaminated water or food form trophozoites in the small intestine, in colone feed on bacteria and may invade colon epithelium (ulceration), can spread to the liver (abscesses)
 - **Dg** – fecals samples – motile trophozoites or cysts in fecal samples, liver abscess – IgG specific antibodies
 - **Therapy** – metronidazol

Amebas – cycle



trophozoite



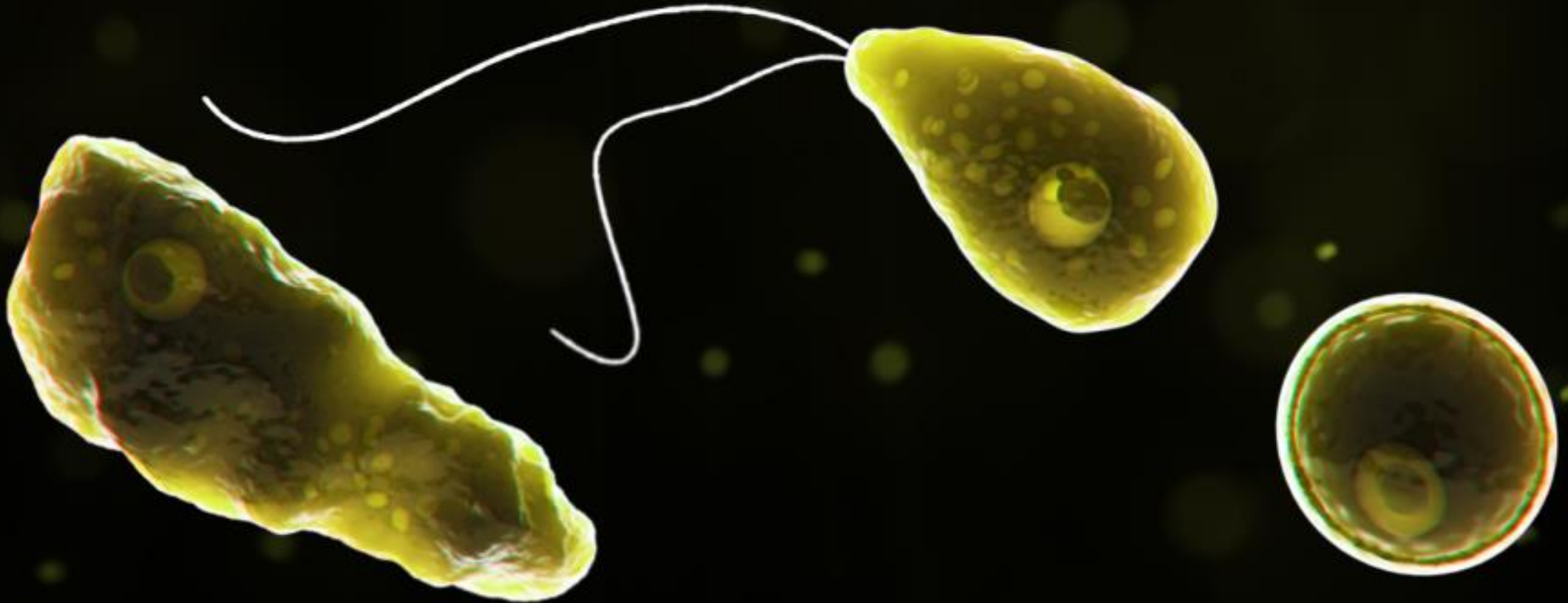cyst

<https://www.cdc.gov/dpdx/amebiasis/index.html>

Other ameboid

Naegleria fowleri (commonly referred to as the “**brain-eating amoeba**” or “brain-eating ameba”), is a free-living microscopic ameba, (single-celled living organism). It can cause a **rare and devastating infection** of the brain called **primary amebic meningoencephalitis (PAM)**. The ameba is commonly found in warm freshwater (e.g. lakes, rivers, and hot springs) and soil. **Source-**contaminated water enters the body through the nose. Once the ameba enters the nose, it travels to the brain where it causes PAM, which is usually fatal. Infection typically occurs when people go swimming or diving in warm freshwater places, like lakes and rivers. In very rare instances, *Naegleria* infections may also occur when contaminated water from other sources (such as inadequately chlorinated swimming pool water or heated and contaminated tap water) enters the nose. You **cannot** get infected from **swallowing** water contaminated with *Naegleria*.

Naegleria fowleri



Computer-generated representation of Naegleria fowleri in its ameboid trophozoite stage, in its flagellated stage, and in its cyst stage. (CDC, Atlanta)

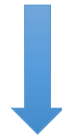Acanthamoeba

Acanthamoeba is a microscopic, free-living amoeba, or amoeba (single-celled living organism), that can cause rare, but severe **infections of the eye, skin, and central nervous system**. The amoeba is found worldwide in the environment in water and soil. The amoeba can be spread to the eyes through contact lens use, cuts, or skin wounds or by being inhaled into the lungs. Most people will be exposed to *Acanthamoeba* during their lifetime, but very few will become sick from this exposure. ***Acanthamoeba* keratitis** – An infection of the eye that typically occurs in healthy persons and can result in permanent visual impairment or blindness. **Granulomatous Amebic Encephalitis (GAE)** – A serious infection of the brain and spinal cord that typically occurs in persons with a compromised immune system. **Disseminated infection** – A widespread infection that can affect the skin, sinuses, lungs, and other organs independently or in combination. It is also more common in persons with a compromised immune system.

Flagellates – infections, diagnosis, treatment

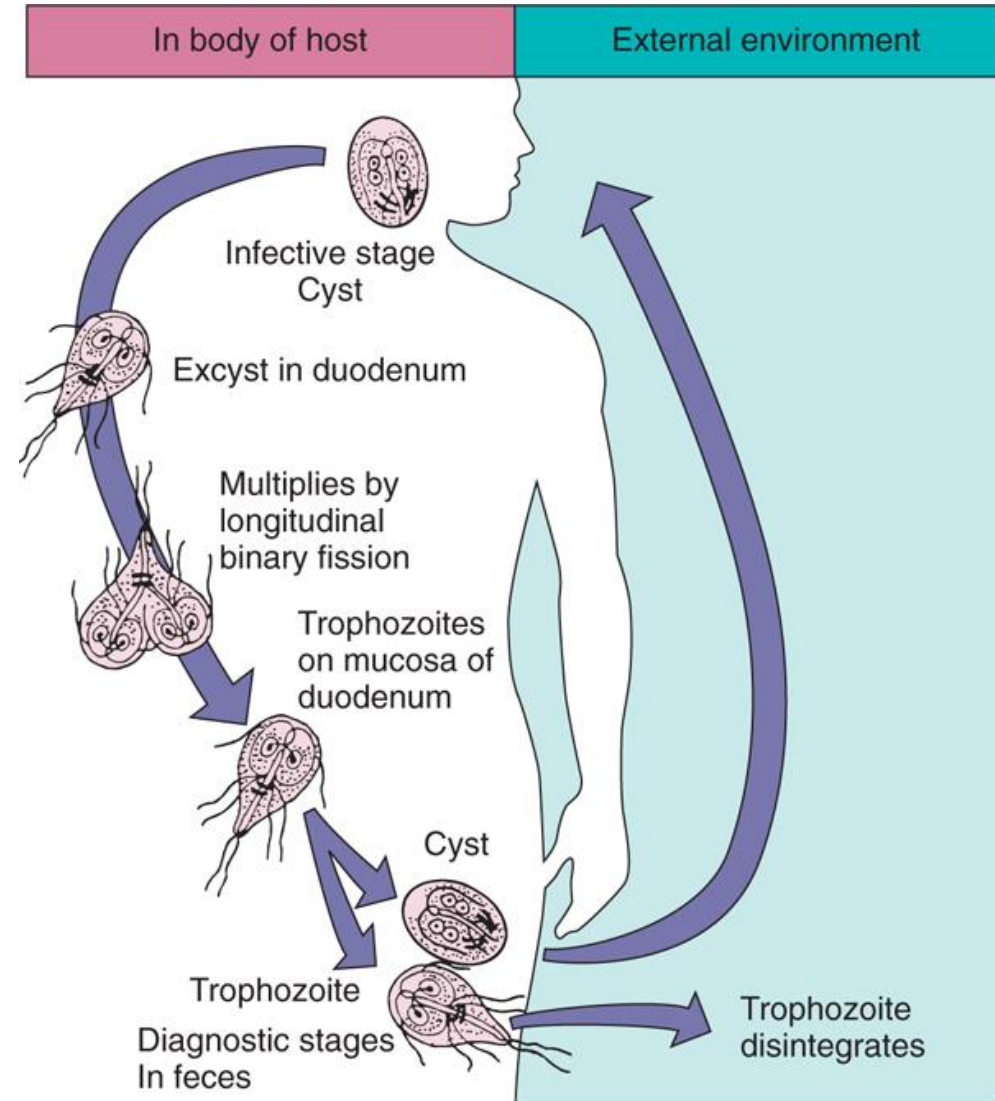
Giardia lamblia

- Two forms: cyst and motile trophozoite
- gastric acid stimulates excystation
- Release trophozoites in duodenum that adhere to small intestine wall



Interferes fat absorption!

Steatorrhea



Giardia lamblia

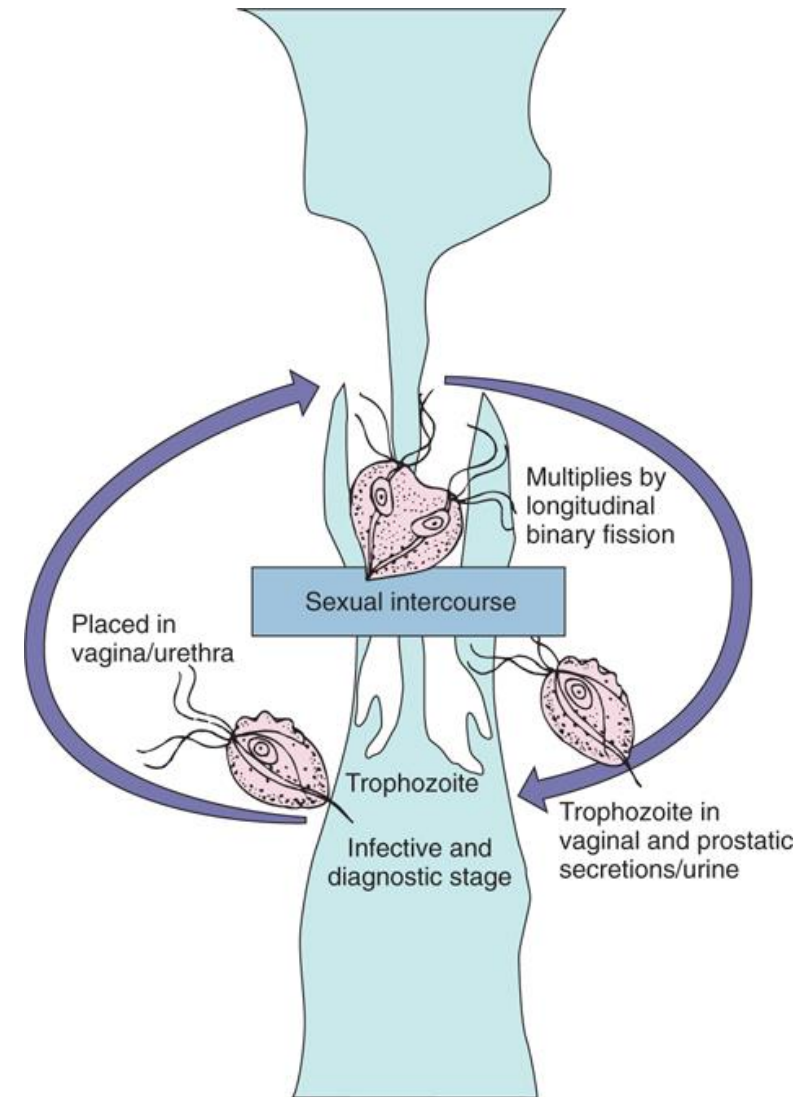
- Fat packed stools gives giardia it's best known symptom: **Foul smelling diarrhea!**
- Giardia does not invade the intestinal wall! There is NO blood in the stool!
- **Epidemiology:** worldwide, sylvatic, streams, lakes
- **Source - water, uncooked vegetables or fruits, fecal-oral transmission**
- cyst stage is resistant to chlorine concentrations used in most water-treatment facilities
- asymptomatic carriage (50%) or symptomatic disease, ranging from mild diarrhea to severe malabsorption syndrome
- Incubation 1-4 weeks, sudden onset
- spontaneous recovery after 10-14d, although more chronic disease with multiple relapses - particularly pp with Ig A deficiency or intestinal diverticula.

Giardia lamblia

- Diagnosis:
 1. Examination of stool specimens for cysts/ trophozoites
 2. You should never accept single negative
 3. 1 specimen/day for 3 days should be examined
- If remain negative and giardiasis is highly suspected: duodenal aspiration, string test, or biopsy of upper small intestine
- Immunologic tests for fecal antigen: highly sensitive and specific
- **Treatment: metronidazole**

Trichomonas vaginalis

- Flagellate, 4 short flagella, undulating membrane, Trophozoite form only
- Disease: UTI's
 - men: urethra + prostate
 - women: urethra + vagina
- Clinical:
 - **women:** asymptomatic or scant, watery vaginal discharge;
 - vaginitis: extensive inflammation (strawberry vagina)
 - Frothy, malodorous, yellow green vaginal discharge
 - erosion of epithelial lining – itching, burning and painful urination
 - **men:** mainly asymptomatic carriers
 - occasionally: urethritis, prostatitis, other urinary problems

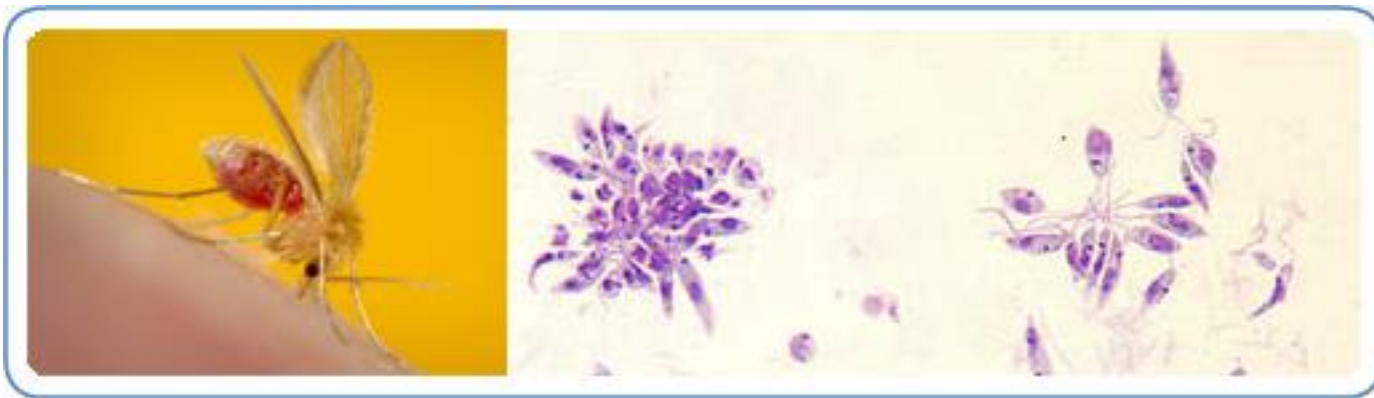


Trichomonas vaginalis

- Epidemiology: worldwide; developed countries: 5-20% women; 2-10% men;
- Transmission:
 - Sexual intercourse
 - Fomites (eg.clothing)
 - Birth canal infection;
- Laboratory Diagnostics:
 - microscopic examination of urethral/ vaginal discharge – unstained or stained with Giemsa, Papanicolau – motile trophozoites
 - Improved by culture or monoclonal fluorescent Ab staining (good sensitivity);
- Treatment: metronidazole – patient + sexual partner

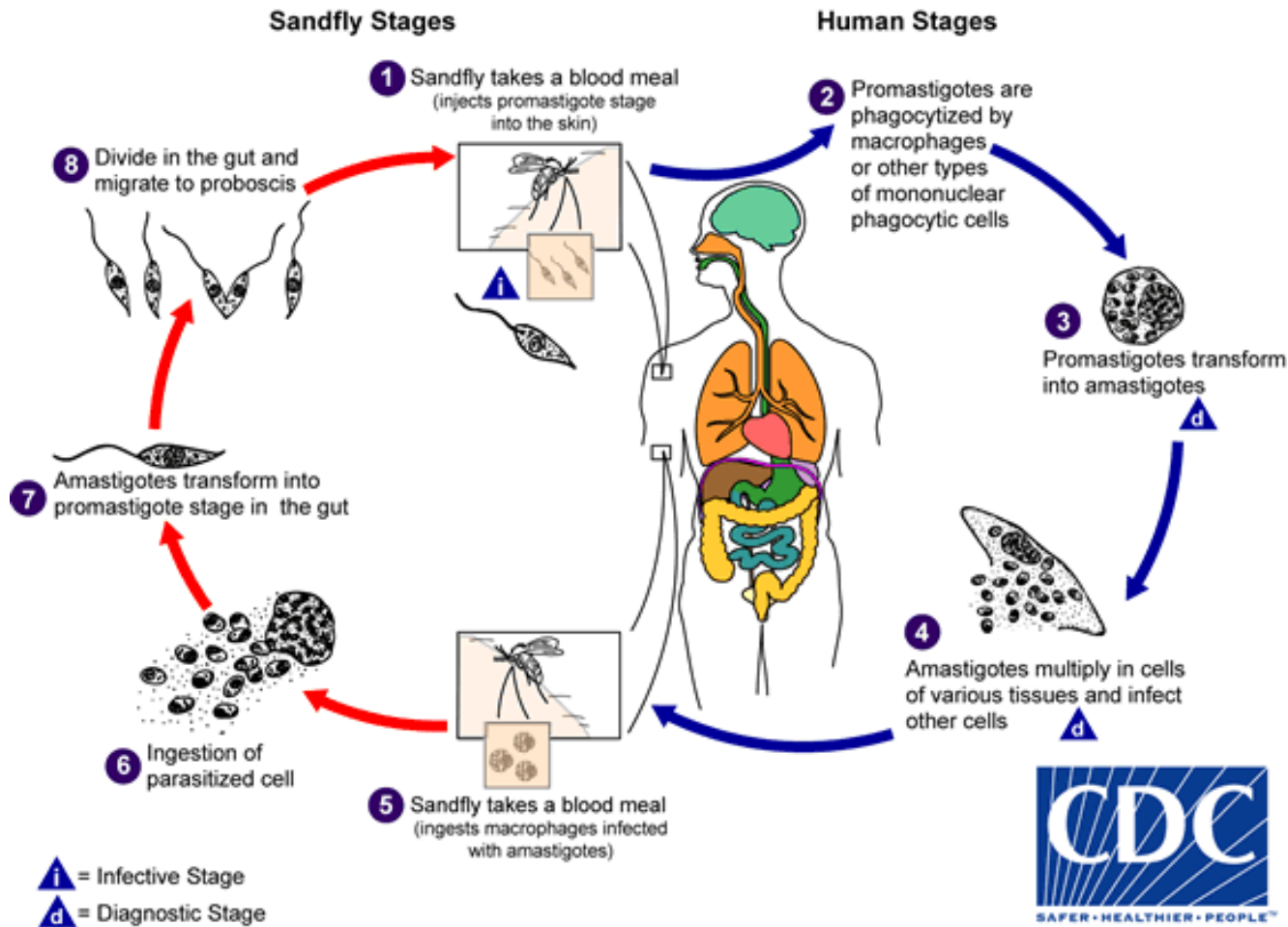
Leishmania (*L. donovani*, *L. tropica*, *L. mexicana*)

Leishmaniasis is a parasitic disease that is found in parts of the tropics, subtropics, and southern Europe. Leishmaniasis is caused by infection with *Leishmania* parasites, which are **spread** by the bite of **phlebotomine sand flies**. There are several different forms of leishmaniasis in people. The most common forms are **cutaneous leishmaniasis**, which causes skin sores, and **visceral leishmaniasis**, which affects several internal organs (usually spleen, liver, and bone marrow).



The sand flies that transmit the parasite are only about one third the size of typical mosquitoes or even smaller. On the left, an example of a vector sand fly (*Phlebotomus papatasi*) is shown; its blood meal is visible in its distended transparent abdomen. On the right, *Leishmania* promastigotes from a culture are shown. The flagellated promastigote stage of the parasite is found in sand flies and in cultures. (CDC, Atlanta)

Leishmania life cycle



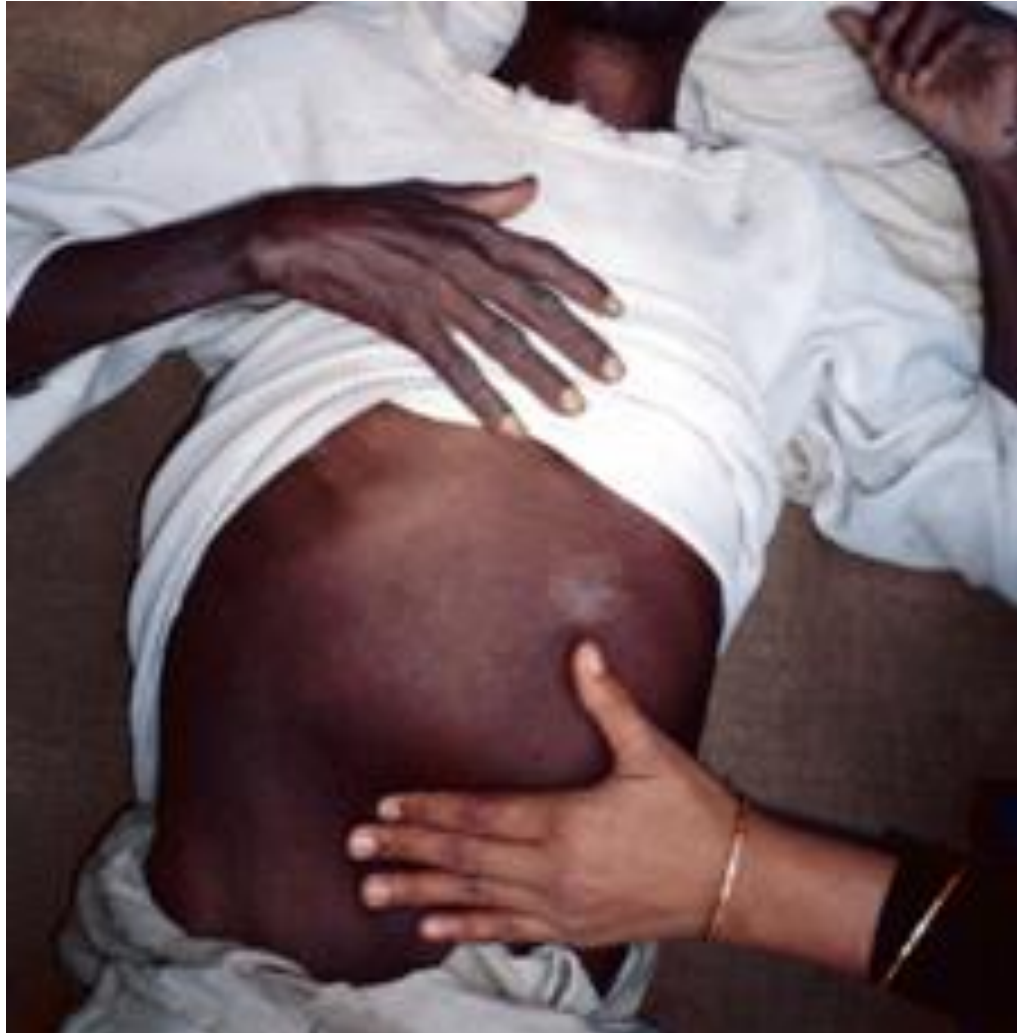Leishmaniasis is transmitted by the bite of infected female phlebotomine sandflies. The sandflies inject the infective stage (i.e., promastigotes) from their proboscis during blood meals. The **number 1**. Promastigotes that reach the puncture wound are phagocytized by macrophages. The **number 2** and other types of mononuclear phagocytic cells. Promastigotes transform in these cells into the tissue stage of the parasite (i.e., amastigotes) The **number 3**, which multiply by simple division and proceed to infect other mononuclear phagocytic cells. The **number 4**. Parasite, host, and other factors affect whether the infection becomes symptomatic and whether cutaneous or visceral leishmaniasis results. Sandflies become infected by ingesting infected cells during blood meals (The **number 5**, The **number 6**). In sandflies, amastigotes transform into promastigotes, develop in the gut and migrate to the proboscis. The **number 8**.

Infections

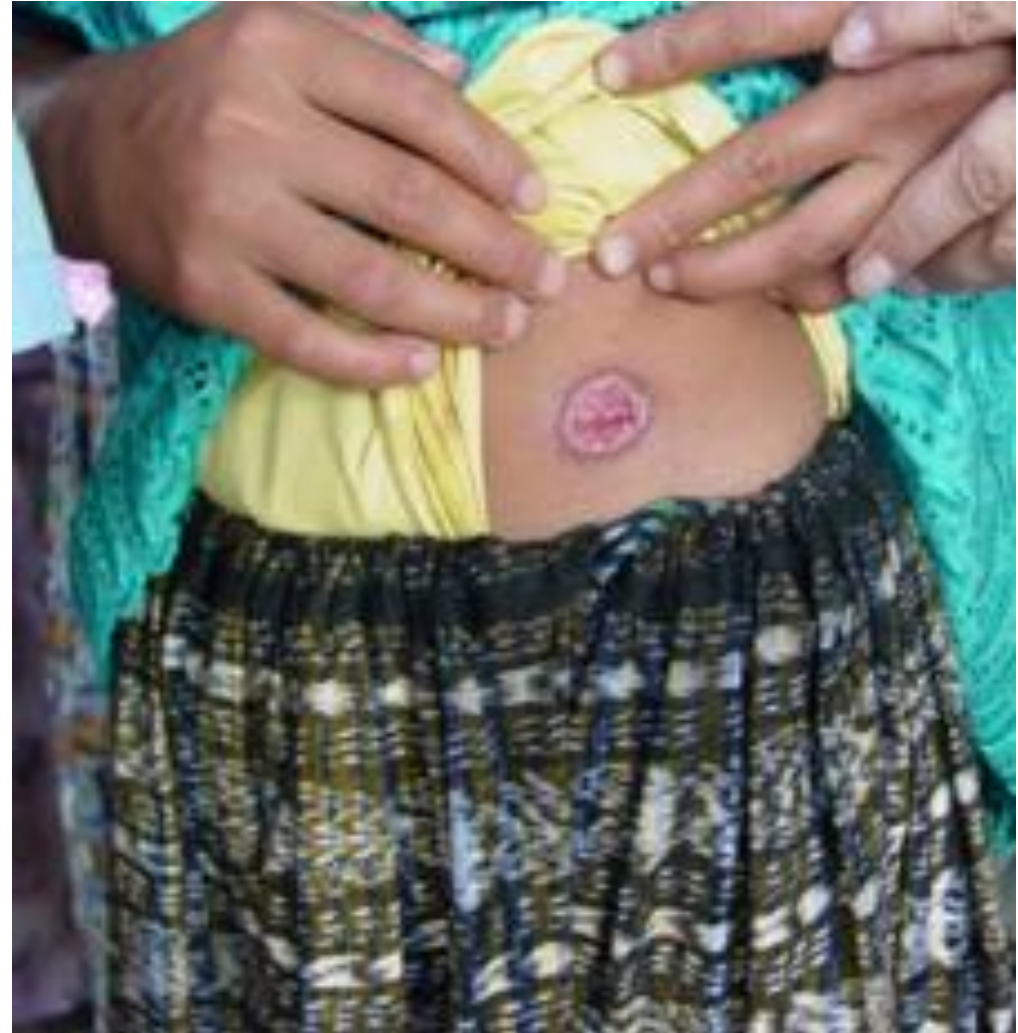The most common form is **cutaneous leishmaniasis**, which causes skin sores. The sores typically develop **within a few weeks** or months of the sand fly bite. The sores can change in size and appearance over time. The sores may start out as papules (bumps) or nodules (lumps) and may **end up as ulcers** (like a volcano, with a raised edge and central crater); skin ulcers might be covered by scab or crust. The sores usually are painless but can be painful. Some people have swollen glands near the sores (for example, under the arm, if the sores are on the arm or hand).

The other main form is **visceral leishmaniasis**, which affects several internal organs (usually spleen, liver, and bone marrow) and **can be life threatening**. The illness typically **develops within months** (sometimes as long as years) of the sand fly bite. Affected people usually have fever, weight loss, **enlargement (swelling) of the spleen and liver**, and low blood counts—a low red blood cell count (anemia), a low white blood cell count (leukopenia), and a low platelet count (thrombocytopenia).

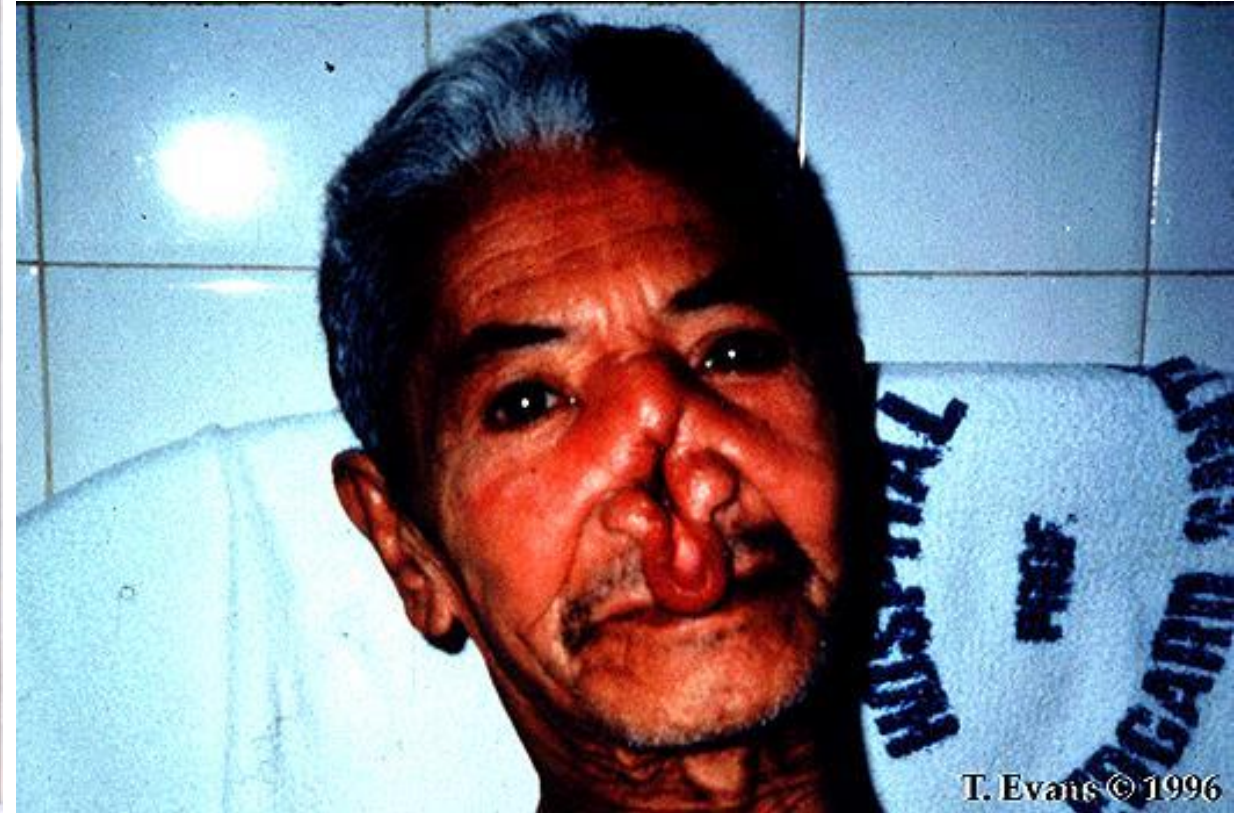
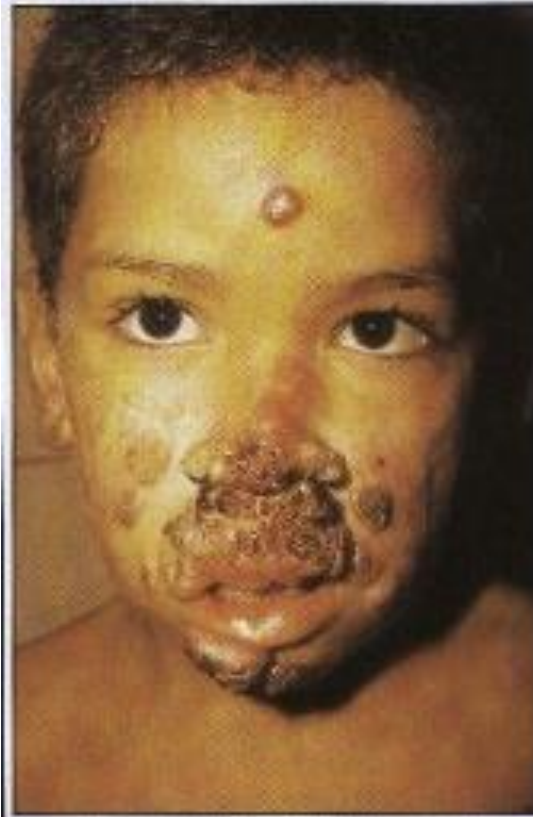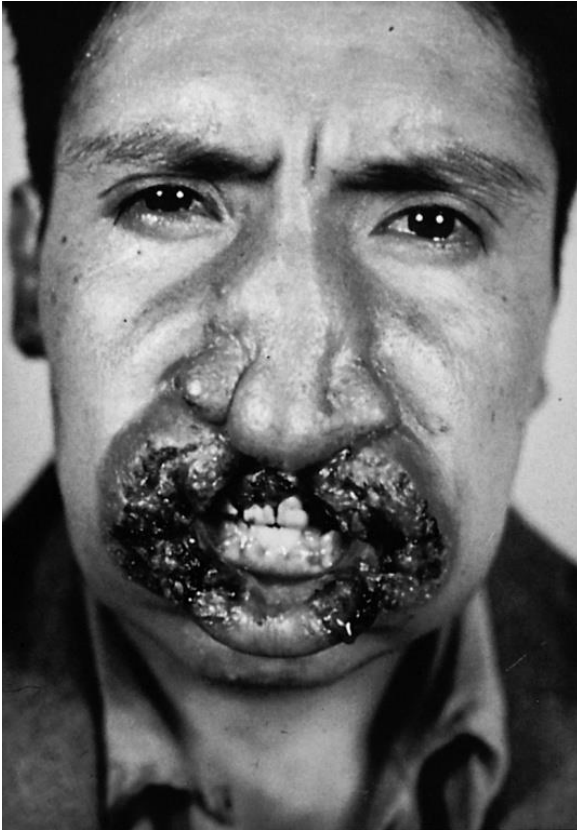
Mucosal leishmaniasis is an example of one of the less common forms of leishmaniasis. This form can be a sequela (consequence) of infection with some of the species (types) of the parasite that cause cutaneous leishmaniasis in parts of Latin America: certain types of the parasite might spread from the skin and cause sores in the **mucous membranes of the nose** (most common location), **mouth, or throat**. The best way to prevent mucosal leishmaniasis is to ensure adequate treatment of the original cutaneous (skin) infection.



Marked splenomegaly (enlargement/swelling of the spleen) in a patient in lowland Nepal who has **visceral leishmaniasis**. (Credit: C. Bern, CDC)



Ulcerative skin lesion, with a raised outer border, on a Guatemalan patient who has **cutaneous leishmaniasis**. (Credit: B. Arana, MERTU, Guatemala)



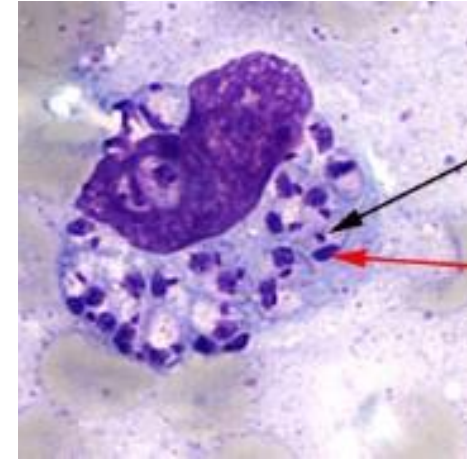
Mucosal leishmaniasis Lesions may multiply and increase in size, which can contribute to severe deformity. Because it causes major disability, those infected may be humiliated and suffer from being ostracized by their society. Respiratory tract mucosal invasion may also occur, causing numerous respiratory problems, and can result in malnutrition and pneumonia. **Secondary infection is responsible for most deaths.**

(<https://web.stanford.edu/class/humbio103/ParaSites2006/Leishmaniasis/Mucocutaneous.htm>).

Diagnosis and therapy

Various laboratory methods can be used to diagnose leishmaniasis—to detect the parasite as well as to identify the *Leishmania* species (type). Some of the methods are available only in reference laboratories. In the United States, CDC staff can assist with the testing for leishmaniasis.

Tissue specimens—such as from skin sores (for cutaneous leishmaniasis) or from bone marrow (for visceral leishmaniasis)—can be examined for the parasite under a microscope, in special cultures, and in other ways. Blood tests that **detect antibody (an immune response)** to the parasite can be helpful for cases of visceral leishmaniasis; tests to **look for the parasite itself** usually also are done.



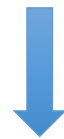Light-microscopic examination of a stained bone marrow specimen from a patient with visceral leishmaniasis—showing a macrophage (a special type of white blood cell) containing multiple *Leishmania amastigotes* (the tissue stage of the parasite). Note that each amastigote has a **nucleus** (red arrow) and a rod-shaped **kinetoplast** (black arrow). Visualization of the kinetoplast is important for diagnostic purposes, to be confident the patient has leishmaniasis. (CDC Atlanta)

Therapy – sodium stibogluconate with pentamidine and amphotericin B

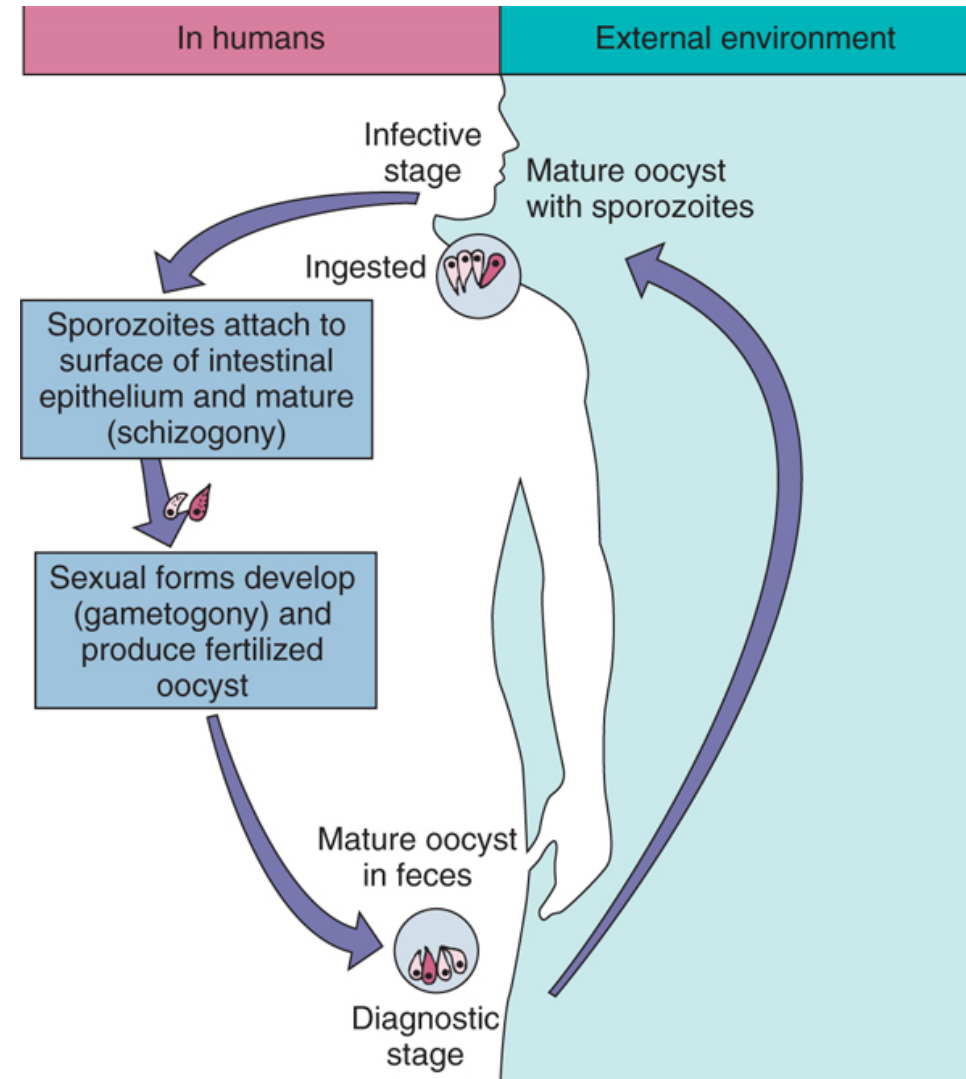
Sporozoa (apicomplexa) – GIT infections, diagnosis, treatment

Cryptosporidium

- Intestinal apicomplexa
- Ingested as round oocyst with 4 motile sporozoites
- Life cycle occurs within intestinal epithelial cells and produce more infectious oocysts



Causes diarrhea and abdominal pain



Cryptosporidium

- In normal patient – Self-limiting
- In **Immunocompromised** – severe diarrhea that is life-threatening (3-17L of stools per day!!)
- **Epidemiology:**
 - worldwide
 - Fecal-oral usually by waterborne transmission;
 - Resistant to usual water-purification procedures (chlorination and ozone); zoonotic spread;
 - Risk: veterinaries, animal handlers, homosexuals; municipal swimming pools and day-care centers;

Cryptosporidium

- Diagnosis:
 - **Acid-fast** oocysts in stool sample
 - Minimum 3 specimens should be examined
- Therapy:
 - Main goal is restoration of immune function
 - Fluid replacement
 - Nitazoxanide or paramomycin can be tried

Sporozoa (apicomplexa) – bod/tissue infections, diagnosis, treatment

Plasmodium

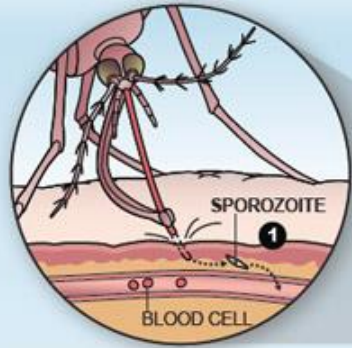
- 2 hosts: *Anopheles* mosquito (sexual) & humans/animals (asexual)
- Infection of **300-500 million people worldwide/ year**
- **1-3 million deaths/year** (85% Africa);
- **Life cycle: sporozoites** (thin, motile, spindle-shaped) in *Anopheles* saliva
- Bite -> blood -> liver -> asexual reproduction:
 - **Trophozoite:** sporozoite rounds up into a ball
 - **Schizont:** big mass, many nuclei
 - **Merozoites:** from cytoplasmic division of schizont; released from overloaded liver cell

Sporozoa (apicomplexa) – bod/tissue infections, diagnosis, treatment

Plasmodium

- *P. vivax* & *P. ovale* establish dormant stage: **hypnozoites**
- attach/ enter RBCs: **erythrocytic cycle**
- 3 phases:
 - 1. Immature trophozoite/ **ring** (nuclear material resembles diamond)
 - 2a. **Mature trophozoite**
 - 2b. Development into gametocytes - sexual reproduction if ingested by anopheles;
 - 3. **Schizont**, rupture RBC releasing **merozoites** -> **fever, chills and sweats**

The Life Cycle of Malaria



1 To start the cycle, an infected female *Anopheles* mosquito injects sporozoites into the skin while feeding.

An infected mosquito starts the cycle



SPOROZOITES

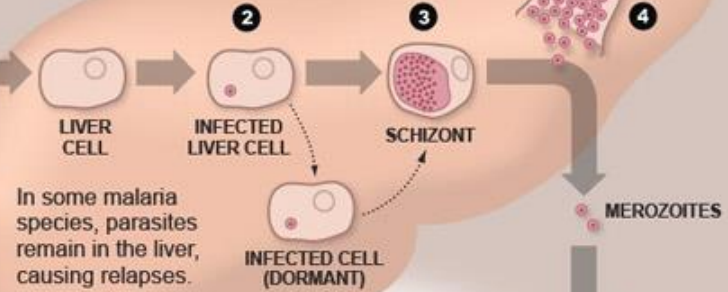


2 Sporozoites enter the blood stream and are carried to the liver, where they infect liver cells.

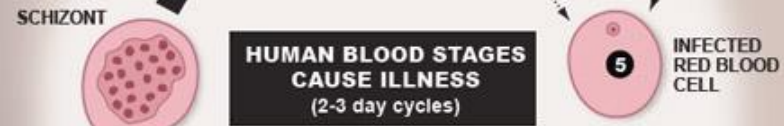3 Within liver cells, the parasites develop into schizonts.

4 The schizonts rupture, releasing thousands of individual merozoites into the bloodstream.

HUMAN LIVER STAGES (About 2 weeks)



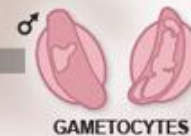5 Merozoites infect red blood cells.



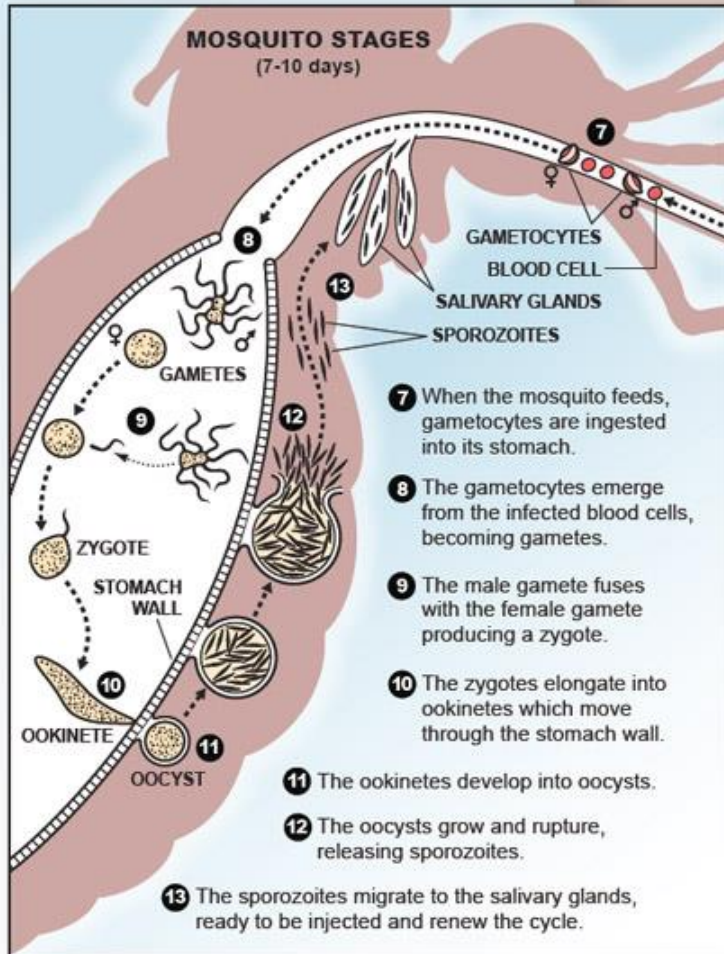
TROPHOZOITE

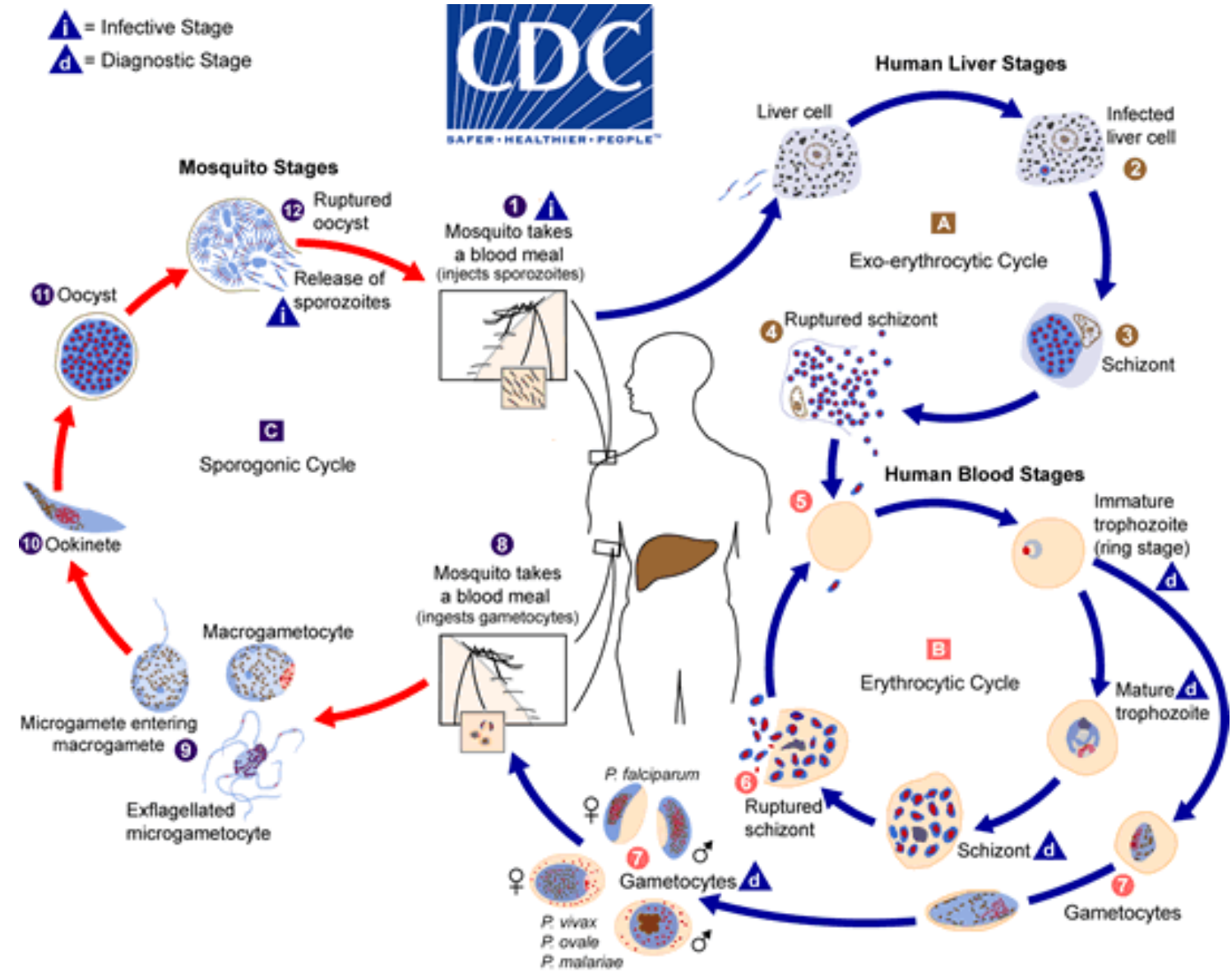
RING STAGE

Another mosquito becomes infected, continuing the cycle



6 Some parasites change into male and female forms called gametocytes.





References: <https://www.cdc.gov/malaria/about/biology/index.html>

Plasmodium falciparum

- Tropical and subtropical regions with frequent co-infection with HIV
- shortest incubation period: 7-10 days
- early influenza-like signs
- Chills, fever with profuse sweating
- malignant tertian malaria (36-48h);
- capillary plugging
- **cerebral malaria that can lead to coma and death**
- kidney damage – intravascular hemolysis and hemoglobinuria
- hepatosplenomegaly – abdominal pain, vomiting of bile, diarrhea and dehydration
- * trophozoite/ schizonts in liver & spleen
- peripheral blood smears: only young rings/ gametocytes

Plasmodium falciparum

- Chloroquine-resistant strains in all endemic areas (Africa, Southeast Asia, South America); exception in Central America & Caribbean regions
- If not-resistant: **chloroquine** or **parenteral quinine**;
- **Resistant:**
 - **mefloquine ± artesunate**
 - artemether ± lumefantrine
 - quinine, quinidine, doxycycline, atovaquone-proguanil (Malarone), pyrimethamine-sulfadoxine (Fansidar),
- Quinine, pyrimethamine-sulfadoxine: may be toxic; treatment rather than prophylaxis
- Newer agents against multidrug-resistant strains:
 1. Phenanthrene methanols: halofantrine and lumefantrine;
 2. Artemisinins: artemether, artesunate
- * **Whole-blood exchange: if available; in severe cases; cerebral malaria**, acute lung injury, severe hemolysis with acidemia, shock, or a rising level of parasitemia despite adequate IV therapy;

Plasmodium vivax and *P. ovale*

- Differences from *P. falciparum*:
- Most prevalent; in tropics, subtropics and temperate regions
- Incubation 10-17 days
- Tertian malaria – chills, fever, sweats every 48h

- Ability to form **hypnozoites** in liver – **cause relapsing malaria!**

- Treatment: Cloroquine + Primaquine (for hypnozoites)

Plasmodium malariae

- Longest Incubation: 18-40days
- Quartan malaria – 72h intervals
- Moderate to severe attacks and can persist for hours

Plasmodium - diagnosis

- **Thick and thin blood smears** 1000x under oil emersion;
- **Only young rings/ gametocytes**
- infected RBCs do not enlarge/ become distorted (vs *P. Vivax* and *P. ovale*)

- Rapid Ag based diagnostic tests (expensive)
- PCR

Natural protection

- Absence of RBC membrane antigens **Duffy a** and **b** that *P.vivax* uses for binding
- Sickle cell anemia trait protects RBC from *P. falciparum*

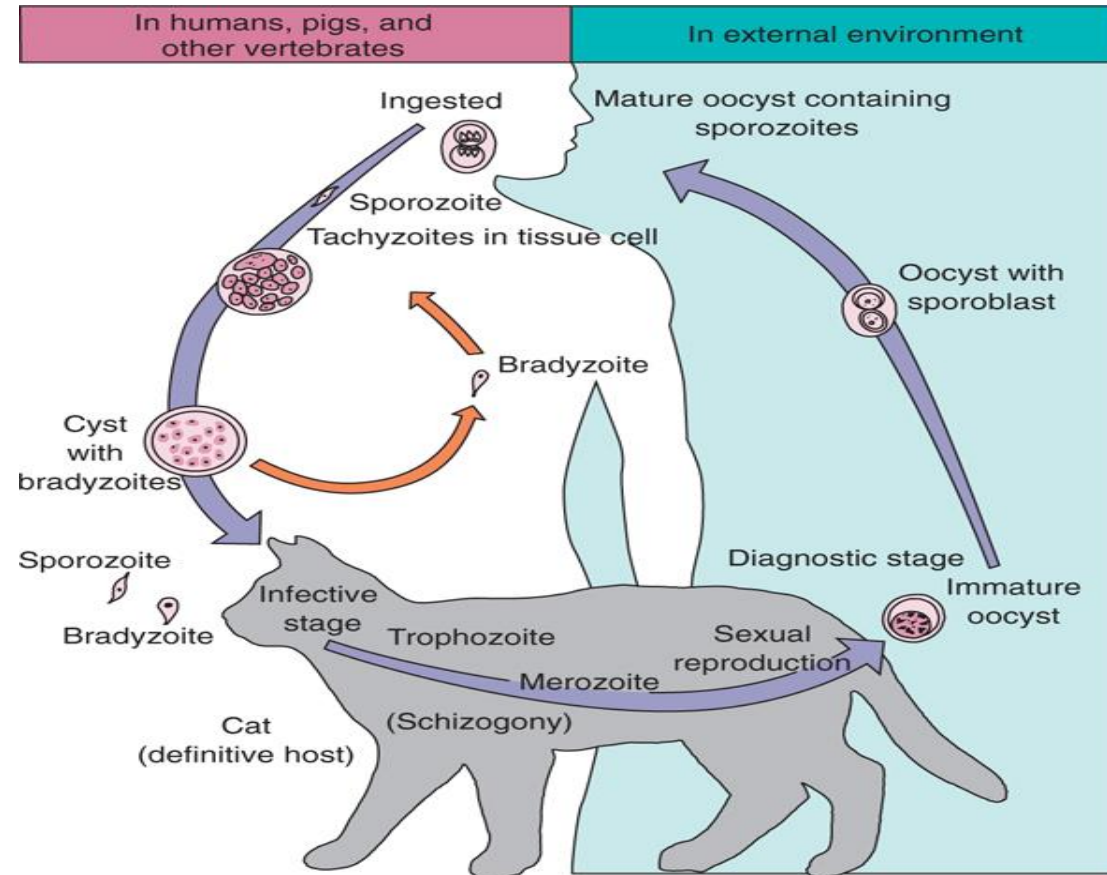
Toxoplasma gondii

- **Coccidian parasite.** Phylum Sporozoa.
- **Intracellular parasite** in birds and humans
- Reservoir is household cat.
- Many other animal sources. Humans into contact with:
 - 1) Improperly cooked from animals that are intermediate hosts.
 - 2) Ingestion of infective oocysts.

Toxoplasma gondii

- Uncooked meats/ meat juices or contact with cat faeces.
- **Clinical:**
- TRANSPLACENTAL infection (vertical), also transfusions and IV drug users.
- Most infections are asymp. Problem when it relocates from blood to tissue (becoming an intracellular parasite)
- Lung, heart, lymphoid organs and CNS.

Toxoplasma gondii



Toxoplasma gondii

- **Signs and symptoms:**

- Acute- rash, fever, chills.
- Chronic- hepatitis, lymphadenitis, myocarditis and chorioretinitis -> blindness.

- **1st Tri= Spontaneous abortion or still birth.**

- After 1st: Asymp. but then: Epilepsy, encephalitis, microcephaly, hydrocephalus, chorioretinitis.

Toxoplasma gondii

- **Diagnosis:**
- **Serology for acute infections** (serially collected bloods with increasing Ab titres).
- Immunocompetent **pregnant women**: test **IgM and IgG Abs** to *T.gondii*. Confirmation - at a Toxoplasma reference lab.
- **MRI to dg toxo-encephalitis.**

Toxoplasma gondii

- **Treatment:**
- Most mononucleosis-like infections resolve spontaneously and require no therapy.
- **Always treat disseminated or CNS toxo**
- HIV setting means high dose of Pyrimethamine and sulphadiazine and then low dose forever.
- Co-trimoxazole/trimethaprim sulpha

Trypanosomes

- Two distinct disease forms.
 - 1. T. brucei gambiense and T. brucei rhodiense**
 - Tsetse fly vector >> African sleeping sickness
 - 2. T. cruzi**
 - Reduviids >> Chagas disease (American)

Trypanosoma brucei gambiense

- Trypomastigote is infective stage, present in salivary glands of transmitting **Tsetse flies**.
- Has **free flagella** and **undulating membrane**.
- Moves into the organism through bite wound of the fly, into CNS- reproduce in blood, lymph and CSF by binary or longitudinal fission.
- Another Tsetse infected when bites human
- Epimastigote develops into Trypo after 4-6wks

Trypanosoma brucei gambiense

Clinical:

- **Ulcer at bite site.** Chronic course, usually fatal. Lymph nodes invaded with swelling of post. cervical LNs typical in Gambian.
- **Mental retardation, meningoencephalitis.** Then convulsions, hemiplegia and incontinence.
- **Death due to CNS damage** or infections (malaria/pneum)

Trypanosoma brucei gambiense

Lab diagnosis:

- **Thick** and **thin films** in concentrated anti-coagulated blood preparations and LN and CSF aspirations. Centrifugation and anion-exchange chromatography.
- **ELISA** or **immunofluorescence** but costly and reagents can't be bought
- **PCR**

Trypanosoma brucei gambiense

Treatment:

- Suramin treats acute blood and lymphatic stages of the dz. Suramin and alternative Pentamidine dont cross BBB. So Melarsoprol is used in CNS involvement.
- DFMO (Difluoromethylornithine) is a cytostatic used for acute and late (CNS) stages.
- Use of traps and insecticide with the drugs most effective.

Trypanosoma brucei rhodesiense

- Similar life cycle to *T.b.gambiense*.
- Incubation shorter.
- Cattle and sheep are hosts and wild game animals reservoir hosts.
Makes it more difficult to control!
- Acute illness (fever, rigors and myalgia)
- 9-12 months dead

Trypanosoma brucei rhodesiense

Lab diagnosis:

- Blood and CSF like T.b.gambiense

Treatment:

- Same again!

Trypanosoma cruzi

- Additional Amastigote- no flagellum and no undulating membrane.
- Infective trypomastigote found in faeces of Reduviid 'kissing bug' enters wound. Mouth usually site of bite!
- Trypomastigote has tropism to cardiac muscle, liver and brain -> Loses flagellum and undulating memb -> Into Amastigote

Trypanosoma cruzi

- Chagoma at bite site and oedema and rash around eyes and face as Romana sign.
- Lacking agents against Chagas'
- Benzidazole and Nifurtimox for acute but not so much for chronic.
- Major side effects.
- DDT for everyone means less malaria and Chagas'.

Chagoma

