

# *NON-PURULENT NEUROINFECTIONS*

*Dušan Pícha*

*1st Clinic for Infectious Diseases*  
*Charles University*

# Patophysiological mechanisms in CNS inflammation I.

## PRIMARY CYTOPATHIC LESION

- Direct viral damage : lyssa; TBE ...

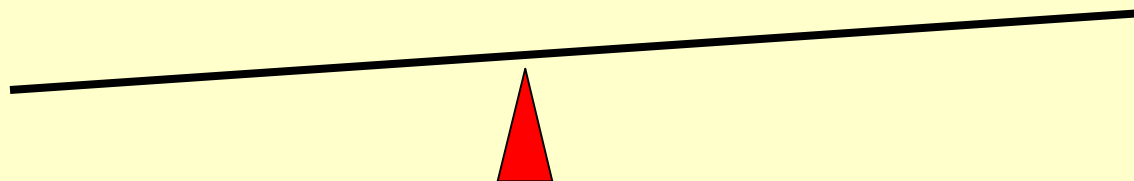
## IMMUNOPATHOLOGICAL REACTIONS

- 1. **HEB break-through** (nonspecific inflammatory reactions)
- 2. **cell damage** (elevated level of autoantigens)
- 3. **auto-sensibilisation** (autoreactive clones of cells, autoantibodies)
- 4. **autoimmune reaction** (pathological impact but downregulated finally; parainfection encephalomyelitis; morbili, rubella ...)
- 5. **autoimmune disease triggered** (SSPE, MS)

*infectious agent*

*immunity*

*autologic tissue - CNS*



# Patophysiological mechanisms in CNS inflammation II. - TOXIC DAMAGE

## Toxoinfectious encephalopathy

- Exo a endotoxins of bacteria and viruses
    - Exotoxins - shigella, adenoviruses, influenza
    - Intestinal infections – absorbed toxins
  - Patogenesis: disturbances - vascular, metabolic, hypoxia, small infarctions
  - Pathological source: – brain edema; reversible changes; duration hours - days
  - Clinical manifestation: disturbances of consciousness, increasing of muscular tonus, spasms, dysautonomia
  - Treatment: 1) symptomatic: antipyretics, antiedematous treatment, antiepileptics  
2) treatment of basic disease (ATB ...)
- 

- botulism
- tetanus
- diphtheria
- pertussis

# *Patophysiological mechanisms in CNS inflammation III*

- ***METABOLIC ORIGIN***

- *Collapse of metabolism: Reye sy., mitochondrial diseases*
- *Decompensation of endocrinopathies: DM, thyreopathy ...*

- ***MICROVASCULAR DAMAGE***

*Embolism* – *ictus, abscess*

*Microembolism: sepsis – microabscesses, diffuse  
or disperse lesions*

*Encephalopathy: mediators of sepsis, DIC,  
hypotension ...*

# Patophysiological mechanisms in CNS inflammation IV. DYNAMIC

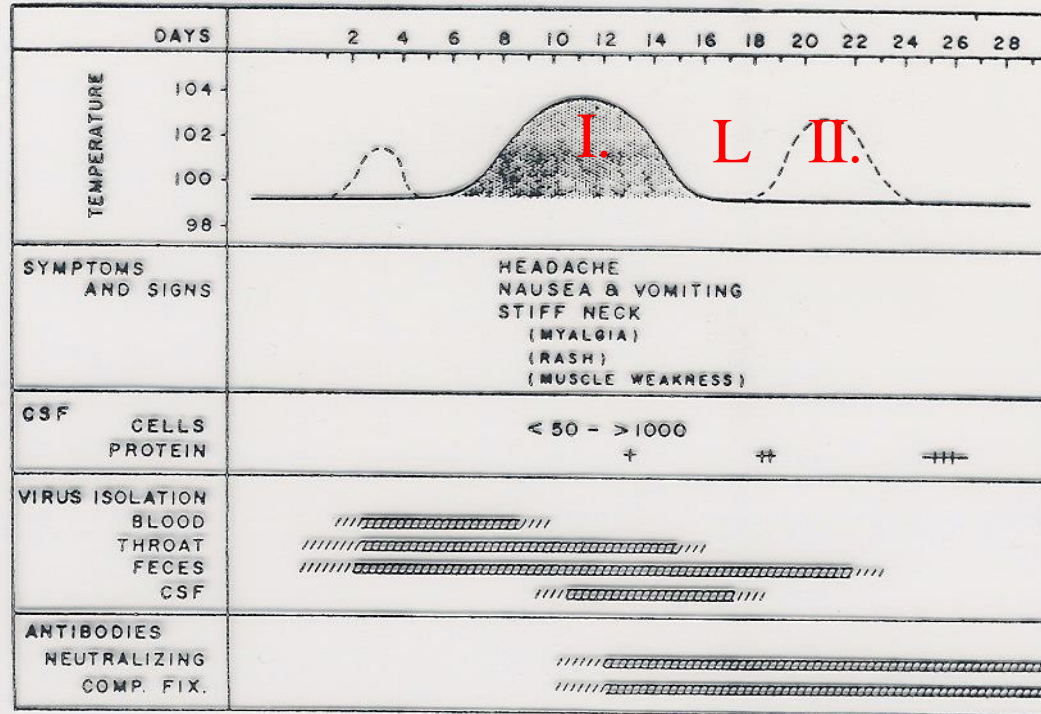


FIG. 2. The clinical course of EV aseptic meningitis. (From Horstmann and Yamada, ref. 86, with permission.)

Table 39-7 Viral neurologic syndromes

Virus identification	Common diseases	Acute meningitis	Acute encephalitis	Meningomyelitic*	Subacute encephalomyelitis†	Static embryopathy	Progressive encephalopathy
Parvoviruses	Arthritis	0	0	0	0	0	0
Papovaviruses	Warts, PML	0	+	0	+	0	+++
Hepadnaviruses	Hepatitis B	0	+	0	0	0	0
Adenoviruses	Acute upper respiratory infection	+	+	0	+	+	0
Iridoviruses	No human disease	0	0	0	0	0	0
Poxviruses	Small pox, vaccinia	0	+	+	+	0	0
Orthopoxvirus							
Herpesvirus simplex (1 and 2)	Encephalitis, stomatitis	+	+++	+	+	+	+
Herpesvirus	Chicken pox, shingles	+	+	+	++	+	+
Varicella							
Herpesvirus	Cytomegalic inclusion disease	+	+	+	+	+++	++
Cytomegalovirus							
Herpesvirus	Infectious mononucleosis	+	+	++	+	+	+
Epstein-Barr							
Picornaviruses	Polio myelitis	+	+	+++	+	+	++
Enteroviruses							
Polioviruses							
Picornaviruses	Meningitis	+++	+	++	+	+	0
Enteroviruses							
Coxsackievirus							
Picornaviruses	Meningitis	+++	+	+	+	+	+
Enteroviruses							
Echovirus							
Picornaviruses	Acute hemorrhagic conjunctivitis	++	+	++	+	0	+
Enteroviruses							
Picornaviruses	Common cold	+	0	+	+	+	0
Rhinoviruses							
Orthomyxoviruses	Flu	+	+	+	+	+	+
Influenza (A and B)							
Paramyxoviruses	Flu	+	+	+	+	+	0
Parainfluenza							
Paramyxoviruses	Parotitis	++	++	+	+	0	0
Mumps							
Paramyxoviruses	Measles, distemper	+	++	+	+	+	+++
Morbillivirus							
Measles							
Togaviruses	Rubella, PRP	+	+	+	+	+++	+++
Rubivirus							
Togaviruses	Group A encephalitis	+	+++	+	0	+	0
Alphavirus							
Togaviruses	Group B encephalitis	+	++	+	0	0	0
Flavivirus							
Retroviruses	Leukemia, AIDS	+	+	+	++	+	+++
Oncoviruses							
HTLV-I-III							
Reoviruses	Colorado tick fever	+	+	+	0	0	0
Orbivirus							
Reoviruses	Infantile diarrhea	+	+	+	0	0	0
Rotavirus							
Rhabdoviruses	Rabies, stomatitis	+	+	+	+++	+	+
Lyssavirus							
Vesiculovirus							
Bunyaviruses	California encephalitis, sandfly fever	+	++	0	0	0	0
Arenaviruses							
LCM virus	Lymphocytic choriomeningitis	++	+	+	+	0	0
Coronaviruses	Acute upper respiratory infection	+	0	0	0	+	0
Caliciviruses							
Norwalk gastroenteritis		0	0	0	+	0	0
Unconventional agents	Kuru, Jakob-Creutzfeldt disease	0	0	0	0	0	+++

# CLINICAL MANIFESTATION ACUTE VIRAL NEUROINFECTION

## 1st. Stage:

flu-like syndrome:  
*Headache, myalgias, arthralgias, fatigue*



Latent period

99 %

Recovery

## 2nd. Stage:

- Headache, myalgias, arthralgias, fatigue
- fever (subfebrility)
- nausea, vomiting
- phypersnsitivity: photophobia, hyperaccusia
- meningeal syndrome - muscular hypertonia

< 1 %

+

Focal neurological findings

MENINGITIS

ENCEPHALITIS


MYELITIS

MENINGO+ENCEFALO+MYELO+POLY+RADIKULO+NEURI+TIS



# CLINICAL MANIFESTATION ACUTE VIRAL NEUROINFECTION

## Focal neurological findings




### MENINGITIS

- without neurologic involvement



### ENCEPHALITIS

- disturbances of consciousness
- paresis - central
- cerebellar syndrome
- vestibular syndrome
- tremor
- any other neurologic findings central and peripheral



### MYELITIS

- paresis central or peripheral
- pain
- disturbances of sensitivity paresthesias, hypesthesia



# CLINICAL MANIFESTATION

## SUBACUTE and CHRONIC NEUROINFECTION

~~1st. phase:  
většinou nebyva manifestní~~

~~Latency~~

*Slowly increasing symptoms*

- Headache, myalgias, arthralgias, fatigue
- subfebrility (fever)
- nausea, vomiting
- hypersensitivity: photophobia, hyperacusia
- meningeal syndrome – slowly increasing
- (hypersensitivity to stimuli): photodysphoria, hyperacusation

+

Focal neurological findings

MENINGITIS

ENCEPHALITIS

MYELITIS

MENINGO+ENCEPHALO+MYELO+NEURI+TIS

# CLINICAL MANIFESTATION SUBACUTE and CHRONIC NEUROINFECTION

## Focal neurological findings



### MENINGITIS

- without neurologic findings
- cranial nerve involvement



### ENCEPHALITIS

- disturbances of consciousness
- paresis central
- (cerebellar syndrome)
- (vestibular syndrome)
- tremor
- any neurol. findings.



### MYELITIS

- paresis central or peripheral
- pain
- disturbances of sensitivity paresthesias, hypesthesia

Etiology: TBC, fungi, yeasts, parasites (toxoplasma, cysticercus); slow virus infections; tumor carcinomatosis; mitigated bacterial meningitis, pachymeningitis - posthemorrhagic

# ***DIAGNOSTIC of VIRAL CNS INFLAMMATIONS***

- **CLINICAL:**

- \* *patients' history, neurologic status*

- **LABORATORY METHODS:**

- \* **CSF examination** (*basic- cytologis, biochemic, cultivation, antigens, PCR, ABs, antibody index ...*)

- \* **blood - etiologic diagnostic** (*serology, cultivation, PCR ...*)

- \* *X ray, CT, NMR, angiology ...*

- \* **elektrophysiological methods** (*EEG, VEP, BEP...*)

- \* **other** (*ORL, vestibular, eye ...*)

# ***DIFFERENTIAL DIAGNOSTIC***

- ***VIRAL x NON-VIRAL***
  - *TBE, mitigated bacterial infections, opportunistic infections ...*
- ***VASCULAR DISEASES***
  - *Embolia*
  - *Trombosis arterial, venous, venous sinus trombosis*
  - *Bleeding (SAH, intraparenchymatic, sub-epidural ...)*
  - *Vestibular affection (Menniere attacks)*
  - *Vasculitis*
- ***PARADURAL FOCI (abscesses)***
- ***TUMORS***
- ***INTOXICATION (drugs, chemical agents, botulism, tetanus ...)***
- ***METABOLIC DISEASES***
  - *Toxoinfectious diseases*
  - *Mineral dysballance – Na, K ...*
  - *Metabolic diseases*
- ***PSYCHOSIS and Hysteria***

# THERAPY – ACUTE VIRAL NEUROINFECTIONS

MENINGITIS

ENCEPHALITIS

MYELITIS

**PHYSICAL AND PSYCHIC  
CESSATION !!!**

**ANTIVIRALS**



## SYMPTOMATIC THERAPY:

*Brain edema: mannitol (1,5-2 g/kg/24h), steroids (dexamethason),*

*Balanced fluid intake*

*Analgesia, sedation*

*Hypnotics*

*Anticonvulsants (diazepam, phenytoin ...)*

*Symptomatic therapy (art. ventilation, cardiac action, diabetes, minerals ...)*

CONVALESCENCE: 1) individual, meningitis shorter than encephalitis

2) encephalitis - more severe involvement 3-6 months; !cave postenc. sy!

3) Paresis – longer convalescence cca 75% till 6 months, max. up 2 years

4) Always to inform patient

# THERAPY – ACUTE VIRAL NEUROINFECTIONS

## MENINGITIS

## ENCEPHALITIS

## MYELITIS

### ANTIVIRALS

#### Against herpetic viruses:

- |  |   |
|--|---|
| * <i>acyclovir</i>                               | <i>HSV 1,2; VZV</i>                     |
| * <i>valacyclovir</i>                            | <i>HSV 1,2; VZV</i>                     |
| * <i>famcyclovir (analog pencycloviru)</i>       | <i>HSV 1,2; VZV</i>                     |
| * <i>ganycyclovir</i>                            | <i>HSV 1,2; VZV; <u>CMV</u></i>         |
| * <i>valgancyclovir (prodrug of gancyclovir)</i> | <i>CMV p.o.!</i>                        |
| * <i>foscarnet</i>                               | <i>CMV</i>                              |
| * <i>cidofovir</i>                               | <i>CMV; adenoviruses, papovaviruses</i> |
| * <i>fomivirsen - intravitreal,</i>              | <i>CMV retinitis</i>                    |

#### Anti-flu:

- \* *amantadin, rimantadin – „classic“ antivirals*
- \* *zanamivir (Relenza Rotadisk)*
- \* *oseltamivir (Tamiflu)*

Other: \* *ribavirin (in some RNA viruses)*

# **THERAPY – ACUTE VIRAL NEUROINFECTIONS**

**MENINGITISA**

**ENCEPHALITIS**

**MYELITIS**

## **ANTIVIRALS**

### **Antiretrovirotics:**

- \* *inhibitors of reverse transcriptasis*
  - \* *nucleoside*
  - \* *nucleotide*
  - \* *non-nucleoside*
- \* *proteainase inhibitors*
- \* *integrase inhibitors*
- \* *inhibitors of fusion*
- \* *inhibitors of entry*



# SALT DISTURBANCES IN U NEUROINFECTIONS

## SY inadekvátní sekrece ADH - SIADH










- hyponatrémie bez hypervolémie resp. deplece Na
- zvýšení sérové hladiny ADH (ve vztahu k aktuální osmo.)
- Příčiny: hnisavé men, TU + paraneoplastické sy, snížení tlaku v levé síni srdeční, SAK, léky, stres
- Terapie: redukce tekutin (1-1,5 l - negativní bilance, substituce Na při hladině pod 125 mmol)

## SY cerebral salt wasting - CSWS

- Hyponatrémie
- Příčiny: SAK, záněty, nádory,
- Terapie: podání Na + tekutiny; fludrocortisone 0,2-0,4 mg/D

## Diabetes insipidus

- hypernatrémie
- dehydratace
- snížená produkce ADH
- Příčiny: 45% idiopatický; záněty, nádory

	Na-sér	Na-moč	Osmo-sér	Osmo-moč	Tělesná voda
<b>SIADH</b>		>20		> Osmo-séra	
<b>CSWS</b>		>20		?	
<b>D. Insipidus</b>		<10		velmi nízká	

↑ sekrece ADH

↑ reabsorpce vody v distálním nefronu

diluční hyponatrémie

↑ objemu plazmy

↓ sekrece aldosteronu

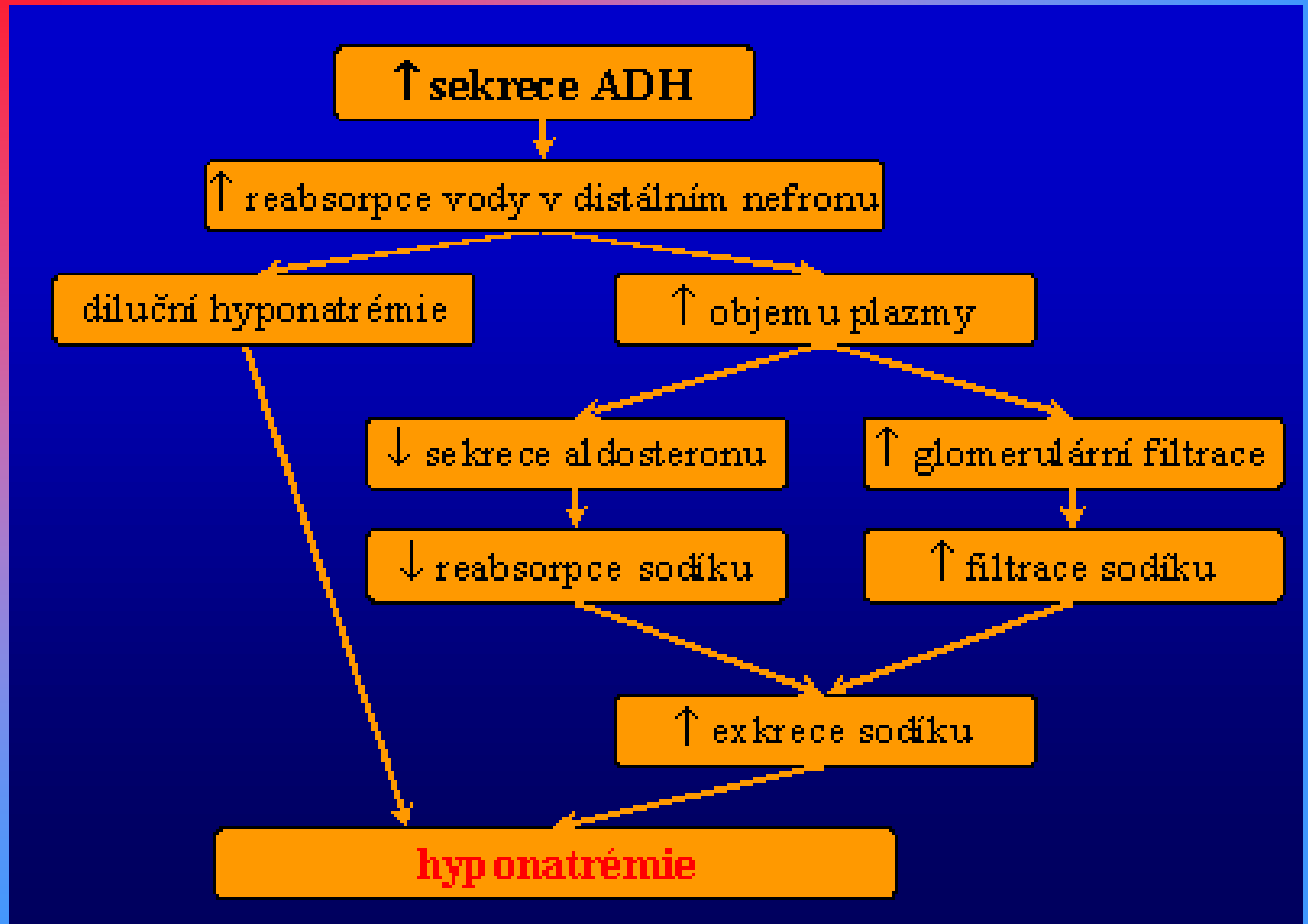
↑ glomerulární filtrace

↓ reabsorpce sodíku

↑ filtrace sodíku

↑ exkrece sodíku

**hyp onatrémie**



# SEQUELAE of NEUROINFECTIONS

## CENTRAL INVOLVEMENT

### FREQUENCY



- ***spastic paresis***
- ***pseudoneurathen. sy.***
- ***disturbances of vision***
  - ***“ of hearing***
  - ***of stability***
- ***tremor***
- ***mental deficit***
- ***PMR***
- ***hydrocephalus***
- ***epilepsy***
- ***d. of sensitivity***
- ***d. of mineral metabol.***

### PURULENT NON-PURUL.

++++	++++
++	++++
+	-+
++	-+
+	++
+	+
+	+
++	+
++++	-
+-	+-
+	-
+-	-

# SEQUELAE of NEUROINFECTIONS

## CENTRAL INVOLVEMENT

### *Pseudoneurasthenic syndrome – postencephalitic syndrome*

- *After encephalitis, less frequently after other infections*
- *Etiology unknown – morphologic tissue changes, scarring of CNS*
- *Clinical manifestations: fatigue, lack of concentration, emotion lability, depression, headache, sleep disturbances*
- *Therapy: symptomatic; restriction in working - „fighting“ do not help*
  - *analgetics, hypnotics, nootropics (rather placebo)*
- *Prevention: sufficient coalescence, to inform patient*
- *Prognosis: quoad vitam very good, quoad sanationem bad – persits long (months, years, somatisation)*

# SEQUELAE of NEUROINFECTIONS

## PERIPHERAL INVOLVEMENT

FREKVENCY



- **flaccid paresis**
- **pain**
- **sensitive deficit**
- **paresthesia**

PURULENT NON-PURUL.

+	+++
+/-	++
+	++

# **PARESIS in INFECTIOUS DISEASES**

## **CENTRAL INVOLVEMENT**

- **spastic (central) paresis: viral encephalitis, purulent meningitis, other meningitis**
  - **myelitis**
- **flaccid paresis: viral myelitis, bacterial infections**

## **PERIPHERAL INVOLVEMENT**

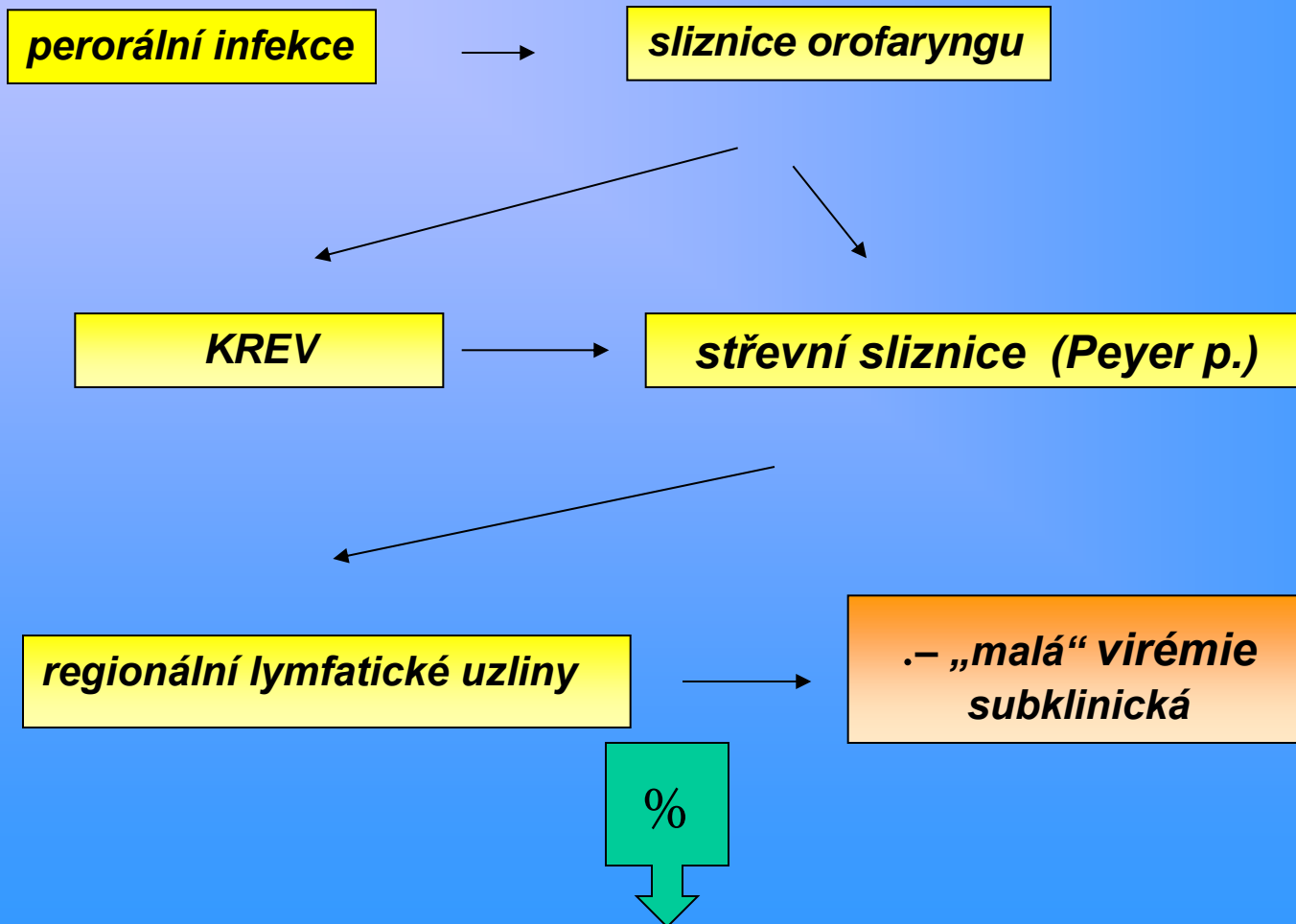
- **flaccid paresis:**
  - **cranial neuritis – viral, purulent meningitis, lyme borreliosis**
  - **plexitis, radiculitis – more viral, lyme borel.,**
  - **polyneuritis, polyradiculoneuritis (GBS)**
  - **distal neuritis – all viral and bacterial infections**

# *The MOST FREQUENT VIRAL NEUROINFECTIONS in CR*

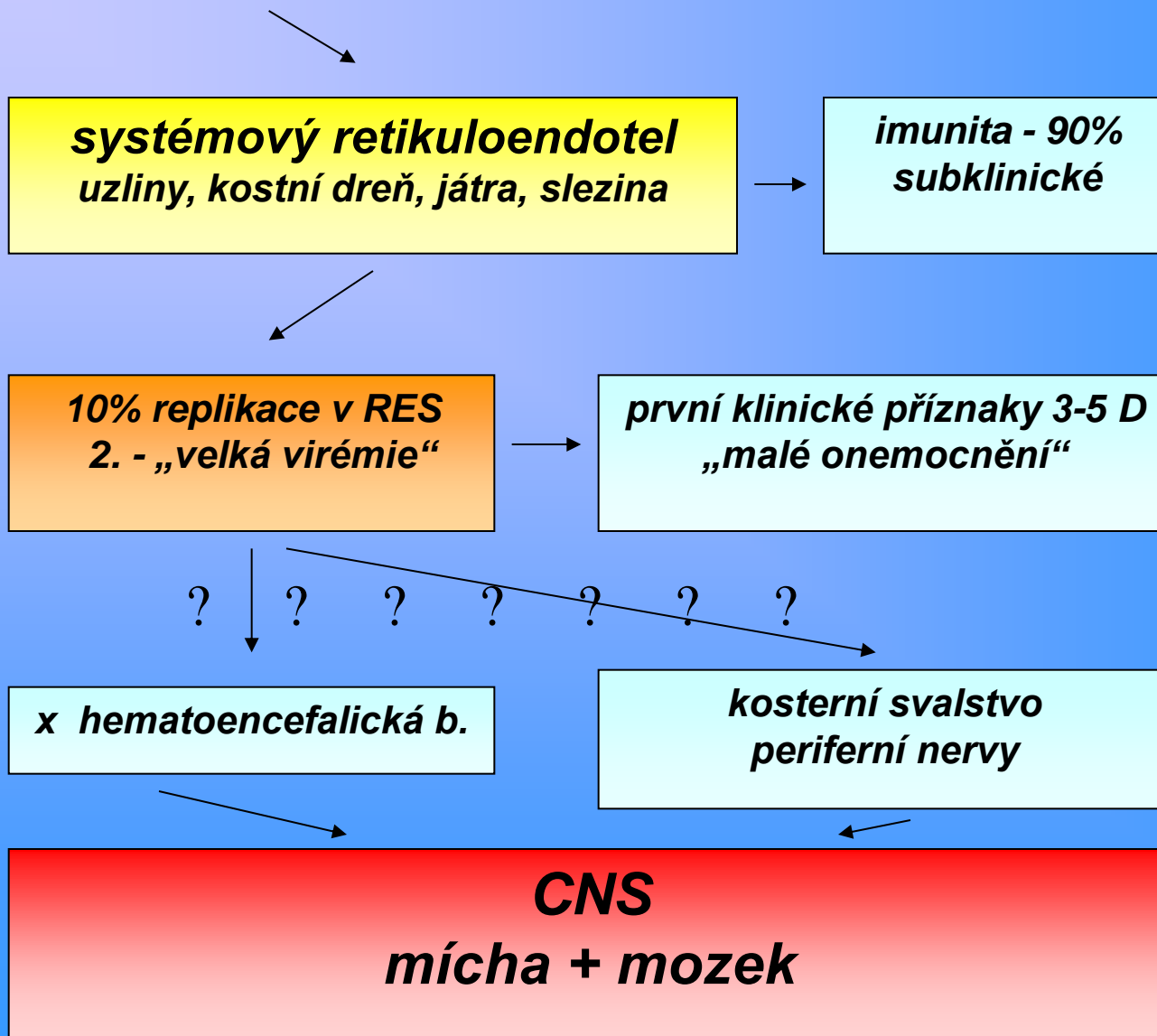

- *TBE*
- *enterovirusis – meningitis or (meningoenceph.)*
- *others – less frequent*
  - *adenovirus*
  - *influenza, parainfluenza*
  - ...



# ***PATOFYZIOLOGIE POLIOVIRŮ I.***



# ***PATOFYZIOLOGIE POLIOVIRŮ II.***



# HERPETIC VIRUSES

- **HSV 1**

- **HSV 2**

- **VZV**

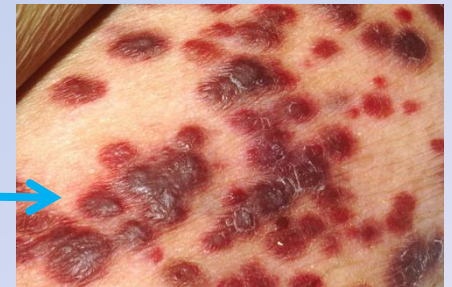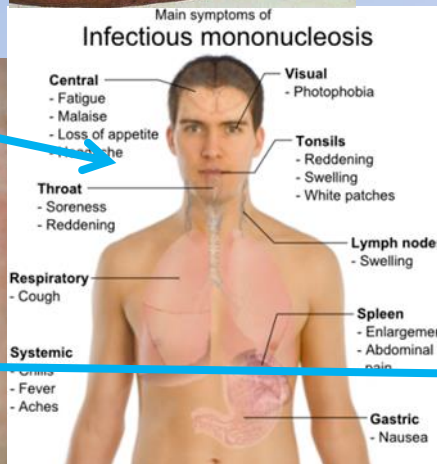
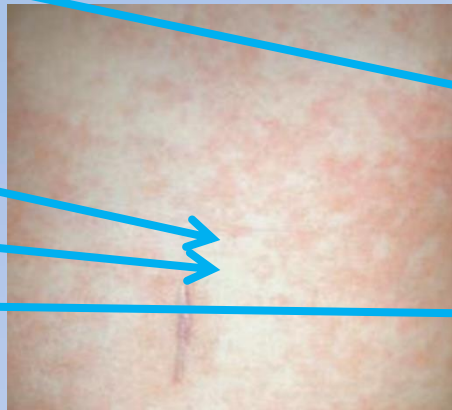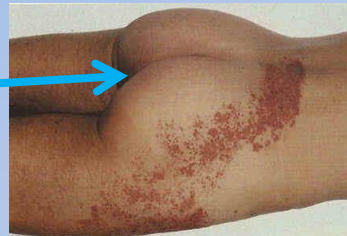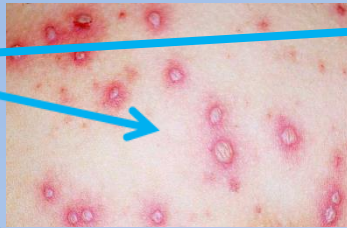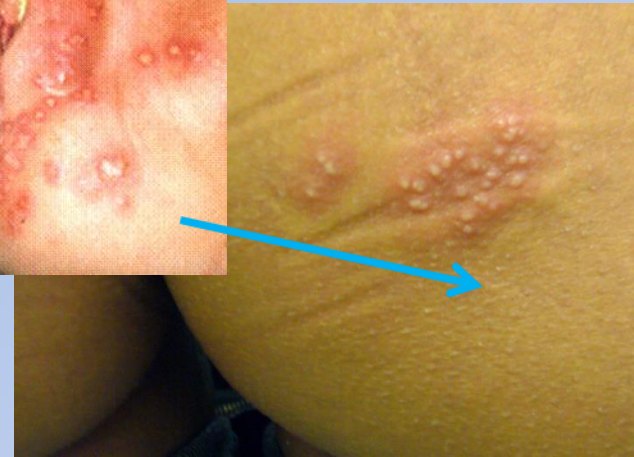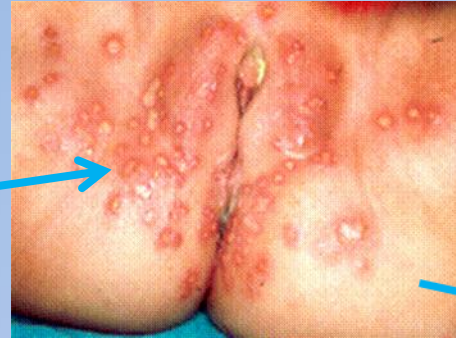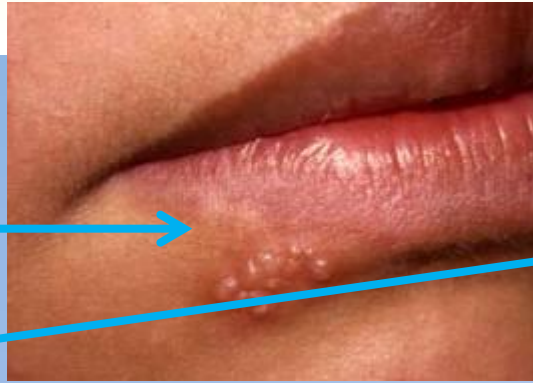
- **EBV**

- **CMV**

- **HHV 6**

- **HHV 7**

- **HHV 8**



# ***PATOHYIOLOGY of INFECTION***

## ***HERPES SIMPLEX 1,2 - I.***

***HSV 1***

***HSV 2***

***prime propagation in mucosa***

***oral GIT***

***urogenital tract***

***retrograde axonal transport  
into regional ganglia***

***ganglion n.V.***

***generalized infectio***  
1) ***mucocutaneous***  
2) ***polyorgan***

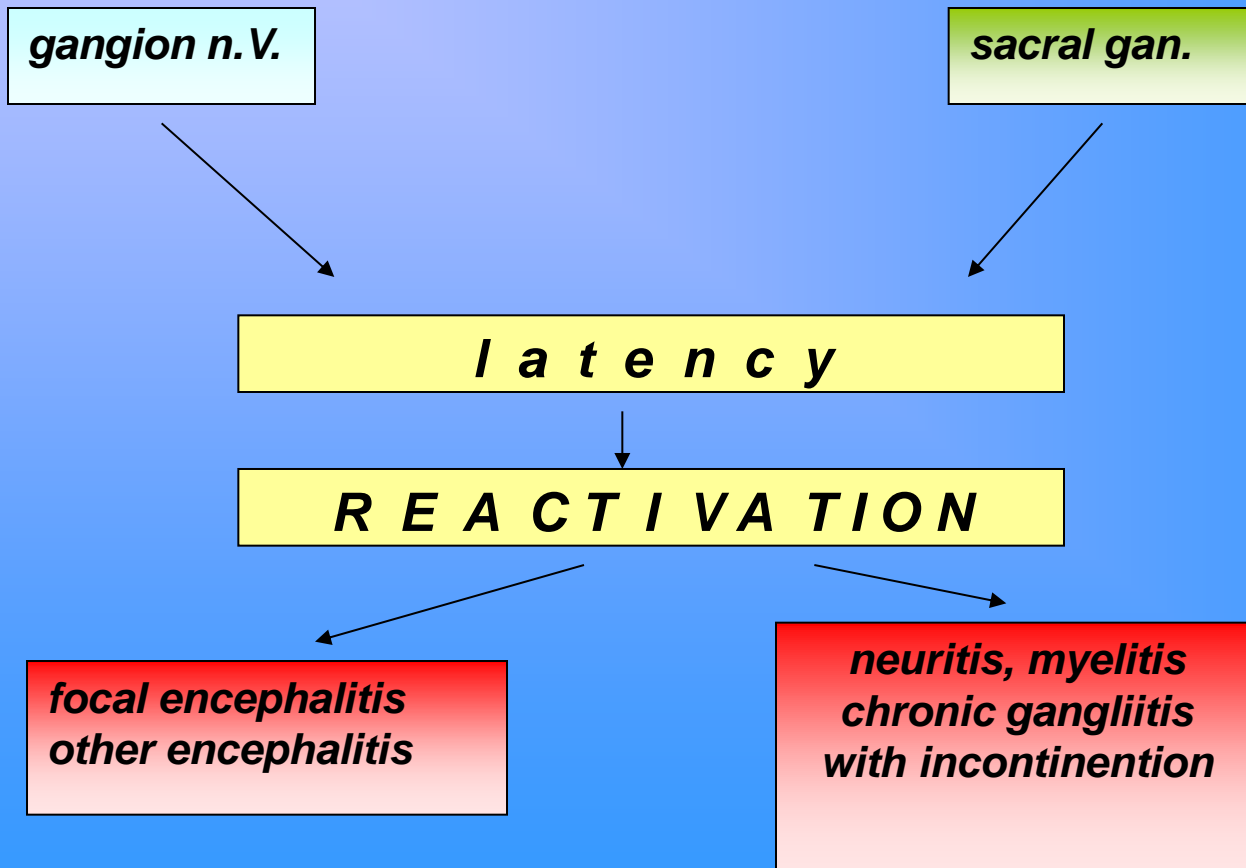
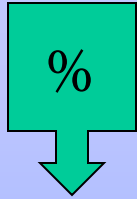
***sacral gan.***

***%***



# ***PATOHYIOLOGY of INFECTION***

## ***HERPES SIMPLEX 1,2 - II.***



# ***HERPETIC VIRUSES***

- ***HSV 1***
- ***HSV 2***
- ***VZV***
- ***EBV***
- ***CMV***
- ***HHV 6***
- ***HHV 7***
- ***HHV 8***

## ***Common features:***

\* ***perzistence of virus in organism***  
***after primoinfection***

\* ***affinity to neurocutaneous***  
***tissues***

\* ***affinity to blood cells***

# ***HERPES SIMPLEX 1 and 2***

## **Common features:**

- ***Related subtypes***
  - ***Both - orofacial and genital lesions – not distinguishable clinically***
  - ***Localization of reactivation depends on subtype of virus***
  - ***Broad spectrum of manifestation from asymptomatic infection to generalized form s multiorgan involvement***
  - ***Typical primoinfection HSV-1 gingivostomatitis  
HSV-2 genital herpes***
  - ***Both of types – can cause anal and proctal inflammations***
  - ***Skin lesions anywhere***



# *HSV 1 and 2*

**ADULTS + OLDER CHILDREN**

## **HERPETIC ENCEPHALITIS -**

- **Etiology: HSV 1 > 95%, rest HSV 2**
- **Focal encephalitis (temporal lobe)**
  - **cca 10% of viral encephalitis in USA**
  - **Two – peak manifestation: 5-30year, over 50 y.**
  - **Pathophysiology:**
    - **1) primoinfection HSV**
    - **2) reinfection with other strain**
    - **3) endogenous reactivation**
- **Pathology:**
  - **virus replication in brain tissue**
  - **vasculitis - hemorrhagy - hemorrhagic encephalitis**

# *HSV 1 and 2*

**ADULTS + OLDER CHILDREN**

## **HERPETIC ENCEPHALITIS**

- **Diagnostic:**
  - ***Clinical manifestaion:***
    - ***fatic – speach - deficit***
    - ***At the beggining non-specific findings (confusion, lethargy, brainstem involvement, similar to other viral enc.***
  - ***PCR – real-time***
  - ***CT, NMR***
  - ***Serology – late marker and not diagnostic (high seroprevalence)***
  - ***Brain biopsy – abandoned in USA and elsewhere; the highest specificity***

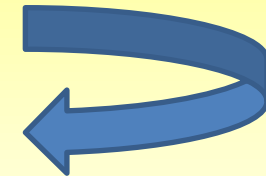
# *HSV 1 and 2*

**ADULTS + OLDER CHILDREN**

## **HERPETIC ENCEPHALITIS**

### **Treatment:**

- ***empirical indication necessary !!!!!***
- ***acyclovir i.v. 10 mg/kg 3times daily***
- ***Duration of treatment – 2-3 weeks***
  - ***Somebody recommends untill negativization of DNA in CSF***
- ***Sparsely recurrences up to 3 months***



### **Sequellae:**

- ***fatic disturbances***
- ***(hemi)paresis – according to the initiation of therapy ...***

# ***HERPES SIMPLEX 1 a 2 TREATMENT*** ***other than encephalitis***

- \* **aseptic meningitis**  
**(acyclovir 3x 5 mg/kg/D)**
- \* **ascendent – transversal myelitis**
- \* **sacral radiculitis**  
**acyclovir 3x 10 mg/kg/D**
- \* **Chronic peripheral neuritis**  
***i.v. x p.o. depends on clinical involvement***

# ***HSV 1 + 2 in PREGNANCY CONGENITAL INFECTION***

- **Risk factor:**
  - ***primoinfection in pregnancy***
  - ***risk are infection HSV 1 and 2 !!***
- ***Fetopathy is uncommon***
- **Clinical manifestation:**
  - ***abortus, embryopathy, fetopathy, growth and PMR***
- ***In recurrent herpes pregnancy usually is not risk – besides of immunocompromized***
- ***Primoinfection of genital herpes in pregnancy should be treated (acyclovir 3x400 mg p.o.; valacyklovir 2x 0,5 – 1g p.o.)***
- **Prophylactic treatment recommendations are not introduced**

# ***CYTOMEGALOVIRUS – CMV NERVE INVOLVEMENT***

- **Congenital infection:**

- **1-2% of seronegative women acquire infection in pregnancy**



**10%  
embryopathy**

- **Multiple organ manifestation**
- **Nerve:**
  - **Microcephalia**
  - **Motor - sensoric disturbances, epilepsy, PMR ....**
  - **Long-lasting excretion of virus !!!!**

- **Perinatal infection – 1) usually asymptomatic**

- **2) can cause excretion of virus**
- **3) fevers – growth retardation**
- **4) pneumonia – hepatitis**
- **5) vision, hearing disturbances, PMR**

# ***CYTOMEGALOVIRUS – CMV NERVE INVOLVEMENT***

- **THERAPY:**
  - *Moderate involvement - only symptomatic treatment*
  - **More severe – organ manifestation and immunocompromized:**
    - *Gancyklovir, foscarnet, cidofovir*
    - *Specific globulin*
    - *Life-long secondary prophylaction (HIV, transplantated)*



# ***EPSTEIN - BARR VIRUS - EBV***

- *Infectious mononucleosis* → **Primo infection**
- *Malignances*
  - *Lymphomas: Burkitt's lymphoma – discovery of EBV in Africa - in 50's,*
  - *Naso-pharyngeal carcinoma*
  - *Hairy leukoplacy of tongue*
  - *Fatigue syndrome*
- *meningitis – encephalitis; myelitis – very rare*  
***cranial and peripheral neuritis, GBS***
- ***THERAPY:***
- ***Symptomatic***
- ***Antiviral drugs***
  - *effective only in the phasis of lytic – early primoinfection*
  - *lately virus entries into the core and antivirals are ineffective*

# ***VIRUS VARICELA – ZOSTER - PRIMO INFECTION***

## ***CEREBELITIS (cerebellar ataxia, encefalopathy)***

- ***Clinical manif.: Children, ataxia, astasia: neo + paleocerebellar sy***
- ***Diagnostic: clinically (exanthema)***
- ***Patogenesis: unknown, immunopathological reaction, replication of virus is not the only or main factor***
- ***Treatment: mostly symptomatic, in immunocompromized or server course - acyclovir i.v.***

## ***ENCEPHALITIS; MYELITIS***

- ***Extremly rare – children and adults the same frequency***
- ***Pathogenesis: diffuse CNS leasion – replication of virus + imunopathological reaction***
- ***Treatment with antivirotics necessary***

# ***VIRUS VARICELA – ZOSTER - RECURRENCE***

- *cranial and peripheral neuritis*
  - *Sy Ramsay-Hunt*
- *leukoencephalitis in AIDS*
- *Post-zoster ditrubances: meningoencephalitis, meningomyelitis, neuritis (multiple), postherpetic neuralgia*

## ***„STROKE“ SYNDROMES***

- *VERY RARE*
- *after varicella, after ocular herpes*
- *especially typical for children and young adults with arterial trombosis*
- *Granulomatous arteriitis – with the proof of VZV antigens in lesions*
- *trombosis of arteria cerebri media*
- *hemiparesis after paresis of n.ophtalmicus (trom. ACA)*

# **VIRUS VARICELLA – ZOSTER - PREGNANCY**

## **CONGENITAL VARICELLA SYNDROME**

- *Varicella in mother in the 1st trimester*
- *Rare*
- *Generalized infection VZV – damage of bones, skull, brain, scarring of skin*

## **NEONATAL VARICELLA**

- *Varicella in mother 2-3 weeks before delivery*
- *Disease is mitigated by mother's antibodies – usually mild disease*
- *Clinically manifested by exanthema (in delivery or shortly after it)*

## **GENERALIZED (ADNATE) VARICELLA**

- *Varicella in mother 5 days before - 2 days after the delivery*
- *Treatment is necessary - acyclovir*
- *Clinical involvement is severe - visceral varicella – skin + other organs (lungs ...)*
- *Prevention – zoster immunoglobulin to newborn, acyclovir*

# HHV 6,7

- *Beta-herpesviruses – roseoloviruses*
- *Target cells:*
  - *T lys and other blood mononuclears*
  - *+ other tissues including CNS*
- *Quick infection of population - in childhood*
  - *40-50% children infected up to 1 year*
- *The most common asymptomatic – subclinical infection*
- *The cause of exanthema subitum*
- *Rarely generalized infection in immunocompromised*

**HHV-6B**

**HHV-7**

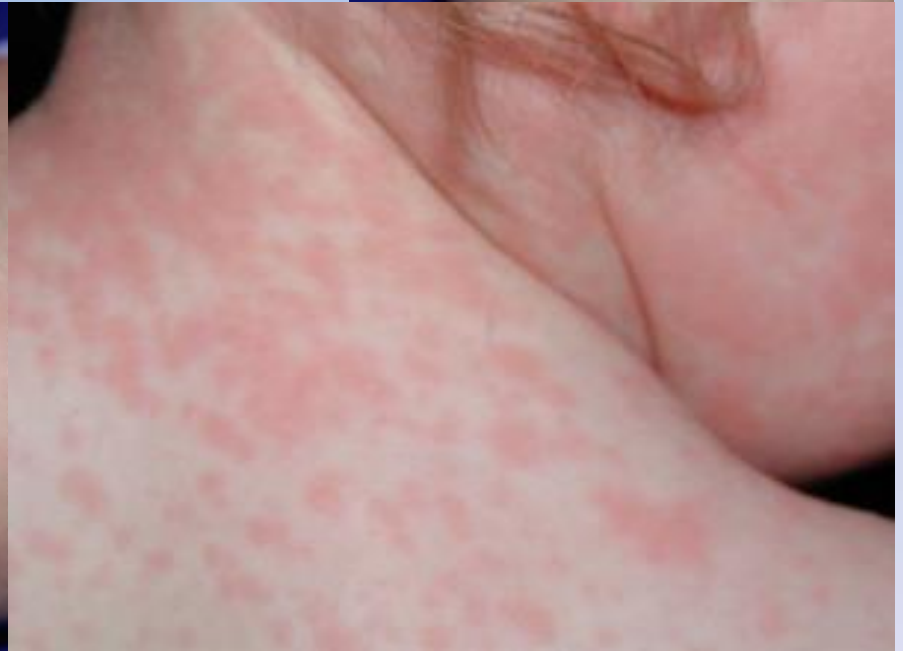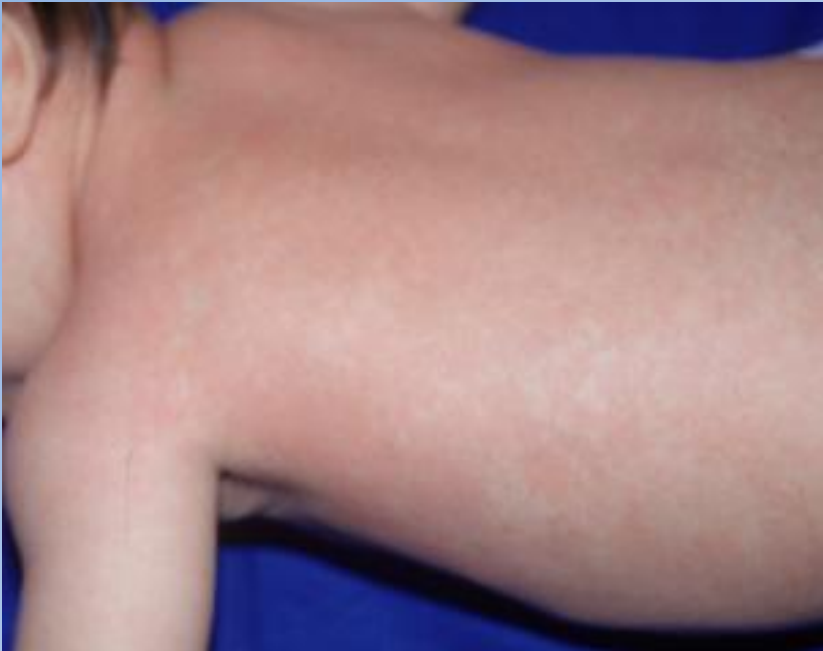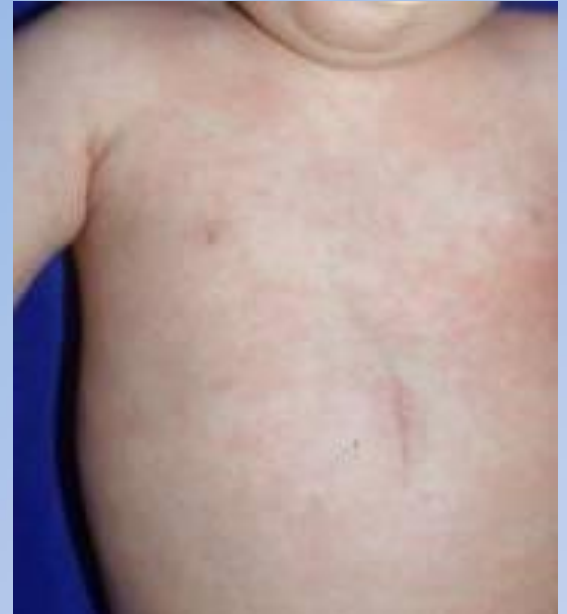# HHV 6

- *HHV 6A + HHV 6B*
- *In many peoples intergated into genom and passed vertically*
- *Clinical manifestations:*
  - *Fever*
  - *Respiratory symptoms, (diarrhoe)*
  - *Exanthema*
  - *Fever convulsions*
    - *It is referred that 1/3 FC is connected with HHV-6*
  - *Rare:*
    - *Meningitis, encephalitis*
    - *cranial neuritis*
    - *Trombocytopenia*
    - *Hepatitis*

*HHV-6A asymptomatic*  
*HHV-6B exanthema subitum*

*Adults – rarely sy inf. mononucleosis*

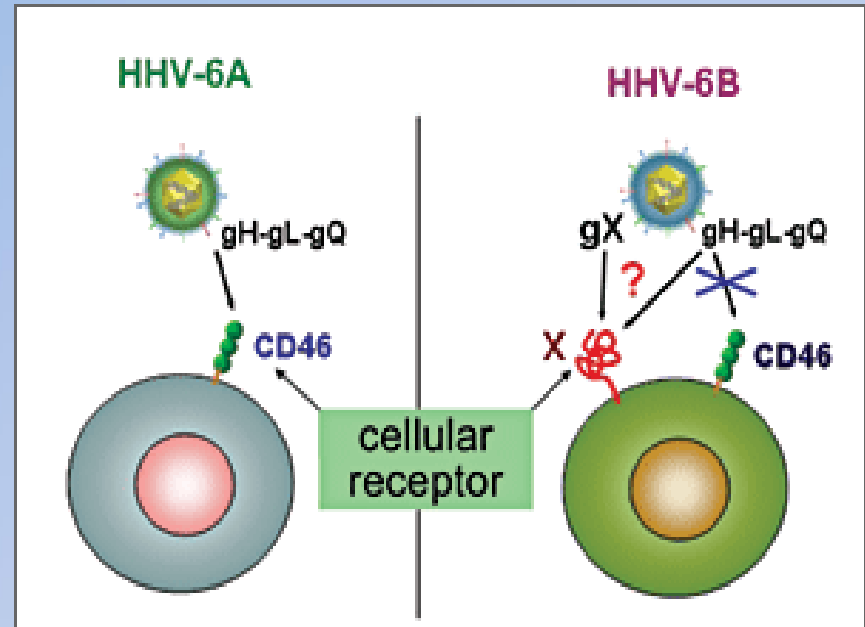
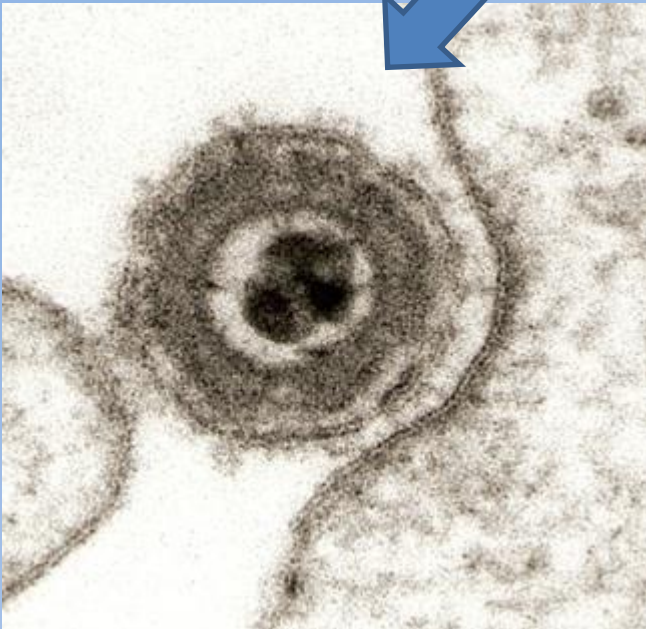
## ***Exanthema subitum***



# HHV 6

**ELMI HHV-6**

**Infection T lymphocyte**





# HHV 6

- **Immunocompromized:**
  - *AIDS – interaction between HIV and HHV-6*
  - *Transplanted*
    - *coinfection CMV + HHV-6*
    - *Rejection of transplanted organ*
    - *Pneumonia in bone marrow transplatation*
- **Diagnostic:**
  - *Serologiy – do not distinguish HHV6A,B, HHV7 infection*
  - *PCR specific but – not routinely available*
- **Treatment:** *gancyclovir, foscarnet, cidofovir*

# HHV 7

- *HHV 7 isolated 1990 from T lymphocytes*
  - *From patient with exanthema subitum*
  - *20-70% homology with HHV 6*
- *Population infected later than HHV 6*
  - *Maximum of infections in age 2-5 year, direct contact – in saliva*
- *Infects many organs*
- *Clinical manif.: – similar to HHV-6:*
  - *Fever*
  - *Respiratory symptoms*
  - *Exanthema*
  - *Febrile convulsions*
  - *Rare:*
    - *Meningitis, encephalitis, cranial neuritis*

**HHV-7 mostly asymptomatic  
exanthema subitum**

# HHV 8

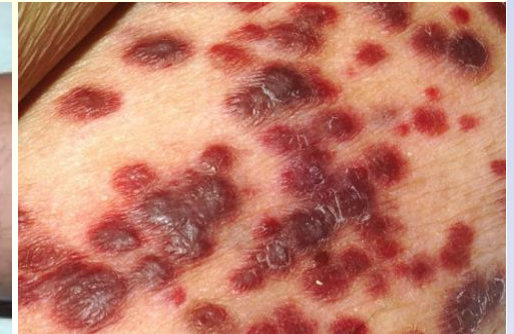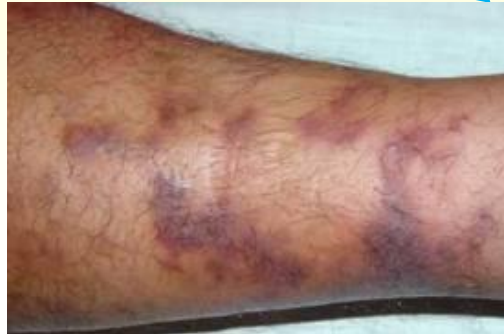## ***Kaposi's sarcoma-associated herpesvirus***

- *Identified in Kaposi's sarcoma – already before HIV pandemia*
- *Rhadinovirus – rezervoire - monkeys od Old and New World*
- *DNA virus*
- *Acquires host genes – „molekular pirate“*
- *Great onkogenic potential*
- *Infection mostly sexually but other way also - saliva ...*
  - *Prevalence correlates with sexual promiscuity*
  - *USA 1-3% of blood donors*
- *Target tissue: B-lymfocytes a fibroblasts*
  - *Is integrated into genom*

# HHV 8

## ***Kaposi's sarcoma-associated herpesvirus***

- **Clinical symptoms:**
  - ***Immunocompetent – inaparent infection***
  - ***Immunocmpromized - cellular deficit – till a few years:***
    - ***Kaposi's sarcoma***
    - ***Angiosarcoma***
    - ***Primary effusion lymfoma***
    - ***Castelman disease – benigne tumor of lymphiod tissue***
- ***Diagnostic:***
  - ***Serology***
  - ***PCR routinely  
not available***
- ***Treatment: unknown***



# ***EPIDEMIC PAROTITIS***

- *Paramyxovirus – related to virus of parainfluenza*
- *Rare under 1 year – mother antibodies*
- *99% decline of morbidity after vaccination – in CR 1987*
- *Neurotropism of virus is high – 50% of patients with mumps have pleiocytosis in CSF*
- *Meningitis (meningoencephalitis):*
  - *Benigne, frequent 1-10% of patients with mumps*
- *Encephalitis:*
  - *Primary - virus – paralelly with beginning of mumps ; neuronal lesion without demyelization; 1:4000-6000 mumps*
  - *„parainfectious“ – with demyeliniztion lesions; more frequent; 7-10 days after oedema of partic glands; imunopathological etiology*
- *Rare complications:*
  - *Hearing loss: – usually unilateral; without vestibular lesion or mild; frequence 4% in young adults*
  - *Rarely: myelitis, facial palsy; GBS ...*
- *Congenital infection:*
  - *Has not been definitely confirmed*
  - *Suspected cases have non-specific symptoms*
- *Therapy symptomatic*

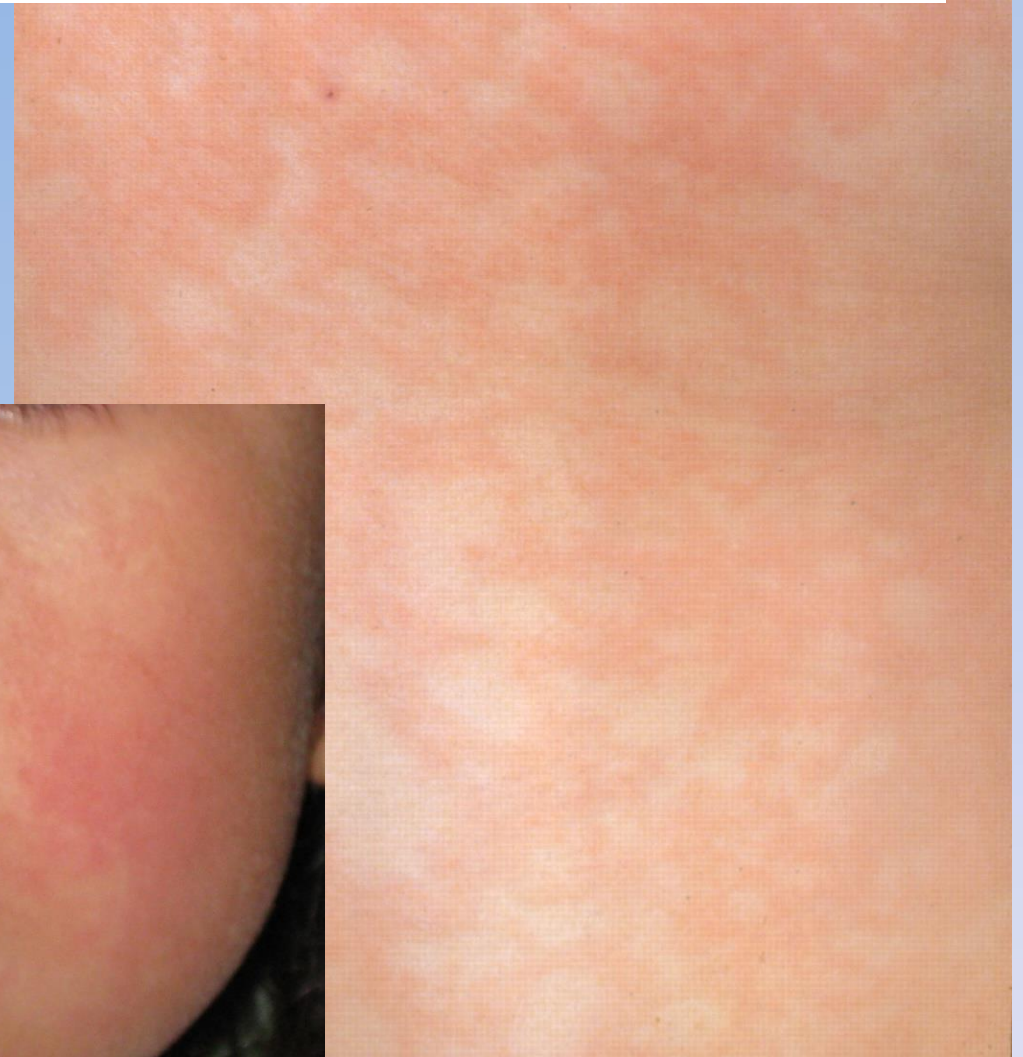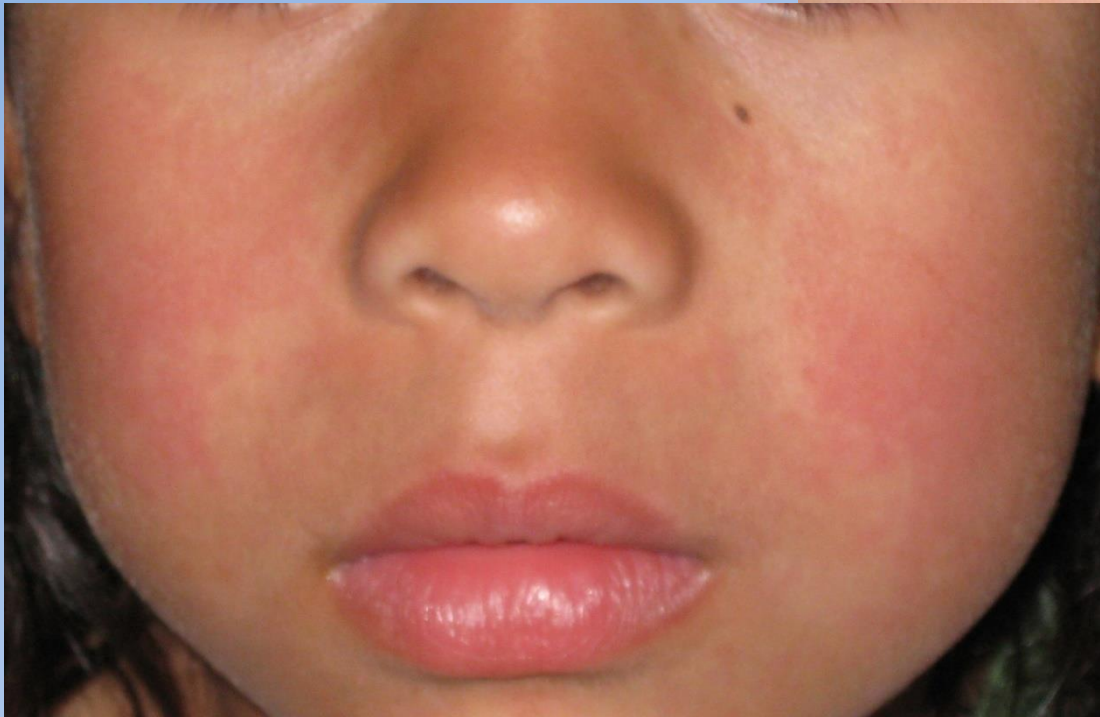# ***PARVOVIRUS B19***

- *Clinical manifestation:*

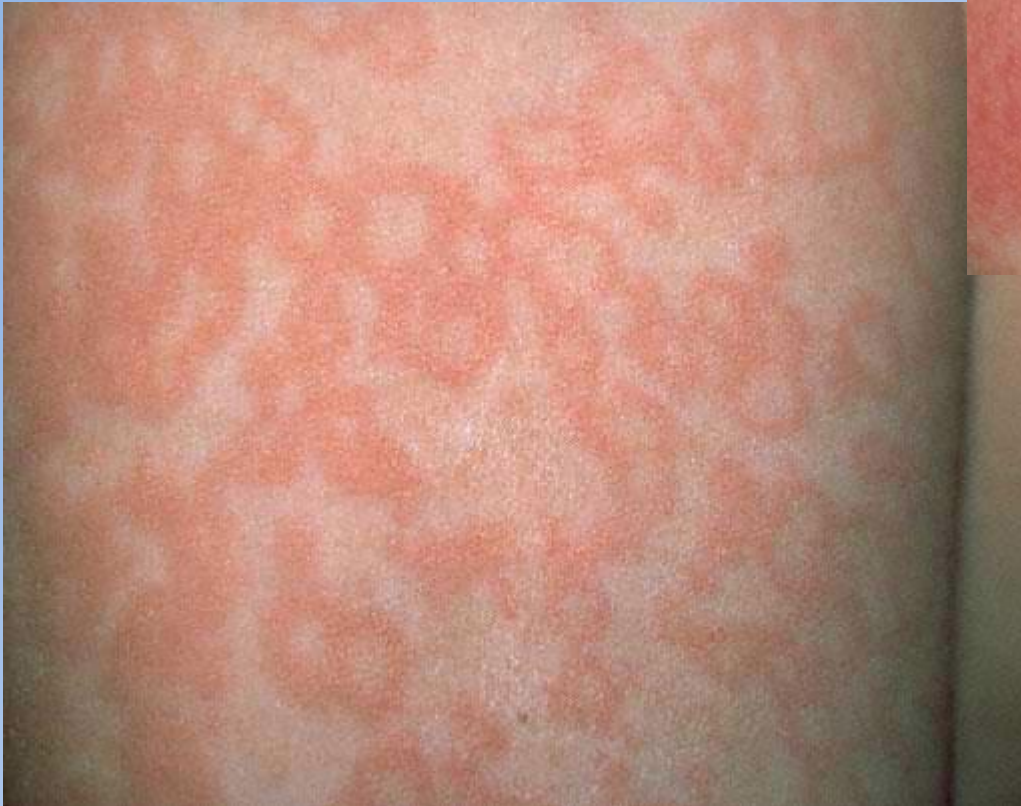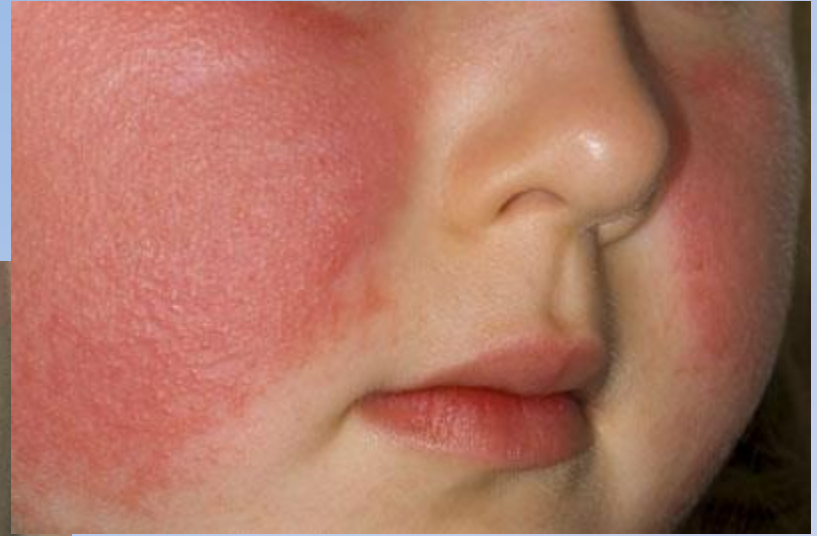- *Asymptomatic – mostly*
- *Megalerythema infectiosum + others nonspecific exanthema (livedo reticularis)*
- *Artralgias, arthritis uncommon*
- *Aplastic crisis in some hematologic diseases - especially „hemolytic type“ (trombocytopenia, erythrocyte aplasia ...*
- *Nonimmune fetal hydrops – the most frequently in first 20 weeks of pregnancy; risk 9%*
- *Aseptic meningitis, encephalitis – rarely*



***PARVOVIRUS B19***  
***Megalerythema infectiosum***



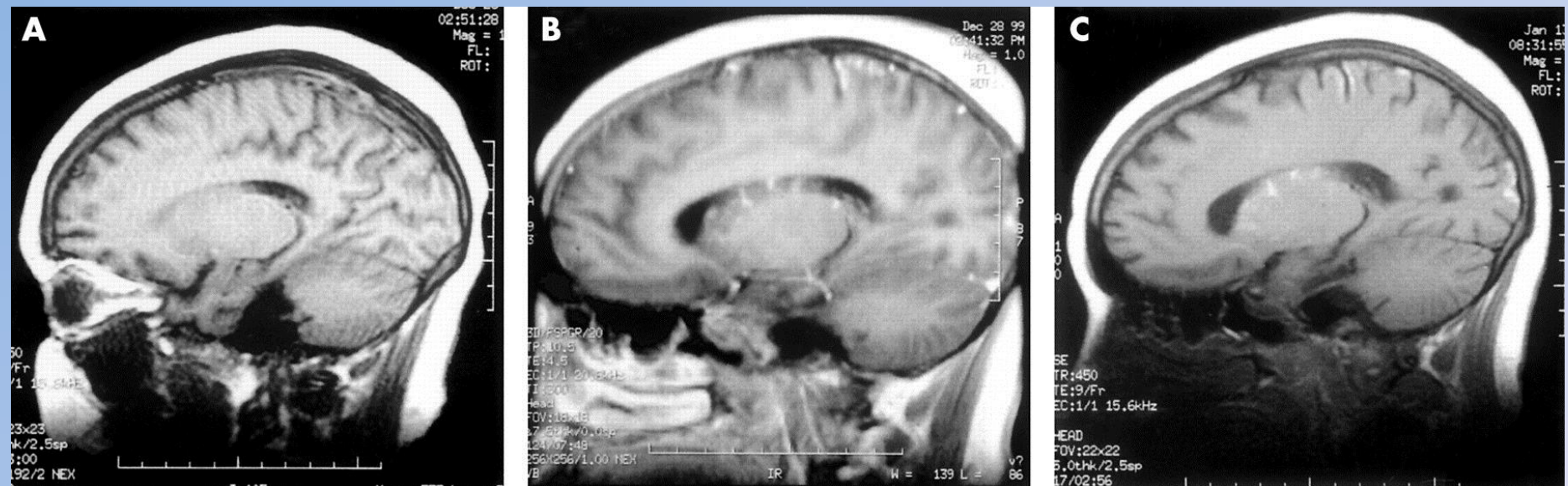
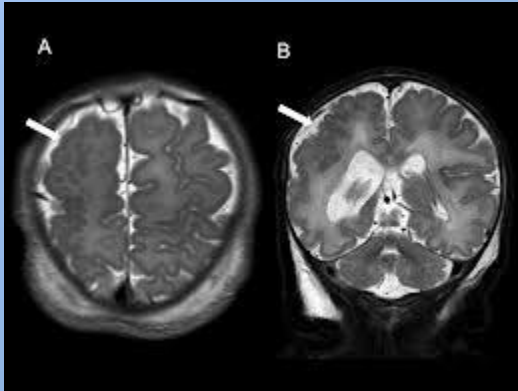
***PARVOVIRUS B19***  
***Megalerythema infectiosum***





# PARVOVIRUS B19

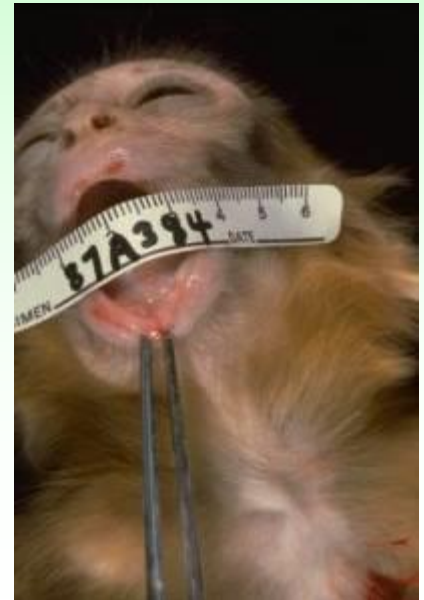A 13 year old girl with haemoglobin **S $\beta$ +thalassaemia** developed simultaneous aplastic crisis and **encephalopathy** associated with parvovirus B19 (PB19) infection. Brain magnetic resonance imaging findings were consistent with central nervous system (CNS) vasculitis and her symptoms resolved with steroid therapy. Thus, PB19 induced CNS hypersensitivity vasculitis must be considered in the differential diagnosis of encephalopathy.



# ***MACACINE herpesvirus 1; HERPES B VIRUS***

- *Macacine herpesvirus 1*; formerly known as *Cercopithecine herpesvirus 1* (*Herpesvirus simiae* or *Herpes B virus*)
- *100% prevalence in some monkey colonies*
  - *In – many macaque species*
- *High virus concentration in saliva* – stressed animals during transportation
- *Clinical manifestation:*
  - *Human infection very rare*
  - *Rarely*
    - *Ascendent myelitis*
    - *Encephalitis*

**Severe disease  
lethal outcome**



# ***MACACINE herpesvirus 1; HERPES B VIRUS***

- ***Treatment:***

- ***Profylaxix:***

- ***Valacyclovir 1g 3times/d***
- ***Acyclovir p.o. 800 mg/5 times /d.***

- ***Treatment:***

- ***No CNS symptoms:***

- ***Acyclovir i.v. 12,5-15 mg/kg 3 times /d***
- ***Or gancyclovir 5 mg/kg 2 times /d***

- ***CNS symptoms:***

- ***Gancyclovir 5 mg/kg 2 times /d***



# EXANTHEMATIC DISEASES I.

## MEASLES

- **CNS involvement**

- • **postinfectious encefalomyelitis:**
  - latency ce 1-2 weeks
  - Immunpathologic pathogenesis – demylinization; virus is not in brain
  - TH – corticosteroids?
- • **inclusion measles encephalitis:**
  - latency weeks – months
  - Inkompletne measles inclusions; multiple RNA mutations
  - TH – ribavirin?
- • **subacute sclerosing pancencephalitis (van Bogaert):**
  - latency years
  - homogeneous clone of mutant virus
  - TH ??

# EXANTHEMATIC DISEASES II.

## RUBELLA

### • CNS involvement

- • postinfectious encefalomyelitis:
  - latency ce 1-2 weeks
  - Immunpathologic pathogenesis – demylinization; virus is not in brain
  - TH – corticosteroids?
- • congenital syndromes:
  - Inkompletne measles inclusions; multiple RNA mutations
  - TH – ribavirin?
- • progressive rubella pancephalitis
  - similar to measles subacute sclerosing pancephalitis
  - uncommon, age 8-21 years
  - Virus isolated rarely from invoved tissues
  - TH - ??

# ***IMMUNE-MEDIATED NEUROPATHIES – Guillain-Barré sy***

**AIDP**

- **Etiology:**
  - *unknown, immunopathologic*
  - *molecular mimicry – cross-reacting antigens; Campylobacter jejuni; anti-ganglioside antibodies (GM1, GM2, GD ...)*
- **Pathology:**
  - *Lymphocytic infiltration; segmental demyelination of nerves; axonal damage also*
- **Clinical symptoms**
  - *Peripheral nerve involvement - ascendent motor deficit, mostly more severe than sensitive symptoms*




# ***IMMUNE-MEDIATED NEUROPATHIES – Guillain-Barré sy***

**AIDP**

- ***Diagnosis:***
  - *1) progressive motor deficit (sensitive or vegetative forms exist)*
  - *2) proteino-cytologic dissociation in CSF*
  - *3) areflexia*
  - *4) conductive block in EMG*
- ***Therapy:***
  - *plasmapheresis*
  - *IVIG 2-4 g/kg*
- ***Prognosis:***
  - *Relative promising – week or months*
  - *Convalescence 1-2 years*

***THANKS for ATTENTION***

***8.8. 2009 - Netherlands***



***30.7.2012 - Germany***